RAJASTHAN UNIVERSITY LIBRARY

DATE LABEL

C. No.....

Accn. No. 46535

Date of Release for loan

This book should be re urned to the library on or before the date marked below.

ARCHIVES OF SURGERY

EDITORIAL BOARD

DEAN LEWIS, Chicago
EVARTS A. GRAHAM, St. Louis
THOMAS CULLEN, Baltimore
HUGH CABOT, Ann Arbor, Mich.
WILLIAM DARRACH, New York City
WILLIAM J. MAYO, Rochester, Minn.

VOLUME 2
1921

PUBLISHERS
AMERICAN MEDICAL ASSOCIATION
CHICAGO, ILL.

(RR)
L:4:7m73:N20
F1
46535

CONTENTS OF VOLUME 2

JANUARY, 1921. NUMBER 1

PAGE

Surgery of Substernal and Intrathoracic Goiters. J. deJ. Pemberton, M.D., Rochester, Minn. 1

Are There Reliable Criteria of Operability in Exophthalmic Goiter? David Cheever, M.D., Boston 21

Repair of Bone Following Fractures. Joseph A. Blake, M. D., New York 37

Treatment of Fracture of the Femur. Kellogg Speed, M.D., Chicago 45

The Association of Hepatitis with Experimental Cholecystitis and Its Bearing on the Pathogenesis of Cholecystitis in the Human. M. G. Peterman, M.D., Walter S. Priest, Jr., M.D., and Evarts A. Graham, M.D., St. Louis 92

The Effect of Combined Radiation and Heat on Neoplasms. G. L. Rohdenburg, M.D., and Frederick Prime, M.D., New York 116

Unrecognized Occupational Destruction of the Tendon of the Long Head of the Biceps Brachii. Arthur William Meyer, M.D., Palo Alto, Calif. 130

Recurrence of Calculi in Common and Hepatic Ducts after Cholecystectomy. George Emerson Brewer, M.D., New York 145

The Rôle of the Ureteral Lymphatics in Experimental Urinary Tract Infections. Vernon C. David, M. D., and Peter M. Mattill, M.D., Chicago 153

Nerve Suture: An Experimental Study to Determine the Strength of the Suture Line. Edwin M. Miller, M.D., Chicago 167

The Correction of Scar Tissue Deformities by Epithelial Grafts: Report of Five Cases. Edmund B. Spaeth, M.D., Washington, D. C. 176

MARCH, 1921. NUMBER 2

The Relation of Chronic Fibrosis and Thrombophlebitis of the Spleen to Conditions of the Blood and of the Liver. William J. Mayo, M.D., Rochester, Minn. 185

Studies in Exhaustion: An Experimental Research. G. W. Crile, M.D., Cleveland 196

Operation for Epiphysitis of the Head of the Femur (Perthes' Disease): Findings and Result. D. B. Phemister, M.D. Chicago 221

The Prognosis in Prostatectomy. John B. Deaver, M.D., and Leon Herman, M.D., Philadelphia 231

Pelvic Abscess: A Study Based on a Series of Seven Hundred and Sixteen Cases. Lawrence R. Wharton, M.D., Baltimore 246

MARCH, 1921—Continued

PAGE

The Gynecologic Significance of Appendicitis in Early Life. William P. Graves, M.D., Boston 315

The Treatment of Pes Cavus (Hollow Claw Foot). Arthur Steindler, M.D., Iowa City 325

Midline Congenital Cervical Fistula of Tracheal Origin. M. G. Seelig, M.D., St. Louis 338

Diverticula of the Jejunum. Wallace I. Terry, M.D., and Frederick R. Mugler, M.D., San Francisco 347

Fracture Reduction and Fixation with a Specially Designed Band. Asa W. Collins, M.D., San Francisco 354

Progress in Orthopedic Surgery: Fourteenth Report of Progress in Orthopedic Surgery. R. B. Osgood, M.D.; R. Soutter, M. D.; M. S. Danforth, M.D.; H. C. Low, M.D.; H. Bucholz, M.D.; L. T. Brown, M.D., and P. D. Wilson, M.D., Boston 367

MAY, 1921. NUMBER 3

Reactions to the Parenteral Introduction of Horse Serum in Man. Fraser B. Gurd, M.D., Montreal, Canada 409

The Relation of Multiple Vascular Tumors of Bone to Myeloma. H. Gideon Wells, M.D., Chicago 435

Three Cases of Subperitoneal, Pedunculated Adenomyoma. Thomas S. Cullen, M.D., Baltimore 443

Observations on the Normally Developing Elbow. Isidore Cohn, M.D., New Orleans 455

The Histogenesis of Malignant Tumors of the Testicle. Oscar T. Schultz, M.D., and Daniel N. Eisendrath, M.D., Chicago 493

Accessory Pancreatic Tissue: Report of Two Cases. E. J. Horgan, M.D., Rochester, Minn. 521

A Short Account of the Deaths Occurring in the Gynecologic Service of the Johns Hopkins Hospital During the Year 1919. Henry N. Shaw, M.D., Baltimore 535

Diverticulum of the First Portion of the Duodenum. Ernest K. Cullen, M.D., Detroit 542

The Effect on the Kidney of Various Surgical Procedures on the Blood Supply, Capsule, and on the Ureters. Stuart W. Harrington, M.D., Rochester, Minn. 547

Tuberculosis of Bone: Results of a Study. Nathaniel Allison, M.D., St. Louis 593

The Treatment of Acute Empyema. J. F. Binnie, C.M., Kansas City, Mo. 627

ARCHIVES OF SURGERY

VOL. 2 JANUARY, 1921 No. 1

SURGERY OF SUBSTERNAL AND INTRATHORACIC GOITERS *

J. DEJ. PEMBERTON, M.D.
ROCHESTER, MINN.

In denoting the presence of a prolongation or of the enlargement of the entire thyroid gland behind the sternum or within the thoracic cavity, the terms "substernal" and "intrathoracic" have been used synonymously. In this article, the term intrathoracic goiter will be limited to those growths of the thyroid in which the major portion of the tumor lies within the thorax. This does not necessarily imply that the greater portion of the entire thyroid gland lies concealed, for obviously the greater portion of the goiter may be cervical and confined to one lobe, while there may be a large, but smaller, growth in the other lobe entirely within the cavity of the chest. All other tumors of the thyroid whose inferior projection, varying in depth below the sternal border from 1.25 cm. to 7.5 cm., and equivalent to less than one half of the growth, are classed as substernal goiters.

MECHANISM OF PRODUCTION

Occasionally in emphysematous patients with short necks the diffuse hyperplastic gland may lie partially behind the sternum, yet its downward projection is usually limited to 1.25 cm. or less, and offers no additional difficulty in its removal. This type will not be considered in this discussion.

The large substernal and intrathoracic growths consist of the simple benign or malignant adenomas, either cystic or solid, and occasionally a diffuse colloid projection. Various causes for the descent of these tumors have been suggested, namely, the pressure exerted by the depressor muscles of the hyoid and the sternomastoid (Lahey), the

* From the Section on Surgery, Mayo Clinic.

* Presented before the Minnesota State Medical Association, St. Paul, Oct. 1, 1920.

1. Lahey, F. H.: Intrathoracic Goiter, Boston M. & S. J. **176**:341 (March 8) 1917; Diagnosis and Management of Intrathoracic Goiters, J. A. M. A. **75**:163-166 (July 17) 1920.

influence of swallowing, ptosis of the larynx, gravity, flexion and extension of the head, and the development of an adenoma in a normally low thyroid, which has been congenitally displaced by traction of the thymus during its embryologic development. All of these may be contributing influences. When the anatomy of the region is borne in mind, it seems natural that the extension of growths developed in the lower poles should be downward behind the sternum. The thyroid is only relatively fixed, since it follows the movements of the trachea in deglutition. It is bound firmly to the trachea by connective tissue attachments, and to the larynx and hyoid bone by median bands,

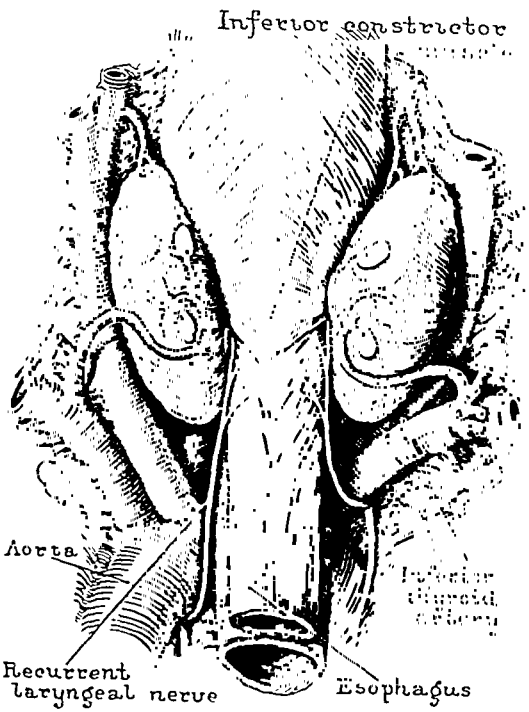

Fig. 1.—Position of recurrent laryngeal nerves and inferior thyroid arteries, viewed posteriorly.

the suspensory ligaments, and it is partly anchored at the points of entrance of the two main arteries. The superior thyroid artery joins the gland at its superior pole, but the inferior thyroid artery enters the capsule on the posterior surface near its mesial border, slightly below a point half way between the superior and inferior poles (Fig. 1). As the inferior thyroid artery ascends in the neck behind the carotid sheath, it is snugly bound behind the prevertebral layer of the deep cervical fascia, from which it emerges a short distance before joining the gland. It will readily be seen that this affords a good anchorage for this portion of the lobe. However, the part of the gland below

this level, amounting to nearly half a lobe, has no firm attachments to the neighboring structures. The inferior thyroid veins leaving the gland at its inferior pole offer only a meager support. The thyroid is loosely encased between the middle and the prevertebral layers of the deep cervical fascia, both of which extend down into the mediastinum. It can be readily appreciated that an adenoma developing in this part of the lobe below the level of the entrance of the inferior thyroid artery will extend downward between the fascial planes in the direction of least resistance. Anteriorly and laterally its extension is resisted by the overlying muscles, especially the sternohyoid, sternothyroid, omohyoid, and the sternomastoid; posteriorly, by the muscles covering the spine, and superiorly, by the firm attachment of the upper part of the lobe to the trachea and to the inferior thyroid artery. Inferiorly, it is separated from the thorax by thin areolar tissue only.

The influences of deep respiratory movements of the thorax in coughing, straining, and the like, play an equally important rôle in the mechanism of production of substernal and intrathoracic goiters. The shape of the thoracic cage is that of an irregular truncated cone. Its reniform inlet formed by an imaginary plane slanting downward and forward from the top of the first thoracic vertebra to the sternum is the narrowest part, the anteroposterior diameter measuring 5.5 cm. and the transverse diameter 10.5 cm. (Woolsey).[2] In forced inspiration the sternum is raised, thus increasing the anteroposterior diameter; since the ribs swing upward and outward, the transverse diameter is likewise increased (Piersol).[3] Also, in deep inspiration, because of the greatly increased capacity of the thorax, a negative pressure is created within the chest which tends to drag the goiter downward. The effect of this can be tested by observing a small cervical goiter entirely disappear behind the sternum when the patient takes a deep breath.

As the adenoma enlarges, the direction of its growth continues in the line of least resistance, that is, downward into the cavity of the chest, where it is obstructed only by the bony walls of the cage. When the condition develops in the young, a deformity of the chest wall may occur (Fig. 2). The shape of the larger tumors is molded by these boundaries, resulting in the characteristic flask or pear shape, the small end corresponding to the constricted inlet. As long as the size of the intrathoracic portion remains less than that of the inlet, the tumor may be forced, partially or completely, up into the neck by coughing or swallowing, which accounts for the occasional so-called

2. Woolsey, G.: Applied Surgical Anatomy, Philadelphia, Lea and Febiger, 1908, p. 228.

3. Piersol, G. A.: Human Anatomy, Ed. 5, Philadelphia, J. B. Lippincott Company, 1916, p. 166.

diving goiter, *goître plongeant* of Fodéré.[4] When the intrathoracic goiter has enlarged so that it cannot be forced up through the narrow strait, one of two things may happen. As the intrathoracic portion is relatively fixed and as the cervical part of the gland continues to follow the movements of the trachea, intermittent traction is exerted at the juncture, and either this connecting portion becomes more attenuated, resulting in a partial or complete detachment of the intra-



Fig. 2 (Case 297878).—Deformity of chest in case of large intrathoracic goiter.

thoracic portion, or the cervical lobe is dragged down into the chest. It appears that a great many of the accessory intrathoracic goiters are developed in this manner from the cervical thyroid rather than from the enlargement of the so-called aberrant thyroid tissue. Analogous growths are not infrequently found in the neck when adenomas lie in the posterior cervical triangle joined to the original goiter by only

4. Fodéré, quoted by Sharpe, N. W.: Report and Analysis of a Goiter with Marked Intrathoracic Extension. Interstate M. J. **18**:314-325, 1911.

a small band of connective tissue, or completely detached, living a parasitic existence. In this series, the intrathoracic tumor was detached from the cervical goiter in seven patients.

INCIDENCE

Within a period of approximately three and one-half years, from Jan. 1, 1917, to June 6, 1920, 4,006 thyroidectomies were performed in the Mayo Clinic for simple colloid and adenomatous goiters. Five hundred and forty-two (13.5 per cent.) were found at operation to be substernal, and twenty-five (0.6 per cent.) of these were classified as intrathoracic.

The duration of the goiter ranged from two months to forty-eight years, averaging eighteen and one-half years. Seven patients had no knowledge of the presence of a goiter. The oldest patient was 71 years of age, the youngest 15, and the average age was 46.11 years.

TABLE 1.—SITUATION OF SUBSTERNAL PROJECTION

Situation	Cases
Right lobe	158
Left lobe	299
Both lobes	66
Isthmus	8
Not noted	11
Total	542

TABLE 2.—DEPTH OF GOITER

Depth	Cases
1.25 cm. to 2.5 cm.	300
3.75 cm. to 5.0 cm.	170
6.25 cm. to 7.5 cm.	60
8.75 cm. to 12.5 cm.	12

The influence of sex does not apparently play an important rôle in the total incidence of substernal goiter. While in the male, heavier neck muscles develop, in the female this additional influence is offset by the fact that the upper aperture is wider, and that thoracic rather than abdominal breathing is the rule. In this series, substernal or intrathoracic goiter occurred in 82 males (13.5 per cent.) and in 460 females, or 1 male to every 5.6 females. During the same period, the ratio of incidence in males and females in all other simple goiters was 469 to 2,295, respectively, or 1 to 6.38. However, of twenty patients between the ages of 15 and 25 with substernal or intrathoracic goiter, six (30.0 per cent.) were males.

There was malignant degeneration in seven goiters.

SYMPTOMS

Substernal and intrathoracic goiters, are, in the greater number of cases, associated with cervical enlargement, and the symptoms from which the patient seeks relief vary from deformity of the neck to a train of symptoms incident to hyperthyroidism, or to the pressure of the tumor on the neighboring structures.

In seventy-two patients of the series, there were no symptoms other than the presence of a tumor. In 128 patients (25.4 per cent.), the goiter was associated with definite hyperthyroidism, evidenced by



Fig. 3 (Case 297878).—Anteroposterior view of large intrathoracic goiter shown in Figure 2, before operation.

the symptoms and physical examination and corroborated by an increased basal metabolic rate.

The symptoms resulting from the pressure of the substernal tumor vary according to the structure compressed, and the symptoms and their intensity vary not in proportion to the size of the tumor, but to the degree of compression. A small adenoma lying just within the inlet, in front of or behind the trachea, may produce marked dyspnea or choking spells, while a huge, completely intrathoracic tumor

may be wholly without pressure symptoms. This is illustrated by the subjoined case history.

History (Case 297878).—A man, aged 21, was admitted to the Mayo Clinic, Nov. 25, 1919, having been discharged from the army a year before on account of tachycardia. The patient stated that he had always enjoyed good health and had been an active athlete. Because he did not have so much "pep" as formerly, he consulted a physician a few weeks prior to his admission to the Clinic. A diagnosis of exophthalmic goiter in a substernal thyroid was made by his family physician. There was no dyspnea, palpitation, or other complaint.



Fig. 4 (Case 297878).—Lateral view of large intrathoracic goiter shown in Figure 2, before operation.

The patient said that his chest had always been prominent, probably more than usually prominent for the last six months (Fig. 2). He had not lost weight.

Examination.—No enlargement in the cervical region was found; but there was an area of dulness which extended downward 5 cm. on each side of the midsternal line. The systolic blood pressure was 164, the diastolic 84, and the pulse 120. The urine was normal. The basal metabolic rate taken on three different occasions was +33, +29 and +23. A roentgenogram revealed a bilateral mediastinal tumor, and the fluoroscopic examination revealed a mediastinal mass atypical for substernal goiter (Figs. 3 and 4). There was no

SYMPTOMS

Substernal and intrathoracic goiters, are, in the greater number of cases, associated with cervical enlargement, and the symptoms from which the patient seeks relief vary from deformity of the neck to a train of symptoms incident to hyperthyroidism, or to the pressure of the tumor on the neighboring structures.

In seventy-two patients of the series, there were no symptoms other than the presence of a tumor. In 128 patients (25.4 per cent.), the goiter was associated with definite hyperthyroidism, evidenced by

Fig. 3 (Case 297878).—Anteroposterior view of large intrathoracic goiter shown in Figure 2, before operation.

the symptoms and physical examination and corroborated by an increased basal metabolic rate.

The symptoms resulting from the pressure of the substernal tumor vary according to the structure compressed, and the symptoms and their intensity vary not in proportion to the size of the tumor, but to the degree of compression. A small adenoma lying just within the inlet, in front of or behind the trachea, may produce marked dyspnea or choking spells, while a huge, completely intrathoracic tumor

may be wholly without pressure symptoms. This is illustrated by the subjoined case history.

History (Case 297878).—A man, aged 21, was admitted to the Mayo Clinic, Nov. 25, 1919, having been discharged from the army a year before on account of tachycardia. The patient stated that he had always enjoyed good health and had been an active athlete. Because he did not have so much "pep" as formerly, he consulted a physician a few weeks prior to his admission to the Clinic. A diagnosis of exophthalmic goiter in a substernal thyroid was made by his family physician. There was no dyspnea, palpitation, or other complaint.



Fig. 4 (Case 297878).—Lateral view of large intrathoracic goiter shown in Figure 2, before operation.

The patient said that his chest had always been prominent, probably more than usually prominent for the last six months (Fig. 2). He had not lost weight.

Examination.—No enlargement in the cervical region was found; but there was an area of dulness which extended downward 5 cm. on each side of the midsternal line. The systolic blood pressure was 164, the diastolic 84, and the pulse 120. The urine was normal. The basal metabolic rate taken on three different occasions was +33, +29 and +23. A roentgenogram revealed a bilateral mediastinal tumor, and the fluoroscopic examination revealed a mediastinal mass atypical for substernal goiter (Figs. 3 and 4). There was no

SYMPTOMS

Substernal and intrathoracic goiters, are, in the greater number of cases, associated with cervical enlargement, and the symptoms from which the patient seeks relief vary from deformity of the neck to a train of symptoms incident to hyperthyroidism, or to the pressure of the tumor on the neighboring structures.

In seventy-two patients of the series, there were no symptoms other than the presence of a tumor. In 128 patients (25.4 per cent.), the goiter was associated with definite hyperthyroidism, evidenced by

Fig. 3 (Case 297878).—Anteroposterior view of large intrathoracic goiter shown in Figure 2, before operation.

the symptoms and physical examination and corroborated by an increased basal metabolic rate.

The symptoms resulting from the pressure of the substernal tumor vary according to the structure compressed, and the symptoms and their intensity vary not in proportion to the size of the tumor, but to the degree of compression. A small adenoma lying just within the inlet, in front of or behind the trachea, may produce marked dyspnea or choking spells, while a huge, completely intrathoracic tumor

may be wholly without pressure symptoms. This is illustrated by the subjoined case history.

History (Case 297878).—A man, aged 21, was admitted to the Mayo Clinic, Nov. 25, 1919, having been discharged from the army a year before on account of tachycardia. The patient stated that he had always enjoyed good health and had been an active athlete. Because he did not have so much "pep" as formerly, he consulted a physician a few weeks prior to his admission to the Clinic. A diagnosis of exophthalmic goiter in a substernal thyroid was made by his family physician. There was no dyspnea, palpitation, or other complaint.



Fig. 4 (Case 297878).—Lateral view of large intrathoracic goiter shown in Figure 2, before operation.

The patient said that his chest had always been prominent, probably more than usually prominent for the last six months (Fig. 2). He had not lost weight.

Examination.—No enlargement in the cervical region was found; but there was an area of dulness which extended downward 5 cm. on each side of the midsternal line. The systolic blood pressure was 164, the diastolic 84, and the pulse 120. The urine was normal. The basal metabolic rate taken on three different occasions was +33, +29 and +23. A roentgenogram revealed a bilateral mediastinal tumor, and the fluoroscopic examination revealed a mediastinal mass atypical for substernal goiter (Figs. 3 and 4). There was no

exophthalmos. A diagnosis of mild hyperthyroidism in an intrathoracic goiter was made.

Operation and Results.—A partial thyroidectomy, resection of the left lobe and division of the isthmus, was performed, Dec. 12, 1919, for a single degenerated colloidal adenoma in a substernal goiter. A huge substernal goiter, about 12 or 15 cm. in diameter, lay in front of the trachea, resting on the base of the heart. It originated in the left lobe and probably the isthmus, drawing the isthmus and superior pole of the left lobe down to the base of the neck. The curved collar incision was prolonged downward, with the idea

Fig. 5 (Case 297878).—Patient shown in Figure 2, after operation.

of splitting the sternum if necessary. The gland was ruptured to reduce its volume before bringing it out of the chest cavity. Tissue amounting to one fourth of a normal sized lobe was preserved on the left side of the trachea.

The patient's postoperative convalescence was normal (Figs. 5 and 6). The metabolic rate, Dec. 24, 1919, was + 9. December 30, the blood pressure was 116 systolic, and 74 diastolic; the pulse rate was 78.

The more snugly the tumor is wedged into the thoracic aperture, the more pronounced are the symptoms. The retrosternal tumor lies

in close relation to the trachea, esophagus, common carotid artery, internal jugular vein, pneumogastric, sympathetic, phrenic, and recurrent laryngeal nerves, and as it descends, it is in close relation to the innominate and subclavian vessels, the thoracic duct, lungs, bronchi, the arch of the aorta, and the pericardium (Fig. 7). On account of the capaciousness of the thoracic cavity and the relative movability of its contents, the completely intrathoracic goiter may be without symptoms, since all the structures can be displaced without being

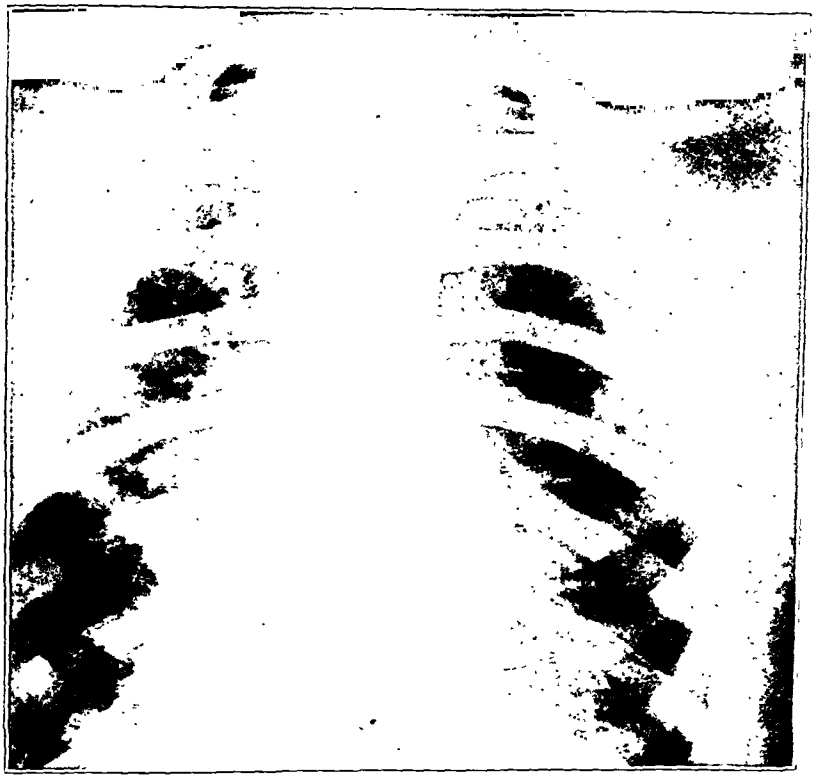

Fig. 6 (Case 297878).—Anteroposterior view of chest of patient shown in Figures 3 and 4, after operation.

actually compressed. The recurrent laryngeal nerve is an exception, as displacement of the large arterial trunks may exert traction resulting in its partial or total paralysis. However, any structure that passes through the upper thoracic aperture may be compressed by the goiter, with resulting symptoms. Pain is practically never present unless the tumor is malignant, but a sense of pressure or fulness is very frequent. Symptoms arising from pressure on the trachea, the recurrent laryngeal and the internal jugular vein are the most frequent.

Definite tracheal deformity was noted in 163 patients (30 per cent.) of the series. The tumor may lie anterior, posterior, or to the side of the trachea, and the symptoms, if any, are varying degrees of dyspnea, such as rasping breathing with inspiratory stridor, and choking and coughing spells. Sudden muscular exertion or extension or flexion of the head may cause the tumor to become wedged in the inlet, resulting in spells of obstructive breathing, with choking and coughing. Dilated veins in the neck and on the chest wall were noted in fifty-eight patients (10.7 per cent.), (Figs. 8, 9 and 10). Laryngeal

Fig. 7 (Case 333997).—Huge intrathoracic goiter filling the right upper portion of the chest.

examinations were recorded for 452 patients, and in forty-five (10 per cent.) a partial or complete paralysis of one or both cords was noted, although hoarseness was recorded in only twenty-nine patients.

DIAGNOSIS

In the presence of a cervical enlargement, a substernal or intrathoracic goiter can frequently be diagnosed by palpation. In most cervical goiters, the inferior pole of the lobe is well outlined when

the patient swallows or coughs. If the limit of the lower pole cannot be palpated, a substernal projection is suspected. If the neck is not enlarged, often a tumor may be felt or seen above the clavicle or sternum when the patient swallows or coughs. With the larger growths, percussion may reveal dulness. Many have emphasized the importance of the sudden disappearance of a cervical goiter with or without the appearance of marked obstructive symp-

Fig. 8 (Case 320327).—Huge intrathoracic goiter producing marked obstruction and dilatation of veins over neck and chest.

toms. In only seven patients in this group was an appreciable diminution in the size of the goiter noted, and in three of these the history was indefinite. Only one patient gave a definite history of disappearance of the gland, with the production of obstructive respiratory symptoms. As the shadow of a small, retrosternal goiter may not be discerned in the roentgenogram the final preoperative diagnosis rests on the fluoroscopic examination.

OPERATIVE TECHNIC

In patients with large substernal goiters, or in those who have any obstructive dyspnea, local anesthesia should be employed. Not infrequently when the patient is under the influence of a general anesthetic serious respiratory obstruction is encountered, either during the elevation of the tumor or even before the incision in the skin has been made. In many of these patients, the pressure of the goiter on the trachea has so embarrassed breathing that the accessory muscles of respiration have been brought into play, especially the sternomas-

Fig. 9 (Case 320327).—Goiter shown in Figure 8.

toids, trapezius, pectoralis major and minor, rhomboideus major and minor, and the erector spinae. Under a general anesthetic the assistance of these muscles is lost, and respiratory movement may be extremely difficult or impossible. In such cases the operator must either hastily elevate the tumor, or perform a tracheotomy. If possible both procedures should be avoided. When the goiter is raised hastily, frequently the thyroid veins, and sometimes the inferior thyroid artery, are torn. Attempts to clamp these may result in the injury of important neighboring structures, such as the internal jugular vein

and the recurrent laryngeal nerve. The technic of the operation was recently described by Judd.[5]

The thyroid is approached through the usual low transverse incision, reflecting upward a flap of skin and the platysma muscle. It is essential that all the bleeding vessels are caught and tied before the goiter is approached; otherwise the field of operation may be partially obstructed by the presence of hemostats. The goiter is exposed by dividing the fascia in the midline between the two sterno-

Fig. 10 (Case 320327).—Patient shown in Figure 8, after operation.

hyoids. These muscles are divided between clamps, including a part of the sternocleidomastoid if necessary for better exposure.

As tracheal obstruction may be encountered at any stage of the operation, the surgeon should at once locate the trachea; its position may be greatly changed from the normal, owing to the pressure of the tumor. The first step in removing the intrathoracic goiter is free-

5. Judd, E. S.: Intrathoracic Goiter, Internat. Clin. **1**:149, 1920.

ing the superior pole by dividing the superior thyroid vessels between double clamps (Fig. 11). These vessels are tied immediately, in order to rid the operative field of the presence of the forceps, which, if left, might be pulled off during the course of the operation, resulting in troublesome bleeding.

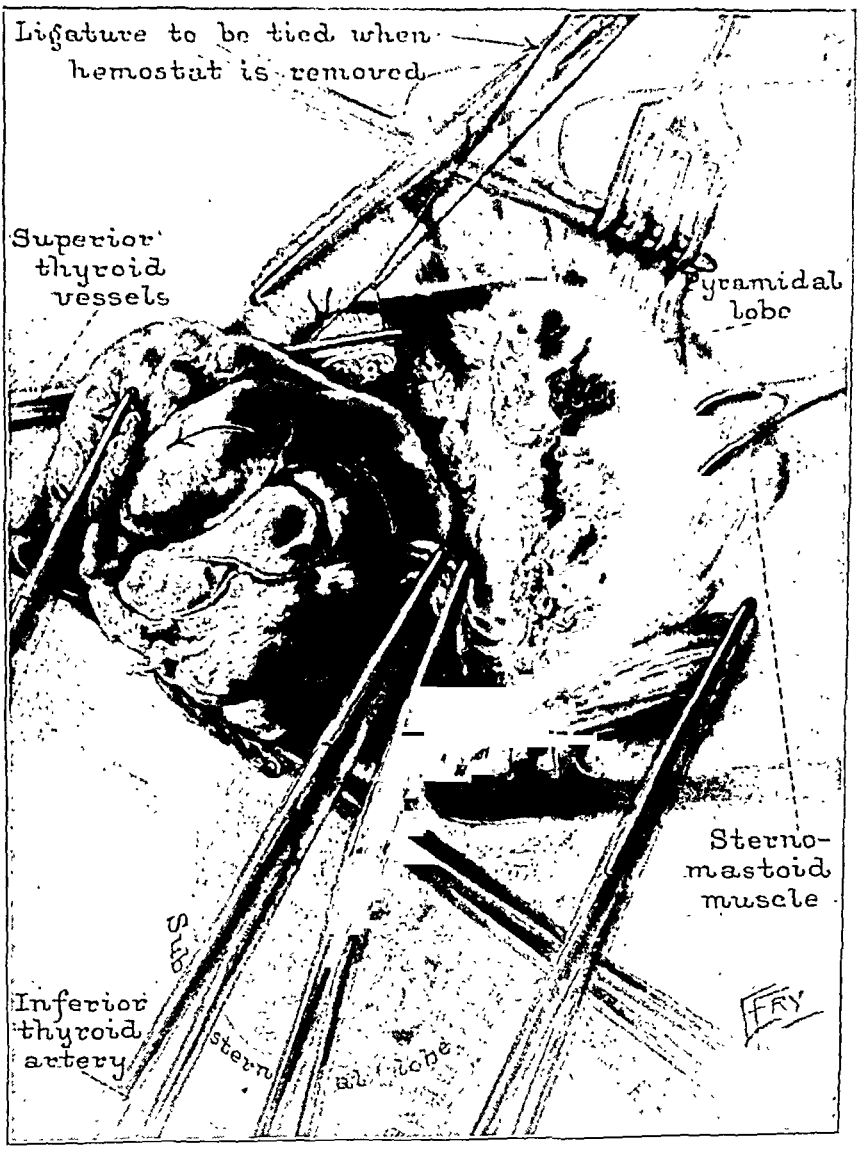

Fig. 11.—Right superior pole of gland free and isthmus divided. Mesial branch of inferior thyroid artery before it is divided.

The middle thyroid vein, which drains a rich plexus of veins beneath the capsule, emerges from the lateral surface of the gland

and enters directly into the internal jugular. This is divided and tied immediately.

The isthmus is then divided and the lobe freed from its attachment to the trachea. By traction on the tumor in a forward and slightly downward direction, the goiter may be resected from above

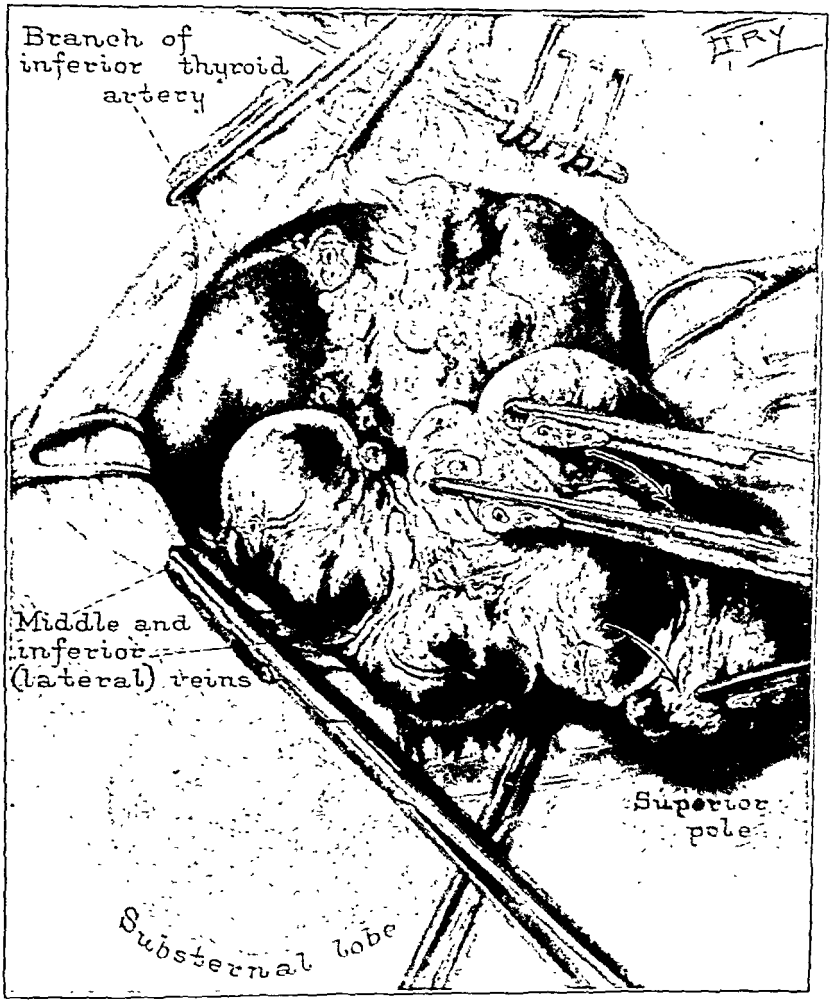

Fig. 12.—Superior thyroid pole drawn downward and inward. Both branches of the inferior thyroid artery have been divided and ligated before the substernal tumor is elevated.

downward, leaving the posterior capsule. As the inferior thyroid artery enters the gland near the middle of the lobe and remains partly in the neck in practically all substernal goiters, its branches can be clamped and severed before the substernal projection is raised

ing the superior pole by dividing the superior thyroid vessels between double clamps (Fig. 11). These vessels are tied immediately, in order to rid the operative field of the presence of the forceps, which, if left, might be pulled off during the course of the operation, resulting in troublesome bleeding.

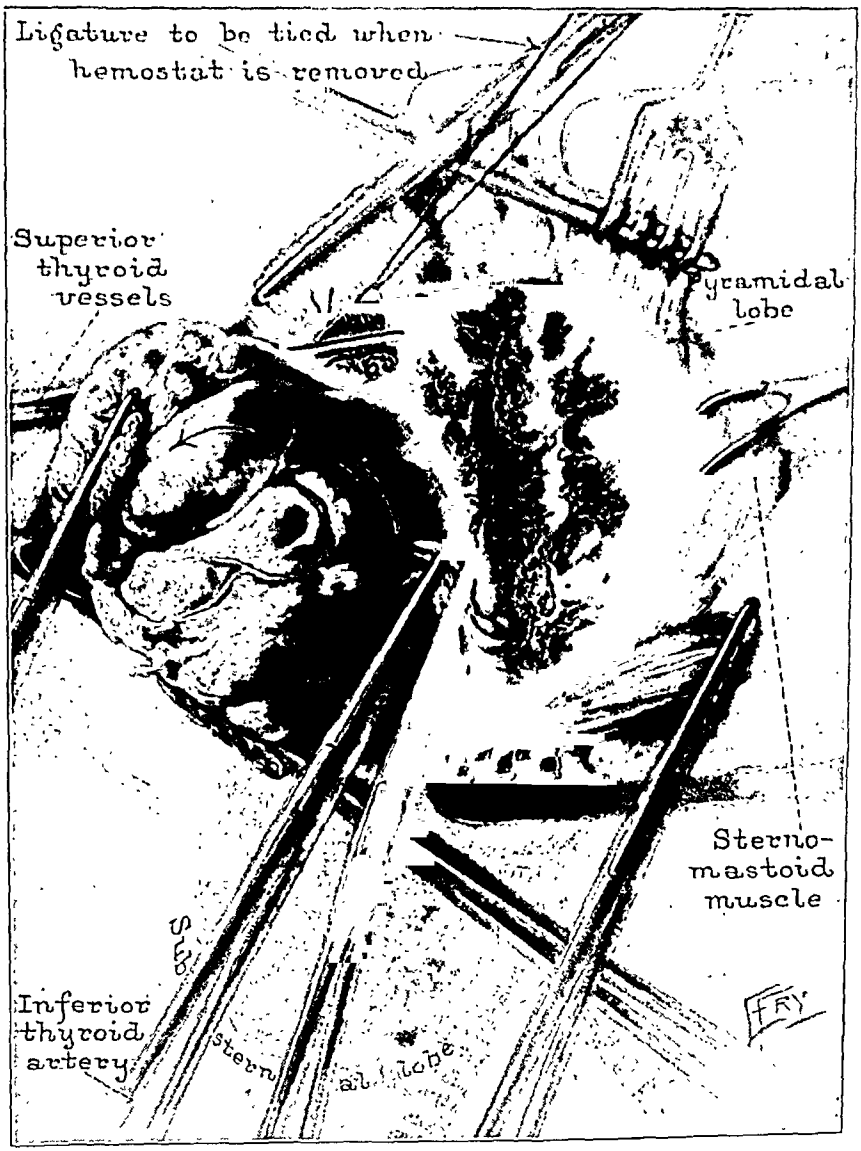

Fig. 11.—Right superior pole of gland free and isthmus divided. Mesial branch of inferior thyroid artery before it is divided.

The middle thyroid vein, which drains a rich plexus of veins beneath the capsule, emerges from the lateral surface of the gland

and enters directly into the internal jugular. This is divided and tied immediately.

The isthmus is then divided and the lobe freed from its attachment to the trachea. By traction on the tumor in a forward and slightly downward direction, the goiter may be resected from above



Fig. 12.—Superior thyroid pole drawn downward and inward. Both branches of the inferior thyroid artery have been divided and ligated before the substernal tumor is elevated.

downward, leaving the posterior capsule. As the inferior thyroid artery enters the gland near the middle of the lobe and remains partly in the neck in practically all substernal goiters, its branches can be clamped and severed before the substernal projection is raised

(Fig. 12). If an attempt is made to pry up the intrathoracic portion before dividing the inferior thyroid artery, there is always danger of tearing this vessel.

The only unclamped vessels remaining are the inferior thyroid veins (often two) which leave the gland at its inferior pole. These will usually be found entirely within the thorax. By traction on the cervi-

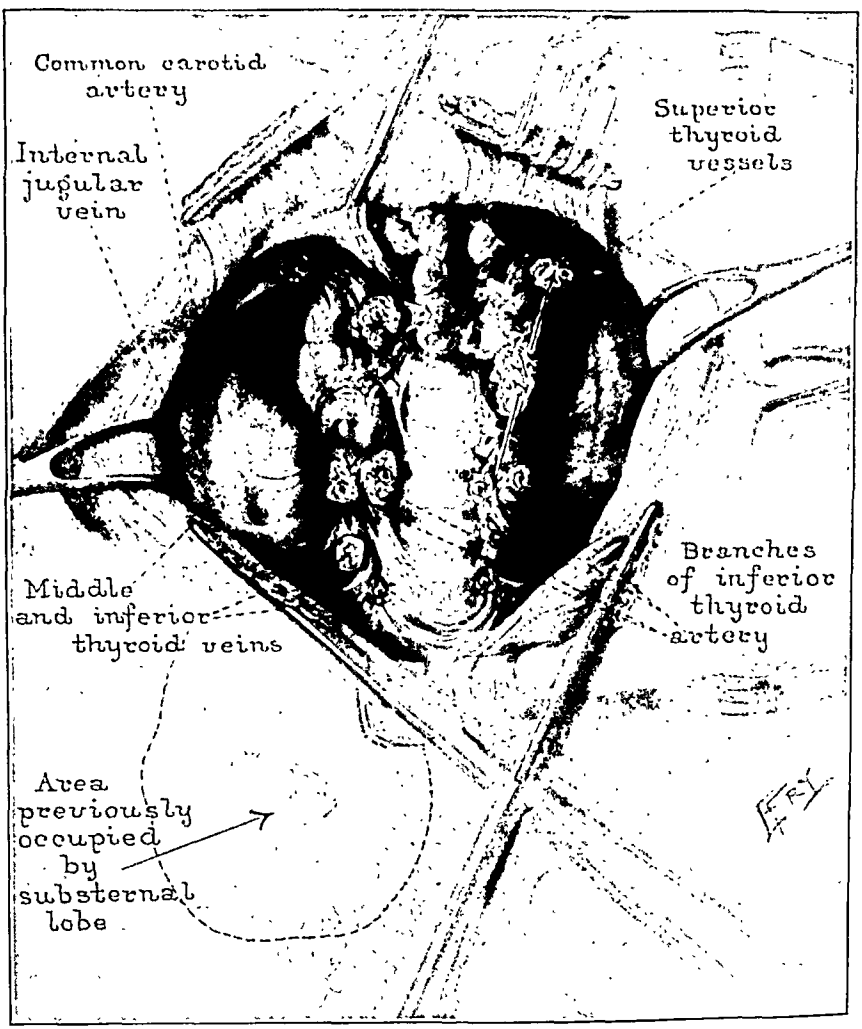

Fig. 13.—Operation completed except suture of divided muscles and closure of skin incision.

cal portion of the goiter, the intrathoracic projection can be elevated and the inferior thyroid veins clamped as they come into view (Fig. 13).

Difficulty may be experienced in elevating the tumor from the thorax. If it cannot be elevated easily, one of two procedures may

be followed, namely, removal by morcellation or longitudinal division of the sternum in order to increase the diameter of the thoracic aperture, as suggested by Lilienthal.[6] If the inferior thyroid artery can be secured first, removal by morcellation may be accomplished with safety. However, if the entire thyroid gland is within the thorax and the inferior thyroid artery cannot be secured, it is probable that division of the sternum may be necessary for the removal of the tumor, although this procedure will be undertaken with definite additional risk.

If a large cervical tumor is also present on the side opposite the intrathoracic projection, it is often well to resect this tumor first as better exposure will be obtained for attacking the substernal tumor.

In every thyroidectomy, an examination of both lobes should be made as a matter of routine, since often very large tumors may be concealed behind the sternomastoid, possibly behind the trachea or beneath the sternum. In our experience the "recurrences" of simple adenomatous growths have been due to failure to remove all adenomatous tissue at the first operation. In this series there were seventeen patients who had had previous operations for the removal of a portion of the gland. Three of these had had two operations. In 448 patients, the goiter involved both lobes, and bilateral resections were required; in thirty-five patients, the right lobe and isthmus were removed, and in fifty-eight patients, the left lobe and isthmus.

The intrathoracic tumor, unless malignant, is definitely encased within the capsule of the thyroid. It is separated from the intrathoracic organs by an additional layer of fascia to which the tumor is usually attached only lightly, and offers no increased difficulties in the removal of the entire capsule. The malignant tumors infiltrate into the surrounding tissues and are inoperable. Occasionally the capsule of a benign tumor is so firmly adherent and in such a relatively inaccessible position, closely associated with the large arterial and venous trunks, that its separation is attended with added risk. In such cases, after the removal of the cervical portion of the goiter, the contents of the intrathoracic capsule may be enucleated entirely by dissecting with the finger without much loss of blood. The edges of the capsule are steadied by forceps, the finger of the left hand is placed laterally and posterior to the capsule to control the inferior thyroid artery by compression. With the index finger of the right hand the capsule is ruptured and its adenomatous content is shelled out. The sac is then packed with gauze, which is removed in four or five days.

---

6. Lilienthal, H.: A Case of Mediastinal Thyroid Removed by Transsternal Mediastinotomy, Surg., Gynec. & Obst. **20**:589-593, 1915.

COMPLICATIONS

Tracheal obstruction may be encountered either during the operation or several hours later. The collapse of the trachea during the course of the operation is frequently due to pressure obstruction from the goiter or from the forceps; it occurs most frequently during the elevation of a large growth on one side, or immediately after, and is usually the result of an adenoma, possibly unsuspected, lying behind the trachea or below the sternum on the opposite side. The obstruction is relieved by the elevation of the second growth. A tracheotomy may have been necessary before the elevation of the second growth; usually the opening in the trachea can be closed at the completion of the operation. In this series it was not necessary to do a tracheotomy during the course of the operation. Marked tracheal deformities, such as the scabbard trachea, due to bilateral pressure resulting in softening of the cartilaginous rings of the trachea, are not infrequently seen, and are often associated with obstructive breathing, at times requiring the opening of the trachea. However, the indication for tracheotomy in these cases does not usually appear for from twenty-four to forty-eight hours after the operation. A tracheotomy may also be necessary for the dyspnea associated with cord paralysis incident to the operation. The dyspnea of patients with profound hyperthyroidism may be confused with the obstructive dyspnea; but I wish to emphasize the importance of opening the trachea in all cases if any doubt exists, for thus a life will occasionally be saved. In performing a tracheotomy in a thyroidectomized patient, the mediastinal space should always be well walled off by a pack before the trachea is opened to prevent a possible fatal mediastinitis. Eight postoperative tracheotomies were performed in this series, five for obstructive dyspnea and three for toxic dyspnea. All patients in the former group survived and all in the latter died. Obstructive breathing necessitated a tracheotomy in twenty-four hours after operation in three patients, in thirty-two hours in one, and in forty-eight hours in one.

Hemorrhage.—Postoperative hemorrhage is not an infrequent complication following a thyroidectomy. It occurs usually within the first six hours, and is easily diagnosed by the increasing obstructive breathing, choking spells, cyanosis, and a tense swelling in the neck. The wound should be reopened immediately, the clot evacuated, and the open vessel clamped and tied. There were three cases of secondary bleeding in this series. The frequency of secondary hemorrhage is due, first, to the fact that the remaining portion of the thyroid gland is movable, and, following the movements of the trachea, a ligature may become loosened; and, second, that veins are often broken during

the dislocation of a lobe from its bed without the knowledge of the operator. Traction may temporarily occlude the opening in the vein and a clot may form, which will be forced out a few hours later by the patient's straining. To prevent secondary bleeding demands more than the exercise of care in primary hemostasis. The patient should be induced to strain or cough while on the operating table, when the "secondary hemorrhage" can be controlled.

Paralysis of the Vocal Cords.—Preoperative and postoperative examination of the larynx should be a routine in all cases. Injury to the recurrent laryngeal nerve may be either direct or indirect. The direct causes may be stretching or severing the nerve, or crushing or compressing by forceps or suture (Fig. 14). The indirect causes may

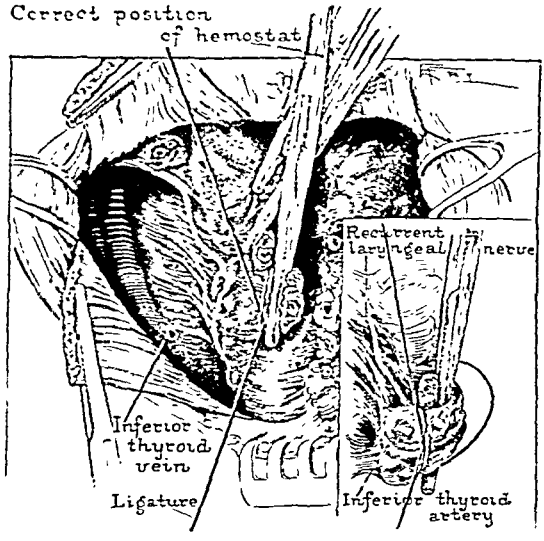

Fig. 14.—Manner in which the recurrent laryngeal nerve may be caught in the ligature by twisting the forceps.

be the traction incident to the swelling in the neighboring tissues, or to edema of the nerve itself, or the nerve may be compressed in scar tissue. In this series a postoperative examination of the larynx was not recorded in ninety-two patients. A positive finding from two to four weeks after the operation, varying from edema, lagging, slight abductor or adductor paresis to a recurrent paralysis, was reported in 170 patients. The right cord was afflicted in sixty-seven, the left in seventy, and both in thirty-three. There was aphonia in two of these, in one of whom the gland had been extirpated for cancer. In the greater number of these patients no change in the voice could be noted, or only a slight huskiness similar to that of many of the patients with negative laryngeal findings. A direct injury to the nerve during the

course of the operation may often be detected immediately by the sudden change in breathing, such as rasping, with inspiratory stridor. Cutting the offending suture may be followed shortly by the return to normal.

Tetany.—Removal of the parathyroids or damage to their blood supply, evidenced by the development of a permanent tetany, is extremely rare following thyroidectomy. Even in cancer of the thyroid, when an attempt is made to remove the entire gland, serious injury to the parathyroids is uncommon. In this series, postoperative tetany occurred in six patients. In all it was temporary; in five it was evidenced by slight cramping of the fingers and toes, and occurred from twelve to forty hours after operation, lasting from twenty-four to forty-eight hours. One patient had convulsive seizures.

Air Embolus.—The danger of extensive air embolism in operations near the root of the neck often is not appreciated. In the removal of large substernal goiters associated with numerous dilated veins the recognition of this complication is of especial importance. The thyroid veins run directly into the larger venous channels, the internal jugular and the innominate. If thyroid veins are torn accidentally and the opening is not recognized, an opportunity is afforded for the aspiration of a large quantity of air into the vein. The accident may occur during the course of the operation or shortly afterward, during straining or coughing. Cyanosis and dyspnea develop, rapidly becoming more intense. The pulse is little affected until the last. Necropsy reveals the right side of the heart filled with frothy blood. There was no incidence of air embolism in this series.

RESULTS

The results of the operation for the removal of substernal and intrathoracic goiters are very satisfactory. The patients are almost immediately relieved of most distressing symptoms, and they are most grateful. The mortality is low. There were sixteen deaths in this series of 542 operations (2.9 per cent.). Two may be classified as due to faulty technic, one of these to the loss of blood after a thoracotomy for the exploration of a huge intrathoracic cancer, and the other to septicemia, probably originating from the wound. Three patients died from pneumonia. Eleven (68 per cent.) died from acute hyperthyroidism seventy-two hours following operation. The average preoperative basal metabolic rate was + 43. These patients were recognized as bad surgical risks; most of them had been treated medically before the operation.

ARE THERE RELIABLE CRITERIA OF OPERABILITY IN EXOPHTHALMIC GOITER?*

DAVID CHEEVER, M.D.
Assistant Professor of Surgery, Medical School of Harvard University
BOSTON

For the purpose of this inquiry, it may be admitted that exophthalmic goiter and the related condition, toxic adenoma, are characterized by an altered function of the thyroid gland, chiefly an increased secretion; and that the reduction of this activity, by operative removal of a part of the gland, is followed in the great majority of cases by a prompt and more or less lasting amelioration of symptoms. It may also be admitted that in spite of the fact that many patients, especially those with exophthalmic goiter, will recover or be improved by medical measures and many more by appropriate irradiation by roentgen ray or by radium, nevertheless, in certain refractory cases operation is much the best and perhaps the only solution of the problem.

The three chief disadvantages of operative treatment are: first, the associated mortality; second, the ordeal of the operative experience, and third, the scar. The two latter may be dismissed because in expert hands they are trivial and wholly out of proportion to the advantages to be gained. The operative mortality remains, then, the one great drawback, and it is especially serious because it is more difficult to weigh the evidence and predict the outcome in this class of cases than in almost any other. No other peripheral operation not involving the great body cavities carries with it the uncertainties associated with interference with the thyroid gland in cases of hyperthyroidism. Criteria of operability are therefore much to be desired.

It is disappointing in searching the recent literature on the operative treatment of dysthyroidism, to find so few definite statements on the subject of operability. This is doubtless because the various factors concerned in the toxemia are not susceptible of accurate measurement. Almost every writer makes general statements to the effect that an operation must not be performed in the acute stage, or during a crisis, or if the toxemia is very marked, or in the presence of serious organic visceral changes, especially in the heart, liver and kidneys. Others refer in general terms to the excess over normal of the basal metabolism, to the epinephrin test, and to the way in which the shock

*Read before the New England Surgical Society, Providence, R. I., Oct. 7, 1920.

of various preliminary minor procedures is borne. Thus Crile [1] says that caution must be observed and the operation terminated when the pulse reaches the "danger point," but does not state what that point is. Mason [2] says: "In extremely toxic cases it is impossible to determine how much operative interference will be tolerated; the history, general condition, pulse and pulse pressure and metabolic rate give an index to the degree of intoxication," but he does not say what degree of variation from the normal contraindicates operation. Sistrunk [3] declares that "in general a high metabolism plus symptoms of marked toxicity contraindicates surgical procedures," and adds that it is a perplexing problem to decide how toxic a patient is and how much damage has been produced by the disease. He is more specific in saying that "primary partial thyroidectomy is not advised in cases with a metabolism of + 60 to + 70 per cent." and refers to the practice at the Mayo Clinic of performing one or more ligations, possibly preceded in bad cases by injections of boiling water or quinin and urea hydrochlorid, "both to prepare the patient for thyroidectomy and as a means of testing patients about whose fitness for operation there is a doubt." Lahey [4] says that "decision as to the toxicity in a given case is not based on exact percentages of tachycardia, increase in nervousness, loss of weight, etc." Barnhill [5] tries to give an exact criterion, stating that "metabolism of + 33 and a pulse rate of over 120 contraindicate primary thyroidectomy." McCaskey [6] says: "Operative risk increases to an appalling extent when the metabolic rate attains an increase of around 100 per cent." Judd [7] makes a helpful suggestion, in stating that loss of body weight and loss of strength indicated by weakness of the extensor muscles, constitute important evidence of the degree of toxicity, and says further that the surgical mortality is unduly high when the toxemia is progressive, or at the peak of a hyperthyroid wave. De Courcy [8]

1. Crile, G. W.: The Surgical Treatment of Exophthalmic Goiter, Surg., Gynec. & Obst. **30**:27 (Jan.) 1920.

2. Mason, J. T.: Mistakes in One Hundred Thyroidectomies, J. A. M. A. **75**:161 (July 17) 1920.

3. Sistrunk, W. E.: The Selection of Operations for Exophthalmic Goiter, J. A. M. A. **75**:306 (Jan. 31) 1920.

4. Lahey, F. H.: Preliminary Ligation in Hyperthyroidism, Boston M. & S. J. **181**:618 (Nov.) 1919.

5. Barnhill, J. F.: Surgery of the Thyroid, J. A. M. A. **74**:1558 (June 5) 1920.

6. McCaskey, G. W.: Basal Metabolism Determinations in General Internal Diagnosis, J. A. M. A. **74**:927 (April 3) 1920.

7. Judd, E. S.: Results of Operations for Adenoma with Hyperthyroidism and Exophthalmic Goiter, Ann. Surg. **72**:145 (Aug.) 1920.

8. DeCourcy, J. L.: Local Anesthesia in Operations upon the Thyroid Gland, Am. J. Surg. **33**:245 (Oct.) 1919.

says that "thyroidectomy is not advisable if the pulse after moderate exertion exceeds 120." Means and Aub,[9] discussing especially the significance of basal metabolism, show from cases under their observation that as regards the parallelism between the pulse rate and metabolism, cases may be separated into two groups: (1) those in which the pulse rate (when plotted in a uniform way with a base line of a pulse rate of 50 and a normal metabolism, and a top line of a pulse rate of 150 and metabolism + 100 per cent.) runs ten or more points above the metabolism curve, and (2) those in which the pulse curve coincides with, or runs below, the metabolism curve. They remark that of the five operative fatalities reported by them, four belonged to Type 2 and only one to Type 1. They further say that a rising metabolism in spite of complete rest is an apparent contraindication to operation.

In a subsequent paper, Means[10] emphasizes the special importance of the comparison of the metabolism curve, pulse curve, and the gain or loss of body weight in the estimation of the patient's degree of toxemia, and presents charts showing these variables, and states that the prognosis in the sympathetico-tonic type (Type 1, of his previous paper) is better than in the vagotonic type (Type 2). In the former it seems to matter very little whether medical or surgical means are employed, while in the latter recovery may take place with the roentgen ray alone; and although surgery may be necessary, the risk is much greater than in the other type. There is some evidence to show that this risk may be reduced by exposing the thymus to roentgen ray before surgery is undertaken.

It is thus seen that, with notable exceptions, recent writers have found it impossible to formulate any approximately exact criteria of the ability of the patient to withstand operation, and very few have furnished the important data concerning their fatal cases which might afford statistical evidence from which, in time, reliable standards might be deduced.

Various suggestions for determining the resistance of the patient to operative trauma may be enumerated under these headings:

(1) The history, with special reference to the age of the patient, the degree of asthenia, the loss or gain in weight, and the presence or absence of a "wave" of hyperthyroidism.

(2) The general clinical picture, including as an important factor, the mental attitude.

---

9. Means, J. H., and Aub, J. C.: The Basal Metabolism in Exophthalmic Goiter, Arch. Int. Med. **24**:645 (Dec.) 1919.

10. Means, J. H.: Hyperthyroidism—Toxic Goiter, Med. Clin. North America, **3**:1077 (Jan.) 1920.

(3) The presence or absence of organic disease of the heart and other viscera, especially the kidneys, liver, and the cerebrum.

(4) The presence or absence of an enlarged thymus.

(5) The blood pressure.

(6) The pulse rate.

(7) The epinephrin test.

(8) The administration of thyroid extract.

(9) The determination of the basal metabolism.

(10) The manner in which the patient withstands the strain of preliminary procedures involving psychic disturbances or surgical trauma.

Some of these suggestions may be dismissed with but a word or two of comment, as probably lacking in significance, or not susceptible of accurate determination. Thus, the general clinical picture is doubtless of importance in direct proportion to the experience and shrewdness of the surgeon, who often may gain a reliable impression of toxicity from signs or symptoms whose degree cannot be expressed in definite terms, such as "nervousness," "emotionality," "apprehension," and "exhaustion." The psychic factor is no less difficult to gage; but it is not too much to say that operation should not be undertaken unless the patient is hopeful and confident of recovery. The presence of organic disease of the viscera is of disputed significance. Gordinier [11] says that "all cases showing myocardial insufficiency or serious arrhythmias should be treated medically." Most authors refer to a "toxic myocarditis," and degeneration of the liver and kidneys; but it is difficult to find references in the literature to the actual organic change in the two latter viscera. A long continued thyrotoxicosis leads in time to a chronic degeneration of the heart muscle, with dilatation, serious arrhythmias, decompensation, and secondary renal and hepatic changes from passive congestion; but in the earlier years of the disease (except in very acute fulminating cases), there is no decompensation, usually no arrhythmia, the blood pressure is high and there is no obvious interference with the function of the liver and kidneys. In patients that have died of exophthalmic goiter there are no characteristic lesions to be found in the heart, liver or kidneys.[12] In the cases about to be reported, none showed organic changes in these organs except more or less enlargement of the heart, probably with dilatation, never, however, with decompensation.

The interrelation between the various endocrine glands is but ill understood, and this holds true of the thyroid and thymus. Melchior [13]

11. Gordinier, H. C.: The Medical Treatment of Graves' Disease, New York State J. M. **18**:267, 1918.

12. Wolbach, S. B.: Personal communication.

13. Melchior, E.: Ist der post-operative Basedowtod ein Thymustod? Berl. klin. Wchnschr. **54**:837, 1917.

says that from 75 to 85 per cent. of cases of exophthalmic goiter show enlarged thymus glands, that cases in which it is not enlarged are very severe, and give a much worse prognosis. Nordmann,[14] on the contrary, records that in eleven fatal cases of thyroidectomy a persistent and enlarged thymus was found. Most authorities take this view, and advise irradiation of the thymus, whether it is demonstrably enlarged or not, to diminish its activity before attacking the thyroid. For the present, it must be accepted that enlargement of the thymus is a serious contraindication to operation.

The pulse rate is justly recognized as a valuable index of thyrotoxicosis; but whether it can be called a reliable guide is doubtful. Judd[7] well says that the pulse rate (and also the nervousness and tremor) are influenced by so many other factors that their value is limited. Its significance will be further discussed in connection with metabolism. The blood pressure is nearly always elevated, and except when there is severe cardiac decompensation, or when the fall in pressure accompanies other signs of a fatal termination, the degree of its variation from the normal is not of much help in prognosis.

Among tests depending on increasing the amount of ductless gland hormone in the circulation and observing the reaction, may be mentioned the administration of thyroid extract, and of epinephrin. Harrower[15] advises the use of desiccated thyroid for three days, stating that from the severity of the reaction may be inferred the presence of hyperthyroidism and its approximate degree. Goetsch[16] arguing from the researches of Cannon and others that in states of hyperthyroidism there is a sensitization of the sympathetic system, and therefore a hypersensitiveness to epinephrin, has suggested the injection of the latter, and the recording of the succeeding variations in pulse and respiration rate, blood pressure, vasomotor and psychic phenomena, which constitute a reaction whose severity is proportional to the degree of hyperthyroidism. This test has proved a valuable means of differentiating between certain obscure cases of exophthalmic goiter, or of thyroid adenoma with thyrotoxicosis, and other conditions unrelated to the thyroid gland (neurasthenia, incipient tuberculosis). Further expe-

14. Nordmann: Thymusextirpation bei Basedowsche Krankheit. Deutsch. med. Wchnschr. **46**:169 (Jan. 22) 1920.

15. Harrower, H. R.: A Simple Therapeutic Test of Thyroid Function, Med. Rec. **94**:196 (Aug. 3) 1918.

16. Goetsch, E.: Newer Methods in the Diagnosis of Thyroid Disorders. Pathological and Clinical, New York State J. M. **18**:259, 1918.

17. Peabody, F. W.; Sturgis, C. C.; Tompkins, E. M., and Wearn, J. T.: Epinephrin Hypersensitiveness and Its Relation to Hyperthyroidism. Am. J. M. Sc., to be published, and Footnote 7.

rience seems to show, however, that the test is sometimes at variance with both the clinical picture and the basal metabolic rate, and occurs in conditions other than hyperthyroidism. It cannot, therefore, be accepted as one of the criteria for which search is being made.

The introduction of practical clinical methods for the determination of the basal metabolism has justified the hope that a method is at hand for determining accurately the severity of a case of hyperthyroidism. It may be accepted as proved that the thyroid gland presides over the rate of metabolic processes in the cells of the organism; that in overactivity of the gland, the metabolic rate is correspondingly increased, and that in the resting, postabsorptive, afebrile state, no cause outside the thyroid gland acts to raise the metabolism in marked degree, except pituitary disorder, leukemia, and one or two other unexplained conditions.

Sandiford [18] says: "The basal metabolic rate is of great value in thyroid disorders because it gives a very accurate mathematical index of the functional activity of the thyroid gland." Du Bois [19] says: "The heat production is an index of the severity of the disease and of the effect of treatment." McCaskey [6] states that the metabolism is an accurate index of goiter toxicity. Judd [7] declares that "the degree of hyperthyroidism estimated from the clinical features and that determined by basal metabolism practically always correspond." Noble [20] states that "by determining the basal metabolic rate the patient can be placed on a definite scale of toxicity." If the last statement is true, experience should enable us to determine (within limits of error) a level of basal metabolism below which operation will be safe and above which it will be fatal. Unfortunately, while the metabolic rate establishes the activity of the thyroid gland, it may not necessarily define the toxemia (if indeed there exists a true toxemia in addition to the exaggerated function of the gland), and it certainly does not necessarily indicate the patient's resistance to noxious influences, whether toxic or hyperfunctional.

From this brief summary, it is evident that the most promising criteria of a thyrotoxic patient's condition may be gained from certain points in the history, the variation in body weight, and the elevation of pulse and metabolism. With reference to these points, the four fatal

---

18. Sandiford, I.: The Basal Metabolic Rate in Exophthalmic Goiter (1,917 Cases), with a Brief Description of the Technic Used at the Mayo Clinic, Endocrinology **4**:71 (Jan.-Mar.) 1920.

19. DuBois, E. F.: Basal Metabolism in Exophthalmic Goiter, Arch. Int. Med. **17**:915 (June) 1916.

20. Noble, T. B.: Lobectomy vs. Ligation of the Vessels in Toxic Goiter, J. Indiana M. A. **12**:230, 1919.

operative cases which have occurred at the Peter Bent Brigham Hospital have been analyzed, and to them are added six other cases which seemed to illustrate the matter, because of a very high metabolic rate, or because a fatal issue from operation was narrowly averted.

REPORT OF CASES

CASE 1.—M. G., No. S-10209, a Jewess, aged 22 years, had had an enlarged thyroid for five years the etiology of which was obscure. There had been increasing symptoms for the last two years, with marked exacerbation during the last six months and a loss of weight of 17 pounds. Examination revealed the typical syndrome of exophthalmic goiter with no serious visceral lesion: the general impression created was that she was "not extremely toxic." On March 28, 1919, her pulse was 125, metabolism +70, and weight 50 kilograms. Because of the high metabolism, a preliminary ligation of both superior thyroid arteries was performed under procain. The patient became nervous and difficult to control on the operating table: but the pulse did not exceed 130. There was persistent postoperative vomiting, and the following day the temperature was normal, but the pulse had risen to 190. On the second day, the temperature began to rise, and the pulse became more rapid; on the third day the temperature reached 103 F., and the patient lapsed into coma. A metabolism determination was made and showed +62, with a pulse of 200. The patient died on the fourth day (Chart 1).

Comment.—The pulse and metabolism before operation in this case show, so far as one determination goes, that it belongs to Type 2 ("vagotonic") of Means and Aub, which was thought to offer a worse operative prognosis than Type 1 ("sympathetico-tonic"). The wide discrepancy between pulse and metabolism in the moribund state is probably not significant. The general impression of the patient's resistance was erroneous. The undertaking of a minor preliminary procedure was correct; but it might have been made even less of a tax by confining the ligation to one vessel, and perhaps the patient's behavior on the operating table might have suggested this modification. During the postoperative course, measures might have been taken to reduce the temperature had its significance been realized (Crile); but it is interesting to note that although every degree of fever increases the metabolism by +10, in this case the reading taken in coma, with a temperature of 103 F., showed a lower metabolism than before operation with a normal temperature. Presumably the moribund condition explains this, and also the wide discrepancy between pulse and metabolism, at the second determination, where they certainly are of Type 1 ("sympathetico-tonic").

CASE 2.—R. K., No. S-7552, a Jewess, aged 22, had had an enlarged thyroid for five years, the etiology of which apparently was a fright. At the onset, there was an acute wave of hyperthyroidism, with 53 pounds loss of weight in five months. She refused operation at another hospital, and by the end of a

year the wave had subsided. She considered herself "well" and remained so until one year before, when the present acute exacerbation occurred. During March, 1917, she was treated by roentgen ray at the Massachusetts General Hospital.

She was admitted to Peter Bent Brigham Hospital, July 16, 1917. Examination revealed a typical picture of exophthalmic goiter, with a pulse of 120,

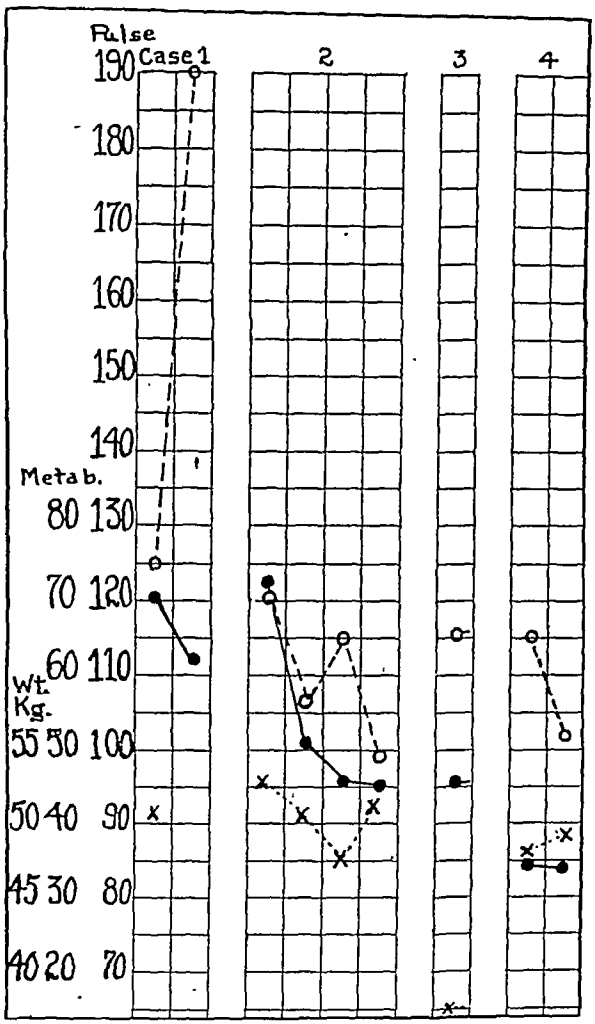

Chart 1.—Pulse, metabolism and weight variations in Cases 1, 2, 3 and 4. In this and the following charts, the solid line represents metabolism; the broken line, pulse, and the dotted line, weight.

and metabolism of + 72. No serious visceral lesion was noted. On account of the high metabolism, a ligation of the left superior thyroid artery was performed under procain, without excessive reaction. Five days later, on July 24, the pulse was 108 and the metabolism had fallen to + 50, and she had lost about 3 kilograms in weight. On July 27, the right superior thyroid vessel was tied. Five days later, the pulse had risen to 115, and the weight

had dropped nearly 3 kilograms more. She was discharged to allow her to gain the full benefit of these procedures, and two months later, on Oct. 19, 1917, under ether anesthesia, the right lobe and a portion of the left were removed. The operation was badly borne, and was followed by an excessive reaction with rapid rise in temperature and death in six hours (Chart 1).

Comment.—At first, this patient's chart suggests that the case belongs to the Type 2 "vagotonic" group, but immediately after the ligation it partook more of the "sympathetico-tonic" type, only to return again at the final determination. It is probable that this variation makes it impossible to assign it definitely to either group. Every precaution to insure safety of operation was taken, and every standard of operability seems to have been met, and it is difficult to understand how a fatality could have been predicted in this case.

CASE 3.—M. H., No. S-4971, female, colored, aged 32 years, had an enlarged thyroid of two and one-half years' duration; the etiology was obscure. The patient had had the usual symptoms of exophthalmic goiter, with especially severe dyspnea and weakness, so that she could hardly walk. She had probably lost about 15 pounds, in spite of resting quietly at home for four months previous to admission, on July 27, 1916. Examination disclosed a typical picture of the disease with no visceral lesion except the usual cardiac enlargement and systolic murmur, but no decompensation. On June 24, the pulse was 114, and the metabolism +46. The opinion of the medical service was that the case was especially suited for surgery, and the consulting surgeon made the same comment. Operation was performed on July 3, 1916, under ether anesthesia, the whole of the enlarged right lobe and one half of the left being removed without accident. The pulse was 130 at the start, but in a few minutes rose to 200, and thereafter varied between 180 and 200. She was put to bed in good condition, and the pulse was 130 six hours later. About eighteen hours after operation, the pulse began to rise, accompanied by the temperature, reaching 280 and 107 F., respectively, before her death about twenty-six hours after operation (Chart 1).

Comment.—So far as one determination can be depended on, this patient belonged to Type 1 "sympathetico-tonic" group. The moderate elevation of the metabolism and her apparent nervous control led to a false sense of security. In advanced "thyrotoxicosis," the lack of nervous control is sometimes shown by an apathetic state. The marked muscular weakness (Judd [7]) might have suggested a grave prognosis. The actual loss of weight was unknown, and it would have been wise to have kept the patient longer under observation, when further loss of, or failure to gain, weight under absolute rest might have led to more caution. A minor operative procedure might have been undertaken to determine her resistance. Gas-oxygen would have been preferable to ether anesthesia. Perhaps the rapid rise of the pulse to 200 during the operation should have led to more conservatism (although this has occurred in many successful cases). The postoperative pyrexia should have been controlled. Its significance was not realized.

CASE 4.—F. D., No. S-12827, a Jewess, aged 31 years, had had an enlarged thyroid for fourteen years; the etiology was obscure. At first there was a period of marked toxicity, treated by rest for three years, when she was told she was "cured." Three years ago the exophthalmos again became marked without aggravation of symptoms; two months ago toxic symptoms again became evident. Examination revealed the clinical picture of exophthalmic goiter of a rather mild type, and no visceral lesions. On July 22, 1920, the metabolism was + 35, the pulse 115, and the weight 47.7 kilograms. Five days later the metabolism was + 35, the pulse 101, and the weight had increased slightly. The impression gained was that the "toxic symptoms are not marked at present." At operation, July 28, 1920, under gas-oxygen and procain anesthesia, the larger left lobe and isthmus, or about two thirds of the gland, were removed. It was not very vascular: the pulse ranged from 100 to 120, and finally rose to 140 at the close of the operation. Later, the pulse and temperature rose progressively to 200 and 106 F., respectively, and death occurred in thirty hours (Chart 1).

Comment.—As far as shown by two determinations, the pulse ranged relatively considerably higher than the metabolism and the case belongs in the Type 1 "sympathetico-tonic" group. There seems to be little to criticize in the conduct of this case, except that perhaps every patient should be under observation longer (which may not be possible in hospital patients). Perhaps every patient should be subjected to a minor operative procedure, no matter how unnecessary such a precaution appears.

CASE 5.—J. E. M., No. S-12207, male, American, aged 26 years, was admitted Sept. 12, 1919, to the Medical Service. The etiology of his condition was obscure, the duration was one and one-half years, and the general impression gained was that he was "very toxic." The symptoms and examination were typically those of exophthalmic goiter, without evident associated visceral disease. The Wassermann reaction was positive. On admission, the metabolism was + 65 and the pulse 97. One month later under complete rest and overfeeding, his metabolism had jumped to 99, and his pulse to 122, and he had lost nearly 3 kilograms. One month later, during which time he had two irradiations over the thymus region, his metabolism had increased to + 116 and his pulse to 134, and he had lost nearly 2 kilograms more. Two months later, during which interval he had eight irradiations over the thyroid and one over the thymus, with continued rest in bed, his metabolism had dropped to + 68 and his pulse to 116, and he had nearly gained back the weight lost since admission. During the next month, he had two more roentgen-ray treatments, and had a heart block, during which the metabolism had fallen to + 48 and the pulse to 85. During his seven months' stay in the hospital, the subjective improvement was but slight and he had lost 3½ kilograms in weight.

April 10, 1920, the right superior thyroid artery was tied under procain; the pulse was 160 and the reaction fairly severe.

On April 20, the left superior thyroid was ligated. On account of the very loud bruit and thrill over the right inferior artery, this vessel was ligated on May 3, 1920. One week later, as a result of these preliminary procedures, the metabolism was essentially the same, + 46, and the pulse had gone to 118,

the heart block having terminated, and he had gained 2 kilograms in spite of the operative ordeals. He was subjectively improved, his morale as regards operation was thoroughly established, and he was full of confidence. A week later, his metabolism had risen 10 points, but his weight was gaining. On May 27, under gas-oxygen, the entire right lobe, the isthmus, and one half of the smaller left lobe were removed. The pulse was 170 at the beginning of the operation and reached 210 at the end, when it became irregular, of poor quality, and the respiration jerky and finally Cheyne-Stokes in type. The condition was very precarious for twenty-four hours, although the temperature

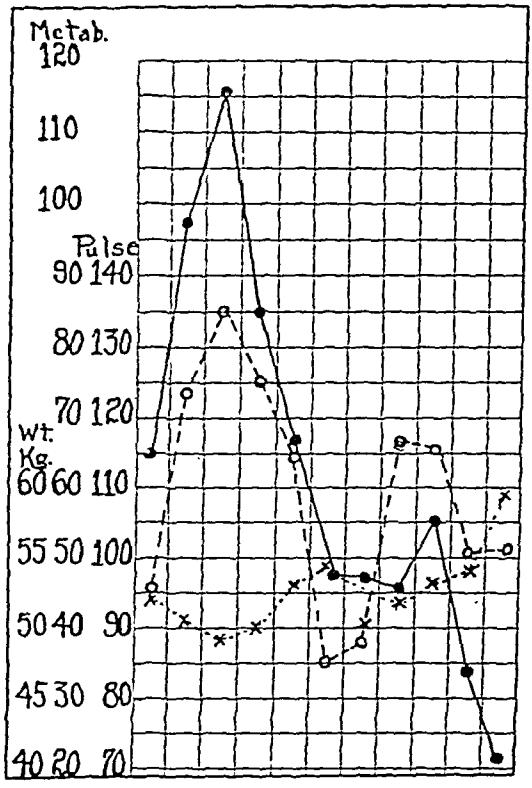

Chart 2.—Pulse, metabolism and weight variations in Case 5.

never went over 101 F. Rapid improvement then began, and two weeks later the metabolism was +33, the pulse 100, and he had gained 1½ kilograms. At this time he was discharged from the hospital. Two months later his metabolism was +21, pulse 100, and he had gained 5½ kilograms more. Since then he has led a nearly normal life (Chart 2).

Comment.—At first the relation between this patient's pulse and metabolism during treatment suggested that he belonged to the Type 2 "vagotonic" group. Finally he tended more to the Type 1 "sympathetico-tonic" group. The building up of his morale and gaging his resistance by minor procedures were perhaps of great importance.

Case 6.—F. K., No. S-8185, an American, male, aged 28 years, had had an enlarged thyroid for two years, and the etiology was obscure. There had been 45 pounds loss of weight and the typical history, symptoms, and signs of exophthalmic goiter. The metabolism was + 116 and the weight 60 kilograms on March 7, 1917. After ten months of rest at home and in the Adirondacks, his metabolism was + 26, his pulse 76, and his weight had increased 7½ kilograms. He showed considerable muscular weakness, however, and was unable to work. Feb. 11, 1918, under procain anesthesia, the right lobe and isthmus were removed. It was intended to remove a large portion of the left, but the difficulty of hemostasis was so great that the

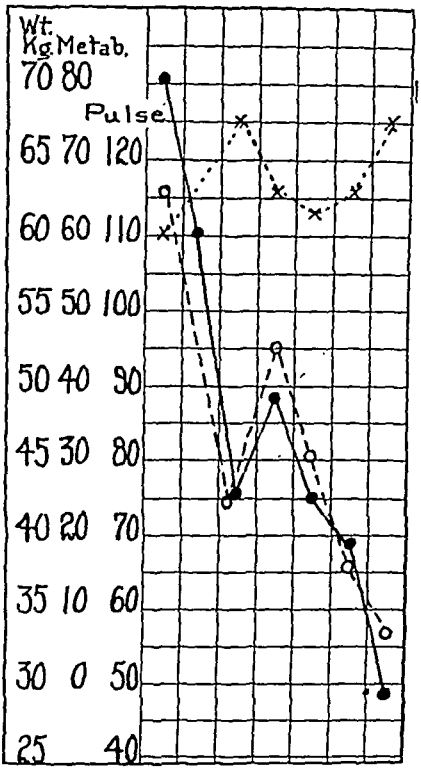

Chart 3.—Pulse, metabolism and weight variations in Case 6.

operation was terminated. (He proved to have a distinctly hemophilic history.) The operation seemed to be well borne; but the first six days of convalescence were marked by grave toxemia and high fever, and he was considered in a precarious condition. Ten days later, both metabolism and pulse had increased slightly. He was discharged nineteen days after operation, and since then his metabolism has dropped to — 1, and his pulse to 58, and he appears and feels normal in every way (Chart 3).

Comment.—This patient's pulse and metabolism chart showed that he should be classed with the Type 2 "vagotonic" group. Perhaps this explains the serious postoperative course in spite of a moderate elevation of metabolism, but it seems possible that it was due to the failure

to remove enough of the gland. If general anesthesia had been used, this could probably have been done. The final result is excellent.

CASE 7.—M. M., No. S-6812, American, female, aged 43 years, had had thyroid enlargement for two years: and there were the typical history, symptoms and signs of exophthalmic goiter, without serious associated visceral lesion. She was admitted to the hospital, May 31, 1917. The metabolism on June 5 was + 73, the pulse 90, and the weight 51.2 kilograms. On June 12, under procain anesthesia, both superior thyroid vessels were ligated with little immediate reaction. There was an immediate slight rise, then a gradual decline in both pulse and metabolism, and an associated gain in weight, until, on Feb. 9, 1920, the metabolism was — 12, the pulse 57, and she had gained 14 kilograms and was leading a normal life (Chart 4).

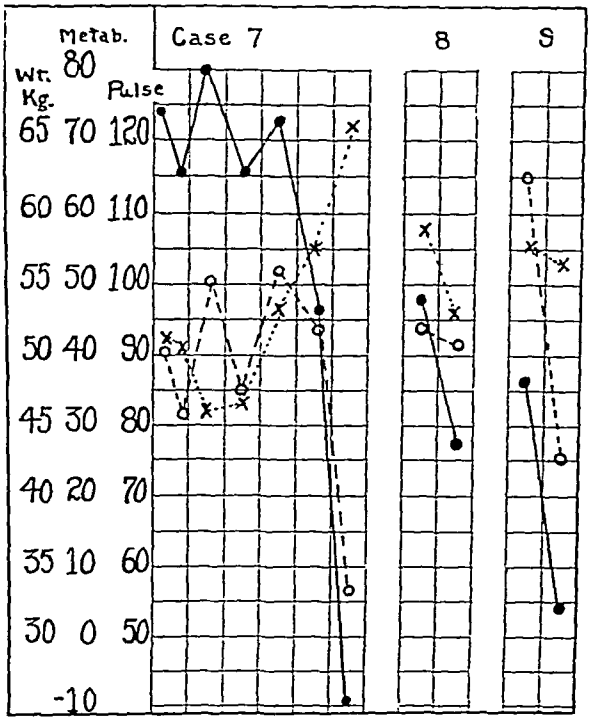

Chart 4.—Pulse, metabolism and weight variations in Cases 7, 8 and 9.

Comment.—The chart shows the patient to be a typical example of the Type 2 "vagotonic" group, in spite of which and of a high metabolism, she showed only mild toxicity and little operative or postoperative reaction. The case is interesting as being a cure from simple double superior ligation.

CASE 8.—G. G. H., No. S-12530, Canadian, female, aged 34 years, had had an enlarged thyroid for two years: the etiology was not clear, and the history, symptoms, and examination were quite typical. On admission, her metabolism was + 49, the pulse 94, and she gave an impression of only moderate toxicity.

She appeared controlled and desired operation. The pulse which was usually about 100, went to 160 during the examination. On June 2, 1920, under gas-oxygen, the enlarged right lobe and one half of the left were removed. The pulse started at 160, went to 210, and the patient was drenched with sweat. The postoperative course was very stormy, with wild delirium, constant vomiting, a temperature of 104 F., and the cardiac impulse shaking the whole bed. She finally recovered, and the metabolism, ten days after operation, was +28, the pulse 92, and she was discharged much improved. (Chart 4).

Comment.—Her chart, judging by two observations, shows that she belongs in the Type 2 "vagotonic" group. A minor procedure should have been undertaken to establish her resistance to operation.

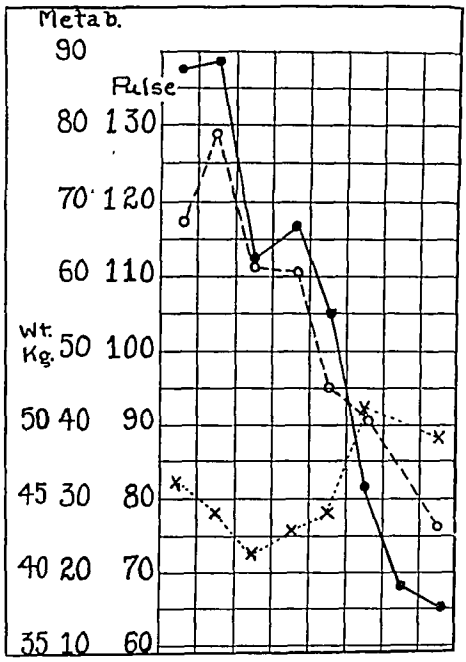

Chart 5.—Pulse, metabolism and weight variations in Case 10.

CASE 9.—C. L., No. S-12629, American, female, aged 23 years, had had an enlarged thyroid for six months: the etiology was apparently an emotional strain. The symptoms included a marked tendency to diarrhea, but were otherwise of moderate severity. The examination gave the impression of very moderate toxicity. The metabolism after a week in bed was +39, and the pulse 114. On June 21, 1920, under gas-oxygen, the major portion of both lobes was removed. The pulse went to 215, while the respirations reached 60, and were alarmingly shallow. The condition seemed very precarious for twenty-four hours, but the later postoperative course was good. Ten days later the metabolism was +3 and the pulse 75. Final recovery was complete (Chart 4).

Comment.—This patient's chart shows that she must be placed in the Type 1 "sympathetico-tonic" group. Nevertheless, the operation itself was poorly withstood, and there was apparently nearly a fatal issue.

CASE 10.—M. E. D., No. S-4536. American, female, aged 21 years, had had thyroid enlargement for six months; the etiology was doubtful. Her history, symptoms, and physical examination were typical of exophthalmic goiter. The metabolism on March 24, 1916, was +88, and the pulse 118. On April 10, 1916, under ether anesthesia, the enlarged right lobe and isthmus, constituting about two thirds of the gland, were removed, and the left superior thyroid artery ligated. Although the pulse reached 210 and the respirations 50 during the operation, the condition did not seem alarming, and the postoperative course was not very severe. A series of determinations since have shown steadily declining pulse and metabolism, until on Oct. 2, 1920, the metabolism was +15 and the pulse 77, in spite of the fact that she had passed through pregnancy and confinement successfully and was constantly subjected to an unusual and severe psychic strain (Chart 5).

Comment.—This patient's chart shows essential correspondence in the metabolism and pulse curves, and she therefore belongs in the Type 2 "vagotonic" group, in spite of which and of a very high metabolism, she withstood a primary thyroidectomy under ether anesthesia without alarming reaction. Nevertheless, it would have been wise to establish her "preoperative morale" by a minor procedure.

CONCLUSIONS

Can satisfactory deductions be drawn from these cases to assist in determining reliable criteria of operability? The suggestion of Means and Aub that patients falling into their Type 2 "vagotonic" group give a more serious prognosis, does not seem to be wholly sustained by the cases above presented. Of the four fatal cases, two belonged to the "sympathetico-tonic" and one to the "vagotonic" group, while one showed different phases, permitting its classification in either group. Of the others, Cases 5, 6, 8 and 9 showed very serious postoperative reactions, and of these, three can be classified as "vagotonic" and one as "sympathetico-tonic." The remaining patients, Cases 7 and 10, were "vagotonic" in type with high metabolism, but both made good recoveries without undue reaction; the operation being ligation in one and the radical procedure in the other. Evidently an investigator with a theory to defend could find in these cases support for either point of view. Perhaps the weight of evidence favors the impression that the "vagotonic" group gives the more serious prognosis.

As far as these cases go, no definite level of pulse or metabolism can be said to constitute an absolute contraindication. One death occurred in a patient with a metabolism as low as +33. It is certainly striking that three of the four fatal cases were those of Jewish women, since in a series of cases of exophthalmic goiter at Peter Bent Brigham Hospital, the proportion of Jewish women was less than one-fifth. It seems worth while to allude more specifically to the possibly very great importance of testing a patient's ability to withstand operative trauma

by one or more preliminary minor procedures. (No comment is intended to be made in this paper on the therapeutic effect of these measures, although they are usually, of course, designed to lessen the thyrotoxicosis.) Such a point of view is mentioned by many writers. Watson [21] says that preliminary injections of saline solution or sterile water should be made into the gland "to raise the patient's threshold of stimuli, thereby preventing an acute attack of hyperthyroidism which might otherwise follow the first quinin and urea injection." Sistrunk [3] speaks of ligation as a means of testing the ability of the patient to stand any operative procedure without precipitating a severe crisis of hyperthyroidism.

It seems reasonable to offer the subjoined tentative conclusions with regard to criteria of the ability of the patient with exophthalmic goiter to withstand the strain of operative therapeusis:

1. During an acute exacerbation of the disease, or in periods of great mental depression, operation is contraindicated.

2. Muscular weakness so great that the patient cannot walk and marked loss of weight with continued loss under absolute rest are serious contraindications.

3. Organic visceral disease so serious as to jeopardize patients' having any operation of similar technical type is a contraindication.

4. Operation should not be undertaken in the presence of an enlarged thymus, until its probable activity has been reduced by irradiation.

5. The Jewish race offers a distinctly higher operative mortality.

6. A metabolism of + 30 introduces a serious risk, which undoubtedly increases with high rates, but not necessarily in proportion, and there is no rate of metabolism which alone contraindicates at least minor surgical procedures.

7. The "vagotonic" type is possibly more vulnerable to the operative ordeal than is the "sympathetico-tonic," but evidence on this point is as yet inconclusive.

8. The minor procedures, whether consisting of injections into the gland, cauterizing or ligating operations, are often most valuable indexes of a patient's resistance to trauma.

In hyperthyroidism, operations will always be attended by a peculiar factor of danger, not present in other operations which are technically similar.

---

21. Watson, L. F.: A Method of Controlling Hyperthyroidism, Endocrinology **1**:178, 1917.

REPAIR OF BONE FOLLOWING FRACTURES*

JOSEPH A. BLAKE, M.D.
NEW YORK

The repair of bone following injury may seem a trite and worn out subject, yet the mass of clinical material furnished by the war has afforded opportunity for some interesting and practical observations.

During the war, there was considerable controversy, at least in France, on the old subject of production of bone by periosteum; and although I have little to say as to the activity of periosteum as a bone former, I have a strong feeling as to its value as a protector and conservator of developing bone. Portions of bone in gunshot fractures are commonly detached and driven into the muscle. Surgeons have frequently placed bone in the muscles to bridge defects. Invariably, as fas as I know, fragments, not lying in immediate contact with bone, have been gradually absorbed and have disappeared. Quite the reverse happens when bone fragments or grafts lie in close contact with bone. They form new bone almost invariably. Also, the connective tissue of repair seems to be favorable, or at least neutral, to the growth of bone, as observed in the production of osteophytic processes in muscles whose activity is violent enough to produce trauma at their insertion.

These facts suggest that while chemical conditions in the bones are favorable to growth of bone, there are substances found in the muscles which are inimical. If this is so, at least one of the functions of the periosteum may be protective in a chemical sense. The periosteum is of the greatest value mechanically in preserving the attachment of fragments of bone to the soft parts, particularly the blood vessels. In excisions of bones and joints practiced according to the method of Ollier, it carries and supports the thin shavings of bone separated by the rugine, and by transmitting the action of the muscles is one of the chief agents in restoring conformation.

Nutrition is of prime importance in the repair of bone. In fact, one may say that the rate of reproduction of bone is directly dependent on the blood supply. The fact is so evident as to make its statement superfluous, yet most of the failures of operations to unite or graft bones are due to ignorance or indifference on the part of the surgeon in regard to the sources of the blood supply. The errors of the oper-

* Read before the Pathological Society of the University of Minnesota, Sept. 28, 1920.

ators become more evident if infection occurs. Then not only do grafts and other detached fragments become necrotic, but very frequently the ends of the main fragments, also the line of demarcation corresponding to the point at which the circulation has been interrupted. Frequently, necrosis of the entire ends occurs up to drill holes passed through the medulla. Drilling through the cortex alone, while it may lead to necrosis about the hole, does not seem to be dangerous; but

Fig. 1.—Ununited fracture of the radius six months after injury and three months after a sliding graft operation. Although there was no history of infection immediately following the operation, an abscess formed two and one-half months after the operation, discharging spontaneously under the plaster cast. Density of the bone between the drill holes denoting necrosis may be noted, also the rarefaction, particularly of the distal fragment.

interference with the medulla, the main source of blood supply, is likely in case of infection to lead to complete death (Fig. 1). In other words, inhibition of the blood supply would seem to convert the terminal portions of the fragments into bone which is no better than that transplanted from another source in the patient.

Almost invariably, finely comminuted fractures in which we know a large part of the fragments are absolutely detached, if not infected, unite with remarkable rapidity, the resulting callus being usually excessively large. Every fragment must contribute its quota of new bone in order to produce the amount observed. I have frequently seen similar bone production from chips inserted about a graft or between the ends of the main fragments. I have also observed a new graft, inserted alongside a graft which had been in for six months and had been fractured at its middle, unite at its sides with both fragments of the original graft; the callus of union being visible at the end of three weeks by roentgenography. All of which proves that fragments of bone, even when detached, produce bone if the conditions are favorable.

When sufficient infection is present to change the chemistry of the fluids about the fragments, all detached and anemic portions of the fragments usually die. On the other hand, as we have all noticed, the presence of infection produces hyperemia in the adjacent structures which leads to rapid production (perverted repair) of bone tissue from the portions of bone not killed. In this way, excessive callus is produced. While this excessive repair is distinctly advantageous in many cases in bridging over the defects resulting from extensive necrosis, it often leads to embarrassing flasklike formations about the dead fragments which are sometimes almost impossible to cure if allowed to become pronounced (Fig. 2). The obvious treatment of such conditions is to remove the dead fragments before the cavities are formed. On the other hand, if long defects have to be bridged, it may be wise to conserve the dead fragments rather than to risk interrupting growth of new bone by their removal. Often much judgment and experience are necessary to decide on the proper moment to intervene.

When a portion of bone dies, it preserves its original density, while the remaining living bone becomes softer and less dense because of absorption of its calcareous constituents. Of the causes of this rarefaction, I shall speak later. At present, I desire to call your attention to the difference in density between the dead and living bone as the most valuable diagnostic aid in determining the presence of dead bone. In roentgenography, the dead portion, or portions, throws a much more distinct shadow. This is well shown in Figure 1. In a roentgenogram a dense portion, particularly if it has sharp and irregular contours, separated by a clear interval from the rest of the bone, is certain to be a sequestrum. Sequestra preserve their density for very long periods. I have roentgenographed and removed a number which I knew had been present for many months, and they have always been extremely hard and dense. Although bacteria invade the canaliculi as

found by Kenneth Taylor,[1] osteoclasts do not, and what sequestra lose by absorption is entirely from their surfaces. I am inclined to believe that they are not absorbed at all, for all that I have removed, whether still attached by the living bone or separated for a long time, have always had the sharp points, often long and attenuated, which are characteristic of the line of demarcation. If absorption does occur, these slender points would be lost. The cavities formed about sequestra are rather caused by absorption of the adjacent living bone, especially the involucrum. The latter thus becomes a shell, being continually added to peripherally and absorbed centrally.



Fig. 2.—Compound fracture of the radius of eighteen months' duration. The end of the distal fragment is almost entirely necrotic. The irregular outlines of the sequestra which are somewhat denser than the involucrum, are outlined by the cavity forming about them. The excessive formation of the callus may be noted. If allowed to remain, the involucrum will be further excavated about the sequestra and a large flasklike cavity will result.

You may ask what happens to fragments of detached bone such as those projected into the muscles in a gunshot fracture if they do not die; for they disappear. My observations lead me to the conviction that they are digested alive either by their own osteoclasts or by the

1. Taylor, Kenneth: The Persistence of Bacteria in Bone Sequestra, Ann. Surg. **66**:522 (Nov.) 1917.

fluids and cells in their strange environment. If they die *en masse,* infection is present and they are discharged with the formation of an abscess or sinus.

I have always found rarefaction present in fractured bones, and I have found that its degree depends more on disuse than on infection. One of the chief etiologic factors in the production of rarefying osteitis as stated in our textbooks is tuberculosis. All surgeons, and I presume pathologists, are familiar with the ease with which the epiphyses of the femur and tibia can be cut in tuberculosis of the knee. Until I had operated on old gunshot fractures in the war, I had believed that tuberculosis was peculiarly productive of rarefying osteitis. In these fractures, I found the same softening of the epiphyses, fully as marked as in tuberculosis, and to a less degree, of course, of the diaphyses. The condition is readily discernible in roentgenograms, especially when compared to roentgenograms of the bones of the sound limbs, but more particularly when roentgenograms taken immediately after the injury and those of a later date are compared. It was also interesting to observe that if the patient was bedridden, rarefaction occurred in the other bones that were not used; but if he were about it occurred only in the immobilized limb. It was also much more marked when the limb was completely immobilized. Rarefaction is accompanied also by decrease in size of the bones. Infection, I do not now believe is so active a factor in producing rarefaction as I had formerly supposed. It seems to act by inhibiting function rather than by any direct toxic factor. In gunshot fractures of the humerus just above the epicondyles, the distal fragments may become almost invisible in the roentgenograms. Delayed union, or nonunion, is very common in these fractures, and rarefaction is more pronounced in such cases, proving that union is dependent on proper nutrition.

It has been my custom to defer operations for nonunion when marked rarefaction of one or both main fragments is present. Obviously an operation, such as inlay grafting, on account of the mutilation necessary in forming a groove, is almost sure to compromise what little circulation remains. It is better in such cases to arrange some sort of apparatus which will permit the patient to use his limb and regain its circulation and nutrition. When an operation is performed in such cases, a sleeve of lamellae of bone chiseled off with the periosteum is better than an inlay graft. A sliding graft should not be attempted, particularly if the bone is a small one, such as the ulna or radius. Inlay grafts from other bones and sliding grafts are indicated when the ends of the fragments are rounded over and the medullary cavity plugged by hard bone (Fig. 3). This rounding over and plugging denotes

repair and coincidently nutrition, and is rarely seen where there is marked rarefaction. In such cases, the channel cut for the graft opens out the medullary cavities, and if the graft is taken from another bone so that active medullary tissue is removed with the graft, success can generally be achieved.

There is another point in regard to the repair of fresh fractures which is of great importance in their treatment. I refer to the rapidity with which repair takes place. Many think that a fracture may be

Fig. 3.—Fracture of the humerus by shell fragments, two years after injury and ten months after an attempt to unite the fragments by means of a graft, which was extruded, the wound having become infected. Complete pseudarthrosis. The rounding over of the end of the proximal fragment and the plugging of the medullary cavity of both fragments by dense bone should be noted.

reduced at any time within the first ten or twelve days. It can be, of course, but if one operates on a fracture on the fourth or fifth or sometimes even the third day, gritty new bone is found around the fragments. This increases rapidly in the next two days and if the fracture has not been reduced this new bone is not only wasted but may

interfere seriously with reduction. Also, the soft parts repair and may prevent reduction. The custom of waiting until swelling has disappeared is a most pernicious one. It developed from the use of the plaster cast, the worst device for treating most fractures, unless used with great judgment and skill, that was ever invented. Of course, a plaster cast cannot be put on before swelling appears because it will become too tight and if put on before swelling disappears it will become too loose. A fracture should be reduced as soon as possible after it has been sustained. Often swelling will be prevented, and, of course, every bit of repair will be utilized effectively. Repair in the sense of forming new bone does not go on indefinitely. Sooner or later it ceases. To treat fractures successfully, it must be conserved and not wasted.

We have found in the treatment of fractures by suspension, *together with constant active mobilization by the patient of the contiguous* articulations, that the circulation is favored, that swelling rapidly disappears, that repair is rapid, and that marked rarefaction and nonunion are very rare. When splints are used, which is necessary for some fractures, they should be removed at least once, better twice a day, and the patient made to make all the motions allowable for the fracture. The appearance of the limb differs markedly from that customarily observed in treatment by splints with edematous skin with ridges here and there denoting irregular circulation. The muscles retain their form and are not atrophic. As the condition of the soft parts must be an index of that of the bony structures, it is reasonable to suppose, as seems to be proved *clinically, that the circulation in the bone* is far better than that obtained when the limb is kept quiet in splints. Manifestly, with better circulation, repair must be more active and there must be less tendency to necrosis of fragments devitalized because of their circulation's being cut off by traumatism or by later infection and thrombosis. Furthermore, suspension allows access to the limb for frequent dressings with the least disturbance to the fracture, which permits of better treatment and therefore quicker consolidation. Also not the least advantage of suspension in promoting circulation is the quicker sequestration of dead bone and the earlier opportunity for its removal before disagreeable callus forms.

Although nothing new has been discovered during the war in regard to the morphology of the repair bone yet much has been learned in regard to what we may expect in the formation of new bone and also in the treatment of dead bone, especially in regard to the period when it should be removed. As I hope I have made clear, it should be removed in most instances as soon as it becomes detached. In exceptional cases when it is desired that exuberant callus be formed

to bridge over defects, it may be wise to leave in sequestra which bridge defects until the rapid callus formation which goes on about them has completed the continuity of the bone. Attention has been called to the use of dead bone for the promotion of repair by Heitz-Boyer.[1] He has called attention not only to the production of new bone about grafts which have died on account of infection, but also to the stimulation caused by the introduction of dead bone from other sources. The conservation, therefore, of dead bone becomes of real practical value in many cases.

Before concluding, I should also call attention to the question as to when newly formed bone can bear the strains of use without deformation. This is of great practical importance in fractures of the femur in which the use of the limb necessitates weight-bearing, that is, a compressive force at the point of fracture. It has been found that it is not safe to allow weight-bearing on the fractured femur until the newly formed bone has established its adult condition with the formation of haversian canals. The reestablishment of the haversian system can be determined by roentgenograms.

1. Heitz-Boyer: Tr. Cong. franç. de Chir., 1919.

TREATMENT OF FRACTURE OF THE FEMUR*

KELLOGG SPEED, M.D.
CHICAGO

SERIES OF FRACTURES OF THE FEMUR REPORTED IN RECENT AMERICAN LITERATURE

Nis reported 575 cases of simple fracture of the femur occurring in the Charity Hospital at New Orleans during ten and one-half years. Of these fractures, ninety-six, or 16.7 per cent., were of the neck of the femur. He found that fractures of the neck were rare in negroes—only fourteen of the ninety-six patients being of this race. There were fifty-six males and forty females. The age incidence in ninety-four cases of fracture of the neck of the femur in this series is recorded in Table 1.

TABLE 1.—AGE INCIDENCE IN FRACTURES OF THE NECK OF THE FEMUR

Age	Number of Cases
1- 10	0
10- 20	7
20- 30	1
30- 40	6
40- 50	7
50- 60	15
60- 70	29
70- 80	20
80- 90	8
90-100	1

No two surgeons of the hospital agreed as to the method of treatment of these fractures. There was not one attempt at complete reduction and restoration of normal function. If patients survived and left the hospital, the usefulness and function of the leg was not investigated. Only two or three patients were given anesthesia and placed in plaster-of-Paris casts, with the limb in abduction. Most of the casts applied were removed within a few days, probably on account of pain, and Buck's extension was thereafter used as the method of treatment. The methods of treatment employed were: Buck's extension in 35.2 per cent. of the cases; plaster of Paris in 29.8 per cent.; extension, cast six weeks, 10 per cent.; Liston's splint, 9 per cent.; Hodgen's splint, 8 per cent., and sand bags, 8 per cent. The mortality in ninety-six fractures of the neck was 15.6 per cent.; and of the fifteen patients who died, fourteen were more than 60 years of age.

Martin published the end-results of 242 cases of simple fracture of the femoral shaft, collected from the hospitals of the city of Philadel-

*Based on a report made before the Société Internationale de Chirurgie. Paris, July, 1920.

phia. Most of these fractures were treated by Buck's extension. Two of his conclusions were:

No. 12.—The unsatisfactory results following the weight extension treatment of simple fracture of the femoral shaft in adults suggest that this method is either inadequate in itself or is unskilfully applied.

No. 13.—Efforts to obtain better results should be directed to (a) employment of more weight to entirely overcome the deformity; (b) early resort to open operation if extension seems insufficient; (c) systematic use of massage and passive motion continued for months; (d) longer use of crutches than is now customary, and (e) education of the patient.

Estes analyzes the reports of 739 cases of fracture of the femur. The age distribution in fractures of the shaft of the femur in this series is given in Table 2.

TABLE 2.—AGE DISTRIBUTION IN FRACTURES OF THE SHAFT OF THE FEMUR

Age	Number of Cases
0-10	90
10-20	65
20-50	122
50-70	55
70-90	12
Total	344

TABLE 3.—AGE DISTRIBUTION IN FRACTURES OF THE FEMUR

Age	Number of Cases
0- 10	125
11- 20	48
21- 30	26
31- 40	23
41- 50	53
51- 60	73
61- 70	77
71- 80	69
81- 90	26
91-100	5
101-110	1

He concluded that during the period of hard active labor there was the greatest number of fractures of the shaft of the femur in America. Speaking of fractures of the middle third, he says: "Except in selected cases I have quite lost my preference for traction methods of treating these fractures, since skiagrams so frequently showed me overlapped fragments, inaccurate apposition and nearly always a little angulation as a part of the result."

In 1890, the fracture committee of the American Surgical Association agreed that if the end-results after fracture of the femur should be considered good there must be: (*a*) firm bony union; (*b*) correct axial relations of fragments; (*c*) maintenance of correct relations of

the anterior planes of upper and lower fragments; (*d*) no shortening to exceed ⅛ to 1 inch; (*e*) no lameness occurring as a result of shortening over 1 inch, and (*f*) an understanding that conditions attending the treatment may prevent these satisfactory results. At that time, this committee reviewed 364 nonoperated cases, in 67 per cent. of which there were good anatomic and functional results.

FRACTURES OF THE FEMUR AT THE COOK COUNTY HOSPITAL, CHICAGO

From the records of the Cook County Hospital, Chicago, for the last three years, I have collected the reports of 526 cases of fracture of the femur, which were observed long enough to warrant their inclusion in this article. Four of the series were compound fractures. The age distribution is given in Table 3.

There were 328 males and 198 females. The right femur was affected in 271 cases; the left in 255. The incidence according to the part of the femur affected is given in Table 4.

TABLE 4.—INCIDENCE OF INJURY IN VARIOUS PARTS OF FEMUR

Site of Injury	Number of Cases	Per Cent.
Neck	124	24
Intertrochanteric	118	22
Greater trochanter	10	2
Subtrochanteric	14	2.5
Shaft: upper	39	
Shaft: middle	157 } 249	47
Shaft: lower	53	
Supracondylar	5	1
Condyles	2	1
Intercondylar	1	0.3

Mortality of Fractures of the Femur.—The total deaths of the series were fifty-six, 11 per cent. Twenty-two deaths were attributed to pneumonia complicating the fracture. Other causes of death were multiple fracture, nephritis, myocarditis, infection and lung abscess. The number of deaths occurring in the different fractures is given in Table 5.

TABLE 5.—NUMBER OF DEATHS OCCURRING IN DIFFERENT FRACTURES

Site of Injury	Number of Cases	Per Cent.
Intertrochanteric	22	18.6 of all intertrochanteric fractures
Neck	20	16.1 of all neck fractures
Shaft: upper 2		
Shaft: middle 4	7	
Shaft: lower 1		
Subtrochanteric	3	
Supracondylar	1	
Greater trochanter	1	
Not stated	2	
Total	53	

Methods of Treatment.—The methods of treatment for the whole series of 526 cases were: rest in bed, sand bags, sitting up in bed supported by pillows, etc., in 35 cases; Thomas splint with suspension traction in 25 cases; vertical extension in children in 56; Buck's extension, sometimes combined with Liston's splint, double inclined plane and molded plaster-of-Paris splints in 97; fracture table, extension and cast in 113, or 21 per cent.; splints of plaster and wood in 8, and treatment not stated in 192, or 36 per cent.

Discharge Results.—The results on discharge from the hospital were: shortening, ½ to 2½ inches, in 101 cases; left hospital on crutches, 189; left hospital in cast, 39; able to walk, 51; nonunion (questionable), 6, and discharge condition not stated, 240, or 47 per cent.

Operations on Fractures of the Femur.—The total number of operations performed to reduce these fractures was fifty-one. divided as in Table 6.

TABLE 6.—OPERATIONS AND RESULTS

Operation		Number	Results	
Site	Type		Good	Bad
Neck	Bone peg	5	2	3
Neck	Steel screws	6	2	4
Shaft	Steel plates	15	6	9
Shaft	Intramedullary bone pegs	11	7	4
Shaft	Metal screws	1	..	1
Shaft	Simple replacement	3	3	
Shaft	Calipers	7	5	2
Shaft	Nail extension	2	1	1
Shaft	Parham's band	1	1	

Mortality Following Operation.—The total deaths following operative interference were 4, or about 8 per cent.: neck, metal screws, 2; shaft, intramedullary bone peg, 1, and shaft, nail extension, 1.

SUGGESTIONS FOR STANDARD TREATMENT

The results tabulated here are not good. In an attempt to improve the results I make the following suggestions:

Indications for Fixation and Traction.—In the general consideration of treatment it is acknowledged that the femur is richly supplied with strong muscular attachments, and consequently a reduction of fracture in any part of its continuity cannot be obtained by simple fixation of the thigh. In addition to fixation, there must be traction to obtain relaxation of the muscles which have become infiltrated with blood to a certain degree, following the trauma. The infiltration causes muscle shortening and pull on the bone, holding it out of normal alinement, *once it is broken.* Traction in the axis of normal muscle action and weight-bearing overcomes muscular contraction and puts the muscles at rest, just as fixation puts the broken ends of the bone at rest. When

these two indications are met, we are treating the fracture properly, but an effort must be made to obtain the best ultimate function of the limb. Hence we must restore the bone to its normal physiologic axis and secure bony union and bone integrity to assure both a structural and functional restoration. Consequently, proper methods of treatment demand precision and system. *The patient with a fractured femur should be hospitalized.* Roentgen-ray examination with reduction and splinting should be made at once, so that a maximum muscle infiltration and contraction will not occur and so that bone fragments may be approximated and immobilized.

General Law of Fracture Treatment.—The distal bone fragment over which the surgeon has control must be brought into a plane of normal relation with the proximal fragment. When this practice becomes general, both the suffering and mortality incident to fractures of the femur will be greatly lessened. In aged patients, some of the mortality is the result of the so-called conservative methods of treatment which lead to pain and which wear out the patients' strength and resistance, so that they succumb easily.

Treatment of the Fracture of Different Parts of the Femur.—Suggestions for standard specific treatment of fractures of the femur may be divided according to the site of fracture, thus—neck, intertrochanteric, subtrochanteric, shaft, supracondylar, epiphyseal separation, and condylar.

FRACTURES OF THE NECK

Of the 124 cases of fracture of the neck in our series, seventy-two were in females and fifty-two in males. Among the twenty deaths after fracture of the neck, only six were in males. This would make it appear that the probability of fatal issue in females was greater than in males after fractures of the neck. The average age of the six males who died was 68; of the fourteen females, 61 years. Only five of the deaths occurred in patients under 60 years of age. Distribution of the neck fractures according to age is given in Table 7.

TABLE 7.—DISTRIBUTION OF FRACTURES OF THE NECK OF THE FEMUR ACCORDING TO AGE

Age	Number of Cases
1- 10	2
11- 20	0
21- 30	3
31- 40	4
41- 50	23
51- 60	25
61- 70	27
71- 80	36
81- 90	10
91-100	1

Methods of Treatment.—The methods of treatment for the whole series of 526 cases were: rest in bed, sand bags, sitting up in bed supported by pillows, etc., in 35 cases; Thomas splint with suspension traction in 25 cases; vertical extension in children in 56; Buck's extension, sometimes combined with Liston's splint, double inclined plane and molded plaster-of-Paris splints in 97; fracture table, extension and cast in 113, or 21 per cent.; splints of plaster and wood in 8, and treatment not stated in 192, or 36 per cent.

Discharge Results.—The results on discharge from the hospital were: shortening, ½ to 2½ inches, in 101 cases; left hospital on crutches, 189; left hospital in cast, 39; able to walk, 51; nonunion (questionable), 6, and discharge condition not stated, 240, or 47 per cent.

Operations on Fractures of the Femur.—The total number of operations performed to reduce these fractures was fifty-one. divided as in Table 6.

TABLE 6.—OPERATIONS AND RESULTS

Operation		Number	Results	
Site	Type		Good	Bad
Neck	Bone peg	5	2	3
Neck	Steel screws	6	2	4
Shaft	Steel plates	15	6	9
Shaft	Intramedullary bone pegs	11	7	4
Shaft	Metal screws	1	..	1
Shaft	Simple replacement	3	3	
Shaft	Calipers	7	5	2
Shaft	Nail extension	2	1	1
Shaft	Parham's band	1	1	

Mortality Following Operation.—The total deaths following operative interference were 4, or about 8 per cent.: neck, metal screws, 2; shaft, intramedullary bone peg, 1, and shaft, nail extension, 1.

SUGGESTIONS FOR STANDARD TREATMENT

The results tabulated here are not good. In an attempt to improve the results I make the following suggestions:

Indications for Fixation and Traction.—In the general consideration of treatment it is acknowledged that the femur is richly supplied with strong muscular attachments, and consequently a reduction of fracture in any part of its continuity cannot be obtained by simple fixation of the thigh. In addition to fixation, there must be traction to obtain relaxation of the muscles which have become infiltrated with blood to a certain degree, following the trauma. The infiltration causes muscle shortening and pull on the bone, holding it out of normal alinement, *once it is broken.* Traction in the axis of normal muscle action and weight-bearing overcomes muscular contraction and puts the muscles at rest, just as fixation puts the broken ends of the bone at rest. When

these two indications are met, we are treating the fracture properly, but an effort must be made to obtain the best ultimate function of the limb. Hence we must restore the bone to its normal physiologic axis and secure bony union and bone integrity to assure both a structural and functional restoration. Consequently, proper methods of treatment demand precision and system. *The patient with a fractured femur should be hospitalized.* Roentgen-ray examination with reduction and splinting should be made at once, so that a maximum muscle infiltration and contraction will not occur and so that bone fragments may be approximated and immobilized.

General Law of Fracture Treatment.—The distal bone fragment over which the surgeon has control must be brought into a plane of normal relation with the proximal fragment. When this practice becomes general, both the suffering and mortality incident to fractures of the femur will be greatly lessened. In aged patients, some of the mortality is the result of the so-called conservative methods of treatment which lead to pain and which wear out the patients' strength and resistance, so that they succumb easily.

Treatment of the Fracture of Different Parts of the Femur.—Suggestions for standard specific treatment of fractures of the femur may be divided according to the site of fracture, thus—neck, intertrochanteric, subtrochanteric, shaft, supracondylar, epiphyseal separation, and condylar.

FRACTURES OF THE NECK

Of the 124 cases of fracture of the neck in our series, seventy-two were in females and fifty-two in males. Among the twenty deaths after fracture of the neck, only six were in males. This would make it appear that the probability of fatal issue in females was greater than in males after fractures of the neck. The average age of the six males who died was 68; of the fourteen females, 61 years. Only five of the deaths occurred in patients under 60 years of age. Distribution of the neck fractures according to age is given in Table 7.

TABLE 7.—DISTRIBUTION OF FRACTURES OF THE NECK OF THE FEMUR ACCORDING TO AGE

Age	Number of Cases
1- 10	2
11- 20	3
21- 30	5
31- 40	4
41- 50	13
51- 60	13
61- 70	23
71- 80	18
81- 90	19
91-100	1

Methods of Treatment.—The methods of treatment for the whole series of 526 cases were: rest in bed, sand bags, sitting up in bed supported by pillows, etc., in 35 cases; Thomas splint with suspension traction in 25 cases; vertical extension in children in 56; Buck's extension, sometimes combined with Liston's splint, double inclined plane and molded plaster-of-Paris splints in 97; fracture table, extension and cast in 113, or 21 per cent.; splints of plaster and wood in 8, and treatment not stated in 192, or 36 per cent.

Discharge Results.—The results on discharge from the hospital were: shortening, ½ to 2½ inches, in 101 cases; left hospital on crutches, 189; left hospital in cast, 39; able to walk, 51; nonunion (questionable), 6, and discharge condition not stated, 240, or 47 per cent.

Operations on Fractures of the Femur.—The total number of operations performed to reduce these fractures was fifty-one. divided as in Table 6.

TABLE 6.—OPERATIONS AND RESULTS

Operation		Number	Results	
Site	Type		Good	Bad
Neck	Bone peg	5	2	3
Neck	Steel screws	6	2	4
Shaft	Steel plates	15	6	9
Shaft	Intramedullary bone pegs	11	7	4
Shaft	Metal screws	1	..	1
Shaft	Simple replacement	3	3	
Shaft	Calipers	7	5	2
Shaft	Nail extension	2	1	1
Shaft	Parham's band	1	1	

Mortality Following Operation.—The total deaths following operative interference were 4, or about 8 per cent.: neck, metal screws, 2; shaft, intramedullary bone peg, 1, and shaft, nail extension, 1.

SUGGESTIONS FOR STANDARD TREATMENT

The results tabulated here are not good. In an attempt to improve the results I make the following suggestions:

Indications for Fixation and Traction.—In the general consideration of treatment it is acknowledged that the femur is richly supplied with strong muscular attachments, and consequently a reduction of fracture in any part of its continuity cannot be obtained by simple fixation of the thigh. In addition to fixation, there must be traction to obtain relaxation of the muscles which have become infiltrated with blood to a certain degree, following the trauma. The infiltration causes muscle shortening and pull on the bone, holding it out of normal alinement, *once it is broken.* Traction in the axis of normal muscle action and weight-bearing overcomes muscular contraction and puts the muscles at rest, just as fixation puts the broken ends of the bone at rest. When

these two indications are met, we are treating the fracture properly, but an effort must be made to obtain the best ultimate function of the limb. Hence we must restore the bone to its normal physiologic axis and secure bony union and bone integrity to assure both a structural and functional restoration. Consequently, proper methods of treatment demand precision and system. *The patient with a fractured femur should be hospitalized.* Roentgen-ray examination with reduction and splinting should be made at once, so that a maximum muscle infiltration and contraction will not occur and so that bone fragments may be approximated and immobilized.

General Law of Fracture Treatment.—The distal bone fragment over which the surgeon has control must be brought into a plane of normal relation with the proximal fragment. When this practice becomes general, both the suffering and mortality incident to fractures of the femur will be greatly lessened. In aged patients, some of the mortality is the result of the so-called conservative methods of treatment which lead to pain and which wear out the patients' strength and resistance, so that they succumb easily.

Treatment of the Fracture of Different Parts of the Femur.—Suggestions for standard specific treatment of fractures of the femur may be divided according to the site of fracture, thus—neck, intertrochanteric, subtrochanteric, shaft, supracondylar, epiphyseal separation, and condylar.

FRACTURES OF THE NECK

Of the 124 cases of fracture of the neck in our series, seventy-two were in females and fifty-two in males. Among the twenty deaths after fracture of the neck, only six were in males. This would make it appear that the probability of fatal issue in females was greater than in males after fractures of the neck. The average age of the six males who died was 68; of the fourteen females, 61 years. Only five of the deaths occurred in patients under 60 years of age. Distribution of the neck fractures according to age is given in Table 7.

TABLE 7.—DISTRIBUTION OF FRACTURES OF THE NECK OF THE FEMUR ACCORDING TO AGE

Age	Number of Cases
1– 10	2
11– 20	0
21– 30	3
31– 40	4
41– 50	23
51– 60	28
61– 70	27
71– 80	26
81– 90	10
91–100	1

Fractures of the Neck in Childhood.—Fracture of the neck occurs in childhood frequently, and was first thoroughly described in America by Royal Whitman in 1890. An early diagnosis is highly desirable because reduction should be made at once. Many of the fractures of the neck in adolescents are epiphyseal separations with little displace-

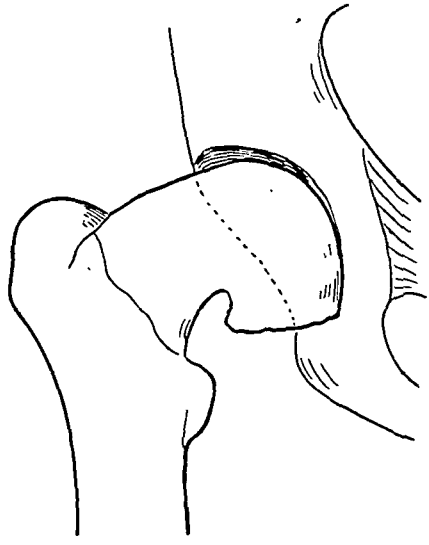

Fig. 1.—Healed neck fracture, with coxa vara from too early unsupported weight-bearing. This illustration and Figures 4, 7, 8, 10, 12 to 25, 32, and 37 to 42 are adapted from the author's textbook, "Fractures and Dislocations," Lea & Febiger, Philadelphia, 1916.

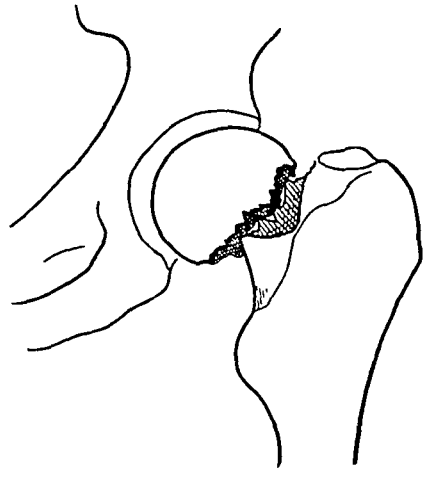

Fig. 2.—The usual type of neck fracture of the femur with a minimum amount of shortening, foot rotated outward. When this fracture was reduced the roentgenogram revealed almost perfect neck angulation and apposition of fragments.

ment. The causative trauma may be overlooked. The child, unlike an adult, may walk away from the scene of the accident, and the gradual displacement accompanying the change in the angle of the femoral neck with shortening frequently follows, as the patient bears weight on the injured leg (Fig. 1). Some process of repair accompanies the gradual displacement of the shaft upward. If the diagnosis is not made early, the neck may be molded, after several weeks, into a firm bony mass, which then requires open operation to effect a perfect reduction.

Technic of Reduction.—If the fresh fracture has resulted in complete separation, either through the epiphyseal line of the neck or at

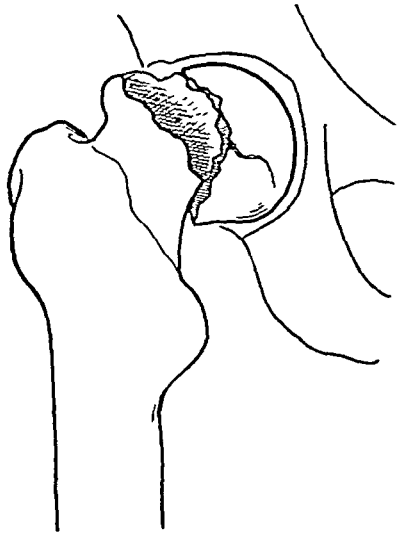

Fig. 3.—Fracture of the neck of the femur involving the head, the usual displacement. It is perfectly evident that there is shortening, rotation outward of the foot and change of the normal axis (130 degrees) of the femoral neck, and that extension, internal rotation followed by complete abduction of the thigh are necessary to effect a proper relation of fragments.

the base of the neck, the shaft usually is moved upward, backward and outward (Fig. 2). Hence to appose the fractured surfaces, the distal portion of the limb over which the surgeon has control must be lifted forward, rotated inward and then must be drawn down to normal length (Fig. 3). This is followed by *abduction to the limit,* so that the greater trochanter is apposed to the rim of the acetabulum and the side of the pelvis and the neck is brought into alinement and contact with the head, aided partly by the capsular ligament and the resistance of the head against the acetabulum. The angle of the neck is thus restored (Fig. 4).

Result of Restoration of Angle of the Neck.—In this position of extreme abduction, the security of the reduction is assured by the capsule, the bony contact and the muscular impotence incidental to the position. Because the range of abduction in the human hip depends on the normal angle of the femoral neck to the shaft, this reduction in a position of extreme abduction looks toward a perfect reestablishment of the angle of the neck. If that is secured, there is no insecure support of the hip later, no shortening and no compensatory distortion of the pelvis is required to accommodate for a changed angle of the neck.

Body Casts and Hip Spicas of Plaster of Paris.—While the leg is in extreme abduction, the patient is placed in a plaster-of-Paris cast

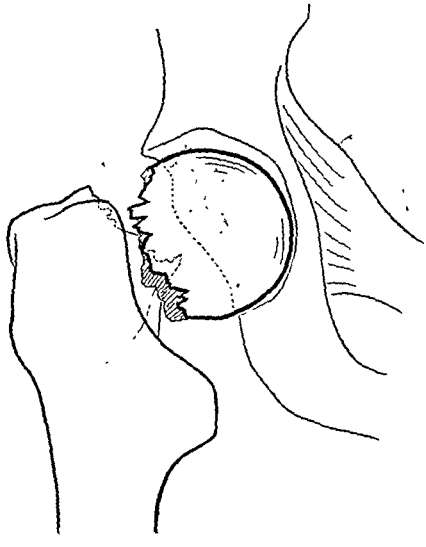

Fig. 4.—Attempted reduction by extension in a straight line. Some length has been regained, but the neck angle is still about 90 degrees and can be corrected by complete abduction. Healing in the position shown would lead to an adducted leg and some shortening.

(Fig. 5), extending from the nipples to the toes, for from eight to twelve weeks, and is not allowed to bear weight for from three to six months thereafter. He must use a walking caliper fitted into the shoe during this period to avoid subsequent development of coxa vara.

The technic of application of the body cast requires that all bony points should be completely padded to avoid pressure necrosis and that the plaster should be well reinforced at the weak points, namely, at the groin and outer aspect of the thigh up to the waist. For padding purposes, I have found that saddler's felt is the best material. The usual cotton or stockinet wadding is used to cover the patient, and the saddler's felt padding is applied in addition. Nine pieces, each about 6 inches square, are required. One is placed over each anterior superior

iliac spine, one over the sacrum between the sacrum and the sacral support, one on each lateral aspect of the knee to be included in the cast and one on each side of both ankles to soften the force used in extension and traction on the fracture table. Multiple layers of plaster bandage are applied longitudinally over the front of the groin and the lateral aspect of the thigh to give strength. This additional strength makes tipping of the patient in the cast, for hygienic purposes and necessary change of position, safe. A fairly large sized pad is placed over the epigastrium (dinner pad) before the cast is applied. This allows room for distention after eating, without unpleasant pressure.

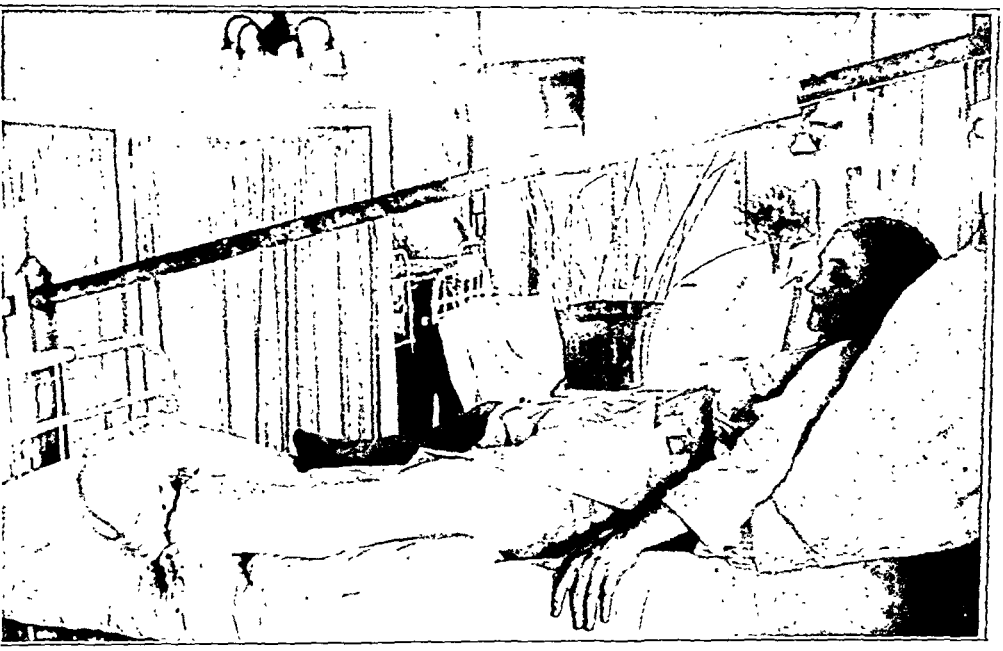

Fig. 5.—Woman, aged 52 years, with fracture of the neck of the femur in body cast. Both legs abducted. The feet are off the edge of the bed on either side, and a more than half sitting posture is possible. She can be turned on her side or even onto her face safely. The cast reaches down to the knee on the uninjured leg. By the pole above the bed, she can move the upper part of the body at will.

After-Treatment—the Walking Caliper.—The walking caliper is made like a Thomas leg splint with a snug fitting thigh ring. The lower ends of the iron side-bars are turned in at right angles and fitted into the heel of the boot, the hole in the boot being of such length that in walking the patient's weight is supported largely by ring pressure against the tuberosity of the ischium. Calipers can be made with adjustable side rods, and they are strapped to the leg by broad canvas

bands (Fig. 6). When the patient goes to bed, the calipers are removed, because the soft callus does not have to support weight.

Treatment of Fractures of the Neck in Adults.—The same treatment is applicable in fractures of the neck of the femur in adults, whether impacted or not, unless the physical condition of the patient precludes any active treatment. It should give a high average of successful results. There is little doubt that nonunion will seldom occur if this careful approximation of fragments is attained. The capacity for

Fig. 6.—Patient in walking caliper after cure of fracture of neck of the femur. Straps hold the leg firmly and the leather ring presses against the ischial tuberosity when the patient bears weight. The length is adjustable by means of the threaded bar and lock nuts.

repair in bony tissues in adults is not so great as it is in children; but still it is active, as evidenced by bony union following open operation on ununited fracture of the femoral neck, where simple freshening and fixation of fragments in apposition is the only operative work performed. The cast is most frequently applied with the patient anesthetized, lying on a fracture table.

Rationale of Abduction Treatment for Fractures of the Neck.—The position of extreme abduction offers the best chance for mechanical apposition of fragments, and that appears to be more important than the blood supply of the head fragment, when ultimate bony union is considered. In this position, the greater trochanter and neck come into close relation with the upper border of the acetabular rim. The Y ligament also assumes a position where it exercises its greatest strength and function, being used as a suspensory fulcrum, on which the major fragment (shaft) is swung outward and into direct contact with the head fragment, on which a direct hold cannot be obtained. After recent fracture of the neck, whether through its narrow or broad portions, this method of treatment approximates satisfactorily the fractured surfaces, and immobilization in the abduction position results in bony union (Fig. 7).

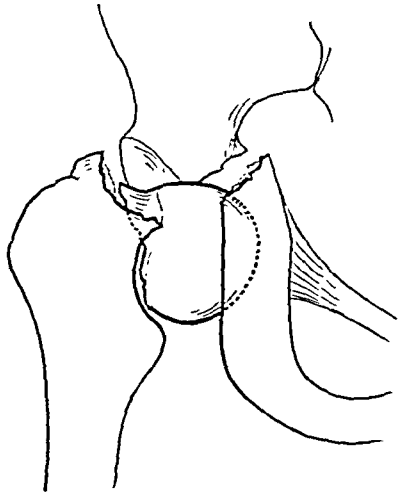

Fig. 7.—The pelvis may be broken along with the femoral neck fracture. The neck angle is less than 90 degrees.

Treatment of Old Fractures in Adults.—In old fractures, however, even where the head fragment is levered into position, it may be difficult to maintain bony contact (Fig. 8). Shortening of the neck, caused by bone absorption from the irritation of motion and use and incomplete reduction, becomes so great that the trochanter impinges on the acetabular rim during abduction and hyperabduction; it may cause a separation of the fragments, rather than a forced contact. Consequently, in old fractures, in order to secure a bony union, it has been considered best to introduce a bone peg through the trochanteric region into the head, while the limb is in a position of extreme abduction. I have

treated a few patients, whose cases are classed under this head, in whom simple freshening of the fragment surfaces near the hip joint, without the introduction of a bone splint, followed by a sufficient period of immobilization in abduction, resulted in bony union. If the head and neck are so much absorbed that a fragment of only from 1 to 1.5 cm. in thickness remains, certain operative methods are necessary if a weight-bearing, painless hip is secured. Either an autogenous bone peg can be driven clear through the head into the acetabulum making a bony ankylosis, fulfilling the conditions mentioned, or the head may be excised and the freshened neck and acetabulum placed in apposition with the thigh in abduction, a bony union being desired (Fig. 9). Tilting of the pelvis will accommodate for much of the shortening, and the bony union will be painless. The necessary factor after operation is the firm

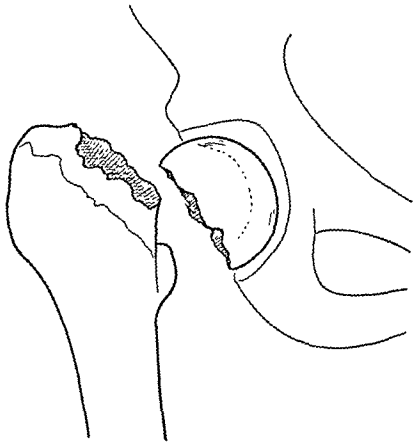

Fig. 8.—Fracture of the femoral neck which had gone untreated for some time. Absorption of the neck and head fragment, adduction of the leg and shortening and rotation of the foot outward are apparent. The abduction position in this type may lead to bony union; more often operation is indicated.

body cast applied while the patient is on a fracture table, with the *thigh in complete abduction,* with the foot rotated inward. If the patient cannot tolerate rest in bed even in the half sitting position that such a cast permits, abduction and extension by the Thomas or Hodgen splint, with rotation of the thigh inward, will also be impossible. If these methods are not applicable, the patient must then be placed in a wheel chair or set up in bed. The result will be a fibrous union of the shaft to the pelvis, which will permit the maximum of shortening when weight is borne on the limb. The pain in such a hip may eventually become bearable, but usually the function is very poor.

Results in Fractures of the Neck.—Probably not more than 15 per cent. of fractures of the neck in adults result in bony union, unless the

patients are treated by extreme abduction (Fig. 10). Originally impacted neck fractures, let alone and not broken up nor brought into reduction and abduction, result, if union obtains, in a short, adducted and outwardly rotated leg. To avoid the bed confinement in a supine position, Moore advised a modification of the Whitman method by the application of the cast with the thigh in abduction, while the patient is in a sitting position. He treated sixteen patients thus, nine of whom were more than 70 years of age; seven had good functional results, one died, two had nonunion, two were not traced and three were still under treat-

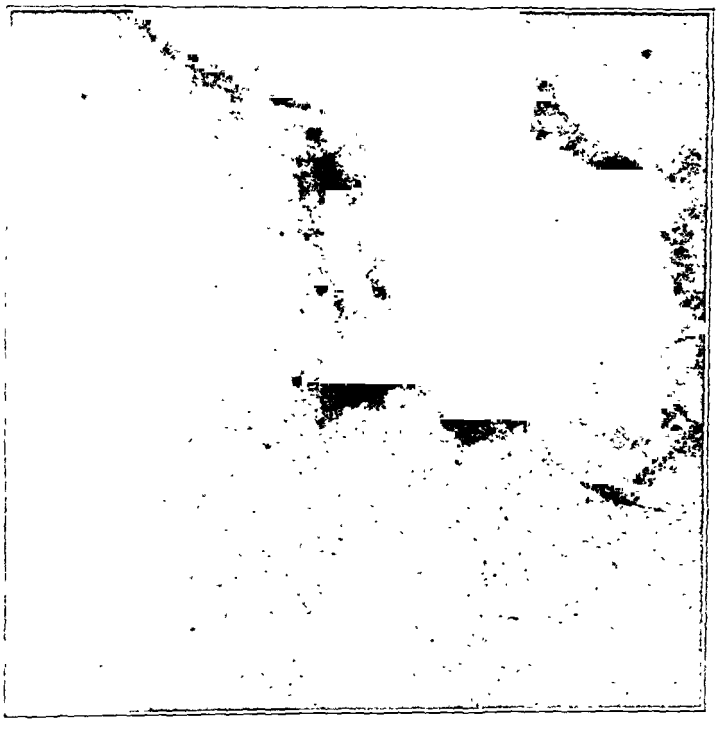

Fig. 9.—Bone transplant into the pelvis through the femur and broken off head. This patient was more than 50 years old and had had this fracture of the neck of the femur for two years. The neck angle has been well restored. the hip is in maximum abduction and the patient now has a weight-bearing, painless, stiff hip joint.

ment. When the ordinary body cast is properly applied the patient can easily assume a half sitting posture (Fig. 5).

Extension Without Abduction in Neck Fractures.—Buck's extension and extension by a Thomas or Hodgen splint with traction and suspension fail to consider the degree of abduction necessary to restore the angle after fracture of the neck. If one leg is drawn into abduc-

tion in these suspended splints, the angulation is not steady because the patient's pelvis is not fixed. The patient consequently can, and does, tip the pelvis to overcome the abduction. Putting both legs in extreme abduction in a suspended Thomas splint or Sinclair's net bed will secure the necessary abduction, but the bed confinement is as severe as that induced by a cast. The same arguments apply to caliper extension (Fig. 11).

Résumé of Treatment of Fractures of the Neck.—The best treatment of fractures in youth or other age is immediate reduction and use of the position of extreme abduction in a plaster-of-Paris body cast. After the patient is etherized, the trochanter is lifted up, the foot is rotated inward, and the leg is drawn down to the fullest extent. Then it is swung out into extreme abduction while still under traction. This procedure is most easily carried out while the patient is on a fracture

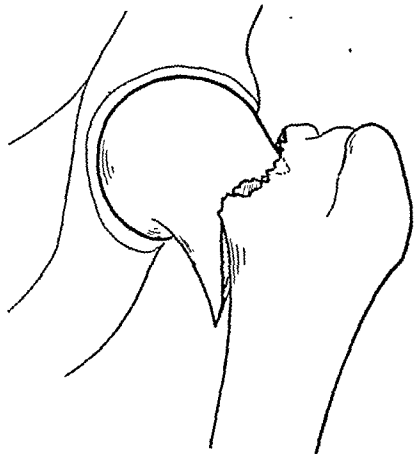

Fig. 10.—Fracture of the femoral neck with impaction. Shortening, adduction of the leg and change of the neck angle are all present. Abduction treatment in a plaster spica would promise a much better result than a "leave impaction alone" treatment.

table. It is almost impossible to secure permanent, proper abduction with restoration of the angle of the neck by any other means. If the patient's health will not permit the use of a plaster cast, it will also preclude the use of any traction which requires bed confinement. Therefore, since no half-hearted method of traction will secure bony apposition and lead to bony union, the only other treatment, which is really no treatment, is sitting up in bed or in a wheel chair supported by pillows.

Impacted Fractures of the Aged.—In the aged, who cannot tolerate the cast abduction treatment, any impaction of fragments should be let alone. The fragments usually slip apart in a few days after rest in bed.

Patients Suffering from Delayed Treatment.—If the patient is not seen for many days after a fracture and a maximum of shortening, combined with some bone absorption in the neck has followed, the abduction and cast method should also be used. Should neck absorption be great enough to lead the surgeon to fear delayed or nonunion, the patient should be subjected to immediate operation, an autogenous bone peg being passed through the trochanter up into the head with the neck angle

Fig. 11.—Double suspension traction in abduction. By this means abduction of the thigh can be maintained. For fractures of the neck of the femur we prefer the plaster spica or cast, allowing the patient to sit up.

restored. Exogenous bone and metal screws or nails should never be used in the neck of the femur. Any successful cases that have been reported following the insertion of nails or screws in the femoral neck for fracture may be attributed to the immobilization and to a position of abduction maintained during the healing, and occurred *in spite* of the foreign body present.

Vicious Union—Coxa Vara.—The most common deformity requiring treatment after vicious union of fractures of the neck of the femur is coxa vara. The neck is shortened, thickened and painful when weight is borne; its angle with the shaft has been reduced to 90 degrees or less, and the shortened adducted leg gives evidence of deformity. For these patients, an osteotomy alone promises a better result. If the thickened neck still permits free hip motion, one may cut across the neck and swing the leg out into extreme abduction and inward rotation under strong traction, hoping to gain a better neck angle and better function. If there is bony union between the neck and head and the pelvis with an adducted leg, one can improve the function by

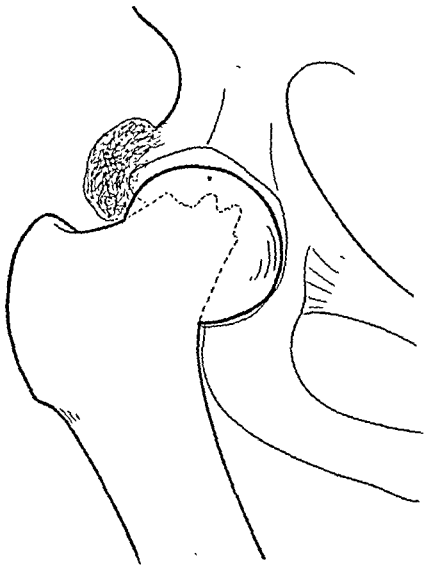

Fig. 12.—Impacted fracture healed with adduction and limited motion. Exostosis at acetabular border.

performing a subtrochanteric osteotomy, swinging the leg into abduction and letting it unite in this position (Fig. 12).

UNUNITED FRACTURES OF THE NECK

Ununited fractures of the neck of the femur demand treatment when the patient desires to be relieved of the disability, usually shown by shortening, adduction of the leg, lameness, the necessity of using a crutch or cane and pain.

Some Causes of Nonunion.—There is no doubt that most instances of nonunion or malunion could be avoided if the adequate primary treatment of extension and abduction outlined were applied after an early correct diagnosis. When true nonunion has occurred no manipu-

lation method will cure; surgical operation alone can give bony union. Some patients treated by the proper method are allowed to bear weight too soon; coxa vara or even a breaking down of the soft callus may result with all the findings of a nonunion. No patient after fracture of the neck of the femur should bear weight on the bone for six months; he should wear a walking caliper.

Treatment of Ununited Fractures of the Neck.—A series of 120 cases of nonunion of hip fractures was reviewed by Henderson. There were sixty-eight males and fifty-two females. Twenty-six were operated on with no deaths, ninety-four were dismissed without treatment. Nails or screws were used in eight cases; bone transplants in eighteen cases. Only two operative wounds were infected. The fibula was used as the graft, and every care was taken to restore the angle of the neck.

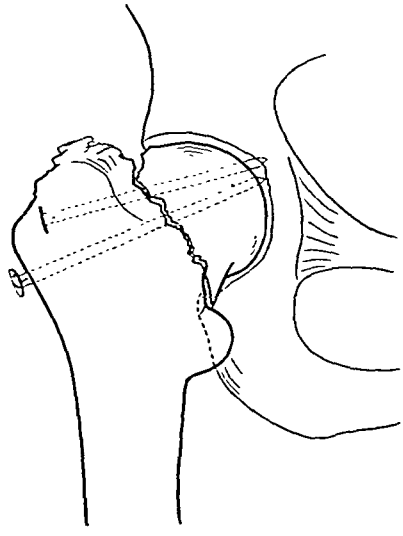

Fig. 13.—Old fracture of femoral neck treated by nailing. Because the nails projected into the acetabular cartilage and caused pain, they were removed eighteen months later. The neck had not united.

Full exposure was made by a U-shaped incision with removal of the greater trochanter. All patients were on a fracture table, and after operation were placed in plaster-of-Paris casts. The end-results in seven cases were not known; ten operations were successful; eight were failures. The percentage of good operative results was 38. but of the entire series of 120 patients only 8.3 per cent. were improved. It was concluded that any means, in suitable cases, which will freshen the fractured surfaces and maintain them in apposition (abduction and traction) are sufficient. I agree with that conclusion, and believe that the value of the autogenous bone peg inserted through the neck into

Vicious Union—Coxa Vara.—The most common deformity requiring treatment after vicious union of fractures of the neck of the femur is coxa vara. The neck is shortened, thickened and painful when weight is borne; its angle with the shaft has been reduced to 90 degrees or less, and the shortened adducted leg gives evidence of deformity. For these patients, an osteotomy alone promises a better result. If the thickened neck still permits free hip motion, one may cut across the neck and swing the leg out into extreme abduction and inward rotation under strong traction, hoping to gain a better neck angle and better function. If there is bony union between the neck and head and the pelvis with an adducted leg, one can improve the function by

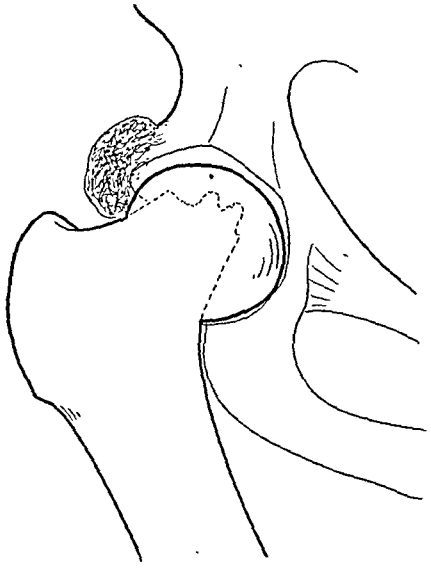

Fig. 12.—Impacted fracture healed with adduction and limited motion. Exostosis at acetabular border.

performing a subtrochanteric osteotomy, swinging the leg into abduction and letting it unite in this position (Fig. 12).

UNUNITED FRACTURES OF THE NECK

Ununited fractures of the neck of the femur demand treatment when the patient desires to be relieved of the disability, usually shown by shortening, adduction of the leg, lameness, the necessity of using a crutch or cane and pain.

Some Causes of Nonunion.—There is no doubt that most instances of nonunion or malunion could be avoided if the adequate primary treatment of extension and abduction outlined were applied after an early correct diagnosis. When true nonunion has occurred no manipu-

lation method will cure; surgical operation alone can give bony union. Some patients treated by the proper method are allowed to bear weight too soon; coxa vara or even a breaking down of the soft callus may result with all the findings of a nonunion. No patient after fracture of the neck of the femur should bear weight on the bone for six months; he should wear a walking caliper.

Treatment of Ununited Fractures of the Neck.—A series of 120 cases of nonunion of hip fractures was reviewed by Henderson. There were sixty-eight males and fifty-two females. Twenty-six were operated on with no deaths, ninety-four were dismissed without treatment. Nails or screws were used in eight cases; bone transplants in eighteen cases. Only two operative wounds were infected. The fibula was used as the graft, and every care was taken to restore the angle of the neck.

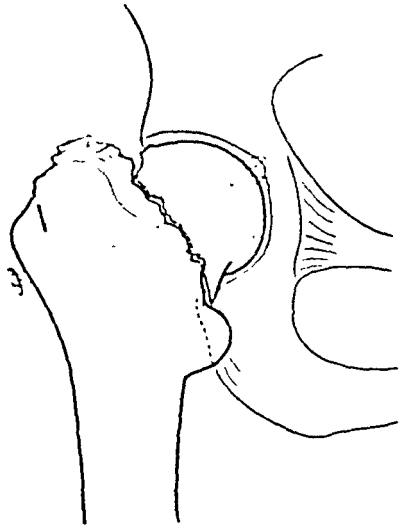

Fig. 13.—Old fracture of femoral neck treated by nailing. Because the nails projected into the acetabular cartilage and caused pain, they were removed eighteen months later. The neck had not united.

Full exposure was made by a U-shaped incision with removal of the greater trochanter. All patients were on a fracture table, and after operation were placed in plaster-of-Paris casts. The end-results in seven cases were not known; ten operations were successful; eight were failures. The percentage of good operative results was 38, but of the entire series of 120 patients only 8.3 per cent. were improved. It was concluded that any means, in suitable cases, which will freshen the fractured surfaces and maintain them in apposition (abduction and traction) are sufficient. I agree with that conclusion, and believe that the value of the autogenous bone peg inserted through the neck into

the head has been overrated. Some operators use two incisions, one over the trochanter through which to insert the peg, another over the femoral neck just outside the great vessels, to freshen the fragments and give a proper guide to the bone peg as it is inserted. Traction and extreme abduction are required on a fracture table during the operation.

A series of eight cases of nonunion of the neck of the femur treated by the insertion of nails was reported by Swett. He made a lateral incision only, making no attempt to freshen the fragments. The results were not satisfactory (Fig. 13).

Absorption of the Femoral Neck.—When the neck fragment has been absorbed by use and improper treatment and when the head is

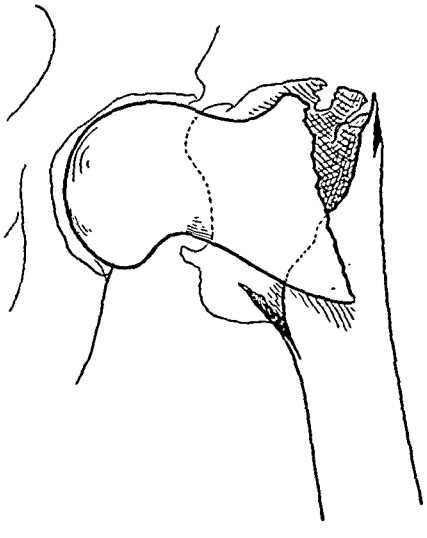

Fig. 14.—Intertrochanteric fracture. The changed neck angle and the large surface of cancellous tissue which insures bony union may be noted. Abduction plainly indicated.

atrophied so that only the articular portion, which does not project beyond the acetabular margin, remains, it is difficult to bring the fragments in apposition.

Viability of the Head of the Femur.—It has always been asserted that the state of nutrition of the head fragment is also a point to be decided. Even if it does not bleed when scraped, it may be viable and conditions favorable to full return of life must be established. A head which has thus been long separated from the shaft is somewhat softened, yellow and contains little holding substance into which a bone transplant can be driven. In the old cases, the use of the graft as a carrier of osteogenetic stimulus is futile unless there is also firm apposition of fragments. It is hardly reasonable to expect

the transplant, which must first be partly renourished by the shaft portion, to save the life of the soft head fragment. Bone regeneration must be developed in the bridge of the transplant and by it carried into bone partly dead. Consequently, some operations for nonunion of the neck by means of a bone transplant will not succeed. If the head in these old cases is considered as a sequestrum, it may become vitalized if grafted on living cancellous bone.

Brackett and New have advised placing the head of the femur on the inner, upper side of the sawed off and freshened trochanter, which is abducted enough to come into contact. After the leg had been in a plaster-of-Paris cast for ten weeks they obtained seven good results in nine cases in which this operation had been performed. The unions

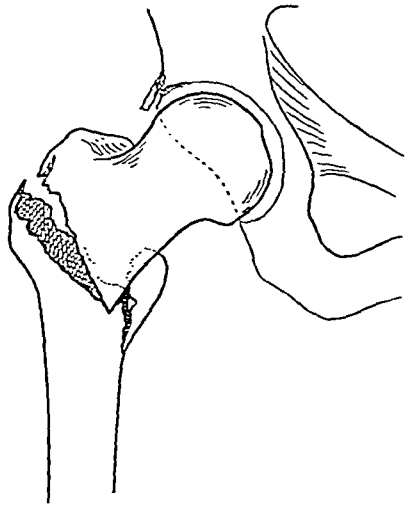

Fig. 15.—Intertrochanteric fracture with separation of the lesser trochanter and tearing of the acetabular rim. Abduction is plainly indicated in the treatment.

were strong and bore weight well; the amount of motion in the hip was not complete but was practical.

Operative Treatment.—My treatment has been as follows:

If there has not been great absorption of the neck, the fragments are freshened through an anterior incision and an autogenous bone peg is then inserted from the trochanter into the head, while traction is maintained and the extremity is abducted and rotated inward. In patients over 50 years of age in whom the hope of bony union of the head to the neck is diminished, it may be better practice to produce an ankylosed hip by driving the bone peg clear on into the pelvis. This promises a stiff hip which bears weight painlessly, which demands a

shorter bed and cast confinement. This bone transplant ankylosis operation is more quickly performed than excision of the head, and it is less of a shock to the patient. However, as stated, I am beginning to doubt the value of the bone transplant. When the head is largely absorbed and fragmented, the best treatment is its excision with freshening of

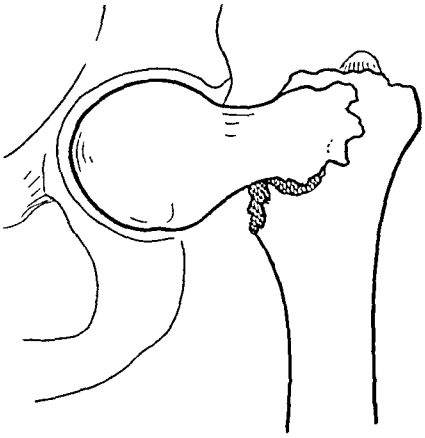

Fig. 16.—Intertrochanteric fracture with shortening and changed neck angle, indicating extension followed by abduction to restore normal position.

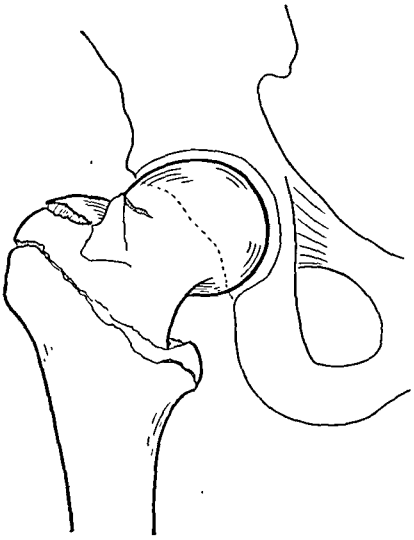

Fig. 17.—Intertrochanteric fracture with little displacement, but one which requires abduction.

the bony surfaces, so that when the limb is drawn down and completely abducted, bony ankylosis in that position results. Brackett's operation is more extensive; it must be reserved for younger and more active patients for whom length of limb and hip joint motion are very essential.

INTERTROCHANTERIC FRACTURE

Intertrochanteric fractures mostly result from direct violence. The plane of fracture runs diagonally from one trochanter to another, and either or both trochanters may be broken off and separated. The great proportion of these fractures makes their treatment important. Many occur in patients who lead an active life and have need of good leg function. The displacements vary—usually there is little shortening, ½ to 1 inch; but the neck angle is reduced from 130 degrees to about 90 degrees in most instances (Figs. 14 and 15). Traction will easily restore full length, and the swinging out to full abduction restores the neck angle. A body plaster-of-Paris cast applied while the patient is on the fracture table in this position gives excellent

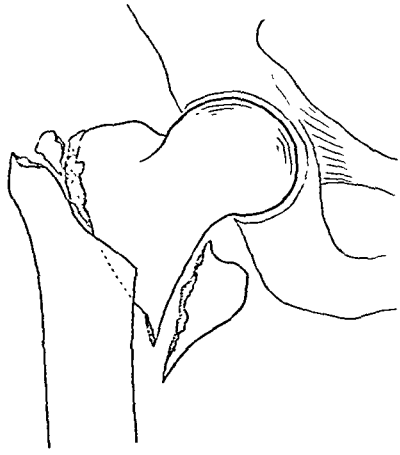

Fig. 18.—Intertrochanteric fracture involving both trochanters. The changed angle between the shaft and neck fragments may be noted.

results. If there is impaction and the patient cannot be confined to bed, sand bags or pillows and a sitting position will frequently give a satisfactory result but with some shortening (Figs. 16 and 17). Non-union of this portion of the bone is rare, because of the large cancellous surfaces which come in contact. Bony union results even when no mobilizing treatment is employed (Fig. 18).

However, our statistics show a higher mortality from this fracture than from fractures of the neck, and we advise great care of the heart and lungs of these patients. Many are very fat, with corresponding cardiac weakness. Prolonged anesthesia should be avoided. If union should fail, an autogenous bone peg or a simple freshening of the bone surfaces is all that is needed operatively before a cast is applied. A walking caliper is required for six months to avoid coxa vara.

TROCHANTERIC FRACTURES

Fractures of the trochanters alone do not often demand unusual treatment. If the greater trochanter is widely separated by the attached muscles, it may be pegged onto the rest of the bone and the leg immobilized in abduction. Usually abduction or rest in bed for two or three weeks gives a useful leg (Fig. 19). Fracture of the lesser trochanter alone is rare. Because the separated fragment is pulled up and inward, it is sufficient to treat the patient by setting him up in bed, with the thigh flexed on the body, for three weeks. Casts are rarely required to maintain this position (Fig. 20).

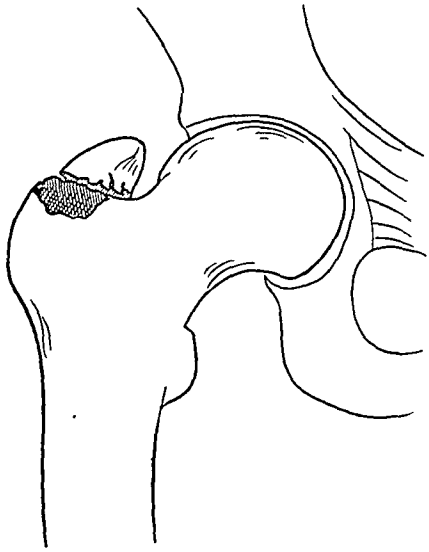

Fig. 19.—Fracture of the greater trochanter.

SUBTROCHANTERIC FRACTURES

Subtrochanteric fractures are not frequently encountered; but they are very important inasmuch as the relative angle of the neck is lessened and shortening occurs. The distal or shaft fragment may be displaced above the level of the acetabulum. These fractures are often short spirals or oblique. It is often most difficult to reduce the deformity and to maintain the fragments in apposition. The two fragments are of unequal lengths: the proximal or upper fragment which is very short contains the head, neck, trochanters and a varying length of shaft up to 2 inches. It is strongly flexed and abducted by attached muscles (Figs. 21 and 22). The distal fragment consists of the remainder of the femur pulled on by all the strong thigh muscles including the quadriceps extensor. The proximal fragment has varying displacement depending on the type of fracture, the cause—direct or

46535

indirect violence—and the pull of the glutei, ilio-psoas and pelvic muscles.

Treatment of Subtrochanteric Fractures.—The best method of treatment is continuous suspension traction with the Hodgen or

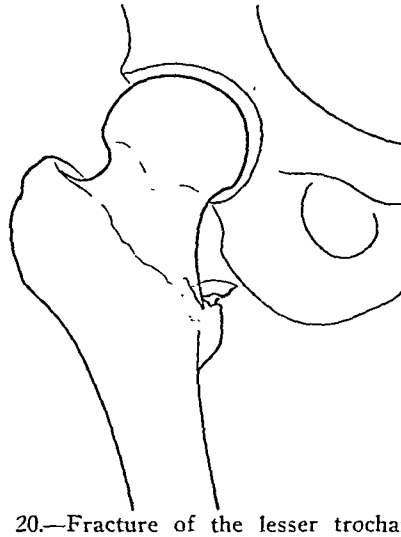

Fig. 20.—Fracture of the lesser trochanter.

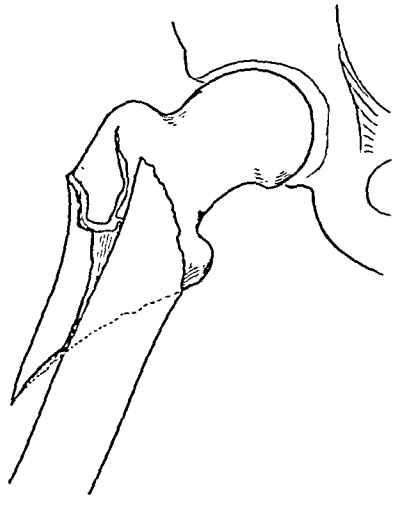

Fig. 21.—Spiral subtrochanteric fracture. Shaft fragment drawn in and up; trochanter rotated outward.

Thomas splint bent at the knee. The large fragment is swung out and up to meet the prolonged axis of the short upper fragment, and at the same time strong traction in that axis must be made to pull the end of the lower fragment into proper relation with the

upper. Because the long fragment tends to be adducted, it may be necessary to apply direct outward push against its upper end by means of a pad on a threaded bar attached to the side of the main splint. Lateral traction by adhesive is often used. All these methods may fail to give complete reduction. Thomas splints with attachment for knee movement are very useful.

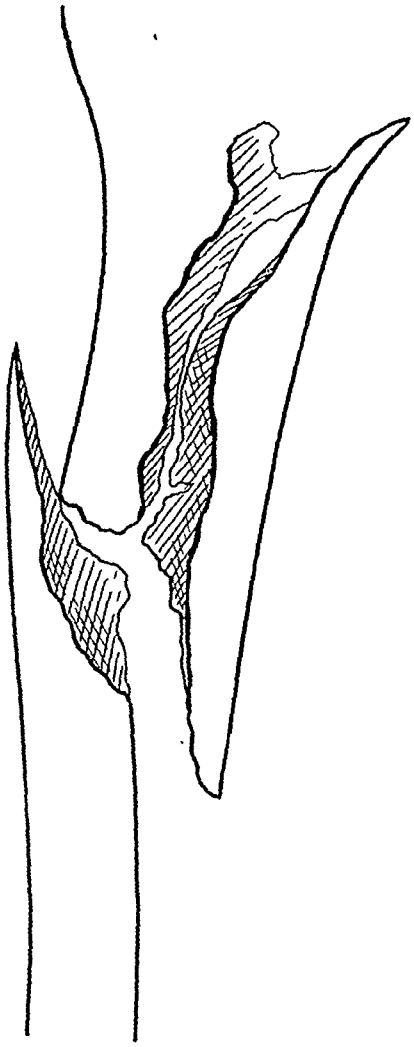

Fig. 22.—Subtrochanteric fracture with triangular fragment. A reduction of this type is difficult to obtain and hold. Extension and abduction of the lower fragment is indicated.

Operation for Subtrochanteric Fracture.—Should reduction fail after six or seven days' effort, as shown by roentgenographic control, operation is indicated. An operative reduction may be difficult, and it may be even more difficult to maintain the reduction during the applica-

tion of an internal splint. The upper fragment is so short that a metal or other plate cannot be attached. When there are spiral fractures, a band or an ivory screw may maintain the reduction. Intramedullary splints do not hold well (Fig. 23). When the deformity tends strongly to reproduce itself, the muscular insertions into the greater trochanter may be loosened by a sharp chisel, or the tendons may be severed so that the upper fragment does not tend to rotate outward so strongly. Reduction may then be accomplished easily.

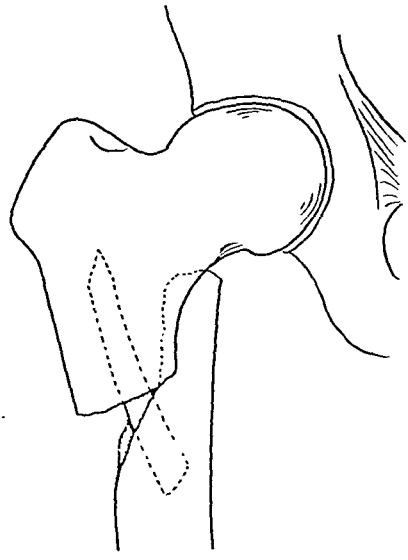

Fig. 23.—Attempted reduction of subtrochanteric fracture by an intramedullary bone peg according to Hey Groves method (*The Journal A. M. A.*, Sept. 6, 1919, p. 742). Little reduction obtained anatomically. The peg was too short and the lower fragment was not sufficiently extended and abducted. A fair functional result followed this repair.

FRACTURES OF THE SHAFT OF THE FEMUR

These occur in any part of the diaphysis, the limits being from just below the lesser trochanter proximally to a plane just above the condyles distally. There are the usual types of transverse or oblique fractures caused by direct violence, resulting frequently in comminution or the freeing of a triangular shaped piece of bone, and the spiral fracture caused by the twists or indirect violence (Figs. 24 and 25). In children, incomplete fractures involving only part of the cortex, and green stick fractures may be encountered. The commonest site at all ages is the middle third of the diaphysis. Treatment aims to restore length by approximating the ends of the fragments, and

to maintain a normal limb axis in both a horizontal and longitudinal plane. Every effort is made to bring the limb's long axis into the proper line for weight-bearing, a straight line from anterior iliac spine through the middle of the patella and on to the second toe. The horizontal axial relation of fragments must also be normal. When

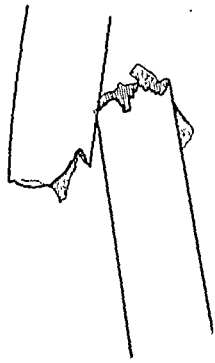

Fig. 24.—Transverse shaft fracture. Very difficult to reduce for end-to-end apposition and axial alinement.

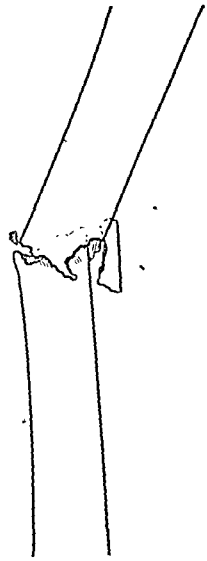

Fig. 25.—Transverse shaft fracture with interlocked fragments—not difficult to reduce.

these axes are not restored, the patient later develops static troubles in the neighboring joints, especially in the knee, and axial rotation may bring on foot troubles when walking is undertaken. Secondary axial deviations from too early weight-bearing on soft callus may cause these troubles.

Shortening is a result of shaft fracture that is most difficult to overcome. In transverse fracture, it sometimes becomes impossible by manipulation and extension methods to get the ends into contact—shortening as such may be overcome. Consequently, oblique and even long spiral fractures may offer a better prognosis, for reduction may be more easily accomplished and the length of the extremity more nearly restored. If the patient is placed on a fracture table an exact end-to-end contact is seldom obtained, even when considerable traction is applied. In oblique and spiral fractures also after the application of body casts following fracture table reduction, the spastic thigh muscles tend to cause a renewal of the displacement no matter how perfect it may have been as shown by roentgenogram at the time of reduction. The position of a shaft fracture, viewed by roentgenogram shortly after reduction and which may seem satisfactory, very frequently shows the original displacement when examined by the roentgen ray ten days later. When the fragment ends of a transverse fracture interlock by their serrated edges, a bowing is liable to develop later from muscle action within a heavy cast. Oblique and spiral fractures simply tend to slip back into the old displacement. It is practically impossible to maintain any real extension in the longitudinal axis of the leg by means of a plaster-of-Paris body cast.

With no hesitation, therefore, I can advise that there is no treatment comparable to continuous traction, best continuous suspension traction. The use of plaster casts for fractures of the shaft, except in instances of children or adults when there is green stick or incomplete fracture and little displacement, should be discarded. The best results in fractures of the shaft in children are obtained by suspension traction treatment. This I have demonstrated in a year's work on sixty-seven shaft fractures which were studied from the standpoint of methods and results of treatment. The extension used was gauze applied with Sinclair's glue to the unshaven limb, attached to a Thomas splint (Figs. 26 and 27). The splint was slung in suspension traction. Children have little trouble with limitation of joint motion after splint traction. Below the age of 4 years, on account of the disproportionate weight of the leg and the body, vertical extension, as usually employed, is advised.

It is not true on the other hand that continuous traction results in an anatomic reduction in all cases, but it assures the restoration of the weight-bearing axis of the leg, an insignificant shortening and a result approaching the normal. Depending on the site of the fracture and the displacement, we can use straight-in-a-line exten-

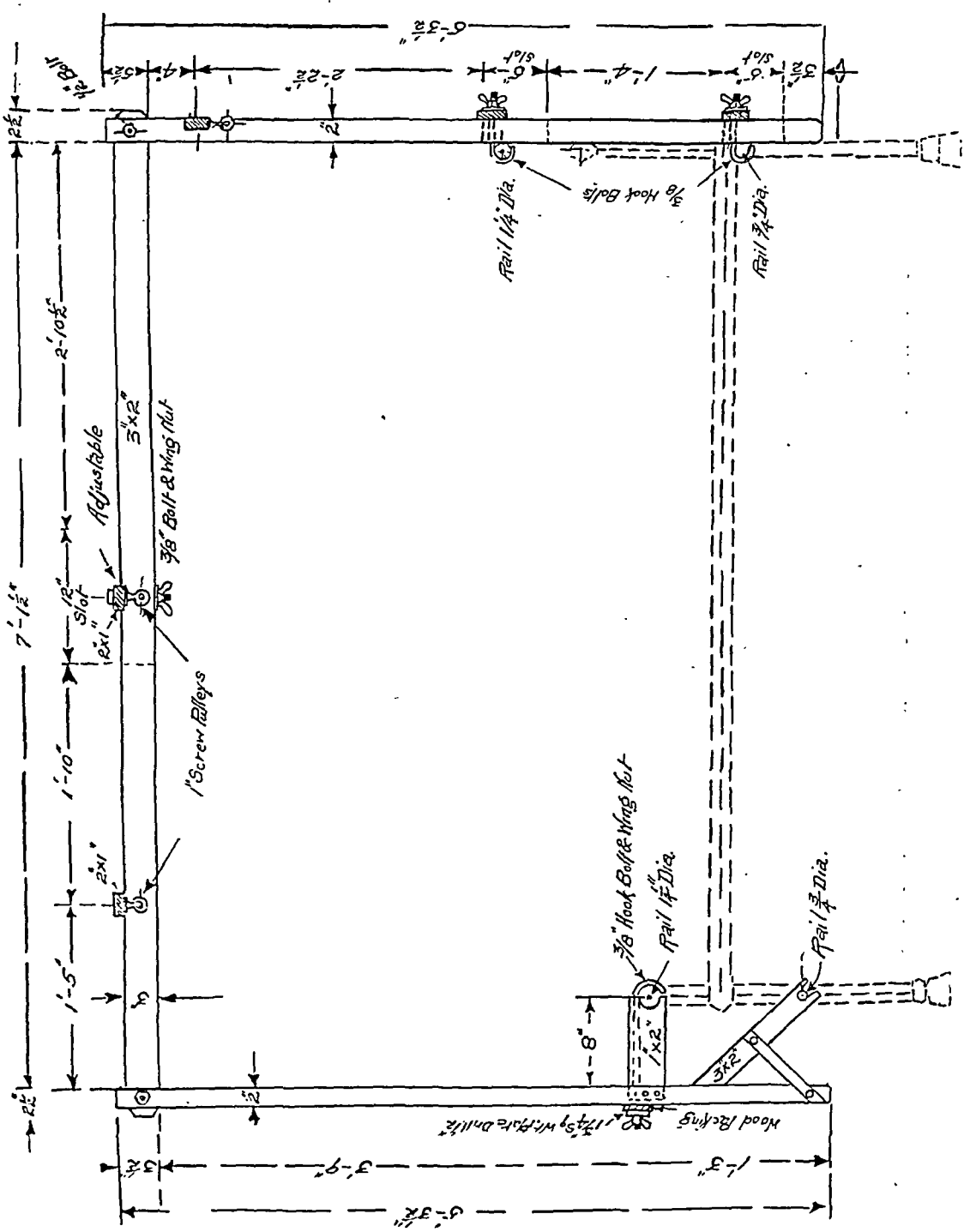

Fig. 26.—Side elevation of Balkan frame designed to fit standard 6 foot, 6 inch cot, in the construction of which four 7 pound sand bags and 12 yards of blind cord are required. Scale, 1 inch equals 1 foot.

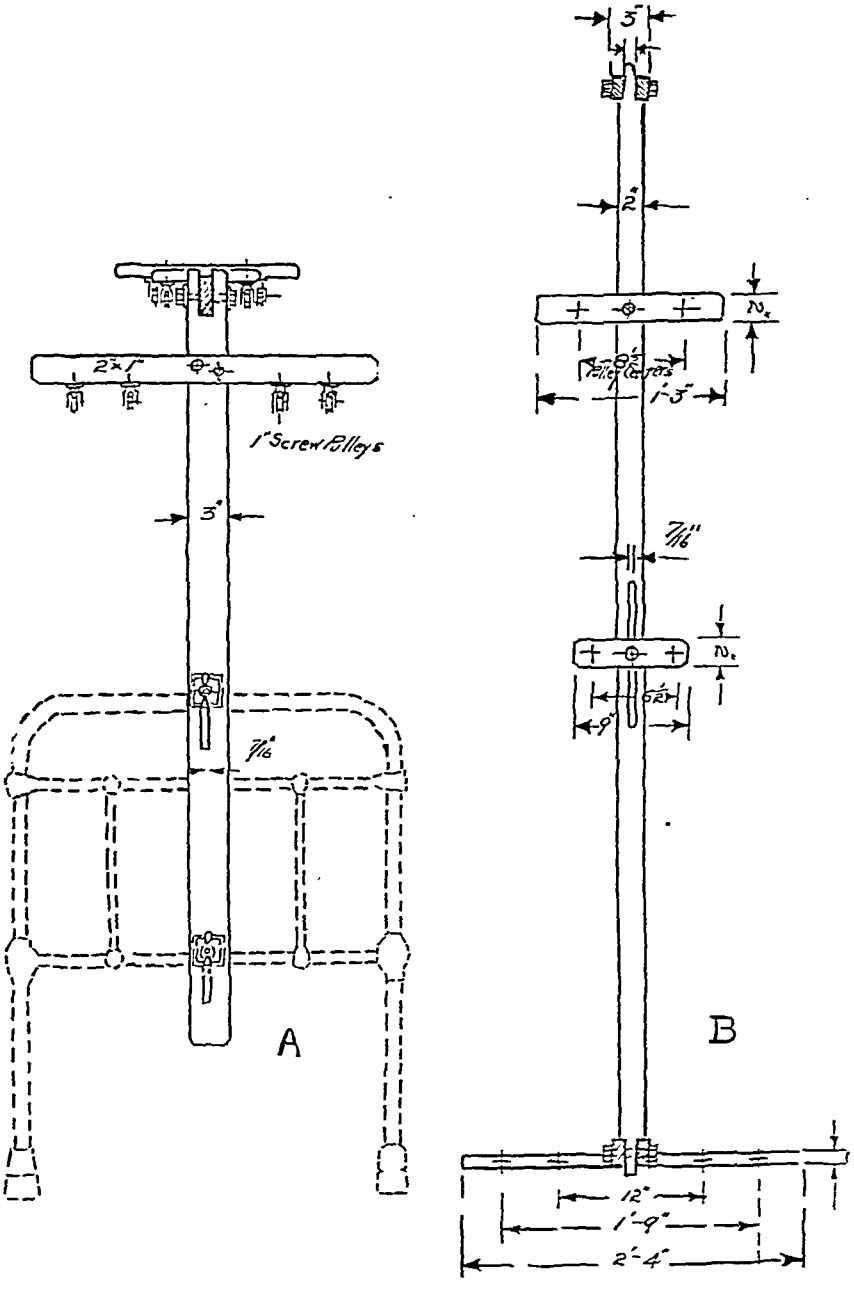

Fig. 27.—*A*, end view of Balkan frame; *B*, overhead frame.

sion or the splint can be bent to give semiflexion. Suspension traction is the best method of all as it allows these variations and furnishes one apparatus for the care of all shaft fractures. The rule already expressed concerning traction must be referred to (Fig. 28). Because the extension acts on the lower fragment and does not modify the axial direction of the upper fragment, it is necessary to bring

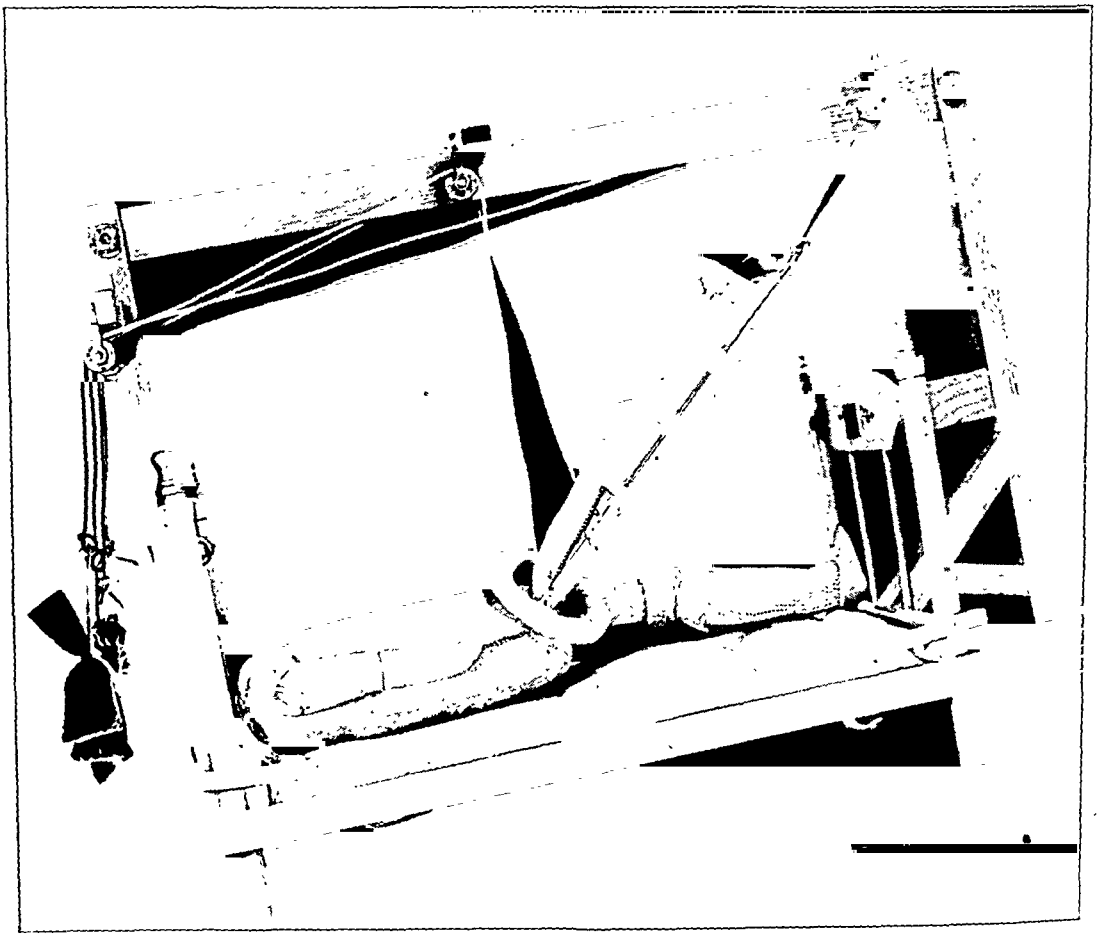

Fig. 28.—Model frame attached to doll's bed, the foot of which is elevated. The weights at the head of the bed are out of the way. The frame is compact and does not touch the floor, leaving the bed free to be moved about if desired.

the mobile lower fragment, which can be easily controlled, into line with the upper fragment.

Suspension traction of the limb in either a Hodgen or Thomas splint, the very best method of obtaining continuous traction, has not been in wide use. Sporadic attempts to revive the use of the Hodgen splint have been made and yet the method has not been widely adopted. This I believe

has been because the average American surgeon is not mechanically inclined. He favors plaster-of-Paris casts or some splint application which is put on once and taken off once before the patient is discharged. Any extension apparatus which involves daily attention and adjustment is too irksome to use. In rural districts, with the patient in his own home, a suspension traction method was deemed impractical because the surgeon could not see the patient often enough (Fig. 29). Among hospital patients, too much time was necessary for the attention required to adjust the splints; the nursing staff did not care to have wards

Fig. 29.—Overhead frames in actual operation. The nearest patient is sitting up to watch proceedings, without affecting the traction on his leg.

and beds disfigured by strange wooden frames. However, a certain proportion of active American physicians had an opportunity during the war to study the methods of suspension traction used by the French and English; this nucleus may help spread the use of the system (Fig. 30).

It is really a blow to American surgery that the idea of suspension traction so highly perfected by Hodgen should have fallen into the discard until revived by foreigners in the Balkan war and later in the World War. We now learn from them its great advantages and we wit-

ness its acceptance by the highest authorities as *the* means of treatment for shaft fractures. Too much is written at this time in the American literature about the use in foreign lands of the Thomas or other leg

Fig. 30.—Suspension traction for an adult. The splint is tied to the post, the extension on the leg is tied to the splint, so that the traction comes from the adult's body-weight.

splint for suspension traction of the thigh. If the writers would consult our own literature and would give credit to the Hodgen splint, America might come into some of the credit due the real inventor (Fig. 31).

MASSAGE AND ELECTRICAL STIMULATION

No résumé of the present treatment of femoral fractures can be complete unless attention is drawn to the extreme negligence shown by American surgeons in the way of providing accessory massage and electrical stimulation of muscles. These two adjuvants must, when possible, be applied during the course of repair. When the limb is enveloped in a plaster cast, they cannot be employed, another

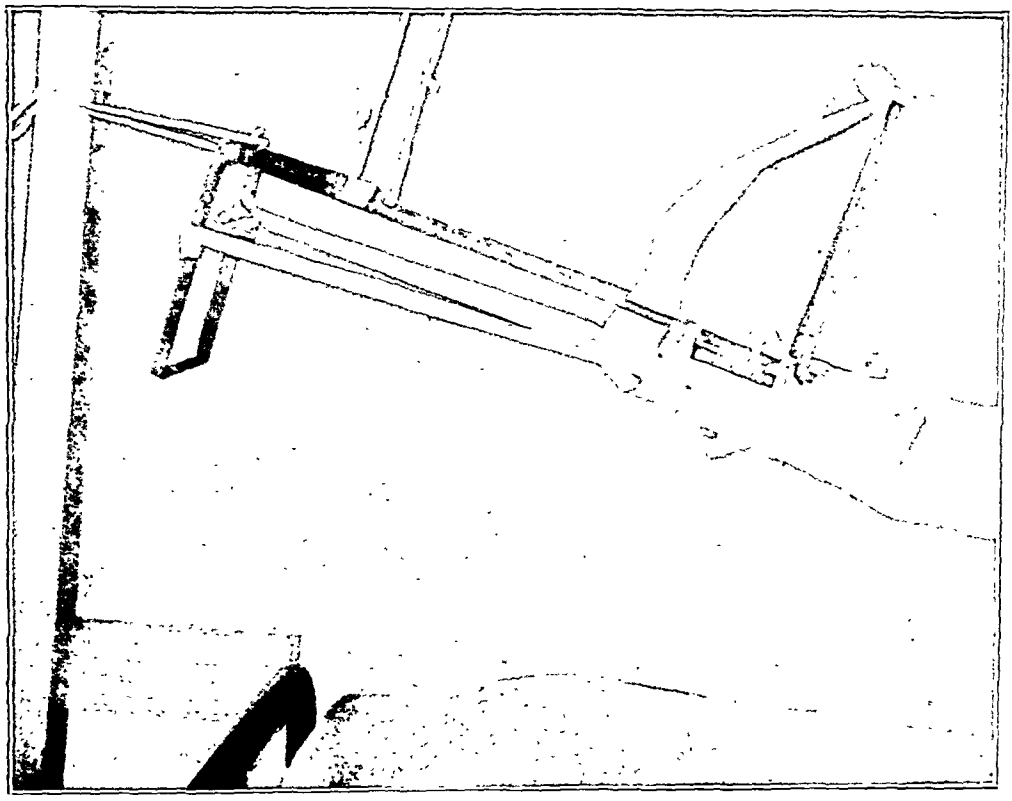

Fig. 31.—The foot is held up by gauze and glue, so that foot-drop cannot occur.

argument in favor of open dressing in suspension traction. The daily massage and galvanic stimulation of thigh muscles in fracture of the femur, whether open or closed, operated on or not, should be as much a part of routine ward work as making the patient's bed. It is rather disheartening to see the great amount of care bestowed on patients about to be operated on in hospitals as compared to the trouble taken in caring for fractured thighs. For the operative patient, all the resources of the hospital are called into play: special anesthetist, a

large operating room force, the surgeon and his assistants, everything being subordinated to the operation, and later much attention given to the postoperative care. The mortality among operative patients is no higher than among those suffering from fractures of the femur. The average patient after appendectomy is up and walking in eight or ten days—the average patient with a fracture of the femur has months of

Fig. 32.—Portable roentgen-ray machine, the operator making a bedside exposure without interfering with the suspension traction.

waiting before he can walk and then must often carry through life distinct evidence of his mishap. The relative economic loss of two such conditions cannot be compared.

As a result of massage and electrical treatment during healing of the bone, when the patient's splint is removed, the thigh and calf muscles are found prepared to function. There is no atrophy of disuse,

no waiting for shrunken thighs to regain size and power, and there is more rapid convalescence, free from fear of falls on account of loss of muscular power. Ambulatory calipers supplement this shortening of disability and insure a stability of the callus while reduction is maintained.

Fractures of the femur are very grave injuries; the supplies needed for caring for these patients, including frames, splints, extensions and dressings, should be as liberally and punctually supplied as those for laparotomy. The facilities for roentgenographic work for bedside diagnosis should be found in every hospital in which these fractures are treated (Fig. 32).

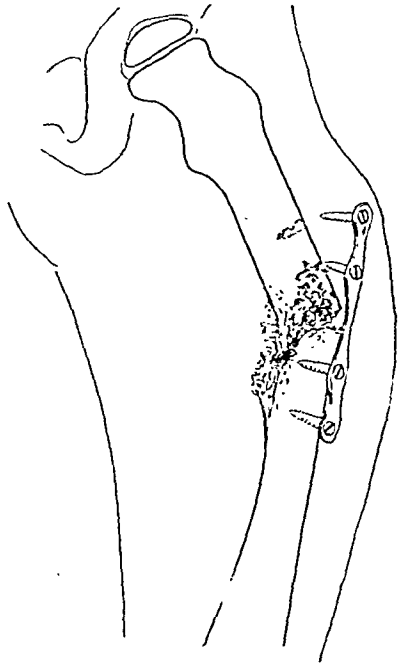

Fig. 33.—Shaft fracture in a child treated by Lane plate which has pulled out because of insufficient external splintage and too early weight-bearing.

AFTER-TREATMENT

When the callus has formed and can be felt to be firm by the examining hand (in children after three or four weeks; in adults after eight or ten weeks), the leg is lowered and kept loosely bound in a Thomas splint. The patient remains in bed and the splint protects the soft callus. After another week, a walking caliper having been made in the interim, the patient is fitted with a caliper and allowed to stand with crutches. The patient soon begins to walk, but the wise surgeon will see that the walking caliper fits perfectly and is worn for

from four to six months, depending on the type of fracture and the patient's bony reaction. With that security, one knows there will be no disappointments resulting from secondary deformities and shortening (Figs. 33, 34, 35 and 36).

Nail and Caliper Extension in Suspension Traction.—When ordinary traction fails, on account of damaged skin or slipping adhesive or glue, calipers or nail extension can be substituted. Should these fail to bring apial correction and full lengthening, as so frequently happens when the treatment is delayed too long, open operation offers a chance for anatomic reposition. By persistence and attention to

Fig. 34.—A healed gunshot fracture of the femur treated by suspension traction, showing the length obtained.

details, with inspection of leg, splints, ropes, pulleys and weights twice a day, the percentage of patients requiring nail or caliper extension will not rise over 3. We prefer the nail extension through the femoral condyles, and we employ steel drill rod sharpened at one end like a meat skewer, driven rapidly through the bone at the correct right-angled axis under the restrictions laid down by Steinmann. The nail will not slip as the caliper is inclined to, nor can the patient pull it out. The newer calipers like Schiassi's (Fig. 37) hold quite firmly; but any caliper is objectionable, inasmuch as there is some movement of the points within the skin wounds. This movement leads to a little

irritation and to infection which may not be serious, but which adds to the patient's troubles. The nail, on the other hand, does not move; it holds the lower fragment rigidly and permits a nice correction of the deformity. The nail also is cheap. We have had no infections from nails. In adults the nail treatment of femoral fracture must sometimes be used through the os calcis; in children this cannot be done on account of the slow development of this bone. A child up to 12 years of age has very little bone in the os calcis.

Portable Roentgen-Ray Control.—Regardless of the method used to obtain the traction in this suspension treatment, the operator must not trust alone to his eye for complete correction of the deformities. Roentgenographic controls by means of the portable roentgen-ray tube are absolutely necessary. If the patient's limb is removed from traction, and he is carted to a roentgen-ray room for exposure, the true



Fig. 35.—After the fracture has healed, attention is first paid to moving the knee joint while the patient is still confined to bed. The first step is bending the joint over a pillow.

state of reduction as obtained in the traction is lost. Consequently, the plates must be made while the limb is under traction with the patient in bed. When fractures of the shaft of the femur occur, they should be given immediate treatment. If that treatment is suspension traction, the roentgenogram for control must be made in case of a child within forty-eight hours, in case of an adult within four days, so that measures may be taken to vary the weight used in traction, to bend the splint at the proper angle, or to make pressure against one side of the limb or the other to correct axial deviations. There is no other way to insure a maximum correction of length and axis. It may happen that too much weight has been employed and that the fragments are actually separated.

SURGICAL TREATMENT

There are many methods of procedure in open operations. Usually the patient lies on the fracture table with the feet bound to the supports, ready for immediate application of a plaster-of-Paris body cast after the operation is finished and while the anesthesia is still effective. The simplest method of open operation is replacement of the fractured ends to the normal axis after correction of overriding and the local pathologic condition. Lane plates of steel, Parham's steel bands and wire are

Fig. 36.—The second step to increase knee joint motion. The patient is his own masseur.

used to hold fragments in position. Ivory or bone plates, with screws of corresponding material are also used. Inlay and intramedullary bone and ivory pegs are used, every internal operation requiring external splinting subsequently, a fact sometimes overlooked by the surgeon. Bone splints may be autogenous, taken from the tibia, fibula, or the femur itself, near the site of fracture. They may also be exogenous, usually beef bone used in the intramedullary fixations when a simple mechanical connection is desired. Numerous modifications of inlay bone fixations are offered, some sliding in character, taken from the

operative field, some held by bone dowels cut from their own substance, others held by flanged edges made in the sawing. For these operations there is required a special electric outfit. One may well conclude that the best operation is the one which obtains, by the simplest technic, a satisfactory end-to-end approximation which will hold with the aid of external immobilization. The longer the exposure and the greater the local manipulation of bone ends and implanted fragments, the greater the possibility of infection.

A Lane plate should be employed only when the fracture cannot be reduced and maintained in reduction by other means. In children the indication for its use is found in neglected fractures

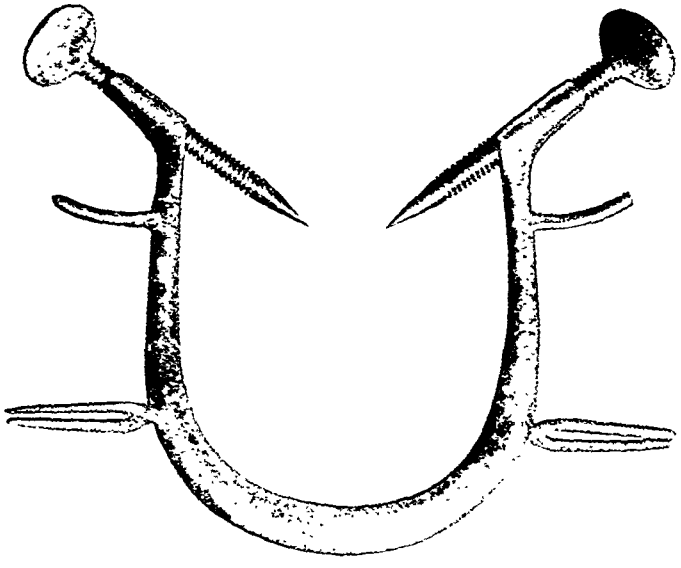

Fig. 37.—Schiassi's (Bologna) caliper for extension on the calcaneus. This can be modified for use above the malleoli or on the femur itself.

with overriding of from 2 to 3 inches, the fracture being of the transverse or sharp oblique type. When these fractures have not been submitted to suspension traction soon after their occurrence, the shortening soon passes beyond the possibility of being overcome by any traction, and callus forms so rapidly that within from two to three weeks a union is inaugurated. Therefore the ends must be freed, the callus removed, and the steadying plate is applied outside the periosteum. But we remove all such plates within six weeks in children and twelve weeks in adults; then we apply the walking caliper to protect the callus. The patient thus leaves the care of his surgeon with the plate removed: there are no complications. We believe that

the internal splint, especially one of nonabsorbable material such as a steel plate, is merely a means to an end. Its function is to hold the fragments in apposition until the bone wound is sealed by callus. Once that duty is performed, the metal plate should be removed; if that duty has not ended in a normal union in the customary period of time, its

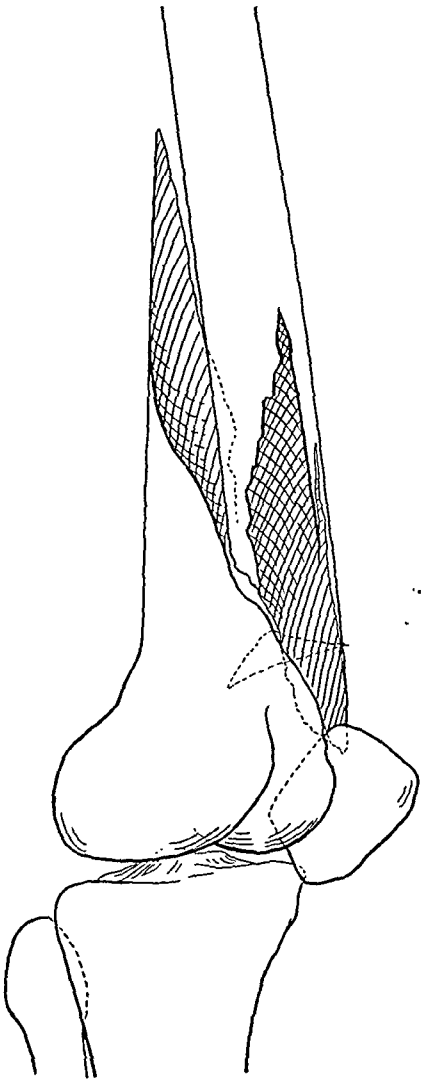

Fig. 38.—Spiral supracondylar fracture with penetration of the knee joint by the sharp upper fragment.

presence for any longer period is not likely to insure union. However, we may modify the time of removal a little in case callus development is slow, though the plate should be removed as promptly as possible.

SUPRACONDYLAR FRACTURES

These do not include separations of the lower epiphysis of the femur, nor true articular fractures. The supracondyloid site is that point of union between the diaphysis and its spreading portion that quickly widens into the massive condylar area. In children, fractures in this area are high up and may be green stick in character or even subperiosteal, but in adults we find the usual transverse or oblique and spiral types.

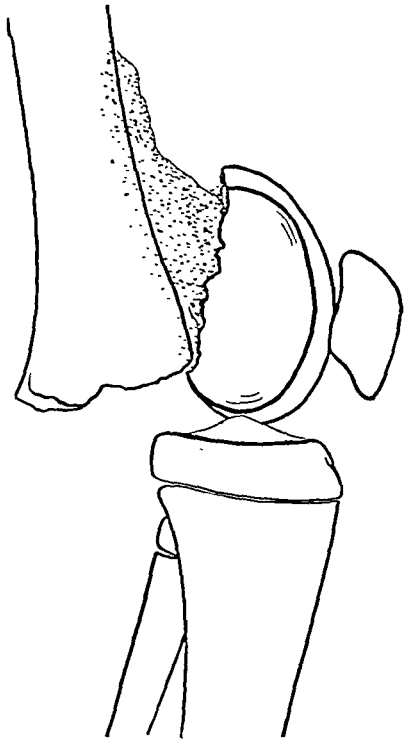

Fig. 39.—Unreduced bicondylar fracture which operation alone will benefit.

The primary displacement is usually due to a continuation of the force producing the fracture. The upper long fragment may be sharp, may penetrate muscles outward or inward or may be forced downward, lying just beneath the skin, or may penetrate the subcrural pouch of the knee joint to lie in contact with the patella (Fig. 38). The lower fragment is usually drawn backward and downward by the gastrocnemii. Injury of nerves and blood vessels may demand immediate treatment. A large hematoma should excite suspicion of vascular damage, and exploration need not be feared. Very early gangrene may call for amputation; but it is best delayed if possible for a line of demarcation.

Old Cases of Supracondylar Fracture.—Should a complete supracondylar fracture heal with shortening, vicious deformity and large callus, operation promises a functional result. Osteophytic outgrowths may greatly restrict knee joint motion or interfere with the vascular and nerve supply of the leg, and it is also common to find that there is restricted joint motion after the hemarthrosis which accompanies the fracture. The greatest part of the partial ankylosis of the knee probably comes from fibrous changes in the periarticular structures, less frequently from intra-articular fibrosis.

Treatment of Supracondylar Fracture.—The treatment of supracondylar fracture must be prompt (Fig. 39). When incomplete, or green stick, or only slightly displaced, extension on a fracture table with pressure of the fragments back into line, followed by a molded plaster

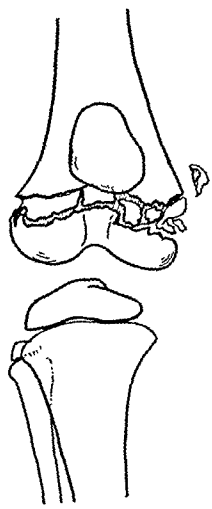

Fig. 40.—Epiphyseal separation with little displacement.

splint for four weeks, will give good results. It may be necessary to put the leg in flexion. If the hemarthrosis is large, the joint can be aspirated, but not until active hemorrhage has ceased.

When there is real displacement of fragments, extension manually or on a fracture table may assist in an easy reduction when pressure is made on the lower fragment. One must take pains not to injure the popliteal vessels. It is too frequently discovered, however, that after a reduction of this kind—especially in oblique and spiral fractures—the fragments immediately slip out of place, once the traction is released. Consequently, continuous traction must often be resorted to. The best position is with the thigh at right angles to the pelvis and the leg at right angles to the thigh, to relax the gastrocnemii. The extension is applied to the leg and the thigh, and the body acting as

a counter weight insures reduction. Nail or caliper extension applied to the lower fragment has a real use in these fractures. We can use here the double inclined plane; but we must be sure there is sufficient traction on the leg. If reduction does not follow within five days, open operation should be undertaken. When the thigh is opened (as it would be at first for all nervous or vascular lesions) the faces of

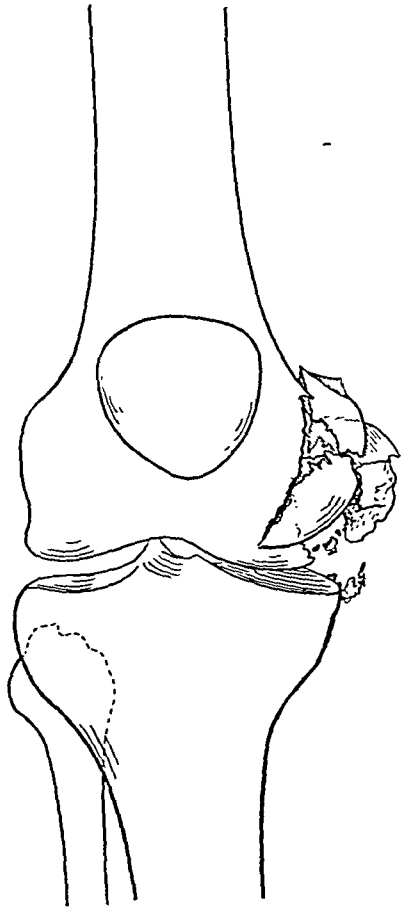

Fig. 41.—Fracture of internal condyle from direct violence.

the fragments may hold when reduction is accomplished. If the fracture is oblique or spiral, it may be held by a cerclage of wire, a Parham's band or an ivory or bone screw. The leg is held in flexion in a molded plaster-of-Paris splint. After three weeks, passive knee motion must be cautiously begun.

Separation of the Lower Epiphysis.—Separation of the lower epiphysis may occur in any direction, forward, backward, inward or outward. The ligaments of the knee joint usually remain intact and the distal

fragment retains its normal relationship to the tibia. In these accidents, vasculonervous complications must be searched for; also the stretching or tearing of the skin must be considered. In the treatment an examination for vascular and nervous lesions must first be made. When such are found, immediate operation is indicated (Fig. 40).

Treatment of Epiphyseal Separations.—For incomplete separations of the epiphysis, manual reduction must be performed at once under anesthesia. A plaster-of-Paris molded splint with the leg in extension will suffice for after-treatment. One great difficulty is the hematoma

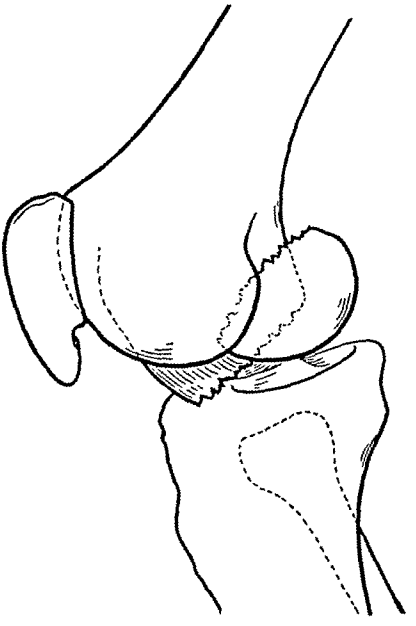

Fig. 42.—Condylar fracture with displacement.

about the fracture. It spreads from groin to heel. There may develop a tendency to leg flexion after the patient becomes ambulatory—best guarded against by having him wear a walking caliper for three months. Complete displacements in any direction must be immediately reduced. Under anesthesia, usually ether, the knee is flexed acutely, an assistant makes counter traction on the flexed thigh and the surgeon, by traction on the flexed leg, pulls the epiphysis into position. The reduction is usually recognized by the soft cartilaginous rub as the surfaces pass into position.

After reduction, the leg and thigh are immobilized in a plaster-of-Paris gutter which holds the heel against the buttock. Two weeks in that position are sufficient. This position has the advantage of relaxing the hamstrings, of using the tension of the quadriceps as a splint and of preventing the contracting epiphyseal surfaces from lateral dis-

placement, much as the position of flexion of the forearm is used in elbow fractures.

Operative Treatment of Epiphyseal Separation.—If manipulation with extension fails to reduce the fracture, an open operation is necessary. The epiphyseal surfaces should not be roughly handled, likewise the diaphysis should never be shortened for fear of interfering with subsequent growth. If the fracture has healed in malposition, all callus must be removed, the fragment ends must be freshened gently and then completely reduced.

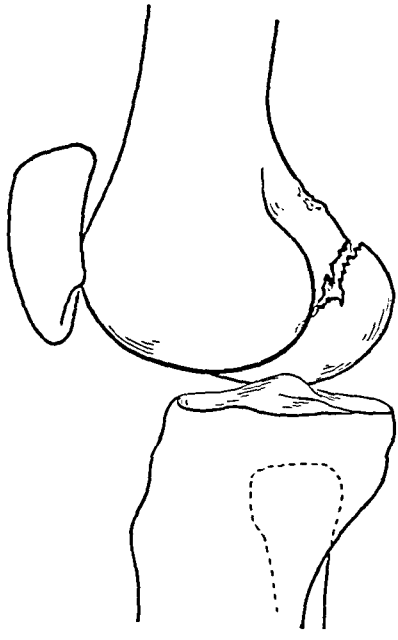

Fig. 43.—Replacement of condylar fracture shown in Figure 42 by means of traction and manipulation.

KNEE JOINT FRACTURES

Bicondylar fractures, T and Y fractures, are best treated by strong continuous extension in semiflexion. Manual pressure on the fragments can aid a reduction (Fig. 41). When this fails, an open operation must follow, best performed within eight days. These are true articular fractures and the operation is an arthrotomy. Two methods of approach are offered: The best is to saw the patella longitudinally, retract the extensor mass over the femoral condyles, bring them together, maintaining contact by an ivory screw or nail driven in laterally. The joint is then carefully and completely closed. Another method of approach is obtained by a large U-shaped incision extending just below the tibial tubercle, so that the insertion of the patellar tendon can be chiseled free and the joint exposed (Figs. 42 and 43).

FRACTURE RECORD

General Results:	GOOD	MODERATE	BAD
Anatomical			
Functional			

AMERICAN SURGICAL ASSOCIATION

1. Bone ..... 2. Site—Neck....Upper....Middle....Lower 3d....Condyle....Involving joint.....
.....

3. Name ..... 4. Sex—M.....F..... 5. Age..... 6. Occupation.....

7. Time fracture occurred—Date.....Hour..... 8. Hospital entered—Date.....Hour.....

9. First treatment—Date.....Hour..... 10. Cause of fracture.....

11. Kind of fracture—Oblique....Transverse....Spiral...Impacted....Comminuted.....Simple.....Compound....Greenstick....Subperiosteal .....

12. Was there serious injury to soft parts—Skin—Yes...No... Muscles—Yes....No... Vessels—Yes....No... Nerves—Yes....No...

13. Reduction: How many hours elapsed after accident before reduction? .....

14. Was anatomical reposition of fragments obtained? Yes....No.....

15. Anesthetic used: Yes....No.... Ether..... Gas.....

16. Fixation: Closed Method.

Postion: Hyperflexion.....full supination .....abduction.....

Splints .....

Plaster of Paris .....

Traction: Buck's....Thomas....Hodgen...Balkan frame...

Steinmann .....

Amount of weight used .....

17. Fixation: Open Method.

Was non-operative treatment tried first.....

How long after injury was operation performed.....

Was open reduction alone performed.....

What form of internal fixation used—Steel Plates....Wire....

Nails...Screws...Bone transplants or implants.....

Was it later necessary to remove fixation materials? Yes.....

No.... Date.....

18. Shortening at first examination.....cm. When all apparatus removed.....cm. Date.....

When discharged from hospital.....cm. Date..... At last observation.....cm. Date.....

19. X-Ray used—Yes...No...First finding—Date.....day before reduction; .....day after reduction

Plate No.	Fragments Displaced	Not	Slightly	Markedly	Over-riding	Rotation	Angulation
	Before reduction, date						
	After reduction, date						
	After union, date						

20. How long confined in bed..... How long in Hospital .....

21. How long did patient use crutches.....Cane .....

22. Results: Final examinations made ... weeks.. .. months after injury. Union. Bony.....Fibrous.....Non-union.....

23. Disability. Absent.. .Partial . Complete . Estimated by..... .. .Shortening.. .Angulation....Swelling of soft parts....Pain . Nerve involvement....Interference with joint function . Endurance .....

24. Mortality. Main cause of death... Age of patient. Shock. Hemorrhage....Other injuries....Sepsis....Exhaustion .....

25. Duration of absence from work .....weeks. . ...months . .....

26. Is patient fully able to take his former job .....

27. Present wage-earning capacity compared with former .....

28. Compensation under insurance, legislative act or legal process obtained—Yes. ..No..... Expected—Yes... ..No.....

Fig. 44.—Fracture record sheet compiled by the American Surgical Association.

Fracture of a Condyle.—For condylar fractures, the best treatment is continuous extension in a straight line aided by manual pressure. Some prefer semiflexion, but it has failed in our hands. When reduction cannot be obtained, an operation should be undertaken to restore the articular surface of the knee.

CONCLUSIONS

1. Because there is no accepted American standard of results after fracture of the femur, there is no American standard of treatment.

2. A large percentage of the fractured femurs are cared for by the first physician that sees them; specialists are not employed to direct treatment.

3. There is not sufficient effort put forth to use abduction or suspension traction methods, as obtained by the Hodgen or Thomas splint in fractures of the shaft, which may allow knee motion during the course of bone repair without disturbing the extension.

4. Portable roentgen-ray outfits should be furnished in all hospitals treating fractures of the femur, so that results in the course of treatment can be checked as frequently as desired.

5. There have been too many operations performed on fractured femurs by inexperienced operators, and without proper indication.

6. Very little attention is given to massage and electrical stimulation of muscles during bone repair and still less is given to after-treatment, so that many patients are permitted to bear weight on soft callus. Disability results. Walking calipers are little used.

7. The remedies suggested are:

(a) Every patient with fracture of the femur should be directed to a hospital for roentgen-ray examination, correct treatment by any of the accepted methods, and after-treatment when cured. This includes fitting the patient with a walking caliper as soon as he is ambulatory or on his discharge from the hospital.

(b) Because fracture tables offer good means of securing reduction and an easy method of external splinting by plaster of Paris, every hospital receiving cases of fracture of the femur should possess a fracture or orthopedic table. Careful records should be kept in accordance with a fracture record sheet (Fig. 44) such as has been compiled by the American Surgical Association, so that a large number of average results can be grouped, that treatment looking toward the ideal may be worked out.

THE ASSOCIATION OF HEPATITIS WITH EXPERIMENTAL CHOLECYSTITIS AND ITS BEARING ON THE PATHOGENESIS OF CHOLECYSTITIS IN THE HUMAN *

M. G. PETERMAN, M.D.; WALTER S. PRIEST, JR., M.D.,
AND
EVARTS A. GRAHAM, M.D.
ST. LOUIS

A review of the literature on infections of the biliary tract reveals the fact that there is a wide difference of opinion as regards both the frequency and the nature of an hepatic involvement in association with the relatively simple and more common types of cholecystitis. Such conditions as liver abscess and "obstructive biliary cirrhosis" in association with infections of the biliary tract have long been known. But the changes in the liver which occur in connection with the relatively simple types of cholecystitis which are so commonly encountered at operation seem not to have been investigated until the study made by one of us (Graham), the results of which were published in 1918.[1] In general, the only evidence of hepatic involvement which has been considered has been an increase in the size of the liver. Kehr [2] quotes Langenbach as saying that an enlargement of the liver is present only with an obstruction of the common duct. Kehr himself considers that the liver may be increased in size in from 15 to 20 per cent. of cases of cholecystitis, namely, in those with cholangitis. There is a more general agreement, however, about the involvement of the liver in cases in which calculi are present, in other words, in cases of long-standing inflammation of the biliary tract. Thus Grube and Graff [3] state that not uncommonly an interstitial hepatitis which may advance to cirrhosis is found associated with gallstones. Naunyn [4] quotes Charcot as being the first to call attention to the constancy of an enlargement of the liver in association with gallstones, and he considers that such an hyper-

---

* From the Department of Surgery, Washington University Medical School, St. Louis.

1. Graham, E. A.: Hepatitis: A Constant Accompaniment of Cholecystitis, Surg., Gynec. & Obst. **26**:521 (May) 1918.

2. Kehr: Chirurgie der Gallenwege, in Bruns: Neue Deutsche Chirurgie, 1913, p. 303.

3. Grube and Graff: Die Gallensteinkrankheit und ihre Behandlung, Jena, Gustav Fischer, 1912.

4. Naunyn: Klinik der Cholelithiasis, Leipzig, Vogel, 1892.

trophy is seldom absent during or shortly following an attack of gallstone colic. He considers the enlargement, under such circumstances. to be not exclusively due to a biliary obstruction, but also to an infective cholangitis. In 1888, Riedel [5] described the tongue-shaped extension of the right lobe of the liver now commonly known as "Riedel's lobe." He regarded this process as a result of disease of the biliary tract, and he asserted that he had found the liver involved in twenty-four out of forty-two cases of cholelithiasis. Quincke [6] remarks that in cases of cholelithiasis the liver is, as a rule, distinctly enlarged, due perhaps to a stasis of bile, or, in the case of women, to the effects of lacing. Rolleston [7] mentions an enlargement of the liver which may occur in association with cholecystitis if the inflammation has spread to the ducts and so into the organ. But evidently he does not consider this possibility as of very frequent occurrence.

It is the purpose of the present article to call attention to the great frequency of the involvement of the liver in different types of biliary tract infection and to present evidence in favor of the view that cholecystitis is probably often due to an infection by way of the lymphatics of the liver.

In a previous article by one of us (Graham),[1] a report was made of a study of the liver in various types of biliary tract disease, based on the examination of small pieces of liver which were removed during the course of operations on the gallbladder and bile ducts. In that article, it was stated that in thirty consecutive cases of biliary tract disease which had come to operation a distinct enlargement of the liver was present in twenty-six, or in 87 per cent. In the remaining four, there was definite gross evidence of a previous or existing pathologic change in the liver other than an enlargement. In cases of acute or subacute cholecystitis, there was constantly found in the liver microscopic evidence of inflammation. The hepatic inflammation was characterized by leukocytic infiltration of the interlobular, or periportal, sheaths; in the more severe types of inflammation, the infiltration involved also the parenchyma at the peripheries of the lobules and was associated with edema, slight necrosis and moderate fat infiltration. The inflammatory reaction was observed to be chiefly a pericholangitis. Although the intensity of the hepatic changes varied roughly in proportion to the intensity of the cholecystitis, nevertheless, definite inflam-

5. Riedel: Ueber den Zungenformigen Fortsatz des Leber lappens. Berl. klin. Wchnschr. **25**:577 and 622. 1888.

6. Quincke: Diseases of Liver, Pancreas and Suprarenal Glands, in Nothnagel: Encyclopedia of Practical Medicine. Philadelphia, W. B. Saunders Company, 1903, p. 381.

7. Rolleston, H. D.: Diseases of the Liver, Gall-Bladder and Bile-Ducts. London, MacMillan & Co., 1912, p. 611.

matory changes were found in the liver in cases of relatively mild cholecystitis (catarrhal) without calculi. In chronic cholecystitis, the liver often presented microscopically a picture practically identical with that of an early case of cirrhosis even when there had never been a stasis of bile. Cultures from both the liver tissue and from the bile in the gallbladder usually revealed the same organism.

It seems reasonable, therefore, to assume that an involvement of the liver is so frequently an accompaniment of cholecystitis that the

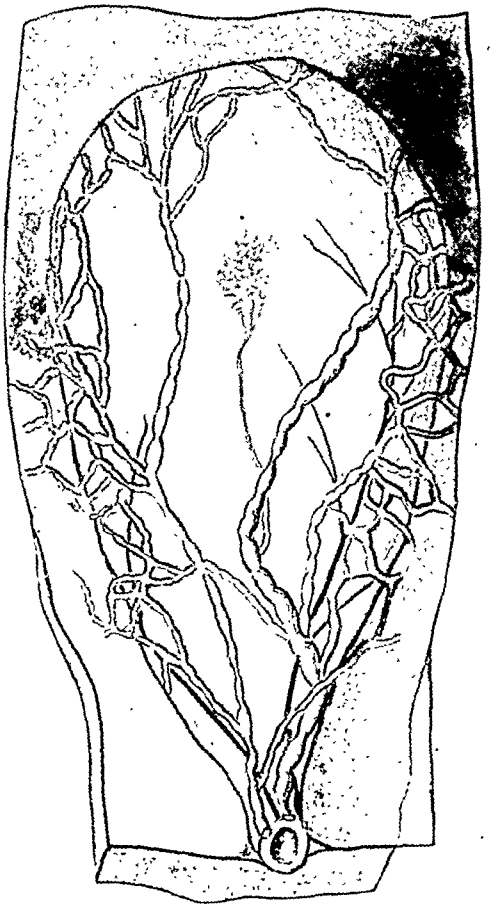

Fig. 1.—Distended lymphatic vessels of pig's gallbladder (taken from Sudler). This distribution is practically identical with that in man. The intimate communication between the lymphatics of the liver and gallbladder is well shown at the sides of the gallbladder.

association must be practically a constant one. The realization of this fact is important for several reasons: (1) because it may cause light to be thrown on the exact pathogenesis of infections of the biliary tract, which, if known, might serve both to prevent many cases and to settle disputed points in the treatment; (2) because it may prevent

many of the serious liver complications which seem to be largely a result of the neglect of early cases of cholecystitis, and (3) because it may lead to an increase of our knowledge of the whole subject of cirrhosis of the liver and various functional disturbances about which so little is known at present.

Present conceptions of the pathogenesis of infections of the gallbladder and bile tracts are based on three assumed possibilities: (1) descending infection from the liver by bacteria carried down in the bile, (2) ascending infections from the duodenum up the lumen of the common bile duct, and (3) hematogenous infections of the gallbladder and ducts.[8] Of these possibilities, it is only the last, the third, which takes into serious consideration the actual infection of the wall of the gallbladder, despite the fact that microscopic examinations of inflamed gallbladders demonstrate that inflammatory changes are present not merely in the mucosa but also in the deeper layers and that usually in gallbladders removed at operation, these changes are more pronounced in the deeper layers. The other two possibilities are concerned only with the entrance of organisms into the lumen of the gallbladder and do not explain their entrance into its walls. Obviously, the mere presence of pathogenic bacteria in the bile contained in a gallbladder does not constitute a cholecystitis; nor does it necessarily imply that a cholecystitis will occur through contact of the mucosa with these organisms. For example, according to Rolleston,[9] "in typhoid fever the bacilli are always present in the gallbladder but cholecystitis is comparatively infrequent." The essential requirement is that the wall of the gallbladder shall be infected since the gallbladder consists of nothing but a wall surrounding a cavity. Failure to take this simple fact into consideration has led to much confusion in the interpretation of experimental results on the pathogenesis of cholecystitis. Rosenow[10] has particularly emphasized the idea of the hematogenous infection of the wall of the gallbladder.

On the other hand, another source of infection, which is probably a frequent and an important one, is by way of the lymphatics from the liver. Strangely enough we have been unable to find in the literature any reference to the fact that this channel of infection has even been considered, although we have succeeded in collecting evidence

---

8. A fourth possibility of a spread of infection through the wall of the gallbladder from an inflamed contiguous organ has been mentioned; but obviously such an occurrence must be relatively rare.

9. Rolleston, H. D.: Diseases of the Liver, Gall-Bladder and Bile-Ducts. p. 608.

10. Rosenow, E. C.: The Etiology of Cholecystitis and Gallstones and Their Production by the Intravenous Injection of Bacteria. J. Infect. Dis. **19**:527 (Oct.) 1916.

which indicates that it must be a relatively frequent occurrence. Sudler,[11] in a careful study of the lymphatics of the gallbladder, has shown that there is a direct and intimate connection between the liver and gallbladder through lymphatics which come from the under surface of the liver and pass through the attachment of the gallbladder to the liver. The lymphatics of the gallbladder can be distended by injections into the portal vein. It is therefore easy to understand how organisms may spread through the lymphatics to the gallbladder wall from an

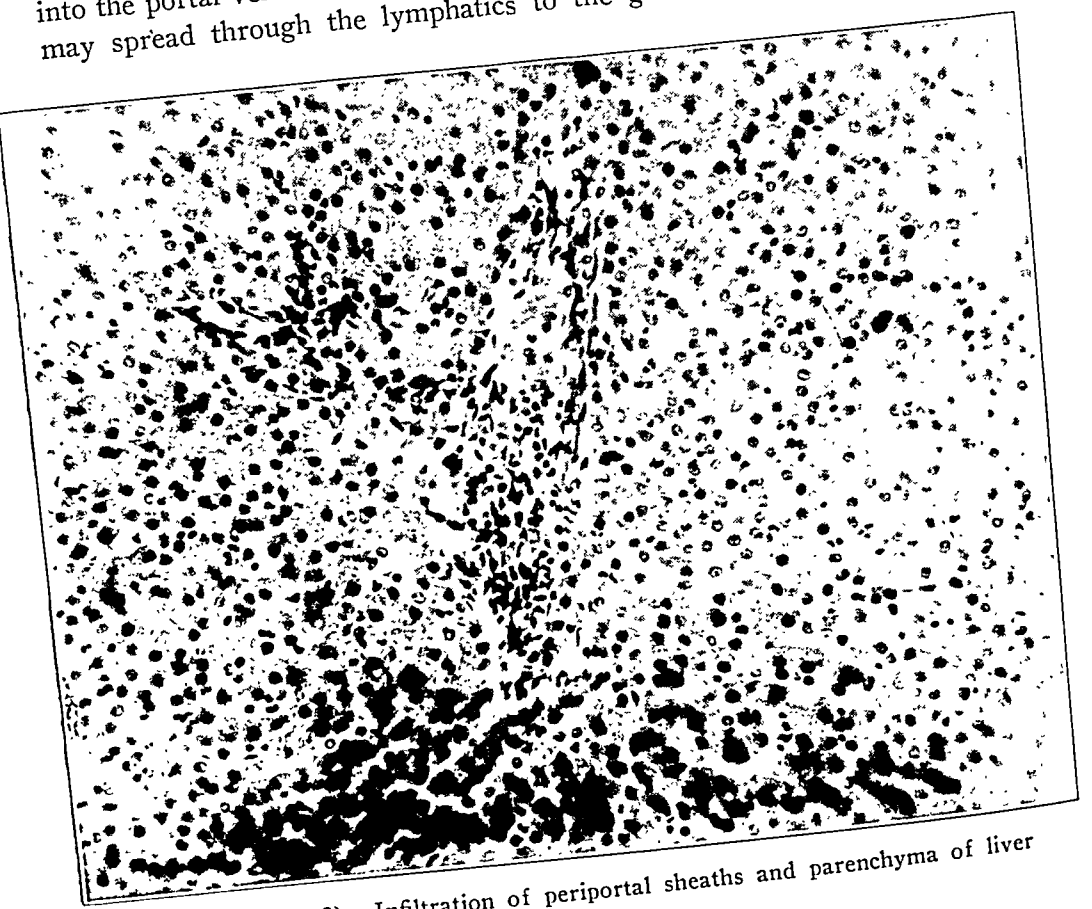

Fig. 2 (Dog 2).—Infiltration of periportal sheaths and parenchyma of liver with polymorphonuclears and round cells.

infection in the liver and thus set up a cholecystitis secondary to a hepatitis. In fact, it seems a much more probable mode of infection than the rather fanciful one of a surface infection of the mucosa of the gallbladder through contact with organisms, floating in the bile, which have been either washed down from the liver or have ascended from the duodenum against the current of the bile in the common and

11. Sudler: The Architecture of the Gall-Bladder, Bull. Johns Hopkins Hosp. **12**:126, 1901.

cystic ducts. In our experiments on dogs, we have found it practically impossible to produce cholecystitis merely by the introduction of organisms into the lumen of the normal gallbladder, even in thick suspensions. The additional factor of obstruction to the outflow of bile seems to be necessary to produce cholecystitis in this way. This also probably implies as a usual occurrence some degree of obstruction of the circulation of the gallbladder by pressure either from within or without. In this connection, the experiments of Chiarolanza [12] are of interest. After injections of typhoid bacilli both intravenously and subcutaneously in rabbits, he found that bacteria lodged in the papillary folds of the gallbladder beneath the mucosa in clumps which he interpreted as capillary emboli. In three animals in which the cystic duct was ligated before the injection, he found bacilli in the bile of the gallbladder. In six animals in which he ligated both the cystic and common ducts before the injection, he found bacilli in large numbers in the gallbladder bile. He concluded that cholecystitis is due to capillary embolism and not to infection from infected bile which is secreted. The livers frequently showed a more or less extensive interlobular leukocytic infiltration and often a marked increase of interlobular connective tissue, similar to what we have noted in the human liver in association with cholecystitis. In rabbits it is practically impossible to avoid the cystic artery in ligation of the cystic duct because of its small size, and Chiarolanza considered that in every case he had ligated the artery with the duct. It is hard, therefore, to understand his conception of the occurrence of capillary embolism in gallbladders the arterial supply of which was already occluded. It seems more probable that with both the artery and the duct ligated the organisms must have gained entrance to the gallbladder through the lymphatic connection with the liver, which has already been mentioned.

Of more practical interest are the questions of the frequency of liver involvement following a cholecystitis and the paths by which the infection is spread to the liver. The question of the advisability of the removal of an inflamed gallbladder is intimately related to the question of how frequently an infection of the liver may follow a cholecystitis. Because of the intimate lymphatic connection between the liver and gallbladder, it is easily conceivable that a vicious circle could be established with the liver on the one side and an infected gallbladder on the other, each being constantly reinfected from the other. Hence the desirability of ascertaining the frequency with which the liver is infected secondary to a cholecystitis is evident. Observations previ-

12. Chiarolanza: Experimentelle Untersuchungen über die Beziehungen der Typhusbazillen zu der Gallenblase und den Gallenwegen. Ztschr. f. Hyg. u. Infectionskrankh. **62**:12. 1909.

ously reported by one of us (Graham [1]), to which reference has already been made, indicate that the association of a hepatitis with a cholecystitis is nearly a constant one. But since in the clinical cases studied, the possibility existed of the hepatitis having been primary to the cholecystitis, it seemed desirable to submit the question to experimental study. Experiments accordingly were carried out which had as their object the study of the liver after the creation of a cholecystitis.

Fig. 3 (Dog 9).—Liver: interlobular leukocytic infiltration.

METHOD OF EXPERIMENTATION

In all, nineteen dogs were used. The following method was used as a routine. After noting the weight and rectal temperature, the animals were anesthetized with ether, and the abdomen was opened by means of an upper right rectus incision from 8 to 10 cm. long. A piece of liver was removed from the most accessible lobe to serve as a control for the later study of the liver after the production of the experimental cholecystitis, and the cut edges were sutured. Only those dogs are included in the series whose livers proved to be normal at the beginning. In some cases, stab cultures of the liver were taken at this time from as many different points as could be reached without

difficulty in order to test the sterility of the liver before the creation of the cholecystitis. In some of these instances, the surface of the liver through which the stab was made was seared in order to rule out possible contamination. Following this, the cystic duct was ligated. This included ligation of the cystic artery, vein and the lymphatic trunks which run along the cystic duct. In some cases, the duct and vessels were ligated twice and the structures divided between the ligatures. Before ligation, the gallbladder was almost completely emptied of bile. We then injected varying amounts (from 0.3 to 2.5 c.c.) of twenty-four hour broth cultures of pathogenic organisms (*B. coli* and *Streptococcus nonhemolyticus*) into the lumen of the gallbladder and closed the needle hole with a purse-string suture. It was found necessary to use a purse-string suture here to prevent leakage even after using the finest needle which could be employed. The abdomen was then closed in layers, and the dog was placed in the observation room. The temperature and general symptoms of each dog were followed daily. Whenever possible the dogs that died were immediately examined at necropsy. Several dogs were operated on a second time and some were killed and postmortem examination was promptly made. At necropsy sections of the gallbladder were taken in two places and of the liver in three places, namely, near the site of the gallbladder and from the extremes of the right and left lobes.

TABLE 1.—AGGLUTINATION RESULTS WITH INJECTION OF BACILLUS COLI

Strain	Homologous Serum	Normal Serum
Dog 10:		
Gallbladder	[illegible]	Positive agglutination, 1:20
Gallbladder	[illegible]	Positive agglutination, 1:20
Liver, right lobe	[illegible]	Positive agglutination, 1:20
Original strain injected	[illegible]	Positive agglutination, 1:20
Stock strain	[illegible]	Positive agglutination, 1:20
Stock strain	[illegible]	Positive agglutination, 1:20
Dog 11:		
Gallbladder	Positive agglutination, 1:160	Positive agglutination, 1:20
Liver near gallbladder	Positive agglutination, 1:160	Positive agglutination, 1:20
Liver, right lobe	Positive agglutination, 1:160	Positive agglutination, 1:20
Intestine	Positive agglutination, 1:40	Positive agglutination, 1:20
Original	Positive agglutination, 1:160	Positive agglutination, 1:20
Stock	Positive agglutination, 1:20	Positive agglutination, 1:20
Stock	Positive agglutination, 1:20	Positive agglutination, 1:20
Dog 13:		
Gallbladder	Positive agglutination, 1:640	Positive agglutination, 1:20
Liver, left lobe	Positive agglutination, 1:320	Positive agglutination, 1:20
Liver	1:320	Positive agglutination, 1:20
Intestine	1:20	Positive agglutination, 1:20
Intestine	1:40	Positive agglutination, 1:20
Original	1:640	Positive agglutination, 1:20
Stock	1:20	Positive agglutination, 1:20
Stock	1:20	Positive agglutination, 1:20

In order to establish the fact that the inflammatory changes in the liver secondary to an experimental cholecystitis were actually the result of the gallbladder infection, it was necessary to show that the same

organism was present in both the gallbladder and liver. For the determination of this point it was considered advisable to submit to agglutination tests the organisms recovered from the gallbladder and liver, respectively. It seemed particularly important to carry out these tests in connection with the colon bacillus, since as is well known, this organism may sometimes be found in the normal liver. In the streptococcus cases, however, this procedure was not undertaken because it was believed unlikely that a streptococcus would be found as an accidental invader of the liver. Accordingly, therefore, after taking cultures at

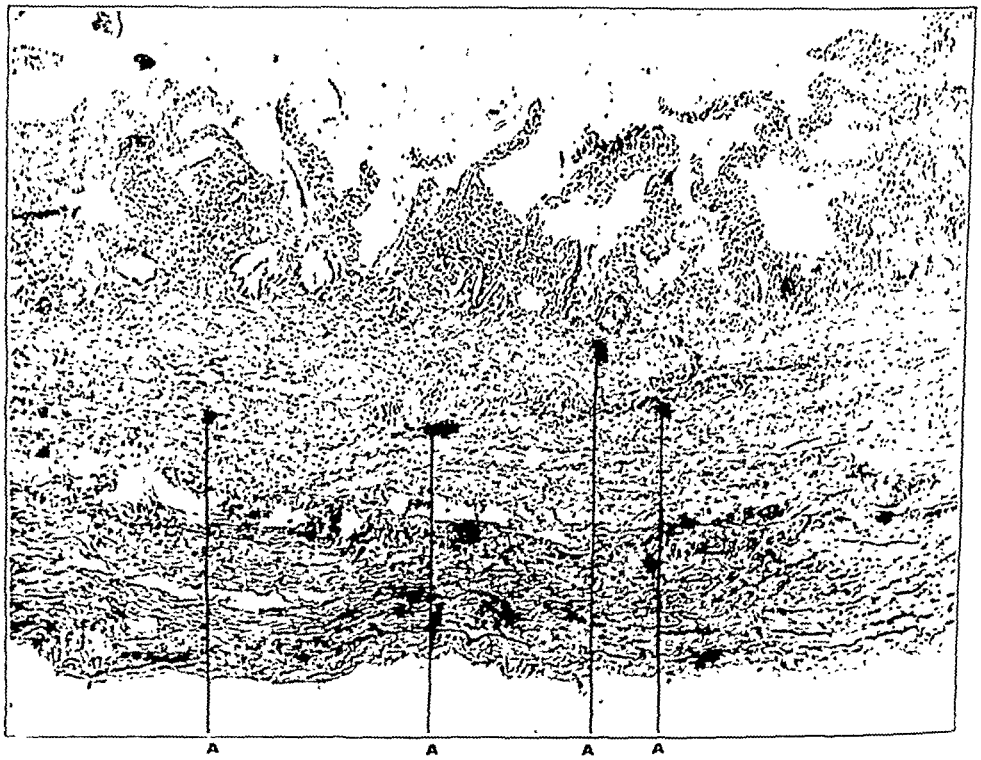

Fig. 4 (Dog 9).—Gallbladder, showing infiltration of leukocytes deep in the gallbladder wall. Each *A* indicates a clump of leukocytes.

necropsy from the gallbladder and from the liver in places corresponding to those from which sections were removed, a series of agglutination tests was run (Table 1) to prove the identity of the organisms recovered from the gallbladder and liver, respectively. In each of three cases it was proved by this method that the strains of *Bacillus coli* recovered from both gallbladder and liver were identical. As is shown in the table, the dog's serum agglutinated these two strains in much higher dilutions than other strains of colon bacilli taken from various sources including the intestine of the same dog. In most of the experiments, cultures were also made of the heart's blood. In isolating the various

strains used in making these agglutination tests, stabs were made at various parts of the liver and inoculated into melted nutrient agar which was then poured into plates. After incubation, colonies were picked and those showing morphology, staining and cultural characteristics of *B. coli* were cultivated in pure culture. Agglutination was carried out with uniform suspensions of eighteen to twenty-four hours' agar slant cultures washed off in physiologic sodium chlorid solution. The serum from the experimental dogs was obtained either just prior to killing them for pathologic study, or at the time of a secondary operation. All strains were agglutinated against serum from normal dogs as a control. Two strains were also obtained from stock laboratory cultures other than the one used in injecting the gallbladder and were used throughout the tests as a further control. These are designated as "stock" in the table. In two of the agglutination tests, strains were also obtained by isolating *Bacillus coli* from the intestine of the experimental animal. This was done to rule out the possibility that the strains recovered from the liver might be the same as those normally inhabiting the dog's intestinal canal. These strains are called "intestine." The failure of the homologous serum in high dilutions to agglutinate these strains, in addition to the other facts brought out, is, we believe, proof that the *Bacillus coli* isolated from the liver was the same as that injected into the gallbladder. The amounts of bacterial cultures injected in each experiment, the postoperative course, the necropsy findings and the histologic changes observed are given in detail in the protocols.

DISCUSSION

In all of these nineteen cases of experimental cholecystitis, inflammatory changes have been observed in the liver. These have consisted chiefly of a leukocytic infiltration around the bile ducts in the interlobular sheaths. The pathologic condition observed has been practically identical with that already noted by us in human cases of relatively acute infection; but the experiments were not continued long enough to observe any pronounced evidence of cirrhosis such as was seen in some of the chronic cases in human beings. The hepatitis in association with streptococcal cholecystitis was more severe than that which occurred in infections with *B. coli*. The fact that these changes are known not to have been present before the creation of the cholecystitis and that they have consistently followed it in each case makes apparent the probability that all cases of cholecystitis are accompanied by a hepatitis. This deduction agrees with the conclusion reached in a previous article by one of us (Graham) in which a report was made of a study of the liver based on an examination of small pieces of it removed at operations on the biliary tract. In our experiments recorded

here the cystic duct was ligated, and at the same time the large lymphatic trunks passing along that duct were obstructed by the ligature. The only paths, therefore, by which the infection could have spread to the liver were either the lymphatics or veins from the gallbladder which pass through the normal attachment of that organ to the under surface of the liver, or by way of a general blood stream infection back to the liver. Since in six of the



Fig. 5 (Dog 10).—Liver: moderate leukocytic infiltration of periportal space

cases, cultures from the heart's blood were sterile, it seems more probable that the infection spread directly to the under surface of the liver. The lymphatic connection here is well shown in Figure 1, taken from Sudler's article, and it would be easy to conceive of the extension of the infection into the liver by way of these lymphatics. Additional support to this view is found in the fact that the leukocytic infiltration is consistently more pronounced in portions of the liver near the site of the gallbladder than at more remote parts. This is seen, for example, in Figures 9 and 10. Since, on the other hand, the

veins in the attachment of the gallbladder to the liver drain into the portal vein (Sudler), one would expect that infection transported in this way would be nearly equally distributed throughout the liver. Moreover, the location of the inflammatory changes chiefly in the interlobular areas harmonizes with known facts about the location of the lymph vessels of the liver.[13] It would seem evident, therefore, that the abundant lymphatic connections between the liver and gallbladder already mentioned render the possibility of the frequent occurrence of a vicious circle between an inflamed gallbladder and an inflamed liver very great. In such circumstances, surgical intervention to break up the circle can be brought to bear only on the gallbladder; and, in fact, because of the well known ability of the liver to destroy bacteria, probably all that is necessary in most instances, is to remove the source of the infection, the gallbladder. In many respects, as, for example, in its shape and structure, the gallbladder resembles the appendix. Like the appendix, also, infections of its walls tend to become chronic, possibly because of its relatively slight vascularity and the ease with which its blood supply can be seriously impaired. Simple drainage of the gallbladder, therefore, cannot be expected to yield the same high percentages of permanent relief that its removal will accomplish, from the same standpoint that one would not expect to accomplish such good results with appendicostomy as with appendectomy. In this clinic, cholecystectomy is considered the operation of choice.[14]

SUMMARY

After the experimental production of cholecystitis in dogs, inflammatory changes have been constantly found in the liver. These changes have been of the same type as those previously described by one of us (Graham) as occurring constantly in the human liver in association with biliary tract infections, namely, a pericholangitis with marked leukocytic infiltration of the interlobular sheaths. The same organism can be isolated from both the liver and gallbladder.

Evidence is submitted that, owing to the free lymphatic communication between the liver and gallbladder, infection may pass easily from one organ to the other and a vicious circle be produced in this way.

Infections of the gallbladder apparently by way of the lymphatics from the liver are easily produced experimentally. In any considera-

13. Mall, F. P.: On the Origin of the Lymphatics in the Liver. Bull. Johns Hopkins Hosp. **12**:146. 1901.

14. The question of the rôle of drainage in assisting the liver to overcome its infection will be taken up in another article to be published soon.

tion of the pathogenesis of cholecystitis in the human, this lymphatic route must be regarded as important and probably frequent, although apparently it has heretofore received no attention.

The probability of a frequent occurrence of a vicious circle between an inflamed gallbladder and an inflamed liver would seem to afford a strong argument in favor of cholecystectomy as an operation of choice in cases of cholecystitis.

PROTOCOLS

Dog 1.—This experiment is the only one of the series in which the cystic duct was not ligated and in which a cholecystitis was produced without ligation of the duct. In several preliminary experiments it was found impossible to produce cholecystitis merely by the injection of bacteria into the lumen of the gallbladder if the cystic duct was not ligated. Two c.c. of *B. coli* culture was injected into the lumen and wall of the gallbladder. The dog did well except for slight elevation of temperature and poor appetite until the seventeenth day. It died on the twentieth day.

TABLE 2.—Condensation of Protocols

Dog	Organism Injected	Amount	Soiling	Days Lived	Postoperative Course†	Second Operation	Days Lived After Second Operation	Normal Liver Culture	Normal Liver Section	Peritonitis	Gross Changes	
											Gallbladder	Liver
1	B. coli	2.0	0	20	D	0	..	..	Neg.	0	Acute inflammation	None
2	B. coli	2.5	0	4	D	0	..	..	Neg.	+	Acute inflammation	Edema; congestion
3	B. coli	1.0	0	8	D	0	..	..	Neg.	0	Acute inflammation	Edema; friable
4	B. coli	2.0	0	13	D	0	..	..	Neg.	+	Empyema	Edema
5	B. coli	1.5	0	10	D	0	..	..	Neg.	0	No change	None
6	B. coli	1.0	0	41 K.	D	0	..	..	Neg.	0	Complete atrophy	Enlarged, edematous
7	B. coli	1.0	0	6	D	0	..	..	Neg.	+	Normal size and color	Enlarged, edematous
8	B. coli	0.5	0	2	D	0	..	..	Neg.	0	No change	Edema
9	B. coli	1.0	0	21 K.	D*	0	..	..	Neg.	0	No change	No change
10	B. coli	1.0	0	30	D*	+	1	..	Neg.	0	Acute inflammation	Enlarged
11	B. coli	1.0	0	8	D*	+	3	..	Neg.	0	Thickened walls	No change
12	B. coli	1.0	0	3	D	0	..	..	Neg.	+	Gangrenous	Enlarged, edematous
13	B. coli	0.75	+	6	D*	+	1	..	Neg.	+	Thick walls	Slightly enlarged
14	B. coli	0.1	0	20 hr.	D	0	..	..	Neg.	+	Gangrenous	Edematous
15	Strep.	0.5	0	20 K.	D	0	..	..	Neg.	0	Thick wall	Enlarged
16	Strep.	0.5	+	?	D	0	..	..	Neg.	+	Gangrenous	Slightly edematous
17	Strep.	0.3	+	2	D	0	..	Neg.	Neg.	+	Gangrenous	Enlarged
18	Strep.	0.3	0	2	D	0	..	Neg.	Neg.	+	Gangrenous	Enlarged
19	Strep.	0.3	0	6	D	0	..	Neg.	Neg.	+	Gangrenous	Enlarged

† D indicates downward trend; D* indicates downward trend with recovery later.

Necropsy.—This revealed a superficial wound infection and a localized peritonitis with adhesions in the gallbladder region. The gallbladder contained brownish-green mucoid material; it was not distended and the walls were slightly thickened. The liver was not enlarged.

Microscopic Examination.—The gallbladder showed destruction of the mucosa, thickening of the wall, increase of fibrous tissue, moderate infiltration with leukocytes, mononuclears predominating. The liver near the gallbladder showed moderate infiltration of leukocytes, chiefly mononuclears, around the bile ducts in the interlobular tissue. There were fatty infiltration and congestion of the parenchyma. At some distance from the gallbladder, the picture was the same but less extensive. Cultures of gallbladder contents and liver showed *B. coli*. The heart blood was sterile.

Dog 2.—The operation was performed as described previously. Two and one-half c.c. of *B. coli* culture was used. Symptoms of peritonitis appeared on the third day. The dog died on the fourth day.



Fig. 6 (Dog 10).—Liver: rather numerous polymorphonuclear leukocytes and round cells under higher magnification.

Necropsy.—This revealed general peritonitis due to leakage through a needle hole in the gallbladder. The gallbladder was dark colored and friable. The liver was enlarged and edematous.

Microscopic Examination.—The gallbladder showed acute inflammation and gangrene. The liver (Fig. 2) showed moderate infiltration of the periportal spaces with polymorphonuclear leukocytes, and marked cloudy swelling of the parenchyma. Changes were most marked near the gallbladder. Cultures from the liver and gallbladder showed *B. coli;* smears from the peritoneum showed a gram-negative bacillus.

Dog 3.—Operation was performed as described. One c.c. of *B. coli* culture was used. The temperature rose to 104 F. on the fifth day and fell to 101 on the eighth day. The dog died on the ninth day. There was a loss of 2,200 gm. in weight.

Necropsy.—There was no general peritonitis. The liver was enlarged, edematous and bluish. The gallbladder showed no leakage of contents; the color was somewhat darker than normal; the contents were a yellowish, turbid mucus. There was bronchopneumonia.

Microscopic Examination.—The gallbladder showed acute inflammation with areas of necrosis; the mucosa was destroyed. There was moderate infiltra-

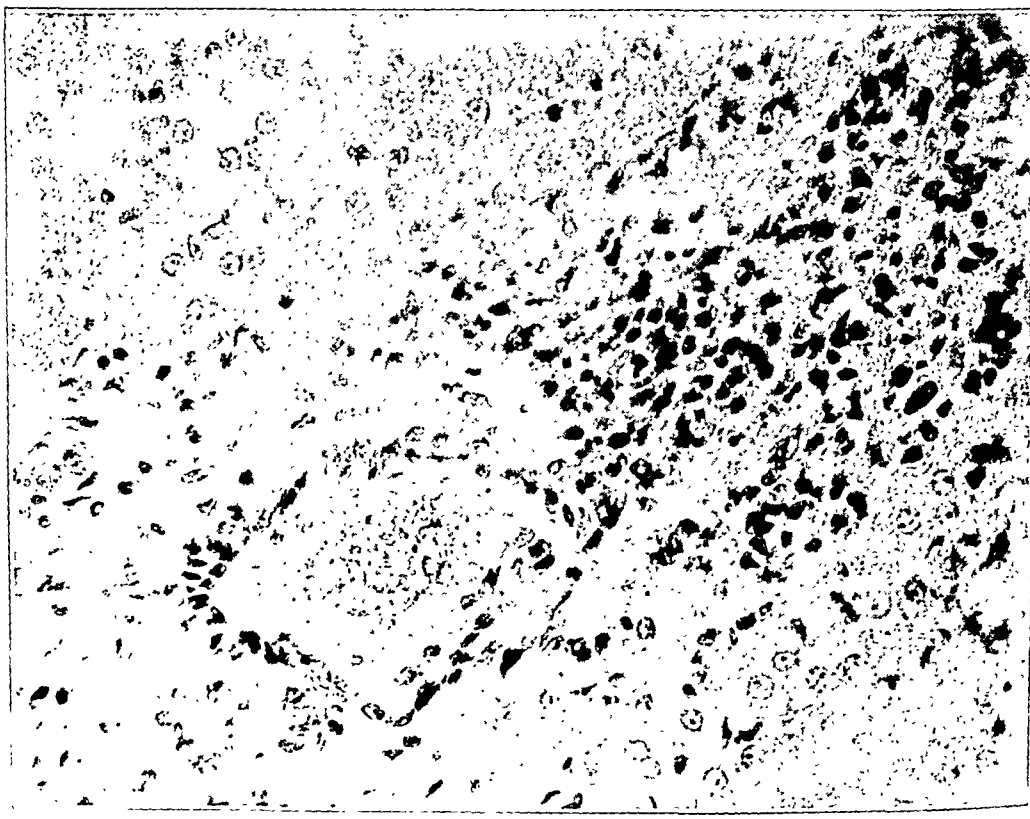

Fig. 7 (Dog 13).—Liver: infiltration of interlobular tissue with leukocytes.

tion of the interlobular tissue of the liver with polymorphonuclear cells, congestion and cloudy swelling. Sections of the liver before cholecystitis showed no leukocytic infiltration. Cultures of the liver and gallbladder contents showed *B. coli.*

Dog 4.—The usual operation was performed. Two c.c. of *B. coli* culture was used. The temperature rose to 103.6 F. on the fourth day, it was normal on the tenth day, with general improvement. The condition was worse on the twelfth day. The dog died on the fifteenth day. The loss in weight was 1,840 gm.

Necropsy.—There were general peritonitis and an extrahepatic abscess in the gallbladder region. The gallbladder was slightly distended and filled with

thick green pus, which escaped through the needle hole. The liver was markedly enlarged and edematous.

Microscopic Examination.—There was acute inflammation of the gallbladder with necrosis. The liver showed marked cloudy swelling with fatty infiltration: there was infiltration of the periportal spaces with polymorphonuclear leukocytes and edema. Liver section before cholecystitis demonstrated that it was normal. Cultures of liver and gallbladder contents showed *B. coli.*

Dog 5.—The usual operation was performed. One and one-half c.c. of *B. coli* culture was used. Death occurred on the tenth day.



Fig. 8 (Dog 15).—Liver: marked pericholangitis under high magnification.

Necropsy.—There was no general peritonitis. The liver was slightly enlarged. The gallbladder was dark in color.

Microscopic Examination.—There was some thickening of the gallbladder walls, degeneration of the submucous layers in places, infiltration with mononuclears and polymorphonuclear cells. All sections of the liver showed slight periportal infiltration with mononuclear and polymorphonuclear cells, congestion and cloudy swelling. There was bronchopneumonia. Liver section was normal before injection. Cultures from the liver and gallbladder showed *B. coli.*

Dog 6.—The usual operation was performed. One c.c. of *B. coli* culture was used. The temperature rose to 104 F. on the fourth day and fell to 102

Dog 3.—Operation was performed as described. One c.c. of *B. coli* culture was used. The temperature rose to 104 F. on the fifth day and fell to 101 on the eighth day. The dog died on the ninth day. There was a loss of 2,200 gm. in weight.

Necropsy.—There was no general peritonitis. The liver was enlarged, edematous and bluish. The gallbladder showed no leakage of contents; the color was somewhat darker than normal; the contents were a yellowish, turbid mucus. There was bronchopneumonia.

Microscopic Examination.—The gallbladder showed acute inflammation with areas of necrosis; the mucosa was destroyed. There was moderate infiltra-



Fig. 7 (Dog 13).—Liver: infiltration of interlobular tissue with leukocytes.

tion of the interlobular tissue of the liver with polymorphonuclear cells, congestion and cloudy swelling. Sections of the liver before cholecystitis showed no leukocytic infiltration. Cultures of the liver and gallbladder contents showed *B. coli*.

Dog 4.—The usual operation was performed. Two c.c. of *B. coli* culture was used. The temperature rose to 103.6 F. on the fourth day, it was normal on the tenth day, with general improvement. The condition was worse on the twelfth day. The dog died on the fifteenth day. The loss in weight was 1,840 gm.

Necropsy.—There were general peritonitis and an extrahepatic abscess in the gallbladder region. The gallbladder was slightly distended and filled with

thick green pus, which escaped through the needle hole. The liver was markedly enlarged and edematous.

Microscopic Examination.—There was acute inflammation of the gallbladder with necrosis. The liver showed marked cloudy swelling with fatty infiltration; there was infiltration of the periportal spaces with polymorphonuclear leukocytes and edema. Liver section before cholecystitis demonstrated that it was normal. Cultures of liver and gallbladder contents showed *B. coli.*

Dog 5.—The usual operation was performed. One and one-half c.c. of *B. coli* culture was used. Death occurred on the tenth day.

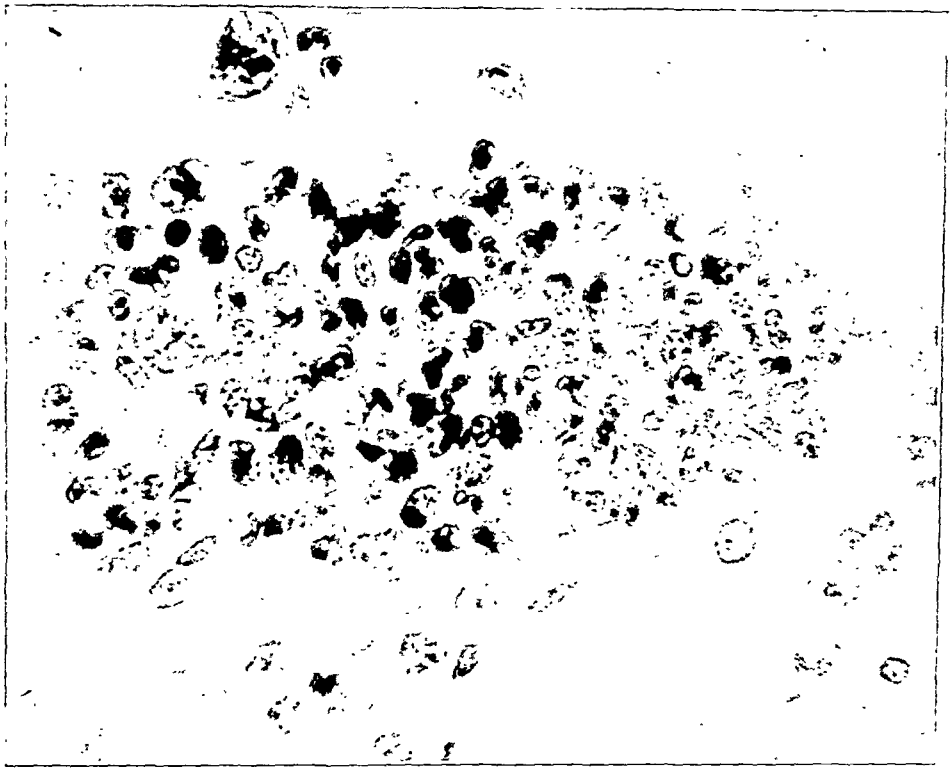

Fig. 8 (Dog 15).—Liver: marked pericholangitis under high magnification.

Necropsy.—There was no general peritonitis. The liver was slightly enlarged. The gallbladder was dark in color.

Microscopic Examination.—There was some thickening of the gallbladder walls, degeneration of the submucous layers in places, infiltration with mononuclears and polymorphonuclear cells. All sections of the liver showed slight periportal infiltration with mononuclear and polymorphonuclear cells, congestion and cloudy swelling. There was bronchopneumonia. Liver section was normal before injection. Cultures from the liver and gallbladder showed *B. coli.*

Dog 6.—The usual operation was performed. One c.c. of *B. coli* culture was used. The temperature rose to 104 F. on the fourth day and fell to 102

on the sixth day; the condition improved, but the appetite was poor. There was progressive loss of weight (2,500 gm.). The dog was killed on the forty-first day and necropsy was performed at once.

Necropsy.—The liver was enlarged to almost twice its size. There was no general peritonitis. The gallbladder was destroyed, the stump of the cystic duct alone remaining. There was a localized abscess at the site of the gallbladder. Smears showed gram-negative bacillus. The urinary bladder was distended with thick, strongly ammoniacal urine. The spleen was enlarged.

Microscopic Examination.—There was marked infiltration of the periportal spaces with polymorphonuclear and mononuclear cells, with cloudy swelling and



Fig. 9 (Dog 19).—Marked leukocytic infiltration of interlobular tissue near the site of the gallbladder. Compare with Figure 10.

necrosis in sections near the gallbladder site. Sections further removed showed a similar, but a much less extensive, picture. There was congestion throughout. Other organs showed cloudy swelling. Cultures of liver and heart blood showed *B. coli*.

Dog 7.—The usual operation was performed. One c.c. of *B. coli* cultu was used. On the third day the animal had chills, a temperature of 104.5 anorexia, and it died on the sixth day.

Necropsy.—There was general peritonitis. The liver was enlarged edematous. The gallbladder was not distended; all sutures and ligatures functioning well

Microscopic Examination.—There was acute inflammation of the gallbladder; the wall was gangrenous. The liver showed infiltration of interlobular tissues with polymorphonuclear cells throughout; there were miliary abscesses. The liver was normal before the production of cholecystitis. Cultures of the liver and gallbladder showed *B. coli.* The heart blood was sterile.

Dog 8.—The usual operation was performed. One-half c.c. of *B. coli* culture was used. Death occurred on second day.

Necropsy.—There was no general peritonitis. The liver was enlarged and edematous. The gallbladder was not distended. The ligatures and sutures were holding.

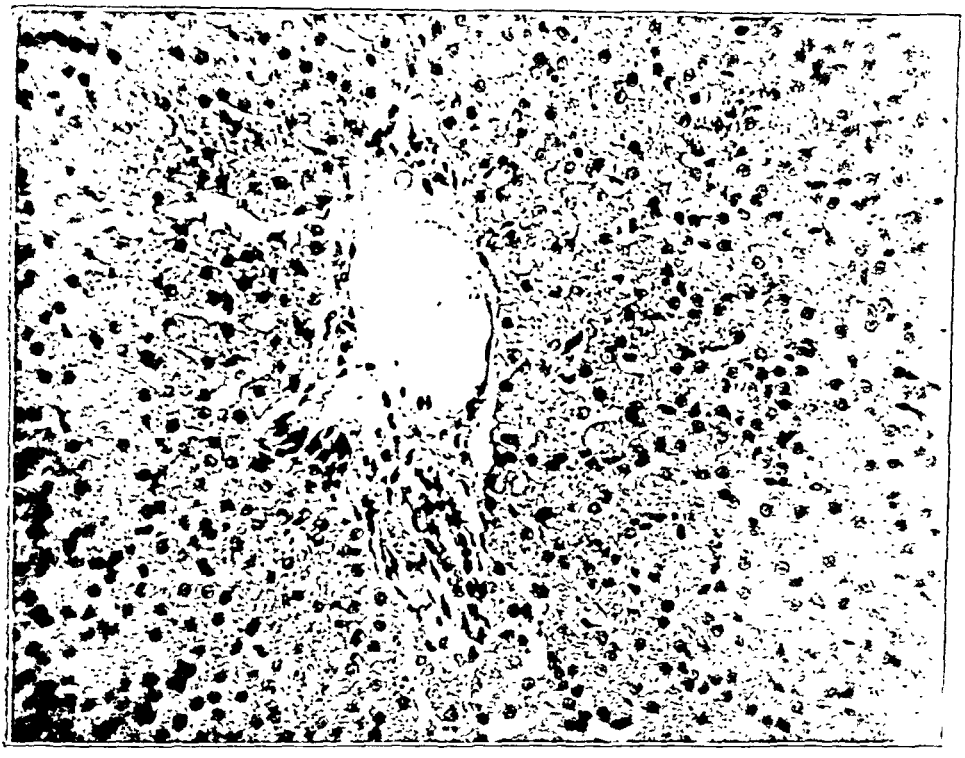

Fig. 10 (Dog 19).—Same liver as in Figure 9, showing moderate leukocytic infiltration in a portion of liver from the left lobe.

Microscopic Examination.—There was marked acute inflammation of the gallbladder. The liver showed infiltration of the periportal spaces with polymorphonuclear cells throughout; there were miliary abscesses. A section of the liver before injection was normal. Cultures of the liver and gallbladder showed B. coli. The heart blood was sterile.

Dog 9.—The usual operation was performed. One c.c. of *B. coli* culture was used. The temperature was 103.2 F. on the fourth day; 102.6 on the seventh day; 104.2 on the ninth day; 104.4 on the twenty-second day. There was a loss of weight of 300 gm. The dog was killed on the twenty-second day.

on the sixth day; the condition improved, but the appetite was poor. There was progressive loss of weight (2,500 gm.). The dog was killed on the forty-first day and necropsy was performed at once.

Necropsy.—The liver was enlarged to almost twice its size. There was no general peritonitis. The gallbladder was destroyed, the stump of the cystic duct alone remaining. There was a localized abscess at the site of the gallbladder. Smears showed gram-negative bacillus. The urinary bladder was distended with thick, strongly ammoniacal urine. The spleen was enlarged.

Microscopic Examination.—There was marked infiltration of the periportal spaces with polymorphonuclear and mononuclear cells, with cloudy swelling and

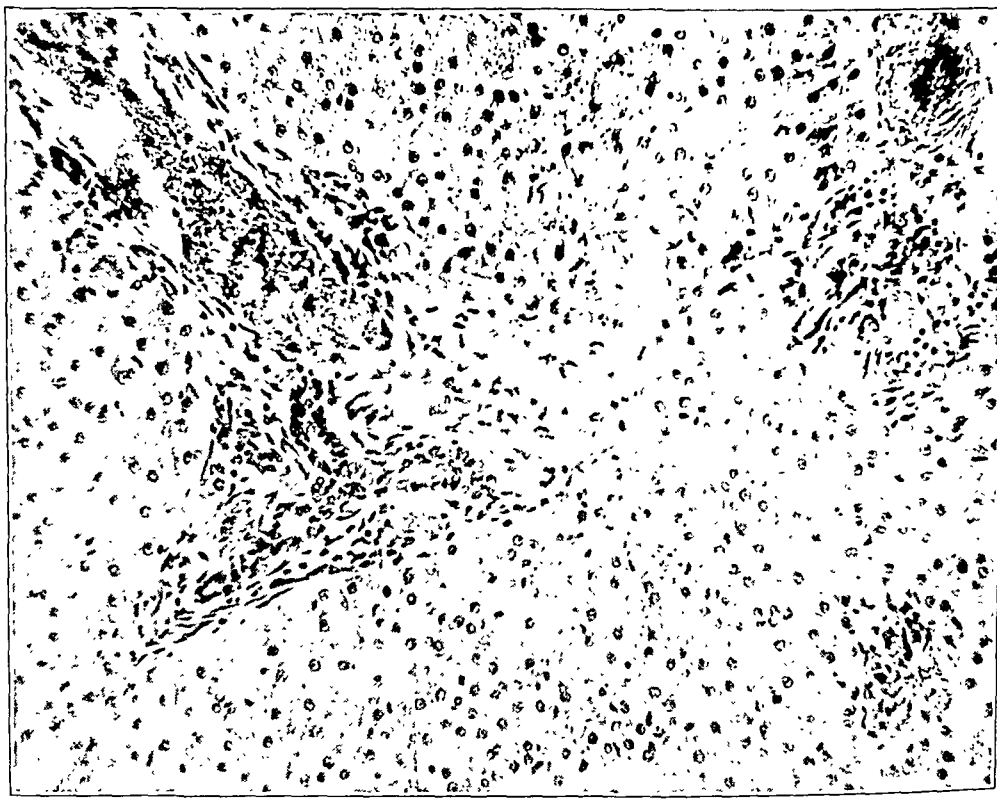

Fig. 9 (Dog 19).—Marked leukocytic infiltration of interlobular tissue near the site of the gallbladder. Compare with Figure 10.

necrosis in sections near the gallbladder site. Sections further removed showed a similar, but a much less extensive, picture. There was congestion throughout. Other organs showed cloudy swelling. Cultures of liver and heart blood showed *B. coli.*

Dog 7.—The usual operation was performed. One c.c. of *B. coli* culture was used. On the third day the animal had chills, a temperature of 104.5 F., anorexia, and it died on the sixth day.

Necropsy.—There was general peritonitis. The liver was enlarged and edematous. The gallbladder was not distended; all sutures and ligatures were functioning well.

Microscopic Examination.—There was acute inflammation of the gallbladder; the wall was gangrenous. The liver showed infiltration of interlobular tissues with polymorphonuclear cells throughout; there were miliary abscesses. The liver was normal before the production of cholecystitis. Cultures of the liver and gallbladder showed *B. coli.* The heart blood was sterile.

Dog 8.—The usual operation was performed. One-half c.c. of *B. coli* culture was used. Death occurred on second day.

Necropsy.—There was no general peritonitis. The liver was enlarged and edematous. The gallbladder was not distended. The ligatures and sutures were holding.

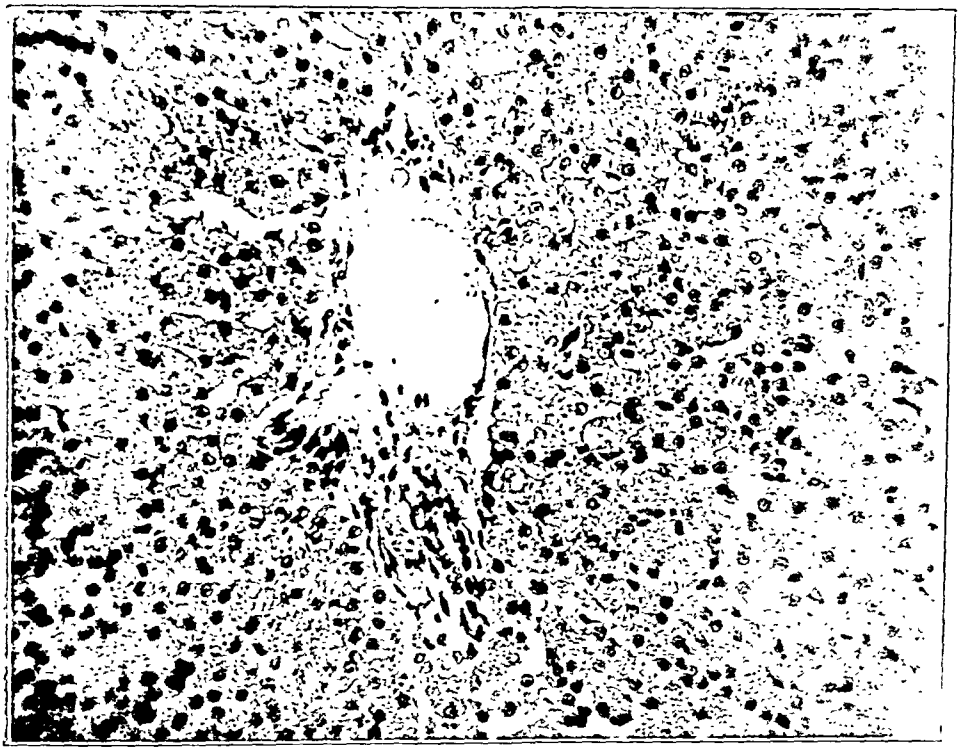

Fig. 10 (Dog 19).—Same liver as in Figure 9, showing moderate leukocytic infiltration in a portion of liver from the left lobe.

Microscopic Examination.—There was marked acute inflammation of the gallbladder. The liver showed infiltration of the periportal spaces with polymorphonuclear cells throughout; there were miliary abscesses. A section of the liver before injection was normal. Cultures of the liver and gallbladder showed B. coli. The heart blood was sterile.

Dog 9.—The usual operation was performed. One c.c. of *B. coli* culture was used. The temperature was 103.2 F. on the fourth day; 102.6 on the seventh day; 104.2 on the ninth day; 104.4 on the twenty-second day. There was a loss of weight of 300 gm. The dog was killed on the twenty-second day.

Necropsy.—There was no general peritonitis. The liver was slightly enlarged. The gallbladder was somewhat distended and filled with dark brown mucus.

Microscopic Examination.—The gallbladder (Fig. 4) showed the mucosa well preserved; the submucosa and muscularis and serosa, edematous and congested, and a small amount of mononuclear and polymorphonuclear infiltration. The liver (Fig. 3) showed infiltration of the periportal spaces with mononuclear and polymorphonuclear cells and cloudy swelling. The liver was normal before injection. Cultures of the gallbladder and liver showed *B. coli.* The heart blood was sterile.

TABLE 3.—BACTERIOLOGIC AND HISTOLOGIC FINDINGS

Dog	Organism Recovered				Microscopic Changes	
	Gallbladder	Liver	Heart Blood	Peritoneum	Gallbladder	Liver
1	+	+	+	..	Acute inflammation; mucosa necrotic	Periportal infiltration; vacuolization
2	+	+	..	+	Acute inflammation; mucosa necrotic	Periportal infiltration moderate; cloudy swelling
3	+	+	0	0	Acute inflammation; mucosa necrotic	Periportal infiltration moderate; degeneration
4	..	..	..	..	Acute inflammation, marked	Periportal infiltration moderate; parenchymatous degeneration
5	+	+	+	+	Acute inflammation; mucosa destroyed	Periportal infiltration moderate; parenchymatous degeneration
6	..	..	..	..	Completely atrophied.....	Periportal infiltration round cells
7	..	..	..	..	Acute inflammation; mucosa gangrenous	Periportal infiltration; parenchymatous degeneration; congestion
8	..	..	..	..	Acute inflammation; mucosa gangrenous	Periportal infiltration; scattered abscesses
9	+	+	0	0	Acute inflammation, slight...	Periportal infiltration; many polymorphonuclears
10*	+	+	0	0	Acute inflammation.....	Periportal infiltration; fatty degeneration
11*	+	+	0	0	Acute inflammation.....	Periportal infiltration; focal necrosis
12	+	+	..	+	Acute inflammation; marked gangrene	Periportal infiltration; parenchymatous degeneration
13*	+	+	0	0	Acute inflammation, marked	Periportal infiltration; parenchymatous degeneration
14	..	..	..	..	Acute inflammation, gangrenous	Periportal infiltration moderate; parenchymatous degeneration
15	..	..	..	..	Acute inflammation.....	Periportal infiltration; many polymorphonuclears
16	+	+	0	0	Acute inflammation, gangrenous	Periportal infiltration; many polymorphonuclears
17	+	+	+	+	Acute inflammation, gangrenous	Periportal infiltration; many polymorphonuclears
18	+	+	+	+	Acute inflammation, gangrenous	Periportal infiltration; many [illegible]
19	..	..	..	..	Acute inflammation, gangrenous	F

* Compare with Table 1.

DOG 10.—The usual operation was performed. One c.c. of *B. coli* culture was used. There was an uneventful recovery. The temperature was 103.2 F. on the third day; 104 on the fifth day and normal on the sixteenth day. On the twenty-ninth day a second operation was attempted. At this time the original incision was well healed; there were many adhesions around the gallbladder; the liver was slightly enlarged; the gallbladder was practically empty and small and the walls were thickened and white. The ligatures were holding. A section from the liver is shown in Figure 5. Blood was taken for agglutination tests (Table 3). The animal died the following day.

Necropsy.—This revealed bronchopneumonia. The condition of the liver was practically the same as at the second operation. There was no general peritonitis.

Microscopic Examination.—There was subacute inflammation of the gallbladder. The reaction was chiefly polymorphonuclear; the wall was fibrous. All sections of the liver showed inflammation of the periportal sheaths similar to those shown in Figure 5. The heart blood was sterile.

Dog 11.—The usual operation was performed. One c.c. of *B. coli* culture was used. The recovery was uneventful. The temperature was 102.4 F. on the fourth day and normal on the ninth day. The second operation was per-

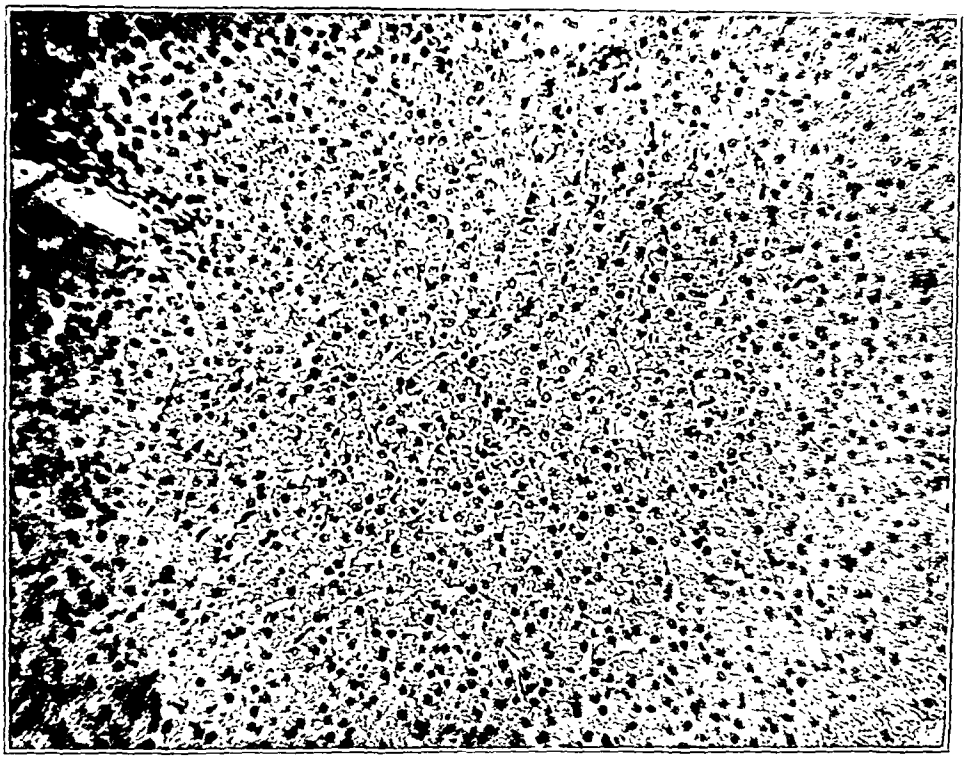

Fig. 11.—Normal dog's liver for comparison.

formed on the ninth day. The wound was healed; the liver was slightly enlarged. Cultures were taken from the right and left lobes, also sections. The gallbladder was not distended; was grayish-blue; the walls were thickened and removed; and it contained dark brown mucus. Blood was taken for agglutination tests (Table 3). The dog died later and the lungs showed bronchopneumonia. The condition of the liver was approximately the same as at the second operation.

Microscopic Examination.—The gallbladder had intact mucosa; it was slightly edematous; the walls were thickened and showed acute inflammation. Sections removed at the second operation showed edema of the interlobular connective tissue with possible increase seen in sections nearest the gallbladder.

central necrosis, cloudy swelling, marked infiltration of the periportal spaces with polymorphonuclear leukocytes throughout. Sections from other portions removed at necropsy showed a similar picture. The heart blood was sterile.

Dog 12.—Routine operation was performed. One c.c. of *B. coli* culture was used. The dog was very sick and died in three days.

Necropsy.—There was considerable free bloody fluid in the peritoneum and there was general peritonitis. The gallbladder was gangrenous, walled in between lobes of liver and contained thick, yellow pus. The liver was enlarged, slightly edematous and bluish in color. Cultures were taken from the extreme right and left portions. The lungs were clear. Death was due to acute peritonitis. Cultures from the gallbladder showed *B. coli,* staphylococcus and mixed culture; from the liver (right and left lobes) *B. coli,* and a large gram-positive bacillus.

Microscopic Examination.—The liver (before injection) showed no pathologic changes. After necropsy, Section A (at a distance from the gallbladder) showed moderate polymorphonuclear infiltration about the portal veins in places, and a few scattered polymorphonuclears around the bile capillaries; Section B (near the gallbladder) showed congestion with necrosis at the periphery of the lobules. Moderate polymorphonuclear infiltration was present in the periportal spaces. In the connective tissue of the stroma and scattered throughout the parenchyma were rod-shaped bodies having the appearance of bacilli. The gallbladder mucosa was almost destroyed. The muscular and serous coats were thickened, edematous, infiltrated with polymorphonuclears and plasma cells. There was an exudate of fibrin and polymorphonuclears outside the serosa.

Dog 13.—Usual routine was followed and 0.75 c.c. *B. coli* culture were injected. There was some leakage and soiling around the gallbladder. The dog made an uneventful recovery. At the second operation the abdomen was opened. The omentum was found wrapped around a mass at the gallbladder site. The mass consisted of gallbladder walled in between lobes of liver and the first and second part of the duodenum. There was no free fluid in the peritoneum and no other adhesions. The liver was slightly enlarged and normal in color. There were numerous adhesions between the liver and abdominal wall, and the liver and the diaphragm. The adhesions were broken. The gallbladder was bluish-white; the walls were thickened and friable. A hole was torn in the gallbladder on manipulation and thick, greenish, gelatinous material oozed out. The hole was closed with purse-string sutures. Stab-cultures and sections were taken from the liver. One c.c. of twenty-four-hour *B. coli* broth culture was injected into the repaired gallbladder. The intestine was opened to obtain the culture. It was closed with purse-string sutures, The abdomen was closed. There were many bleeding points in the separated adhesions. The dog died on the following day.

Necropsy.—There were many freshly formed adhesions in the abdominal viscera; the liver was normal. There was bronchopneumonia. A section of the liver was taken. Death was due to bronchopneumonia. Cultures from the gallbladder showed *B. coli;* from the liver (left lobe) *B. coli;* from the liver (right lobe) *B. coli;* from the intestine (*a*) *B. coli,* and mixed culture; from intestine (*b*) *B. coli,* and mixed culture (Table 3).

Microscopic Examination.—The liver (before injection) showed no pathologic changes. After necropsy there was marked infiltration of the periportal spaces with round cells, plasma cells and polymorphonuclears (Figs. 7 and 8).

The gallbladder showed extremely acute inflammation, marked leukocytic infiltration and hemorrhage.

Dog 14.—The routine operation was performed and 1 c.c. *B. coli* culture was injected. The dog died twenty hours after operation.

Necropsy.—There was a large amount of free bloody fluid, slightly biletinged, in the abdomen. There was diffuse hemorrhagic peritonitis. The liver was dark and slightly edematous. The gallbladder was walled in between lobes of the liver; the distal end of the cystic duct was free; the ligature was off, and there was slight oozing of bile from the duct.



Fig. 12.—Normal dog's liver for comparison.

Microscopic Examination.—The liver showed marked loss of architecture; the cells were swollen and edematous. The picture was that of reaction to peritonitis with slight periportal infiltration, beginning stage. The gallbladder mucosa was degenerated and sloughing; there was acute inflammation; the muscular and serous coats were thickened, edematous and infiltrated with polymorphonuclears.

SERIES II. NONHEMOLYTIC STREPTOCOCCUS

Dog 15.—The usual routine operation was performed and 0.5 c.c. nonhemolytic streptococcus was injected. The cystic duct and vessels were ligated with two ligatures and cut between. The dog had a stormy course. It was killed twenty days after operation.

Necropsy.—The sinus at the upper pole of the wound was discharging pus. There was no free fluid in the peritoneum. The gallbladder was walled in between the lobes of the liver and omentum; the first part of the duodenum was bound in a mass of adhesions. The gallbladder was white, contained clear, thick, yellowish mucus with a small amount of purulent exudate at the base. The liver was enlarged and normal in color. There were several abscesses about the gallbladder site. The lungs showed multiple abscesses. A culture from the liver showed streptococcus (nonhemolytic) both from the abscess as well as from the interior of the right lobe at a distance from the abscess. The gallbladder showed streptococcus (nonhemolytic).

Microscopic Examination.—The liver (before injection) showed no changes. Sections of the liver after injection showed periportal infiltration with general parenchymatous degeneration (Figs. 7 and 8). The gallbladder showed acute inflammation. There was bronchopneumonia.

Dog 16.—The usual routine operation was performed; 0.5 c.c. nonhemolytic streptococcus was injected. The duct was ligated with two ligatures and cut between. The dog died two days after the operation.

Necropsy.—The abdomen was full of free bloody fluid; there was general peritonitis. The liver was dark red, friable and slightly edematous. The gallbladder was black and distended and full of black fluid. The peritoneum was dull red throughout. Culture was made of the heart's blood, which was negative. The gallbladder showed nonhemolytic streptococcus; the liver, nonhemolytic streptococcus. A smear from the peritoneal fluid showed gram-negative and gram-positive rods; no streptococci.

Microscopic Findings.—The liver (before injection) showed no change. Sections (at necropsy) next the gallbladder, showed on one side a layer of inflammatory exudate with polymorphonuclears, plasma cells and fibrin. The inflammation extended into the liver substance, the bile spaces and the periportal areas being infiltrated with polymorphonuclears. The reaction became less severe farther away from the site. Sections at various points in the liver showed cloudy swelling, congestion and varying degrees of polymorphonuclear infiltration. The gallbladder showed edema and necrosis of the mucosa.

Dog 17.—The usual routine operation was performed and 0.3 c.c. of nonhemolytic streptococcus culture was injected. The duct was ligated twice and cut between the ligatures. The dog died in two days.

Necropsy.—The abdomen contained a large amount of free bloody fluid. The liver was enlarged and dark. The gallbladder was walled in between lobes of the liver and plastered down with omentum. It was distended, large, brown, gangrenous and filled with dark brown mucus. The heart was dilated. Culture was made of the heart's blood. Cultures of the liver before production of cholecystitis were sterile. At necropsy the peritoneal fluid showed streptococcus; the gallbladder, streptococcus; the liver, streptococcus, and the heart's blood, streptococcus.

Microscopic Findings.—The liver before injection showed no changes. Sections (at necropsy) showed cloudy swelling, congestion, slight infiltration of polymorphonuclears into the periportal spaces. Sections from the fundus and neck of the gallbladder showed complete necrosis.

Dog 18.—The routine operation was performed; 0.3 c.c. of nonhemolytic streptococcus was injected. There was a double ligature, cut between. The dog died two days after operation.

Necropsy.—This revealed a small amount of free bloody fluid in the peritoneal cavity. There was general, diffuse, acute peritonitis. The gallbladder was surrounded by lobes of the liver; it was small, dark, gangrenous and contained thick, black material. The liver was enlarged and dark red, especially around the gallbladder. Cultures at necropsy from the peritoneum showed streptococcus; from the liver, streptococcus; from the gallbladder, streptococcus, and from the heart's blood, streptococcus.

Microscopic Findings.—The liver, before injection, showed no change. Sections (at necropsy), showed cloudy swelling throughout with areas of central necrosis. There was a collection of round cells and polymorphonuclears in the periportal areas. The gallbladder mucosa was necrotic and it was infiltrated with polymorphonuclears.

Dog 19.—The usual routine was performed; 0.3 c.c. of nonhemolytic streptococcus culture was injected. Double ligatures were made and cut between the ligatures. The dog died six days after operation.

Necropsy.—The abdomen contained a large amount of free bloody fluid; there was diffuse peritonitis. The first portion of the duodenum was wrapped in a mass of omentum which bound the lobes of the liver around the gallbladder. The liver was enlarged with areas of superficial necrosis. The gallbladder was gangrenous and contained thick dark green fluid.

Microscopic Examination.—The liver, before injection into the gallbladder, showed no change. Sections (at necropsy) showed loss of architecture, parenchymatous degeneration, periportal infiltration of polymorphonuclears. The gallbladder showed almost complete necrosis (Figs. 9 and 10).

of 100 per cent. With temperatures higher than 42 C., the lethal effect is in evidence sooner and attains its maximum with shorter periods of exposure until at 46 C. a thirty minute exposure is lethal in more than 60 per cent. of cases.

THE EFFECT OF COMBINED HEAT AND RADIATION ON FRAGMENTS OF TRANSPLANTABLE TUMOR IN VITRO

Having determined the lethal point for the Crocker mouse sarcoma 180 with different degrees of heat at different time intervals, and having the advantage of the results of the previous work of Wood and Prime,[16] who, using the same tumor strain, determined the lethal effect of radiation, we next employed a combination of the two agents, each in sublethal doses.

The technical steps in the experiments in this series were similar to those previously described. The heat exposures were made as previously stated, except that in combining the two physical agents, exposures were made only at 42, 43 and 44 C. for the fixed period of thirty minutes. This time interval represented the threshold of lethal effect at each of these temperatures.

The tumor to be exposed to radiation was cut into small fragments as before, and the fragments were placed in glass dishes with enough cold Ringer's solution to keep them moist, and were covered with a sterile cover glass. The radiation dose was 85,000 volts, 5 milliamperes, with a 3 mm. aluminum filter at a distance of 23 cm. for 10, 20, 30 and 40 minutes.

In these experiments, we again used repeated series of twelve animals each, the grand total being 3,248 animals. The series were as follows: (*a*) animals inoculated with untreated portions of the tumor; (*b*) animals inoculated with fragments treated with heat alone; (*c*) animals inoculated with fragments treated with roentgen ray alone; (*d*) animals inoculated with fragments treated with radiation first and heat directly afterward; (*e*) animals inoculated with fragments treated with heat first and radiation directly afterward. As before, the animals were observed for five weeks after inoculation and the percentage of "takes" was then determined. The data are graphically presented in Charts 2 and 3.

The untreated controls showed 100 per cent. "takes," the animals inoculated with fragments exposed to one erythema dose showed 93 per cent. "takes" and those inoculated with fragments exposed to three erythema doses, 68 per cent. The animals inoculated with frag-

16. Wood, F. C., and Prime, Frederick: Ann. Surg. **62**:751, 1915; Lethal Dose of Roentgen Ray for Cancer Cells, J. A. M. A. **74**:308 (Jan. 31) 1920.

ments treated solely with heat showed 82 per cent. "takes" when the exposure had been to 44 C., and 100 per cent. when the exposure had been to 42 C.

When both heat and radiation are applied in sublethal dose, and it makes but little difference which is applied first, there is a marked lethal effect. Thus, while a temperature of 42 C. for a period of thirty minutes applied after one erythema dose has a lethal effect of but 10 per cent., and when the order of application of the agents is reversed no lethal effect is noted, a temperature only one degree higher produces a lethal effect of 76 per cent. in one instance and 91 per cent.

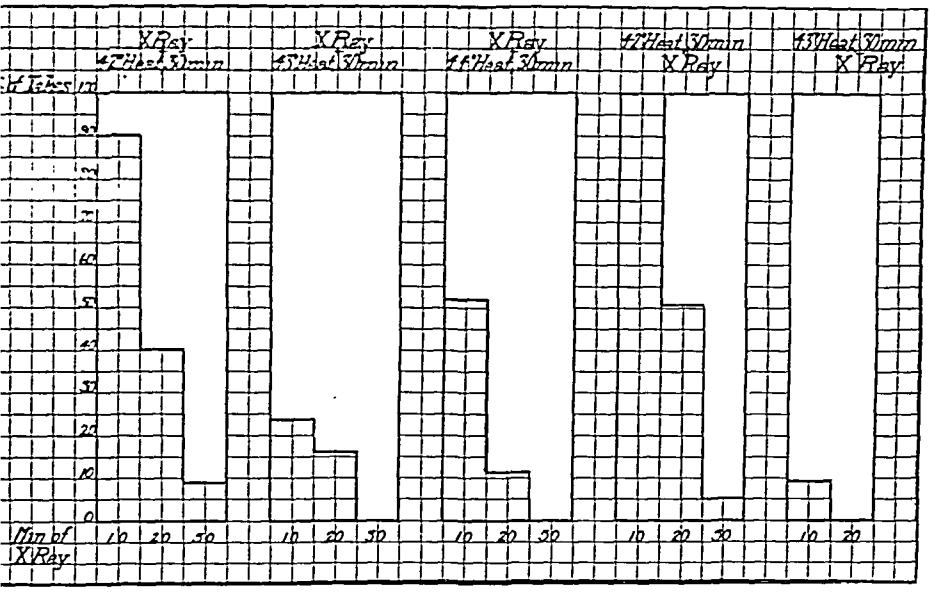

Chart 3.—Effect of combined heat and radiation on fragments of transplantable tumor in vitro.

in the other. The lethal effect of radiation combined with heat is not so marked at 44 C. as at the lower temperature of 43 C. This we have interpreted as an evidence of stimulation comparable to the stimulation which occurs with certain sublethal doses of radiation. The maximum lethal effect of 100 per cent. is obtained with three erythema doses and thirty minutes' exposure to 43 C., the radiation being applied first, or with two erythema doses and thirty minutes' exposure to 43 C., the heat being applied first. The slight difference is probably of no significance. According to the results obtained by Wood and Prime, five erythema doses alone are required to kill the cells of mouse sarcoma 180; and our previously described experiment with the

same tumor strain shows that 120 minutes' heating at 43 C. is required to kill. The combination of a given sublethal dose of the two agents, therefore, produces the same effect as four times the dose of heat when used alone, and as five times the dose of radiation when used alone.

THE EFFECT OF HEAT UPON TUMORS IN VIVO

Since the results of biologic experiments in vivo often are different from those of the same experiments in vitro, these observations were repeated on tumors in the animal body. For this reason in the later experiments, the tumors were heated by diathermy, a term applied to an alternating current of high frequency used so as to create heat in the tissues through which it passes. The degree of heat obtained,

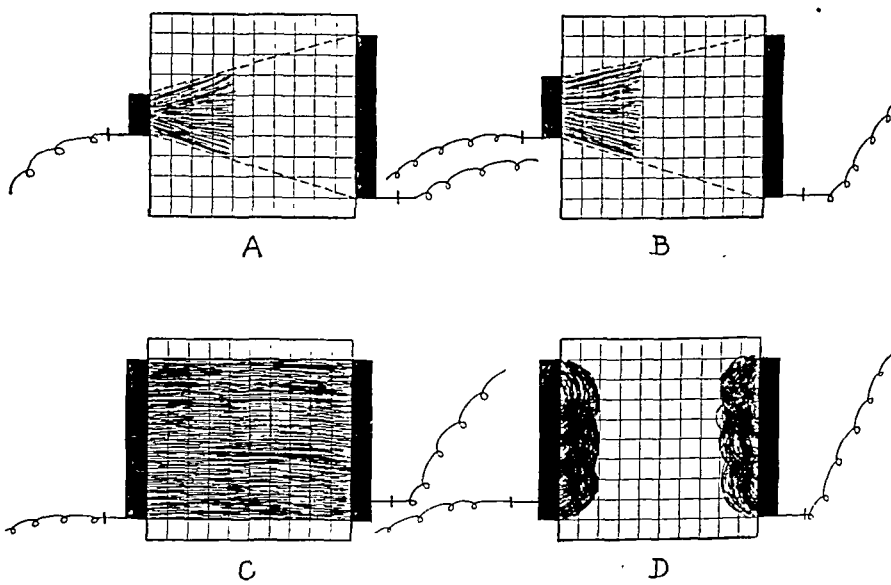

Chart 4.—Effect of electrode shape and current strength on intervening tissues: *A*, 10 ma., ten minutes; *B*, 100 ma., four minutes; *C*, 10 ma., ten minutes; *D*, 100 ma., four minutes. Strong current for a short time gives a superficial action (*B*, *D*). Weak current for a long period gives deeper action (*A*, *C*). If both electrodes are of the same area and the current is weak, the heated zone is cylindric (*C*). If one electrode is small or the current is strong, the heated zone is localized about the electrode (*B*, *D*).

and, hence, the physical changes which occur in the tissues are dependent on two conditions: (*a*) amperage and (*b*) shape and area of the electrode. By varying these two, all effects from a slight increase in temperature to charring of tissues are obtainable.

It was the aim in combining the two agents, radiation and heat, to produce relatively low degrees of temperature, and to continue them over relatively long periods, and it is in these two points that

the method employed differs from all others which have been recorded. Thus, a recent study of this subject [17] is based upon the use of 3 amperes of current for fifteen seconds with very small electrodes, and the conclusion is reached that the method is valueless. To anticipate, in order to indicate the difference between the method used in the present experiments and those in the work just referred to, it may be stated that we have employed 40 milliamperes for a period of twenty minutes with relatively large electrodes. The previous worker reported a typical burn reaction, while the tissues we have treated show no such changes. The temperatures we have employed are also very much lower than those used in the Percy or in any other cauterization or fulguration methods which have been advocated.

As has been stated before, the degree and type of effect of the heat generated by the high frequency current is dependent upon the shape of the electrode. Chart 4 illustrates the points which are of importance. If the electrodes are of unequal size, as in *A*, and the current weak, there will develop a zone of reaction penetrating for a considerable distance into the tissues but attaining its maximum at the small electrode. On the other hand, if the current is increased in strength, the effect is directly localized about the small electrode, as in *B*. If the electrode is of equal size and a weak current is employed, as in *C*, there is a cylindric area of action between the two electrodes, while if the current is strong there is a marked action about each electrode, but none in the depths of the tissues, as in *D*.

While the facts just stated are common knowledge, a search of the literature revealed no data on the amount of current necessary to produce a given rise in temperature. In order to determine this, diathermy was applied to various thicknesses of bone-free meat. The initial temperature of the meat before the application of diathermy was in each instance 10 C. and the given amperage was allowed to flow for a period of twenty minutes. A thermometer was placed in the tissue midway between the electrodes, and the temperature was noted every three minutes. The amperage is based on the square area of one electrode, and both electrodes were of the same shape and size.

Chart 5 presents a curve constructed on the data thus obtained, and while it is far from mathematically accurate, it is close enough for practical purposes. With an electrode with a surface area of 2.5 by 2.5 cm. and with 10 milliamperes, the increase in temperature

17. Stephan, Erich: Histologische Untersuchungen über die Wirkung der Thermopenetration auf normale Gewebe und Carcinom. Beitr. z. klin. Chir. **77**:382, 1912.

produced by twenty minutes' application of current in varying thicknesses of tissue is as shown by the curve. If electrodes of twice this size are used, then the heat produced is one-half that recorded in the chart; and if living instead of dead tissues are used, the rise in temperature is approximately double that indicated on the chart. Why this is so we do not know. The increase of temperature in dead tissue for the first ten minutes of current flow is rather slow, but for the second ten minutes is more rapid; and while a continuation of

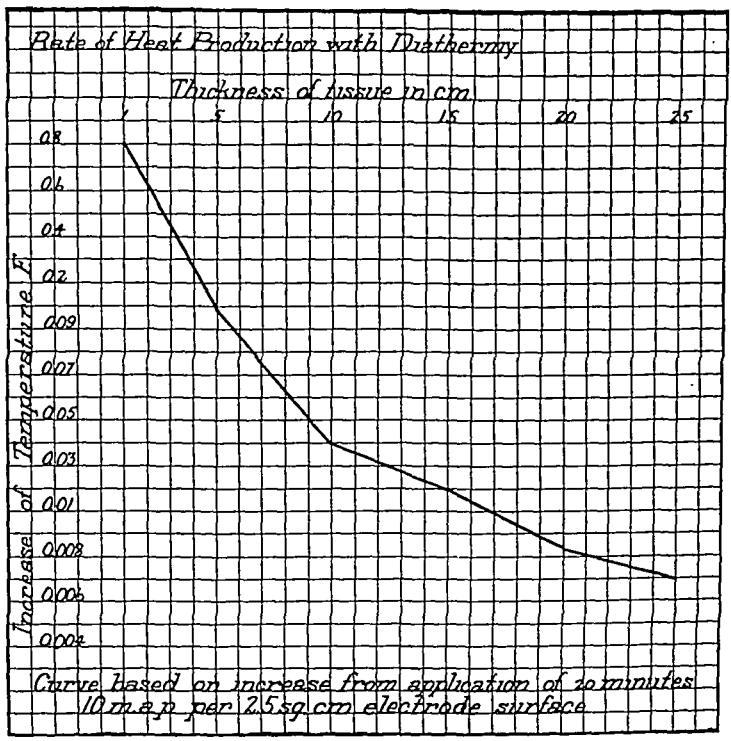

Chart 5.—Amount of current necessary to produce a given rise in temperature.

the same amount of current for more than twenty minutes gradually increases the temperature, this increase is extremely slow, and for practical purposes can be disregarded.

In applying the current to human beings the procedure is as follows: Electrodes of equal size and the same shape are cut from block tin. Gauze compresses, four or five folds thick, are moistened with water and applied to the skin, the compresses being made large enough to allow of a 4 cm. margin outside the electrode. Sparking due to imperfect contact of the electrode or to electrode connections with the skin must be avoided, for sparking is painful and produces burns.

The amperage used is roughly fixed by determining in centimeters the square area of one electrode, dividing this by 6 (the square area of the electrode used in Chart 5), dividing the result by 2 (if the tissues are living), and multiplying the result thus obtained by 10 (the amperage used in the experiment on which Chart 5 is based). The amperage may, however, be more easily regulated by the sensation of the patient. Sparking being obviated, the amperage is increased until the patient states that the degree of heat is uncomfortable; the amperage is then decreased until the patient feels perfectly comfortable with the degree of heat that is being produced. The treatment is timed from twenty minutes after the current is turned on, so that, the average treatment being from thirty to forty minutes, the total exposure is approximately one hour. Our experiments have shown that low degrees of heat (41 C.) produce the same results as high degrees (46 C.), but to be effective the lower temperature must be applied for longer periods. This should be borne in mind when treatments are given.

For the purposes of histologic study of the changes in the tissues, a series of transplantable rat sarcomas and carcinomas were treated with diathermy (exposure twenty minutes); amperage, 40 milliamperes; area of electrode, 8 sq. cm.; depth of tissue, 5 cm. Some of the animals received but one treatment, and were killed at intervals ranging from twenty-four hours to one week after treatment; others received two, three and four treatments at two-day intervals, and were killed at intervals of from twenty-four hours to one week after the last treatment.

The histologic changes observed occurred in this sequence. Twenty-four hours after the treatment there was an intense congestion of all the small blood vessels of the tumor, most of them being from five to six times their normal diameter. This congestion was so intense as to give rise to a deep red color throughout the tumor; this occurred irrespective of whether the animal had had one or more treatments, and was demonstrable up to twenty-four hours after the last treatment. About three days after treatment, the cell outlines became obscure, though the nuclei still preserved their outline and staining qualities. Next the cytoplasm became decidedly acidophil, the tissues took the stains poorly and there was an evident karyorrhexis. About this period, some of the blood vessels became thrombosed, and vacuolation occurred in some of the cells, the connective tissue framework of the tumor standing out markedly owing to the degeneration of the parenchyma. At still later periods (three and six days) areas of liquefaction or massive coagulation necrosis were in evidence; and at the seventh day, replacement fibrosis began to be obvious arising from the

intact blood vessels at the periphery of the tumor or from the surrounding healthy tissue. Absorption of the necrotic material was extremely slow. It is interesting to note that while the untreated tumors showed an average of twenty mitotic figures to the field of a 12 mm. objective, a tumor treated but once showed no mitotic figures in 180 fields, twenty-four hours after treatment. Exposures



Chart 6.—Effect of combined heat and radiation on spontaneous tumors in vivo.

made at intervals more frequent than once in seven days did not increase the intensity of the reaction. Evidently, the damage done with one treatment cannot be duplicated until the neoplasm has had a chance to recuperate to some degree. There were no changes in the organs of the exposed animals which could be attributed to the treatment or to the absorption of dead material.

EFFECT OF COMBINED HEAT AND RADIATION ON SPONTANEOUS TUMORS IN VIVO

For the purpose of this investigation, spontaneous tumors in mice of the "Lathrop" stock were used. The animals of this breed are particularly prone to develop tumors of the breast and all those treated originated in that locality. Some of the tumors were treated with

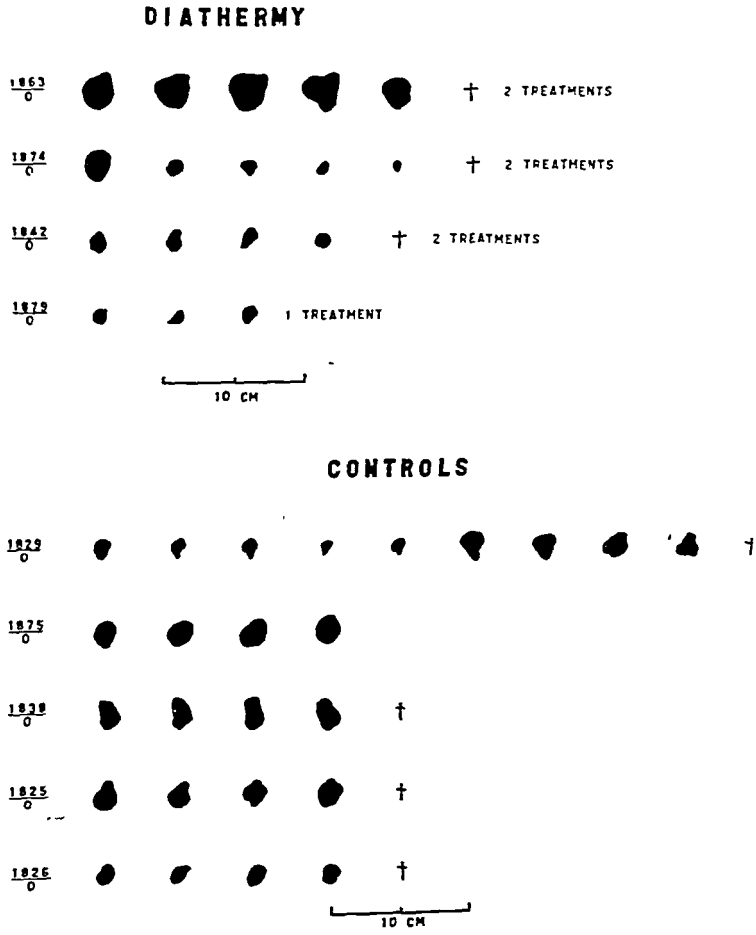

Chart 7.—Effect of combined heat and radiation on spontaneous tumors in vivo.

radiation alone, others with diathermy alone, and still others with a combination of the two agents. Radiation was given the tumor once in from seven to ten days, the distance being 23 cm. from the neoplasm, the rays filtered by 3 mm. aluminum with a voltage of 85,000 and 5 milliamperes through the tube for a period of twenty minutes.

All parts of the animal except the tumor under treatment were carefully screened by heavy lead. Diathermy was given through a 2.5 cm. square electrode for a period of twenty minutes with 40 milliamperes once in seven or ten days. When radiation and heat were both applied it was done in some instances on the same day, in other instances at twenty-four hour intervals; sometimes heat was applied first, while at other times radiation was used first. The interval between successive combination treatments was from seven to ten days.



Chart 8.—Effect of combined heat and radiation on spontaneous tumors in vivo.

The results obtained are graphically shown in Charts 6, 7 and 8. The first column in each chart indicates the size of the tumor on commencing treatment, the other columns indicate the size of the tumor at subsequent weekly intervals. Tumors treated with diathermy or radiation alone show but little inhibition or recession in growth when compared to tumors treated by a combination of both of these agents.

CONCLUSIONS

Low degrees of heat applied for varying periods of time have a lethal action on neoplastic cells in vitro and this lethal action with proper dosage is effective in 100 per cent. of cases. Histologic examination of tumors which have been treated by diathermy reveals cellular changes similar to those observed in tumors exposed to radiation.

Wood and Prime have shown that any tumor may be killed by a sufficient dosage of either radium or roentgen ray; but that in many instances the patient will not survive the dosage necessary to bring about the death of all the cells of an internal, highly malignant carcinoma or sarcoma. Our experiments demonstrate that by combining radiation with an agent not so destructive to the organism the field of usefulness of radiotherapeutic measures may be extended.

The results obtained in the animal experiments show that the therapeutic range of radiation can be considerably increased.

While the principles worked out in the animal experiments here recorded are already being applied in the treatment of cases of neoplasia in human beings, the technical development of the method and the evaluation of the final results will require long and careful observation of the patients before its applicability can be demonstrated.

UNRECOGNIZED OCCUPATIONAL DESTRUCTION OF THE TENDON OF THE LONG HEAD OF THE BICEPS BRACHII *

ARTHUR WILLIAM MEYER, M.D.
PALO ALTO, CALIF.

In 1915 I reported [1] six instances of destruction of the tendon of the long head of the biceps. This destruction occurred between the region of the humeral tuberosities and the supraglenoid tubercle of the scapula. In five of these cases, the destruction of the tendon was complete and was accompanied by destructive changes in the capsule of the shoulder joint, on the acromion and the humeral tuberosities, in the glenoid cavity, on the head of the humerus, in the acromioclavicular joint, and even on the internal surface of the deltoid itself. In one case, the sixth, considerable portions of the articular capsule and the entire lesser tuberosity also were destroyed. Yet in this case, the tendon of the long head was only displaced anteriorly and downward, lying along the anterior margin of the glenoid cavity and then passing to the intertubercular sulcus, which it reached a centimeter distal to the tuberosities. None of these articulations contained any deposits or other evidences of the existence of recent effusion, and the whole picture suggested that the condition resulted from a low grade, long-standing process.

Since the destruction not only of the capsule and the tendon but even of the articular cartilage and also the changes in the adjacent bone were so extensive, it is evident that the process could not have been acute. No evidence of surgical intervention was present in any of these cases, hence the condition could not have been accompanied by much if any suppuration even in the acute stage of the process, if such there was.

It is regrettable that clinical histories of these cases were unobtainable, for they might have thrown light on the probable cause and the nature of these conditions, for similar findings were not found recorded in the literature up to that time, nor have I learned of similar cases since. Such cases apparently do not appear in clinics and dispensaries, for pathologists and orthopedic surgeons seem to be unfamiliar with them. Nor have I learned that similar cases have been observed in other anatomic laboratories, but if I have overlooked such

---

* From the Department of Anatomy, Leland Stanford Junior University School of Medicine.

1. Meyer, A. W.: Anatomical Specimens of Unusual Clinical Interest. (2) The Effect of Arthritis Deformans (?) on the Tendon of the Long Head of the Biceps. Am. J. Orthop. Surg. **13**:91 (July) 1915.

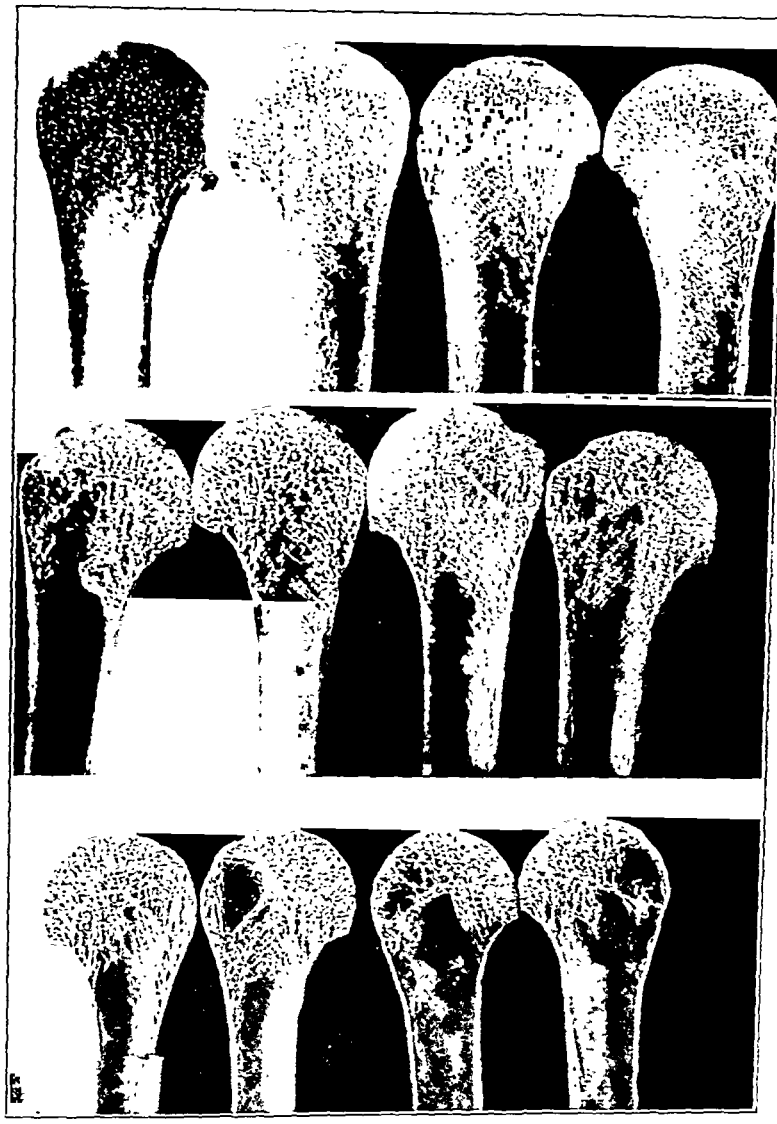

Fig. 1.—Humeri of the first six specimens, bisected longitudinally in a plane approximately parallel to the condylar articular surface.

a report I trust that my attention will be called to it. Since the condition is so surprising it seems strange that the specimens reported in 1915 have not arrested attention sufficiently to have resulted in direct confirmation from other sources, for I have observed seven additional cases since then. Since we have dissected only about sixty cadavers since that time, it is evident that this condition is rather common here. It is possible, though not very probable, that the condition is geographically limited; but one can hardly believe that the occurrence of these

Fig. 2.—Early stage in the destruction of the capsule in a right shoulder joint of a man. The defect in the thickened capsule lies directly above the lesser tuberosity.

cases could be confined to the city of San Francisco, from which we obtained all of our anatomic material. It is true that more arthritic conditions have come to my attention in a single year in our laboratory here, than I saw during four years in other laboratories in which far more dissections were performed; but they seem to fall in a rather different category.

The humerus of each of the six subjects forming the basis of my previous report has been cleaned and bisected longitudinally to permit of inspection of the spongiosa, particularly in the head of the bone.

Although both the humeral tuberosities and the cartilage were partially or wholly destroyed in all these specimens, and although polishing was present somewhere on the head of most of them, the spongiosa contained no gross evidences that there had been suppurative foci previously. This is apparent in Figure 1. Although considerable bone destruction and often also deposition had occurred in the region of the tuberosities of some of these humeri, the underlying spongiosa, nevertheless, was normal. It is true that a large open space is present in the spongiosa under the region of the greater tuberosity in the last two humeri; but as I have previously reported,[2] such not rarely is the case in normal bones. These free spaces in the spongiosa are apparently due to absorption, usually the result of advancing years. Both of the humeri showing these absorption areas came from senile cadavers, and since the adjacent spongiosa looks entirely normal, and since extremely fine trabeculae bridge the margins of these open spaces, it seems very unlikely to me that one could rightly regard them as old abscess cavities from which an infectious process spread to the joints. This conclusion does not, to be sure, wholly exclude the medulla of these bones as a possible source of infection, if such it was, for many of the cancelli are so large that an infectious process, which did not result in destruction of the spongiosa, perhaps could be located there and spread to adjacent extra-articular structures through the numerous vascular canals in the head of the bone. That, however, seems unlikely, although I am not very competent to judge regarding this matter.

Before considering the possible significance of the findings in the seven cases reported herewith, it will be well to examine them somewhat in detail.

DESCRIPTION OF SPECIMENS

SPECIMEN 7.—The earliest stage in the process of destruction of the articular capsule, of the tendon of the long head of the biceps and of the cartilage on portions of the glenoid cavity of the scapula and on the head of the humerus, which I have observed, is represented, in part, in Figure 2. This view represents the lateral surface of the shoulder joint of the right extremity of a male subject and shows the upper end of the humerus and the upper surface of the scapula in outline merely. The border of the opened subdeltoid bursa is represented immediately above the greater tuberosity, and a defect in the thickened articular capsule is shown in natural size directly in front of the acromion. A portion of the articular cartilage on the humeral head is exposed through this defect and very slight bony changes are visible in this portion of the humeral neck.

The biceps is very well developed and the tendon of the long head perfectly preserved up to the region of the tuberosity. It is entirely free throughout the

2. Meyer, A. W.: The Architecture of the Proximal Extremity of the Humerus, Anat. Record **12**:60, 1917.

articulation, and tension on it resulted in movement of the scapula. The superior portion of the capsule of this shoulder joint is from 3.5 to 4 mm. thick and densely fibrous. When the capsule was opened along its inferior border, the cartilage on the head of the humerus and that in the glenoid cavity appeared to be entirely normal. The cartilaginous surface is smooth and glistening and without even a small defect or any evidence of erosion. However, the soft tissues on the inferior surface of the acromion are worn into shreds, apparently from contact with the tuberosities in a position of hyperabduction. The capsular portion of the tendon of the biceps is greatly flattened and shredded, especially on one side, the edges being worn into a fringe for a distance of approximately 4 cm. (Fig. 3).

Specimen 8.—The humeroscapular articulation of the left arm of this female is quite normal. The cartilage is preserved over the whole head of the humerus and also in the glenoid cavity and apparently is of normal thickness. The lesser tuberosity is unaffected, but the greater shows some absorption, roughening, and also some deposition of new bone, especially in the region of the intertubercular sulcus. The capsule is deficient and frayed in its superior portion, and the tendon of the long head of the biceps, which is fused with it,



Fig. 3.—Frayed and shredded tendon from Subject 7. The cut scapular end is to the right, and the narrowest part is the intertubercular portion.

is frayed especially along the posterior margin in the region of the tuberosities where it is reached by some remaining strands, only about one fourth the caliber of the normal tendon. The capsule seems thickened in the region of the supraspinatus and the tendon of the latter is firmly fused with it. The fibrous tissue and the periosteum underneath the tip of the acromion are frayed and entirely worn off over small areas on the under surface of the bone. The acromioclavicular joint seems normal, and the same thing applies to the elbow and wrist joints, except that slight erosion of the cartilage is present over a small area of the capitellum.

Since the tendon of the long head of the biceps shows almost complete destruction in this case, and since it also is adherent to the capsule up to the region of the tuberosities, and also because defects are present in the capsule itself and slight bony changes are present on the acromion and tuberosities, one would seem to be justified in concluding that this arm exemplifies a later stage in the process of destruction of the tendon of the long head of the biceps. In fact, this and the previous case are the only ones in which the tendon had not already been anchored in the region of the tuberosities. In the latter region the destruction of the tendon in this case was less evident, while in the former it was almost complete.

SPECIMEN 9.—In this specimen, the left arm of a male, also with splendid muscular development, the tendon of the long head already is anchored to the shaft of the humerus somewhat distal to the tuberosity. The articular capsule is entirely intact except in the region of the lesser tuberosity where it is thin and deficient. The subdeltoid bursa is extensive, and its wall is fused directly with the capsule at the periphery of the deficiency just mentioned. A diverticulum of this bursa extends beneath, and 4 cm. along, the tendon of the short head of the biceps and the coracobrachialis, and also downward for a distance of 3 cm., lying superficial to the tendon of the subscapularis. It is one of the most extensive subdeltoid bursae I have ever seen, and its cavity communicates directly with a humeroscapular articulation in the region of the deficiency above noted.

Considerable destruction of bone is present in the region of the lesser tuberosity over an area of about 7 sq. cm. Deposition of new bone also has occurred, for this atrophic area is studded with half a dozen bony tubercles from 3 to 6 mm. in diameter and 3 to 4 mm. in height. The superior portion of the capsule, containing the tendon of the supraspinatus, is thickened, and the broad attachment of the latter is displaced downward somewhat. A small closed bursa is located within the thickened capsule itself in the region of fusion of the tendon of the infraspinatus. The cartilage of the humerus is well preserved and appears quite normal, but numerous villi, many of which seem frayed, are located on the under surface of the capsule near its attachment to the superior border of the glenoid cavity. The articular capsule is thickened and fenestrated in its anterior portion near its attachment to the shaft of the humerus directly below the lesser tuberosity. The attachment of the tendon of the long head of the biceps directly distal to the tuberosities is very firm and no remnant of the intra-articular portion could be identified with the unaided eye in cross-sections of the capsule. The cubital, carpal, and the more distal articulations are normal, but the acromioclavicular articulation showed marked bony changes. Both the acromial and clavicular articular surfaces are decidedly roughened and eroded and the cartilage completely destroyed, although the polishing of the acromion is relatively slight.

SPECIMEN 10.—A stage similar to that reported in the preceding specimen is found in the right arm of the same male cadaver, in which all other articulations appear to be normal. In this case also the tendon of the long head of the biceps has secured a firm attachment directly distal to the lesser tuberosity. This attachment is quite comparable to that in the preceding case, and the defects in the capsule also are similar, although somewhat more extensive. The subdeltoid bursa is not so large but the deficiency in the capsule corresponds to more than the anterosuperior half of the head of the humerus. The borders of the capsular defect are thickened, and the dorsal portion receives the displaced tendon of the supraspinatus which has fused firmly with the tendon of the infraspinatus, maintaining however, an attachment to the greater tuberosity although displaced somewhat dorsally. The inferior surface of the acromion shows considerable superficial erosion, which is limited, however, to fraying of the soft tissues. A group of synovial villi is present in the subacromial portion of the subdeltoid bursa, and similar villi also are present on the paraglenoid portion of the articular capsule. The other articulations appear entirely normal and the bony changes seem to be limited to the region of the lesser tuberosity and the intertubercular sulcus. The long head of the biceps is surrounded by the nonadherent synovial sheath for a distance of 5 cm. distal to the tuberosities. This maintains its connection with the joint cavity.

Specimen 11.—This is the left arm of a male subject in which the tendon of the long head of the biceps again is attached immediately distal to the lesser tuberosity as shown in Figure 5. The capsule is deficient in its whole superior extent, its thickened, retracted, dorsal borders containing what seems to be a remnant of the intertubercular portion of the tendon of the long head of the

Fig. 4.—Left arm of a male subject from the front, showing the secondary attachment of the tendon of the long head, the retracted capsule with the tendon of the subscapularis and complete destruction of the superior portion of the capsule. The unusual length of the tendon of the long bicipital head may be noted.

biceps. The thickened portion of the joint capsule is markedly frayed in the region of the greater tuberosity, which is eroded and polished over an area of about 4 sq. cm. As shown in Figure 5, the retracted, thickened anterior portion

of the capsule containing the tendon of the subscapularis has been displaced downward below the level of the head of the humerus. The greater portion of the lesser tuberosity has been destroyed, it being represented by a roughened area to the anterior inferior margin of which the tendon of the subscapularis finds its attachment. The cartilage on the midportion of the humeral head is roughened and almost wholly eroded, but no equivalent area is seen in the glenoid cavity. However, the cartilage is completely eroded near the posterior superior margin of the glenoid cavity and here the underlying bone is polished. This narrow eroded area also extends along the anterior border of the glenoid cavity,

Fig. 5.—Right shoulder joint with the deltoid cut and reflected, showing the point of secondary attachment of the tendon of the long head, the partly occluded intertubercular sulcus and a third head of the biceps obtaining attachment to the tendon of the pectoralis major. Two-thirds natural size.

and inspection of the entire articulation shows that it was contact with this margin that caused the erosion of the cartilage at the most prominent portion of the humeral head. The under surface of the acromion is worn and polished over almost its entire extent, apparently in consequence of contact with a similar, although smaller, area on the greater tuberosity, during a position of extreme abduction. The rest of the joints are normal.

SPECIMEN 12.—A more advanced stage is illustrated by the right arm of a similar subject, a portion of which is represented in Figure 5. As will be noticed, the deltoid has been reflected, and the entire joint cavity has been

laid open. The tendon of the long head of the biceps is attached directly distal to the lesser tuberosity and a third head gains insertion into the tendon of the pectoralis major. The greater tuberosity is considerably eroded and decidedly polished. The under surface of the deltoid is frayed near its acromial attachment as a result of contact with the greater tuberosity. The under surface of the acromion is worn and polished so as to fit exactly a similar area on the greater tuberosity when the arm is placed in a position of hyperabduction and outward rotation. The acromioclavicular ligament and the inferior surface of the capsule of the acromioclavicular joint are entirely destroyed and small areas of the exposed articular surfaces are polished from contact with the head of the humerus and with each other. The capsule of the shoulder joint is destroyed almost completely, only the thickened margin remaining along the anterior border between the region of the coracoid and the acromion. Except for the margin in the region of the tuberosity, the cartilage is present over the entire humeral head and appears quite normal in depth, thickness, and consistency, both over the head of the humerus and in the glenoid cavity.

SPECIMEN 13.—This is represented by the right arm of a male subject and illustrates a still more advanced stage of this condition. As shown in Figure 6, the cartilage over the head of the humerus is very largely eroded; large polished areas are present, and the tuberosities are almost wholly destroyed. The under surface of the acromion again is worn and polished and calcific deposits are present in various portions of the capsule and in the coraco-acromial ligaments. In this case, too, the deltoid acted as the capsule of the joint, and the acromioclavicular joint was laid open in consequence of wear from contact with the greater tuberosity. Almost the entire margin of the glenoid cavity is eroded, but cartilage is present over the rest of the surface. A remnant of the missing tendon of the long head of the biceps possibly may be detected still in the thickened retracted portion of the capsule which hoods the upper half of the glenoid cavity. This remnant of the capsule is interposed between the glenoid cavity and the head of the humerus, which had been elevated against the acromion.

COMMENT

That the disappearance of the tendon in these cases is not due to disuse is fully established by an examination of the same tendons in a case of congenital hydrocephalus in a woman more than 40 years of age. This woman had been partly paralyzed from birth, and although fibrous ankylosis had supervened in the right humeroscapular articulation, thus practically immobilizing this joint, and although the tendon of the biceps was atrophic, it nevertheless could be traced in its entirety although adherent to the joint capsule. It is interesting that it was more difficult to trace this tendon in the left than in the right shoulder joint of this body, although fibrous ankylosis was absent in the latter in which complete erosion of the articular cartilages had taken place and the whole interior surface of the dorsal and inferior portions of the capsule were covered by numerous long and large synovial villi. Except for the complete erosion of the articular cartilages in this joint and the excellent polishing present over the whole of the articular

surfaces, the entire picture was totally different in these two joints from that in those with destruction of the long head of the biceps.

Although erosion, polishing, some eburnation and small exostoses are commonly present in cases of arthritis, these are not the most prominent conditions in the specimens here reported. Next to destruction of the tendon of the long head of the biceps with secondary attachment of the tendon stump distal to the lesser tuberosities, nothing strikes

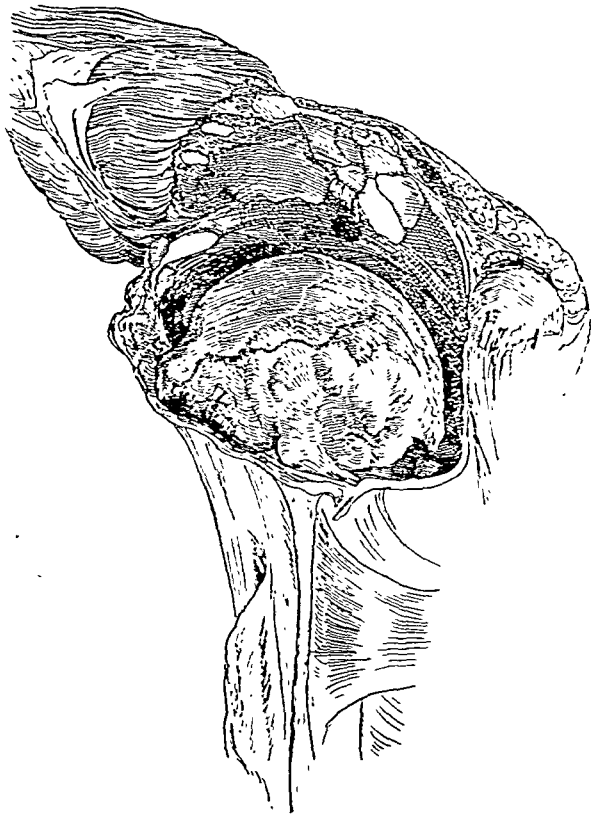

Fig. 6.—Lateral view of right shoulder joint of a male. This shows the most advanced stage of destruction. The deltoid acted as capsule to the joint.

one's attention so forcibly as its total destruction by friction. That friction is very largely if not wholly responsible is indicated by the fraying and fringing of the other soft parts and also by fraying and shredding of the tendon itself. It is surprising and extremely significant that destruction of the tendon can reach a considerable degree in a shoulder joint with cartilages wholly intact and with but a small capsular defect, at a time when the tendon is almost wholly free from adhesion to the capsule.

The first defects in the capsule occur in the region of the tuberosities, and erosion of its external surface often is present in this region alone, although corresponding wear is evident in the soft parts on the inferior surface of the acromion. Since the eroded and polished areas always fit exactly when placed in contact, one cannot doubt that the erosion occurs in a position of marked abduction and external rotation of the arm. This also is the only position in which the under surface of the deltoid in the region of the acromion could become frayed from contact with the greater humeral tuberosity. That the capsular defects always are more pronounced in the region of the latter, even when not wholly confined to it, and that they seem to begin here may be due to folding of the capsule and friction from contact of the greater tuberosity with the acromion, in a position of marked abduction and external rotation of the arm.

Whatever the associated conditions may be, it would seem that these capsular defects result from repeated and long-continued use of the arm in a position of marked abduction and external rotation. This is indicated especially by the antecedent fraying of the soft tissues on the under surface of the acromion with accompanying abrasion in the region of the tuberosities. It would also seem that the irritation and trauma resulting from this friction might bring on a subdeltoid bursitis antecedent to the destruction of this bursa. This unavoidable trauma to the soft parts undoubtedly would also be followed by a protective reaction in the superior portion of the capsule and thus cause thickening of it. However, as soon as the capsule has been worn through near the region of the greater tuberosity, the rough surface of the latter can come in contact with the capsular portion of the tendon of the long head of the biceps and begin its erosion and final destruction.

Although the supposed course of events is merely an inference from the findings in these cases, it quite satisfactorily accounts for all the changes observed, profound though they are. It also accounts for the fact that the pathologic picture in these cases is not wholly comparable to that usually presented in arthritis. The new bone formation, present to some extent in most of these cases, in the region of the tuberosities and in the intertubercular sulcus, may be merely the result of traumatic irritation of the periosteum. Likewise the inflammatory reaction evoked here and in the adjacent soft parts may be responsible for the invariable anchoring of the divided tendon in the region directly distal to the lesser tuberosity.

When the extracapsular lengths of the remaining tendons in cases in which the intracapsular portion was absent were compared with normal tendons, the greater length of the former was very evident. This is noticeable in Figure 4. This increase in length of the tendon between

the muscular portion of the long head and its attachment to the lesser tuberosity may be due in part to atrophy of the muscular belly, but I do not think that this is an important factor. It would seem more probable that the increased length of the extracapsular portion of the tendon is due to retraction in consequence of division near its scapular insertion. However, since this portion of the destroyed tendon not always is longer than the corresponding portion of the normal tendon, it would seem that the tendon sometimes gains attachment in the region of the tuberosity before it is divided, thus limiting the extent of the retraction. This attachment well may result from trauma of the soft parts in this region in consequence of contact with the acromion.

I have not, to be sure, overlooked the possibility of cases of partial congenital absence of the tendon of the long head. Although I have

Fig. 7.—The thickened, trabeculated interbursal septum from the pateliar bursae.

seen but two such cases, they gave me a totally different impression, and I think they may be easily excluded.

The uniformity and the very apparent significance of these findings led me to consider the possibility of an occupational cause, although at first the destruction seemed too extensive to permit of such an assumption. It always had seemed to me that whatever the process responsible for this extensive destruction of the bursa, capsule, tendon and cartilage, it was extra-articular rather than intra-articular. It was because of this fact that I placed an interrogation point in the title of my previous report. The condition did not seem to be primarily arthritic.

It seems possible that long-continued use of the upper extremity in such a posture might easily result in a subdeltoid bursitis, an extension of which to the articulation itself after the production of friction defects in the capsule, easily might complicate the picture; but the arthritic changes always seemed to be of secondary importance. The entire

absence of any evidence of pathologic changes in the spongiosa of the humeri in the first six cases also encouraged me to continue to look for an extra-articular cause. Since the soft tissues on the under surface of the acromion were frayed in many of the cases in which the region of the greater tuberosity also showed slight wear although the capsule and the tendon were wholly preserved, it seemed quite evident that the destructive agent must be friction from contact of the greater tuberosity with the acromion. This was illustrated very well by cases in which this friction had resulted only in slight fraying of the surfaces of contact—the greater tuberosity and the acromion—all else being normal.

Fig. 8.—Subcutaneous and subfascial bursae in the region of the right olecranon, the eroded surface of which forms the base of the deeper bursa. The thickened, cut, reflected trabeculae, especially on the internal surface of the left wall of the superficial bursa, may be noted.

It is somewhat surprising, to be sure, that the thirteen specimens at hand were divided almost equally between right and left arms, for an occupational condition affecting the arms might be expected to affect them approximately in the ratio of right and left handedness. This would cease to be true, however, in all occupations in which no particular skill in the use of the arm is involved, so that the worker could turn from one to the other arm with almost equal facility. Both tendons were destroyed in only one person, and since the arms of two females are included it would seem that several occupations are involved.

I regret exceedingly that it is not possible to verify my explanation from the histories of these cases; but the facts are so unequivocal that I no longer can doubt that the cause of this destruction really is an occupational one.

One might perhaps expect that repair of the tendon would occur or even that such constant use of the arm might result in its hypertrophy. It must be remembered, however, that the posture in which the arm is placed in these movements is rather an abnormal one and that the tendon itself is not subjected to unusual strains but to direct friction from contact with a rather roughened surface which is wholly avoided in the more usual movements of the arm. In a position of extreme abduction and outward rotation, neither tendon nor capsule nor bursa could be expected to show much resistance. Moreover, it is not at all unlikely that tendons have very little regenerative power. This probably would be true especially of such tendons as that of the long head of the biceps which undoubtedly has a relatively poor blood supply. Since none of the twelve shoulders in which the tendon had been destroyed completely contained abrasion products, these apparently are absorbed. I am at a loss to know what the digestive agent is; but the problem is no greater than in cases of abrasion products in connection with erosion of the articular cartilages.

The destruction of the subdeltoid bursa and the joint capsule in these cases reminds one strongly of cases of "housemaid's knee" and "miner's elbow," in which the dense fascial wall between the subcutaneous and subfascial bursae not rarely are shredded from wear, as represented in Figure 6, a photograph of the intervening septum from the patellar region. This septum often is thickened decidedly as well as completely fenestrated, or even trabeculated, and it does not seem improbable that it might ultimately be destroyed completely.

There usually is only one subcutaneous bursa in the region of the olecranon. Rarely, however, two bursae, a superficial and a deep, are located here, wholly comparable to those usually present in the patellar region. The wall of the superficial bursa over the olecranon invariably is thickened when a subfascial bursa is present. This is particularly true of the interbursal septum since the deep fascia over the olecranon is relatively thin. It is evident that long continued use apparently results in extraordinary thickening of it, for it not rarely is 3 mm. thick. In two instances recently observed, these thick interbursal septums, which very evidently must have developed from the deep fascia in response to use, had become fenestrated and were densely fibrous, almost cartilaginous in character. Trabeculae of dense connective tissue also were contained on the inner surface of the bursal walls and in both these cases the olecranon was devoid of periosteum over its

most prominent portion, hence a part of the base of the deeper bursa was formed by bare bone. The size of these bursae alone indicates that there must have been considerable irritation and effusion; but it seems rather surprising that overuse, which results in thickening of the walls, the formation of a deeper bursa and greater thickening of the interbursal septum, also may result in destruction of the septum of the periosteum and erosion of the underlying bone. In both these cases fenestrae and trabeculae were found in the thickened wall between the two bursae, and the condition here was entirely comparable to what one not infrequently finds in the patellar region.

RECURRENCE OF CALCULI IN COMMON AND HEPATIC DUCTS AFTER CHOLECYSTECTOMY *

GEORGE EMERSON BREWER, M.D.
NEW YORK

When one is invited to read an article or to present some topic of professional interest before a medical society, the choice of a subject is often dependent to some extent on the character of the audience. Thus, if one wishes to announce some new or epoch-making discovery, to place on record some valuable, but hitherto unknown, therapeutic measure, to describe some novel and highly successful operation or surgical procedure for the relief or cure of some malady which had hitherto been regarded as hopeless, one is apt to select a large gathering of his professional colleagues, such as one of the great national associations or international congresses, so that the benefit of his discovery or clinical experience may quickly reach the largest number of his professional brethren and through them promptly be handed on to suffering humanity. If, on the other hand, one is anxious to obtain enlightenment on some knotty clinical problem, or seeks to learn from the experience of others how some failure or mistake may be avoided in the future, he generally seeks a smaller body, made up of men whose experience has been greater than his own and in whose judgment and skill he has confidence.

On the only other occasion that I was privileged to address this society, I presented a report on a small, but interesting, group of cases of hemolytic jaundice, in the hope that I might learn from the discussion something more in regard to the nature of this unusual pathologic condition than I had been able to glean from a rather hasty and incomplete review of the literature.

The result in that instance was so satisfactory that I have elected, this evening, to present another group of cases in which jaundice of another and commoner type is one of the chief factors; and I am looking forward with confidence to obtaining from your discussion helpful suggestions which will be of service to me in any future cases I may encounter.

During the last twenty-five years, I have had under my care for operative treatment five cases of obstructive jaundice due to calculus in the common or hepatic ducts, in which previous operative procedures

* Read before the Practitioner's Medical Society of New York, May 12, 1920.

for cholelithiasis had been carried out, including removal of the gallbladder.

That cases belonging to this group are rare is evidenced by the scanty references to them in the standard treatises on diseases of the biliary passages; and by the fact that in several recent communications on the subject of recurrences, by Deaver, Judd and others, the small number of recurrences of stone in the duct after cholecystectomy is in striking contrast to the larger number following cholecystostomy.

REPORT OF CASES

CASE 1.—A woman, aged 60, had submitted to an operation for cholelithiasis performed by one of America's most distinguished surgeons. The gallbladder containing calculi was removed. My meager records do not state whether or not the duct was opened at that time; but from my knowledge of the wisdom, judgment and skill of the operator, I am satisfied that the palpable ducts were free from calculi at the time of operation.

Nine months later, the patient consulted me, complaining of intermittent attacks of pain and slight jaundice. The duct area was exposed, the common and hepatic ducts were found moderately dilated, but showed no other pathologic condition, and were palpated with a negative result. The common duct was opened by a longitudinal incision and a probe was passed easily and without obstruction to the duodenum. The hepatic ducts were next explored; and in the right duct, about three-quarters inch above its entrance into the liver substance, the probe touched a calculus. Attempts to remove the calculus by means of curved forceps were unsuccessful as the blades could not be opened sufficiently wide through the narrow duct to grasp the stone. Then followed a slow and careful dilation of the duct by forceps and the finger, which, much to my surprise, was accomplished without difficulty. When I was finally able to insert my forefinger and touch the calculus, it was found to occupy a dilated pouch fully as large as an English walnut. After further forcible dilation and rupture or incision of the duct, I was able to extract the largest stone I have ever encountered in the duct system of a patient. It measured more than 3 cm. in its greatest diameter, was irregularly cuboidal in shape, black, and when thoroughly dried was exceedingly light in weight and resembled pumice stone in structure: a typical bilirubin-calcium stone, which forms only in the ducts. Drainage by means of a rubber tube was introduced to the intrahepatic pouch, and the patient made an uninterrupted recovery.

Two years later she reported that she was well, never having suffered from a recurrence of symptoms.

CASE 2.—A married woman, aged 50, referred to me by the late Dr. Roswell Park of Buffalo, gave a history of recurrent attacks of colic of the upper abdomen without jaundice, of many years' duration. During the last two or three years, in addition to the colic, there had been associated symptoms of infection, with tenderness and muscular rigidity over the gallbladder area. At operation, shortly after one of these attacks of cholecystitis, the gallbladder was found to be injected, moderately distended, thickened and edematous; and through its walls could be palpated a number of stones, the largest being impacted in the ampulla at the origin of the cystic duct. The gallbladder was removed unopened, the ducts palpated, and as no sign of calculus, dilatation,

or other lesion was demonstrated, the wound was closed with a small cigaret drain. She made a prompt recovery and remained free from symptoms for more than two years.

Then she began to have attacks of epigastric pain with transitory jaundice, but without fever or other evidences of infection. In November, 1911, she was again admitted to the hospital, and at operation the common duct was found to be greatly dilated and a large, round calculus was easily palpated in its lower segment. The common duct was freely opened, the stone extracted, and the ducts easily explored by the finger and probe well within the liver to the point of branching. Drainage of the hepatic duct by means of a rubber tube was instituted, and the abdominal wound was closed by layer suture. Drainage was continued until the bile appeared clear and golden brown, when the tube was removed and the wound allowed to close. The calculus in this instance was oval, black, nonfaceted, with a mulberry surface. It measured 1.5 by 1 cm. in its two diameters. It was of the type of single stone frequently found in the duct, and at the time I was convinced that it had originated in the duct system after my previous operation.

Case 3.—A married woman, aged 60, in March, 1911, underwent an operation in Brooklyn for cholelithiasis, which consisted in opening the gallbladder, removing the stones and closing the wound with drainage. This was followed by recurrent abscesses, and a sinus which persisted for many months.

In October, 1912, cholecystectomy, with removal of stones from the common duct was performed by Dr. Hartley. The patient remained well for eighteen months, when there was a recurrence of symptoms: colic and intermittent jaundice at first, later progressive icterus with clay-colored stools, intense itching, fever, and rapid loss of flesh and strength.

She was admitted to my service at the Roosevelt Hospital with a temperature of 101 F. At operation, the duct was found to be widely dilated; several large, dark brown stones were removed, and the common and hepatic ducts were explored with the finger and probe from the duodenal orifice to points in both hepatic branches well within the liver substance. Tube drainage of the duct was instituted. Normal convalescence followed, with complete disappearance of symptoms and rapid gain in weight. She remained well for eight months.

There then occurred dull pains in the epigastrium of short duration; on one occasion extending to the back and right scapular region. This, however, caused little inconvenience until the latter part of 1915, when she had a series of attacks of sharp colic with transitory jaundice, finally eventuating in a severe attack with chills, fever, and a rapidly deepening icterus. She delayed operation for some weeks in the hope of spontaneous relief, but was finally admitted to my service at the Presbyterian Hospital. In January, 1916, she was again anesthetized and a fourth operation was performed. Owing to the presence of dense adhesions over the entire upper abdominal area, the technical difficulties were considerable. I finally succeeded in exposing the common duct which was greatly dilated, resembling a misplaced gallbladder. This was incised and a large amount of dark brown, foul-smelling fluid evacuated, together with seven soft, brown gallstones, three of which were found high up in the hepatic ducts, well within the liver. Digital palpation of the ducts was followed by irrigation, and the insertion of a rubber drainage tube in the hepatic duct. Drainage was continued for several weeks. She made a slow but satisfactory convalescence. Cultures made at the time of operation gave a gram-positive bacillus. Later cultures showed a colon infection. From the odor of the duct secretion at the time of operation, it is probable that *B. coli*

was present from the first. Autogenous vaccines were made from the cultures and administered for several weeks after she left the hospital by Dr. George Draper, who was called in to study the case and prescribe measures to prevent a recurrence.[1]

CASE 4.—A middle-aged man had been operated on by the late Dr. O. C. Smith of Hartford for a series of attacks characterized by colic, jaundice, chills and fever. The gallbladder was removed and the ducts explored. The patient remained well for twenty months, when there was a recurrence of symptoms, with pain, jaundice, fever and clay-colored stools. These symptoms promptly disappeared; and one year later, he experienced another similar attack which also disappeared without treatment. Six months before admission to the Presbyterian Hospital he began to have frequent mild attacks with jaundice, which never completely disappeared. At operation the duct was found moderately dilated, but palpation revealed no foreign body. The duct was opened and explored with the finger and probe with a negative result. The hepatic ducts within the liver were irrigated with a small catheter, and eight or ten small faceted, yellow stones were washed out from a point high up within the liver substance. Drainage of the hepatic duct was instituted, and the abdominal wound closed in the usual manner. Prompt recovery followed. A letter received four years later stated that he had experienced no return of symptoms.

CASE 5.—A woman, aged 64, consulted me in March, 1915. There was a history of attacks of acute abdominal pain of many years' duration. At first these, thought to be due to indigestion, were apparently of short duration and were relieved by catharsis. Later the attacks became more severe, required more or less prolonged rest in bed, and at times were accompanied by a transitory jaundice.

The present attack began six days before my first visit, with severe abdominal pain, tenderness, nausea, vomiting, fever and increasing prostration. On examination, the abdomen was found to be distended. There was generalized tenderness and marked muscular spasm over the right half. The point of most acute tenderness was midway between the appendix and the gallbladder areas. The temperature was 103.5 F.; the pulse, 120. She was immediately removed to the Roosevelt Hospital, and at operation a gangrenous, ruptured appendix was found with spreading peritonitis. The gallbladder region was not explored; and as her condition was critical, after the removal of the appendix, the abdomen was quickly sutured with adequate drainage. The operation was followed by a stormy convalescence with long-continued drainage. Six weeks later, after the abdominal wound had closed, but before she had left her bed.

---

1. Since this was written, I have received a communication stating that this patient remained well for eighteen months after my last operation. She then had a renewal of attacks, and was operated on for the fifth time by a colleague, and two or three stones were removed from the duct. She apparently remained well for about a year. During the summer of 1919, she began taking probilin pills—a phenolphthalein-containing nostrum—and on the third day she had another attack of acute abdominal pain exactly similar to those she had had in the past. The pills were omitted and the attack subsided. Later the pills were again resumed, and another attack occurred. She then had a roentgenologic examination made of her teeth, and as a result of the findings, had nine teeth extracted in November last. She has had no attacks since that time.

there occurred another attack of acute epigastric pain with nausea and vomiting, followed by fever and jaundice on the second day. As the symptoms were progressive, a second operation was undertaken. The gallbladder was acutely red, edematous and covered with fibrin. On palpation, numerous large and small stones were felt within its cavity. The common duct was dilated and one large oval calculus was palpated in its lower segment. The gallbladder was removed, the common duct incised, and one large and two small calculi were removed. The ducts were thoroughly explored with the finger and probe, and the incision was partly sutured with drainage of the hepatic duct. The following day the temperature reached 101 F., and from that time gradually fell to normal. The convalescence was rapid and satisfactory, and she left the hospital in excellent condition.

She remained well for four years, ate heartily, gained weight, and considered herself thoroughly cured. In the summer of 1919, however, she again began to experience attacks of epigastric pain of short duration, occurring at irregular intervals, but relieved by rest and mild catharsis. In September, I was again called in consultation during one of these attacks. On examination, I found tenderness with slight muscular spasm in the epigastric region, and slight but definite jaundice and no fever. I urged her to enter the hospital again for further observation. This she refused. The attacks continued, gradually increasing in severity, and requiring increasing doses of morphin for their relief. Three weeks later, I saw her again and gave the same advice, but she again refused to enter the hospital. Three months later, I was again called, and found that her condition was much worse. She had just passed through a severe attack requiring much morphin, and the condition was complicated by definite evidences of impaired renal function.

She was finally admitted to the hospital, and on examination the blood pressure was found to be 95-55. The urinary output on the first day was 12 ounces, and on the succeeding day 20. The urine contained albumin and casts. Blood examination revealed: nonprotein nitrogen, 97.50; urea nitrogen, 50.40; creatinin, 2.30; uric acid, 3.40; sugar, 0.098, and carbon dioxid, 60.30. The blood coagulation time was fourteen minutes. She was given water in large quantities, restricted diet, and hot air baths. For several days she was somewhat apathetic, complained of headache, nausea, and occasionally she vomited. The jaundice diminished, but never entirely disappeared. The urine gradually increased to 40 ounces during the following week, and January 9, the report showed nonprotein nitrogen, 47.80; urea nitrogen, 25; creatinin, 1.60; uric acid, 3, and sugar, 0.08. The following two days the amount of urine collected was 18 and 17 ounces, respectively. She then experienced another severe attack of pain, with nausea, vomiting, fever and increased jaundice. The pain was very severe, but as we dared not give her morphin, after consultation we decided to take a desperate chance and operate.

Every effort was made to insure speed of operation, but the adhesions were very extensive, and were separated with great difficulty. The duct was finally exposed. It was found to be much dilated, a stone was palpated and removed through a longitudinal incision. The ducts were thoroughly explored without detecting other calculi. Drainage of the hepatic duct was instituted. The operative shock was not grave; but the day following there was a total suppression of urine, only 2 drams being recovered by catheter. On the second day, the output was half an ounce, and on succeeding days it was 1½, 2, 17, 25, 22, 20½ and 27 ounces. During this period, she was having colon irrigations, cupping, hot packs, intravenous infusions, digitalis, and various other

renal stimulants. There was little postoperative abdominal discomfort. The drainage was abundant. Gas passed freely on the second day, and the bowels moved satisfactorily on the fourth. Sutures were removed on the seventh day. On the ninth day, following the voiding of 27 ounces of urine, she had an attack of cardiac weakness, the excretion of urine ceased entirely, and she died in coma.

The outcome in this case was disappointing as the wound had healed, the drainage tube having been removed two days before, and bile was abundantly present in the stools. It was not, however, unexpected, as I had explained to her family that she had a slight chance of recovery, which would be reduced to zero if the operation was long, more than forty minutes. The actual time of operation, in spite of all our efforts to accelerate it, was more than an hour. It may be that the decision to operate when we did was unwise but to attempt to carry her through another severe attack with the necessary relief from pain by morphin seemed at the time to be hopeless.

COMMENT

It may fairly be assumed that in Case 1 the calculus was probably present in the duct from the beginning, and did not form around an overlooked stone which had migrated to the duct from the gallbladder.

In the second case, the absence of jaundice prior to the first operation, the normal appearance of the duct, and the absence of any evidence of calculus by careful palpation, together with the comparative long interval which elapsed before the second group of symptoms appeared, and the fact that the stone was round, nonfaceted, black and soft, a typical bilirubin-calcium stone, would lead one to regard it as a concretion formed in the duct. On the other hand, these stones are exceedingly rare in uninfected ducts, and the origin of this calculus must be regarded as uncertain.

In Case 3, the duct had already contained one or more calculi, and was therefore presumably infected, conditions favorable for the subsequent formation of duct stones. While it is quite possible that stones hidden in one of the hepatic branches might have been overlooked in any or all of the operations, it is equally possible that the stones formed in the duct between operations, as all conditions favoring calculus formation were present, and as the ducts were widely dilated and easily permitted careful digital exploration.

In Case 4, the character of the stones and their lodgment in the intrahepatic ducts strongly suggest their duct origin. In fact, Beer reports a case in which at necropsy he found a number of small, yellow, faceted stones embedded in one of the smaller intrahepatic ducts, exactly similar to those removed in this case.

In the last case, it is quite probable that a stone might have been overlooked at the second operation, as the condition of the patient at operation was such as to render the expenditure of much time inad-

visable; but the four years of entire freedom from symptoms would make one hesitate to affirm it.

It is perhaps unfortunate that no sections were made of any of the stones removed from the ducts in this series of cases and examined chemically, for the result of such investigation might have thrown some light on their probable origin.

It is now generally recognized that stones formed in the gallbladder generally contain a high percentage of cholesterin, in most cases combined with bilirubin and biliverdin calcium compounds; that they are polished, faceted, and that they vary in color from a light gray or yellow to dark brown or black; the pure cholesterin, the laminated cholesterin or the typical bilirubin-calcium stones being comparatively rare.

On the other hand, calculi formed in the ducts are almost invariably of the bilirubin-calcium type, containing a low percentage of cholesterin; are rarely polished or faceted, and are irregular in shape, black and friable. One of the rarest varieties of duct stone is the small yellow faceted stone formed in the smaller intrahepatic ducts, often in considerable numbers, as in Case 4 and in the case mentioned by Beer.

The finding of a typical gallbladder stone in the duct, or an irregularly shaped, black, friable stone, with a nucleus showing the characteristics of a typical cholesterin stone, would indicate that the duct exploration at the primary operation had been incomplete; as after removal of the gallbladder, no such stone could have migrated to the duct or could have had its origin in the duct system.

If, on the other hand, the examination of the stone demonstrated it to be of the bilirubin-calcium variety, it would by no means prove that it, also, was not an overlooked stone, as such stones of intrahepatic origin are not uncommon in infected ducts which have been dilated by the previous presence of calculi.

It is, therefore, quite useless to speculate further on the question as to the exact origin of these stones, and to admit freely that in three of the cases it is quite possible that the stones removed may have been formed around overlooked stones or fragments present in the duct at the primary operation.

The important question is, what can be done to avoid recurrences in this class of cases?

Unquestionably, early operation, so often emphasized by Deaver and other surgeons of large experience, is highly important, as practically all biliary calculi, with the possible exception of the so-called pure crystalline cholesterin stone, are due primarly to infection. Surgical removal, therefore, at an early period, before advanced or permanent inflammatory changes have occurred in the gallbladder and ducts.

renal stimulants. There was little postoperative abdominal discomfort. The drainage was abundant. Gas passed freely on the second day, and the bowels moved satisfactorily on the fourth. Sutures were removed on the seventh day. On the ninth day, following the voiding of 27 ounces of urine, she had an attack of cardiac weakness, the excretion of urine ceased entirely, and she died in coma.

The outcome in this case was disappointing as the wound had healed, the drainage tube having been removed two days before, and bile was abundantly present in the stools. It was not, however, unexpected, as I had explained to her family that she had a slight chance of recovery, which would be reduced to zero if the operation was long, more than forty minutes. The actual time of operation, in spite of all our efforts to accelerate it, was more than an hour. It may be that the decision to operate when we did was unwise but to attempt to carry her through another severe attack with the necessary relief from pain by morphin seemed at the time to be hopeless.

COMMENT

It may fairly be assumed that in Case 1 the calculus was probably present in the duct from the beginning, and did not form around an overlooked stone which had migrated to the duct from the gallbladder.

In the second case, the absence of jaundice prior to the first operation, the normal appearance of the duct, and the absence of any evidence of calculus by careful palpation, together with the comparative long interval which elapsed before the second group of symptoms appeared, and the fact that the stone was round, nonfaceted, black and soft, a typical bilirubin-calcium stone, would lead one to regard it as a concretion formed in the duct. On the other hand, these stones are exceedingly rare in uninfected ducts, and the origin of this calculus must be regarded as uncertain.

In Case 3, the duct had already contained one or more calculi, and was therefore presumably infected, conditions favorable for the subsequent formation of duct stones. While it is quite possible that stones hidden in one of the hepatic branches might have been overlooked in any or all of the operations, it is equally possible that the stones formed in the duct between operations, as all conditions favoring calculus formation were present, and as the ducts were widely dilated and easily permitted careful digital exploration.

In Case 4, the character of the stones and their lodgment in the intrahepatic ducts strongly suggest their duct origin. In fact, Beer reports a case in which at necropsy he found a number of small, yellow, faceted stones embedded in one of the smaller intrahepatic ducts, exactly similar to those removed in this case.

In the last case, it is quite probable that a stone might have been overlooked at the second operation, as the condition of the patient at operation was such as to render the expenditure of much time inad-

visable; but the four years of entire freedom from symptoms would make one hesitate to affirm it.

It is perhaps unfortunate that no sections were made of any of the stones removed from the ducts in this series of cases and examined chemically, for the result of such investigation might have thrown some light on their probable origin.

It is now generally recognized that stones formed in the gallbladder generally contain a high percentage of cholesterin, in most cases combined with bilirubin and biliverdin calcium compounds; that they are polished, faceted, and that they vary in color from a light gray or yellow to dark brown or black; the pure cholesterin, the laminated cholesterin or the typical bilirubin-calcium stones being comparatively rare.

On the other hand, calculi formed in the ducts are almost invariably of the bilirubin-calcium type, containing a low percentage of cholesterin; are rarely polished or faceted, and are irregular in shape, black and friable. One of the rarest varieties of duct stone is the small yellow faceted stone formed in the smaller intrahepatic ducts, often in considerable numbers, as in Case 4 and in the case mentioned by Beer.

The finding of a typical gallbladder stone in the duct, or an irregularly shaped, black, friable stone, with a nucleus showing the characteristics of a typical cholesterin stone, would indicate that the duct exploration at the primary operation had been incomplete; as after removal of the gallbladder, no such stone could have migrated to the duct or could have had its origin in the duct system.

If, on the other hand, the examination of the stone demonstrated it to be of the bilirubin-calcium variety, it would by no means prove that it, also, was not an overlooked stone, as such stones of intrahepatic origin are not uncommon in infected ducts which have been dilated by the previous presence of calculi.

It is, therefore, quite useless to speculate further on the question as to the exact origin of these stones, and to admit freely that in three of the cases it is quite possible that the stones removed may have been formed around overlooked stones or fragments present in the duct at the primary operation.

The important question is, what can be done to avoid recurrences in this class of cases?

Unquestionably, early operation, so often emphasized by Deaver and other surgeons of large experience, is highly important, as practically all biliary calculi, with the possible exception of the so-called pure crystalline cholesterin stone, are due primarly to infection. Surgical removal, therefore, at an early period, before advanced or permanent inflammatory changes have occurred in the gallbladder and ducts.

is to be recommended. Thoroughness in exploration of the ducts with the finger, probe, and by irrigation at the time of the primary operation, is also of prime importance, for I believe we will all admit that a very large number, if not the majority, of duct recurrences, are due to the presence of overlooked stones or fragments.

It must be recognized, however, that even the most thorough search of the biliary passages by the most skilled operator may fail to reveal the presence of calculi lodged in a small branch of the duct system in the liver substance. Moreover, a floating stone once palpated in the unopened common duct may be aspirated or forced upward into the liver ducts by digital pressure. If the duodenal orifice of the duct is obstructed, the suggestion of Gerster, that in such cases the duct should be palpated only after it has been incised, is a logical one. Equally important in my opinion is prolonged and free drainage of the duct after operation. This, as in other infected cavities, removes pressure, allows the free escape of infected fluid, and favors Nature's process of repair, which in the last analysis is the one most important factor in recovering from any infection.

THE RÔLE OF THE URETERAL LYMPHATICS IN EXPERIMENTAL URINARY TRACT INFECTIONS *

VERNON C. DAVID, M.D., AND PETER M. MATTILL, M.D.
CHICAGO

In a previous article [1] the results of an experimental study to determine the routes by which infection could ascend from the bladder and involve the upper urinary tract were published. In that article these statements were made:

1. In experimental *B. coli* cystitis in dogs, blood stream infection rarely takes place.

2. Without stasis of urine, involvement of the upper urinary tract is rare.

3. With slight obstruction to complete emptying of the bladder, extension of infection to the upper urinary tract practically always occurs.

4. The involvement of the upper urinary tract almost uniformly takes place through the lumen of the ureter, and the ureteral lymphatics are rarely, if ever, the pathway of infection.

Since some of these statements are at variance with the reports of other workers on the same, or correlated, subjects, further evidence will be presented bearing on the rôle of the ureteral lymphatics as a pathway for infection involving the urinary tract.

URETERAL LYMPHATICS AS A PATHWAY FOR INFECTION WITHIN THE URINARY TRACT

Eisendrath and Schultz [2] described round-cell infiltration in the ureteral lymphatics after injecting *B. coli* into the bladder. Bauereisen [3] described the same findings in tuberculosis of the bladder. Stewart [4] explained the kidney infections following implantation of

* From the Surgical Department, Rush Medical College, and the Otho S. A. Sprague Memorial Institute, Children's Memorial Hospital.

1. David, Vernon: Ascending Urinary Infections, Surg., Gynec. & Obst. **26**:159 (Feb.) 1918.

2. Eisendrath and Schultz: The Path of Involvement in Ascending Infections of the Urinary Tract, J. M. Research **35**:295, 1917.

3. Bauereisen, A.: Beitrag zur Frage der aszendierenden Nierentuberkulose, Ztschr. f. gynäk. Urol. **2**:132, 1910.

4. Stewart, L. F.: A Study of Ascending Infection of the Kidney Carried Out by the Transplantation of the Ureters Into the Intestines, Univ. of Penn. M. Bull. **23**:233, 1910-1911.

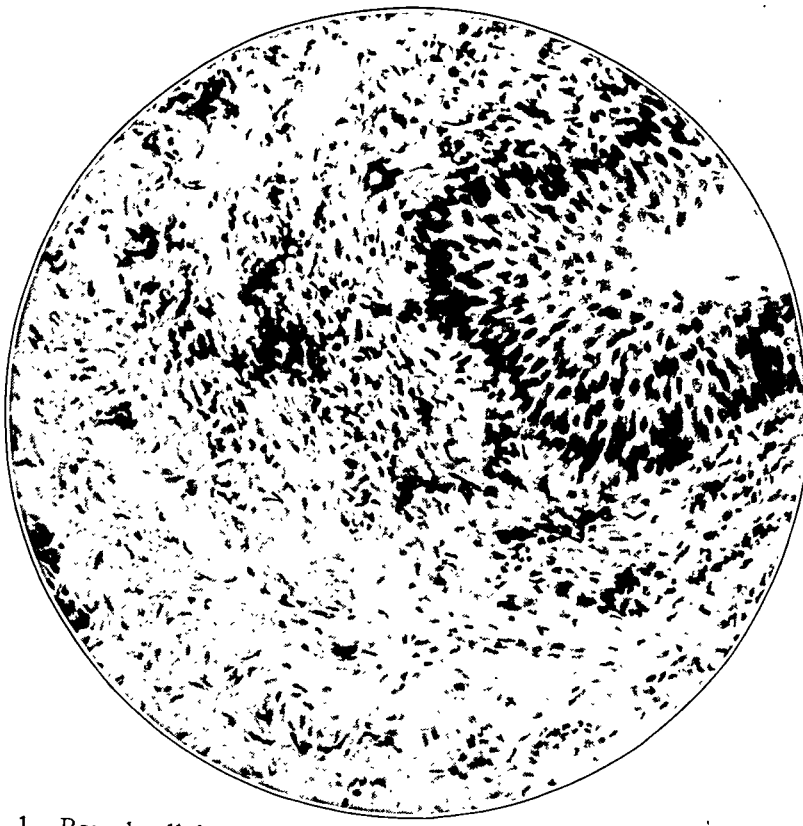

Fig. 1.—Round-cell infiltration in submucosa of ureter of control dog with sterile urine; × 230.

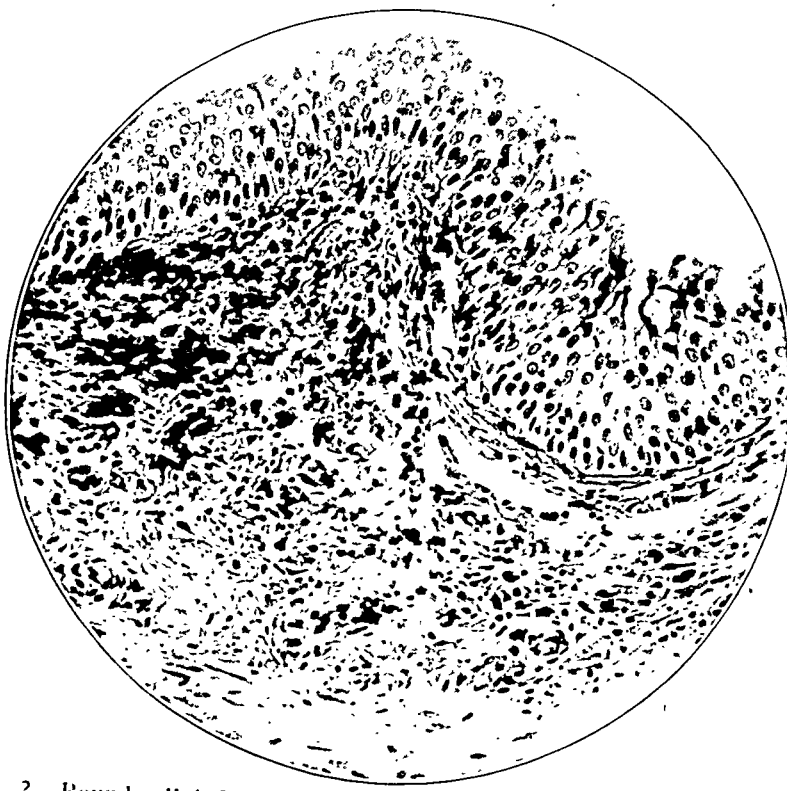

Fig. 2.—Round-cell infiltration in submucosa of ureter of control dog with sterile urine; × 230.

the ureters into the intestinal tract on the basis of an ascending infection through the lymphatics of the ureter. Franke [5] injected lymphatics running from the cecum and ascending colon to the kidney capsule and kidney pelvis. Helmholz and Beeler [6] injected cultures of a virulent organism, found in a rabbit kidney, into the bladders of a series of rabbits. They found pyelitis in fifteen of the animals, but there was evidence of cellular exudate in the ureteral lymphatics in only five. They concluded from this evidence that in some instances

Fig. 3.—Round-cell infiltration of the submucosa of the ureter; sterile cultures from the lumen of the ureter as well as from the macerated ureter; × 60.

the infection ascended by way of the ureteral lymphatics and in others through the lumen of the ureters. In another series of experiments on sixty-six rabbits, organisms of the *B. coli* group were injected intravenously, and pyelitis was found in only two animals. In some

5. Franke: Aetiologie der Coli-Infektionen, Arch. f. Anat. u. Physiol., 1910, p. 191. Ueber die Coliinfektionen der Harnwege. Berl. klin. Wchnschr. **48**: 1973, 1911.

6. Helmholz and Beeler: Infection of the Urinary Tract. Tr. Am. Pediat. Soc. **30**:195, 1918.

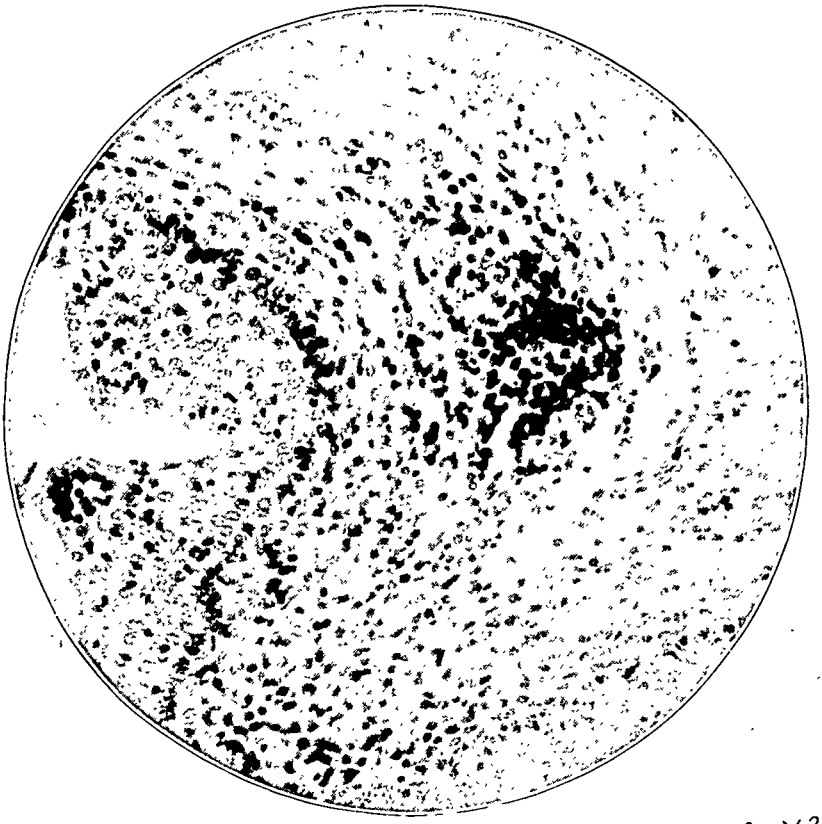

Fig. 4.—Round-cell character of infiltrate shown in Figure 3; ×230.



Fig. 5—Bladder submucosa with polymorphonuclear infiltrate; ×130.

of the experiments a polymorphonuclear exudate was found in the subpelvic lymphatics.

Elaborate studies of the lymphatics of the bladder, ureters and kidney have been made by injection of the lymphatics with silver salts and Prussian blue (Mascagni, Teichman, Sappey, Krause, Gerota, Kumita, Stahr, Sakata). There is no doubt that a rather rich lymphatic system is found in the submucosa and muscularis of the bladder and ureter as well as in the periureteral fat, in the kidney

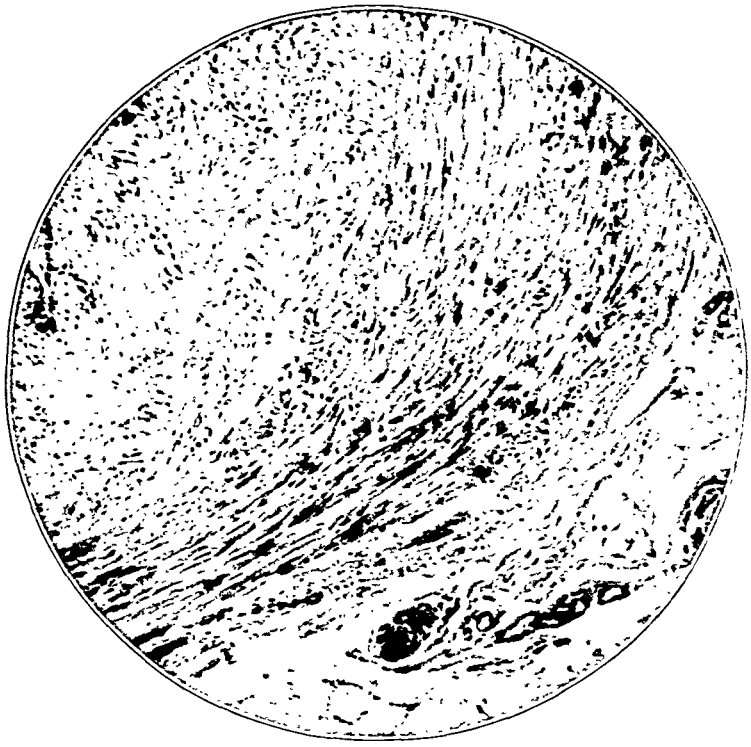

Fig. 6.—Ureter with no cellular infiltrate; × 130.

pelvis, in the parenchyma of the kidney and its fatty capsule. The lymphatics of the bladder, ureter and kidney have distinct communicating branches, but it is equally important to emphasize the fact that the drainage of the bladder, ureter and kidney is segmental into lumbar and hypogastric nodes and into the nodes along the renal vessels. The ready flow of lymph is not from the bladder through the ureter to the kidney, or vice versa.

Having established the premise that these organs have definite lymphatic systems and that involvement of them by inflammatory exudate has been described by several authors, we will herewith pre-

Fig. 7.—Kidney pelvis with no cellular infiltrate; × 130.



Fig. 8.- Polymorphonuclear exudate on peritoneal coat of the bladder; × 230.

sent our evidence to demonstrate that the occurrence of a cellular exudate in the lymphatics of the ureter and pelvis of the kidney does not necessarily indicate an infection of the urinary stream.

1. *Round-Cell Infiltration in Control Ureters with Sterile Urine.*—Control sections of the ureter in thirty-nine dogs have been studied microscopically, and at the same time the urine has been examined for bacteria by smears and cultures. Cellular infiltration in the lymphatics was absent in fourteen dogs, was present to a limited extent

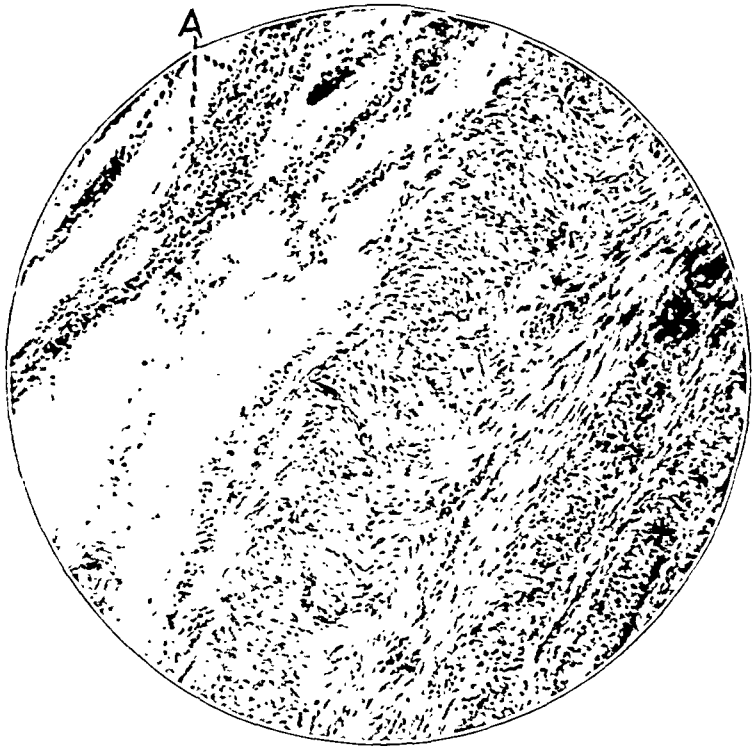

Fig. 9.—Ureter, showing periureteral exudate at *A*; ×90.

in ten, and in five dogs with sterile urine was present to a marked degree (Figs. 1 and 2). In rabbits the presence of round-cell infiltration in the ureter with sterile urine is even more common.

2. *Round-Cell Infiltration of the Ureter with Sterile Urine. Macerated Ureter Sterile.*—*B. coli* was injected into a dog's bladder, and the dog killed in thirty days. *B. coli* was still present in the bladder urine, but cultures from the ureters and kidney pelves were sterile. Microscopic examination of the tissue revealed a marked round-cell infiltration in the submucosa of the bladder and ureters (Figs. 3 and

4). A section of the ureter, which had been removed under aseptic conditions, was macerated in a sterile mortar, and cultures were made of the tissue extract. These were sterile. This experiment indicates that round-cell infiltration of the ureter is not synonymous with urinary stream infection, and that the presence of round-cell infiltration is not necessarily indicative of active infection.

3. *Ulcerative Cystitis with Ascending Ureteral Infection, but No Infection of the Ureteral Lymphatics or the Blood Stream.*—A num-

Fig. 10.—Polymorphonuclear type of exudate at *A* (Fig. 9); ×230.

ber of experiments on dogs were thus conducted: One ureter was ligated and divided to establish a hydronephrosis which acted as a control on blood stream infection, in which event it became converted into a pyonephrosis; the urethra was partially constricted by a band of fascia, but not sufficiently to prevent urination. *B. coli* was injected into the partially obstructed bladder; ulcerative cystitis developed with ascending infection involving the unobstructed ureter, from which *B. coli* was grown. Microscopically there was no cellular infiltration of any type in the ureteral wall though the bladder wall had a dense polymorphonuclear exudate throughout (Figs. 5, 6 and 7).

It is evident in these experiments that polymorphonuclear infiltration of the bladder does not extend to the lymphatics of the ureter and kidney pelvis with any rapidity, though ascending infection occurs early and readily through the lumen of the ureter.

4. *Cut End of Ligated Ureter Adherent to Infectious Material. Polymorphonuclear Infiltrate of the Periureteral Lymphatics. Hydronephrosis, Sterile.*—A few "happenchance" conditions arose in some experimental work which have a bearing on this problem. After liga-



Fig. 11.—Polymorphonuclear exudate in submucosa of kidney pelvis: × 130.

tion and division of one ureter, some dogs came to necropsy with the peritoneal coat of the bladder covered with a plastic exudate due to accidental infection. To this exudate, the cut end of the ligated ureter was adherent. A microscopic study of the ureter demonstrated a rather marked polymorphonuclear exudate in the periureteral tissue reaching above the ureter to the subpelvic fat. However, in these particular experiments the hydronephrosis that developed above the divided ureter was sterile. A periureteral polymorphonuclear exudate with sterile urine was present (Figs. 8, 9, 10 and 11).

With these experiments in mind it seems clear that involvement of the periureteral lymphatics in round-cell or polymorphonuclear cell infiltration is not synonymous with urinary stream infection. Conversely, urinary tract infection occurs, ascending through the lumen of the ureters without involvement of the ureteral lymphatics.

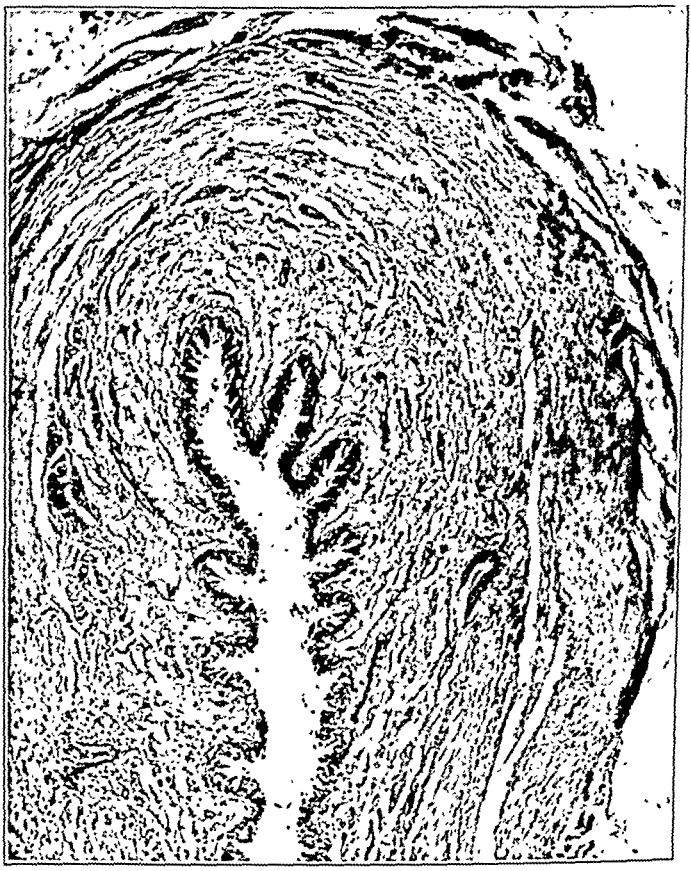

Fig. 12.—Ureter above the gauze showing no infiltrate; × about 70.

URETERAL LYMPHATICS AS A ROUTE FOR EXTRA-URINARY INFECTIONS

The rôle of the lymphatics in conveying infection from the bladder to the ureters and kidneys has thus far been the object of our study. As a corollary, the importance of the ureteral lymphatics in conveying extra-urinary infections to the kidney will be considered.

It is theoretically possible in cases of pyosalpinx, pelvic peritonitis, acute appendicitis or appendiceal abscess that an inflammatory exudate coming in contact with a ureter might involve the periureteral lymphatics of the ureter and eventually spread along them and involve the pelvis of the kidney and kidney itself. This view has been

strongly urged by certain authors to explain the frequency of pyelitis in girl babies whose vaginal secretions have been found to contain *B. coli* soon after birth. In order to consider experimentally these presumptions, the effect of surrounding the ureter in a series of dogs and rabbits with a small piece of gauze impregnated with

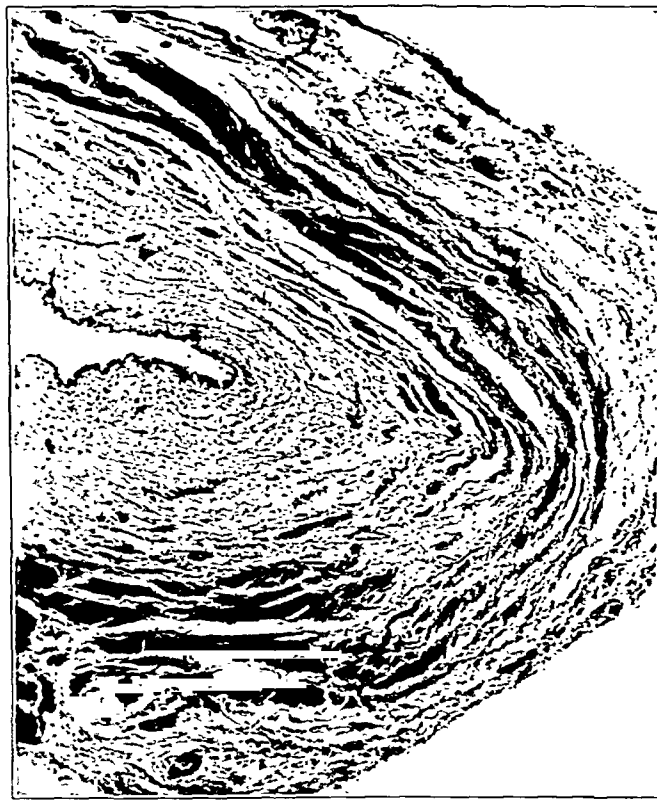

Fig. 13.—Kidney pelvis above the gauze showing no infiltrate; × about 70.

actively growing *B. coli* was studied. This simulates fairly well clinical conditions in which the ureter is in contact with infectious material.

In the first group of rabbits and dogs, a small piece of gauze was drawn under one ureter and saturated with *B. coli* after laparotomy. The opposite ureter was ligated and divided so that the ensuing hydronephrosis would act as a filter for blood stream infection. The control urine, taken before the experiment, was sterile in all of these animals. At postmortem, which occurred from seven to thirty days after the experiment, cultures of urine from both kidneys and bladder were sterile. *B. coli* was grown from the gauze around the ureter. Microscopically, in the region of the gauze, a dense polymorphonuclear

exudate was found around the ureter; but a few centimeters above the gauze, the ureter was free from cellular exudate. Sections of the kidney pelvis and kidney showed no cellular infiltration. On the opposite side, the hydronephrotic kidney and ureter were sterile and showed no cellular exudate (Figs. 12, 13, 14 and 15). The only exceptions to these microscopic findings were in several rabbits in which a few clumps of round cells were found in both kidneys, ureters and bladder. It seems improbable that these cells were related to

Fig. 14.—Ureter below the gauze showing no infiltrate; × about 70.

experimental conditions, as the cellular accumulations were isolated and corresponded to those found in the urinary organs of rabbits under control conditions.

It appears, therefore, that infectious material brought in contact with the periureteral lymphatics does not involve the urinary tract in infection by spreading along the ureteral lymphatics. There was no evidence of ascending infection involving the kidney pelvis or kidney parenchyma, nor was there any descending infection involving the bladder. In a few instances in dogs, the lumbar lymphatic nodes

in the region of the gauze were enlarged and in one instance they suppurated. This is striking evidence of the segmental drainage of the ureter.

In another group of experiments on rabbits and dogs, the ureter was ligated and divided, and the gauze around the ureter, saturated with *B. coli*, was placed near the proximal cut end of the ureter. At necropsy the cut end of the ureter was found embedded in the inflammatory exudate about the gauze. In some of these experiments,

Fig. 15.—Bladder wall with the peritoneal coat showing no infiltrate; × about 70.

the bladder urine and urine from the opposite kidney as well as that from the developing hydronephrosis were infected with *B. coli*, which indicated that a blood stream infection had taken place. On the side of the pyonephrosis, in the submucosa of the kidney pelvis and the ureter as well as in the parenchyma of the kidney, groups of polymorphonuclear cells could be demonstrated microscopically, but there was no characteristic involvement of the spaces about the blood vessels where the larger lymphatics are located.

In other experiments of this type, the urine of the hydronephrosis was sterile as was the urine from the bladder and opposite kidney. There was no involvement of the periureteral lymphatics on the side where the gauze was implanted in the rabbit experiments; but in a few dogs, polymorphonuclear cells were found in the periureteral tissue as high as the pelvis of the kidney.

In experiments on two dogs and one rabbit, with the gauze in contact with the divided ureter, a pyonephrosis was found without periureteral lymphatic or blood stream involvement. The bladder and the kidney urine on the opposite side was sterile. In these instances, the infection probably extended along the lumen of the ureter by direct extension through its cut end.

In those experiments in which a cut end of a ligated ureter came in contact with infectious material, various results were recorded: (*a*) blood stream infection with infection of both kidneys and bladder; (*b*) involvement of the periureteral lymphatics above the point of contact with the infectious material but with no infection of the urinary stream, and (*c*) infection of the hydronephrosis above, with but little or no involvement of the periureteral lymphatics.

In no experiment, however, did it seem probable, after weighing all the evidence, that infection of the hydronephrosis took place by infection traveling along the ureteral lymphatics to the kidney.

CONCLUSIONS

1. Neither round nor polymorphonuclear cellular infiltration of the ureteral or subpelvic kidney lymphatics is synonymous with urinary tract infection, as we regard it clinically.

2. The lymphatics of the bladder and ureter play an unimportant rôle in the conduction of acute infections from the bladder to the kidney.

3. Infectious material brought into intimate contact with the periureteral lymphatics does not affect them to any considerable extent and infection of the urinary stream does not result.

4. An involvement of the periureteral lymphatics may occur when the cut end of a divided ureter, which has been ligated, comes in contact with infectious material; but it is improbable that infection of the kidney pelvis by this route occurs.

NERVE SUTURE

AN EXPERIMENTAL STUDY TO DETERMINE THE STRENGTH OF THE SUTURE LINE *

EDWIN M. MILLER, M.D.
CHICAGO

It is sometimes necessary during the repair of a peripheral nerve injury to resect an extensive scar, even as much as 3 or 4 inches, before reaching normal funiculi, and it is difficult to make an end-to-end suture even when the nerve segments are freely mobilized and approximated by posture. Huber [1] has shown experimentally that end-to-end suture is preferable to any form of transplant, but if a transplant becomes necessary, that taken from the same individual and inserted in the form of a cable is the best. This technic has recently been described by Elsberg [2] and also by Stookey,[3] a large sensory nerve in the neighborhood of the lesion usually being used for the cable. Clinically, this method of repair has not yielded encouraging results, and Lewis [4] attributes this to the tendency of the distal line of suture to act as a block to the regenerating fibers that have successfully traversed the transplant. He is of the opinion that secondary operation in these cases with the removal of the narrow scar at the distal end of the cable and a new end-to-end suture might effectively aid complete regeneration. It would seem wise, then, to employ primarily an end-to-end suture whenever possible, even though extreme flexion is necessary for approximation, but in doing this the question naturally presents itself as to the strength of such a suture line and the length of time necessary to immobilize a limb in flexion before allowing tension on the sutured nerve. This problem has been investigated by us experimentally at the suggestion of Dr. Lewis with the view of establishing a few facts which could be employed in clinical work.

TECHNIC

The first series of experiments included sixteen dogs, eleven of which were free from infection and furnished data for this report. Under ether anesthesia the left sciatic nerve was exposed through

* From the Surgical Department of Rush Medical College.

1. Huber, G. C.: Repair of Peripheral Nerve Injuries, Surg., Gynec. & Obst. **30**:464 (May) 1920.
2. Elsberg, C. A.: Technic of Nerve Suture and Nerve Grafting, J. A. M. A. **73**:1422 (Nov. 8) 1919.
3. Stookey, Byron: The Technic of Nerve Suture, J. A. M. A. **74**:1380 (May 15) 1920.
4. Lewis, Dean: Principles of Nerve Surgery, J. A. M. A. **75**:73 (July 10) 1920.

an incision between muscle planes, the nerve was freed from its bed for a short distance and a section was removed, sufficiently long to necessitate extreme flexion of the leg on the thigh in order to perform an end-to-end suture. The technic of approximation was similar to

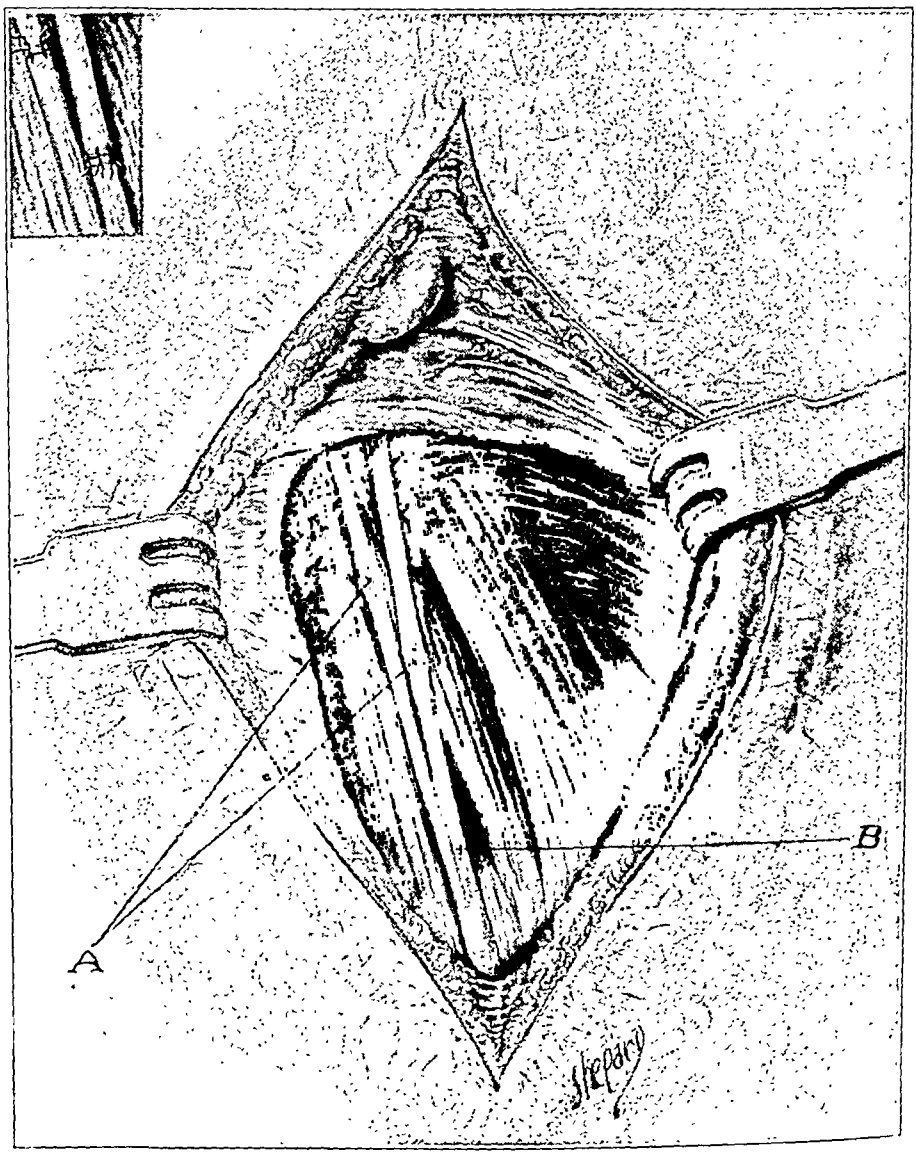

Fig. 1.—*A*, line of suture of posterior tibial and external popliteal nerves on right leg; *B*, location of suture of sciatic nerve on the other leg.

that used and recently described by Elsberg, Huber, Lewis, Stookey and others, namely, interrupted sutures of very fine catgut or silk passed through the epineurium only. A plaster-of-Paris dressing was applied to maintain the flexed position as long as desired.

In this series of animals we noted constantly a smooth fusiform enlargement about 1 cm. long in the region of the suture line. The animals that wore a plaster cast on the flexed limb were not inclined to use the limb actively after its removal, so that the amount of pull

TABLE 1.—EFFECT OF EARLY AND LATE USE OF LIMB ON SUTURE LINE

Dog	Duration of Experiment in Days	Number of Days in Cast	Observations	Necropsy Findings
98	11	11	Leg immobilized entire period	Dog died of distemper on 11th day. Wound clean. Anastomosis intact and surrounded by small organizing blood clot. Nerve removed for microscopic study. Fixation in Mueller's fluid
88	19	12	After removal of cast on 12th day has not used leg in walking. Carries it partly flexed most of the time	Dog killed on 19th day with ether. Anastomosis intact. Fusiform swelling about line of suture. Considerable loose adhesions. Fixation in ammoniated alcohol
95	36	13	Dog has used the leg considerably in walking since removal of the cast	On 36th day the dog was killed with ether. Fusiform smooth swelling 1.5 cm. long in region of anastomosis which is intact and clean. Fixation in Mueller's fluid
90	16	16	No use of limb observed after removal of the cast on the 14th day	Dog died on 16th day. Wound clean. Anastomosis intact. Fusiform enlargement 1 cm. long in region of suture line
92	25	18	No use of limb in walking observed after removal of cast	Dog died on 25th day. Nerve dissected from loose adhesions. Area of anastomosis appears as a smooth swelling. Nerve fixed for microscopic study
80	27	20	Dog did not use the limb after removal of the cast	Dog died on 27th day. Wound clean. Nerve dissected from clean bed with few adhesions. Anastomosis intact. Fusiform enlargement for 0.5 cm. on either side of suture line. Fixation in ammoniated alcohol
99	21	21	Leg immobilized entire period	Dog died on 21st day. Wound clean. Nerve dissected out from loose adhesions. Line of suture has not held. Ends separated 1¾ inches. Neuroma on proximal end. Fixation in Mueller's fluid
96	35	24	General condition good but animal has used leg very little since removal of the cast	Under ether the nerve dissected from loose adhesions. Anastomosis
81	33	None	Protective dressing applied after operation. Animal very shortly began using the leg in walking and running	Dog died on 33d day. Wound clean. Nerve removed from clean bed. Very little enlargement in region of anastomosis which is intact. Fixation in ammoniated alcohol
94	37	None	Protective gauze dressing and bandage applied after operation. Within a few days the animal began using the leg. At the end of 14 days there was very active use in running	Under ether the nerve removed from a bed of a few loose adhesions. Fusiform swelling about suture line, which is intact. Fixation in Mueller's fluid
93	38	None	After the wound had healed the leg was used very actively in walking and running. General condition excellent	Under ether the nerve removed. Wound clean. Suture line intact. Fusiform smooth swelling in region of anastomosis. Fixation in Mueller's fluid

on the line of suture was practically negligible. Those, however, that had only a protective dressing on the wound for a few days soon began to use the limb actively in walking or running. In fact, on several occasions while the dogs were running about in the yard, it was difficult to tell, except for the toe-drop, which leg had been operated on. In these animals the amount of pull on the suture line was considerable, even after a very few days. At necropsy, which was performed anywhere from eleven to thirty-eight days after operation, examination of these nerves showed separation at the suture line in only *one* instance (Dog 99). This dog died while the leg was held flexed in a plaster cast, the separation obviously not being due to tension. Aside from this we were unable to detect any difference at the suture line between those held flexed for a period in a cast and those subjected to strain within a few days after operation.

These observations led us to examine more accurately the actual strength of the suture line at different periods, and to determine whether there was any constant relation between the size of a nerve and its tensile strength at the point of suture. The technic employed was the same as that used in the previous series except that a section of the nerve was not removed. In every case simply a protective dressing was applied until the skin had healed, the animal being allowed to use the limb at will. At the end of the desired period, the dog was killed with ether, the sciatic nerve was dissected from its bed and divided 4 or 5 cm. distal to the suture line, the proximal end remaining intact. A pair of curved artery forceps was applied to the cut end of the nerve (Fig. 1), and the handle was fastened to a small stout cord which, after passing up over a pulley, was tied to the top of a bottle. By adding water to the bottle very slowly the weight necessary to break the suture line was determined. As the apparatus remained constant in all the experiments no allowance was made for the actual weight of the cord. The size of the nerve was measured by its diameter in a normal portion proximal to the anastomosis. As the shape of these nerves is somewhat variable, some being almost round and others a little flattened, a measure of the diameter seemed the only fair and practical way of judging the size. The fusiform swelling about the suture line caused almost invariably an increase of from 1.5 to 2 mm. at the point of greatest thickness. In the first five dogs, the sciatic was sutured well above its bifurcation, using both legs. Variations in the diameter were sought by selecting small, medium sized and large animals. We soon observed, however, that the difference in the size of the sciatic nerve was not appreciable, even though that of the animals was considerable.

The strength of the suture line in nerves of the same size, tested at the same length of time after operation, varied considerably in different animals, a fact accounted for readily by the variance in general health and well-being of the dog. In the last six experiments, we sutured nerves of constantly different diameters in the same animal and tested their strength at the same periods after operation. For this purpose we used the sciatic on the left leg and the external popliteal and posterior tibial on the right, inasmuch as measurement of a large number of normal nerves showed that the external popliteal has a diameter of from 1 to 2 mm., the posterior tibial of from 2.5 to 3.5 mm., and the sciatic of from 4 to 6 mm., a ratio of approximately 1 : 3 : 5. Moreover, the variation in their tensile strengths, as determined by this method, is almost exactly proportional to their diameters.

TABLE 2.—STRENGTH OF NORMAL NERVES OF DIFFERENT SIZES

Nerve	Diameter in Millimeters	Amount of Stretch in 1 Cm. of Nerve	Weight in Gm. to Break the Nerve	Remarks
External popliteal.....	1.5	2.5	2,900	Broke at forceps attachment
Posterior tibial.....	3.0	1.0	3,350	Broke at forceps attachment
Sciatic.....	5.0	1.5	5,450	Pulled out at sacral plexus
			5,540	Broke at forceps hold

It is of interest to consider briefly the histologic picture in the region of the suture line before discussing the effect coincident with the changes on the strength of the suture line. Ranson [5] has beautifully described and illustrated, by means of the pyridin modification of the Cajal silver stain, the steps in the regeneration of a nerve sutured after a cleancut transverse division. Within the first twenty-four hours, there is formed a plastic exudate between the nerve ends. In the distal stump, adjacent to this exudate, is a narrow area in which evidences of an early abortive regeneration are seen, characterized by the formation of many small branches from the axis cylinders, having club shaped end-bulbs. These form a distinct network. Distal to this, degeneration of both medullated and nonmedullated fibers begins at once and progresses rapidly. By the eighth day the neurilemmal cells have increased greatly in size and have formed protoplasmic bands which largely fill up the space formerly occupied by the myelin and axis cylinders. In the proximal stump, a narrow area adjacent to the exudate shows an abortive regeneration similar to that in the distal stump. For a short distance proximal to this is a zone of reaction characterized by a swelling of the nerve fibers and the for-

5. Ranson, S. W.: Degeneration and Regeneration of Nerve Fibers, J. Comp. Neurology **22**:487, 1912.

mation of a neurofibrillar reticulum which fills up the space within the neurilemma. The axis cylinders undergo a retrograde degeneration up to 5 or 10 mm. above the suture line. The new fibers are seen on the eighth day as side branches coming off above the zone of degeneration, multiplying rapidly and growing downward as parallel

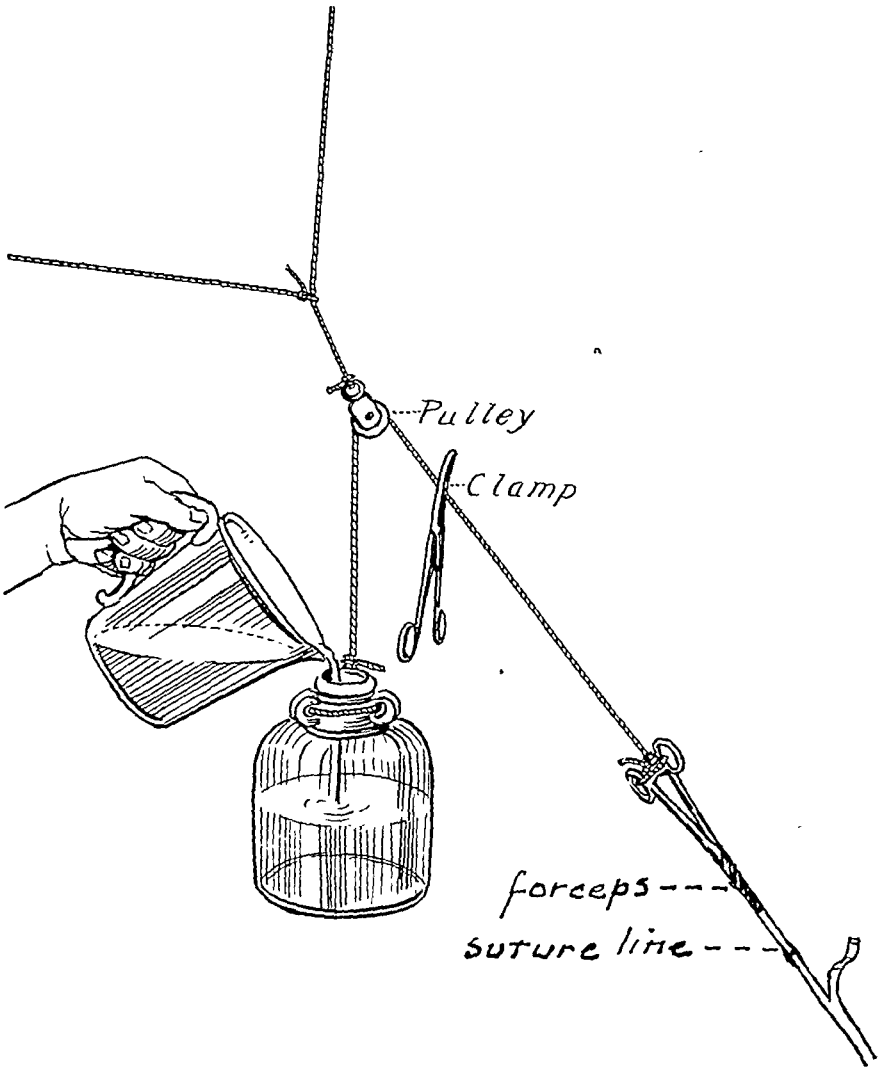

Fig. 2.—Apparatus used to determine the tensile strength of the suture line after end-to-end anastomosis.

bundles within the neurilemma, or spirally to form distinct skeins. When the scar is reached, these new fibers with their terminal bulbs spread in all directions, forming a dense network, the general trend of which is toward the distal stump. By the fourteenth day, a large number of new fibers have bridged the scar and started to grow into

the distal stump, where they are guided by the protoplasmic bands in which they travel. Kirk and Lewis [6] observed similar phenomena after tubulizing with fascia a gap formed by removal of a 10 mm. segment of the sciatic nerve in dogs. They demonstrated that the protoplasmic bands which form bridge the gap within six days and that the regenerated neuraxes from the proximal stump penetrate the distal segment within three weeks.

In the light of the histology of a suture line within the first few weeks after operation, the variations in tensile strength given in Table 3 were determined experimentally.

TABLE 3.—VARIATIONS IN TENSILE STRENGTH

Period after Operation	Dog	Type of Operation: Suture of	Leg	Diameter of Nerve, Mm.	Weight Necessary to Break, Gm.	Remarks
1 wk.	6	Sciatic	Right	4.0	975	Broke at suture line
		Sciatic	Left	—	—	Result not reliable
	30	Sciatic	Right	—	—	Result not reliable
		Sciatic	Left	5.0	430	Broke at suture line
	31	Ext. popliteal	Right	1.5	318	Broke at suture line
		Post. tibial	Right	3.0	—	Accidentally broke
2 wks.	45	Sciatic	Right	5.0	6,327	Broke through line of suture
		Post. tibial	Left	3.0	5,727	Broke through line of suture
	10	Ext. popliteal	Right	1.5	1,665	Threads remained unbroken
		Post. tibial	Right	3.0	2,815	Threads remained unbroken
		Sciatic	Left	5.0	2,615	Broke across suture line
3 wks.	29	Sciatic	Right	2.0	2,885	Broke at suture line
		Sciatic	Left	2.0	1,750	Broke at suture line
	84	Ext. popliteal	Right	1.5	2,215	Broke at suture line
		Post. tibial	Right	2.5	4,800	Pulled out in strands
		Sciatic	Left	4.5	4,950	Pulled out in strands
4 wks.	46	Sciatic	Right	5.0	9,202	Broke at suture line
		Sciatic	Left	5.0	6,342	Broke at forceps attachment
5 wks.	15	Sciatic	Right	1.5	4,675	Broke at suture line
		Sciatic	Left	2.0	4,825	Stitches loose, easily picked out
	80	Ext. popliteal	Right	1.5	2,115	Broke directly across
		Post. tibial	Right	3.0	3,715	Pulled out in long strands
		Sciatic	Left	5.0	5,200	Sutures all loose
	45	Ext. popliteal	Right	2.0	2,615	All stitches loose and easily pulled off before tests were made. These nerves broke directly across suture line
		Post. tibial	Right	5.5	4,850	
		Sciatic	Left	5.0	4,850	

Necropsy Finding: *In all of these animals the wounds were clean and very few adhesions were seen about the nerve. There was invariably a fusiform thickening about 1 cm. long in the region of the suture line which increased the diameter about 2 mm.*

COMMENT ON RESULTS

The results of the first few experiments were disappointing, as we were not accustomed to the apparatus, and used too heavy a weight in testing the strength of the suture line of three of the animals one

6. Kirk, E. G., and Lewis, Dean: Regeneration of Peripheral Nerves. Bull. Johns Hopkins Hosp. 28:71 (Feb.) 1917.

week after suture. Later, however, the determinations were easily made. The efficiency of the apparatus used might be questioned in one respect, that of applying forceps to the distal end of the nerve which must of necessity crush the nerve to some extent. This is true, but it did not affect the accuracy of the tests, because, except in a single instance, rupture of the nerve always took place in the region of the suture line. The weight was always increased very slowly and we invariably observed that before rupture occurred the fusiform enlargement increased in length from 1 to 2 mm.

Strength of Suture Line After One Week.—At the end of the first week after suture, the plastic exudate is beginning to organize. There is degeneration of axis cylinders and medullary sheaths in the areas immediately adjacent to the exudate, protoplasmic bands have partly bridged the gap, but the new neuraxes have not as yet penetrated the scar. The weight necessary to separate the two segments at this stage falls below 1,000 gm., the average for nerves of different diameters being 574 gm.

TABLE 4.—RELATION BETWEEN SIZE OF NERVE AND TENSILE STRENGTH AT DIFFERENT PERIODS AFTER SUTURE

Size of Nerve in Diameter	1 Week	2 Weeks	3 Weeks	4 Weeks	5 Weeks
1.5-2 mm.	318 gm.	1,665 gm.	2,885 gm. 1,750 gm. 2,215 gm.	.....	4,675 gm. 4,825 gm. 2,115 gm.
Average	.....	.....	2,283 gm.	.....	3,357 gm.
3-4 mm.	.....	5,727 gm. 2,815 gm.	4,800 gm.	.....	3,715 gm.
Average	.....	4,271 gm.			
4-6 mm.	785 gm. 430 gm.	6,327 gm. 2,615 gm.	4,960 gm.	9,292 gm. 6,342 gm.	5,200 gm. 4,850 gm. 4,850 gm.
Average	702 gm.	4,471 gm.	.....	7,772 gm.	4,970 gm.

After Two Weeks.—At the end of the second week, a marked change has occurred. The exudate has become a well organized scar, which has increased the diameter of the nerve by about 2 mm. Degeneration in the proximal stump has ceased, and the new neuraxes have not only entered the scar but have formed a dense network there. A few have even penetrated the distal segment. The strength of the suture line has increased enormously. As seen in Table 4 a very small nerve now supports 1,665 gm.; a medium sized nerve on an average, 4,271 gm., and a large 5 mm. nerve, 4,471 gm.

After Three Weeks.—At the end of three weeks the change in tensile strength is less marked. Practically all the new neuraxes have entered the distal segment and have begun their downward growth

within the protoplasmic bands. The strength of the suture line at this period, though not much greater than at the end of two weeks, is becoming more directly proportional to the diameter of the nerve, and the line of separation, instead of always being a cleancut transverse break, is frayed and irregular. The silk stitches have now become less of a factor than in the earlier days. As a rule they can be readily picked off the surface of the scar with forceps.

After Four Weeks.—We should expect from the histology of the changes which have occurred at this time to find the suture line very strong, inasmuch as the scar is completely healed, and made up of cable-like bundles of new, well developed fibers surrounded by organized connective tissue. On Dog 46, a husky animal, a bilateral suture of the sciatic nerve was performed. The right sciatic nerve supported 9,202 gm., while the left nerve broke, not at the suture line, but where the forceps were attached.

After Five Weeks.—At the end of this period the process of repair is complete. The strength of the suture line has now become as great as we should expect it to be even at the end of the sixth, seventh or eighth week. Actually there has been little change in the tensile strengths for the last two weeks, but the direct ratio between the size of the nerve and its strength at the suture line has become better established. What little part the sutures play at this period may be judged from the ease with which they may be removed from the surface.

CONCLUSIONS

1. In dogs, which show individual differences in rapidity of repair as human beings do, the tensile strength of a suture line in the sciatic nerve or its branches is practically as great at the end of the third week as at the end of the fourth or fifth week.

2. The strength of the suture line, especially after the second week, is almost directly proportional to the diameter of the nerve.

3. The epineural sutures of fine catgut or silk play little if any part in the strength of the suture line after the second week.

4. Long defects of nerves may be overcome by mobilization of the segments and posture, an end-to-end suture being performed. The suture line is apparently firm enough after three weeks to begin gradual straightening of the flexed forearm or leg. Clinically after operation upon the sciatic nerve, it would seem best to wait six or eight weeks after suture before extending the leg if flexion has been necessary to complete an end-to-end suture. In case of the median and ulnar, extension of the forearm should not be attempted until after four weeks if flexion has been required.

THE CORRECTION OF SCAR TISSUE DEFORMITIES BY EPITHELIAL GRAFTS

REPORT OF FIVE CASES

EDMUND B. SPAETH, M.D.
Major, M. C., U. S. Army
WASHINGTON, D. C.

In Jaunary, 1920, Col. S. H. McKee, C. A. M. C., published an article on epithelial outlays and inlays in lid repair. Previous to its appearance, one of the patients whose case is reported herewith (Case 2) had already been operated on by free epithelial grafts with unsatisfactory results, prior to his admission to this clinic. Private G. (Case 1) was admitted to this hospital subsequent to the appearance of Colonel McKee's article, and the technic used in the operation in this case was very similar to that suggested by Colonel McKee and by Gillies of Queen's Hospital. The results obtained in the cases here reported were very satisfactory from a functional as well as from a cosmetic standpoint.

REPORT OF CASES

CASE 1.—Private G., aged 23, was admitted to the hospital April 18, 1920. Physical examination was negative except for the eye condition. Vision in the right eye was 20/200, amblyopia exanopsia, and in the left eye, 20/40. The left eye showed a complete ectropion of the upper lid from loss of all tissue, because of a third degree burn, causing scar tissue contraction. The palpebral conjunctiva was deeply ulcerated, in addition to some ulceration of the corneal conjunctiva, i. e., keratitis e lagophthalmo (Fig. 1). The cause of the condition was a third degree burn resulting from the explosion of a gasoline torch four months prior to admission. Under local anesthesia, procain 0.5 per cent. and epinephrin 1:25,000, an incision was made in the upper lid, and the lid margin was allowed to drop to its normal level (Figs. 2 and 3). The edges of the incision were undermined with great care to prevent any destruction of the remaining fibers of the levator palpebrae and its nerve supply. The ulcerated area in the palpebral conjunctiva was completely excised and a very thin, small pedicle flap from the edge of the incision was turned in to cover this raw area (Figs. 4 and 5). A Thiersch graft was cut from the inner aspect of the arm under procain anesthesia (Fig. 6) and wrapped with its epidermal surface internally around a gutta-percha mold. This gutta percha had been sterilized by boiling, then had been softened by hot water after cooling after which the mold had been shaped to fit the cavity formed by the dissection (Figs. 7 and 8). This mold with the graft was then sutured in place (Fig. 8), and the operative field was dressed with warm

1. McKee, S H., Arch. Ophth. **49**:30 (Jan.) 1920.

salt solution for the first twenty-four hours, following which, dry dressings were used. Both eyes were bandaged for three days. At the end of six days, the sutures were removed, the line of incision was reopened, the mold was removed and the pedicle of the flap to the palpebral conjunctiva was resected. A small amount of serum had formed at the site of this outlay, so that the mold was removed without any difficulty. In fact, the mold was

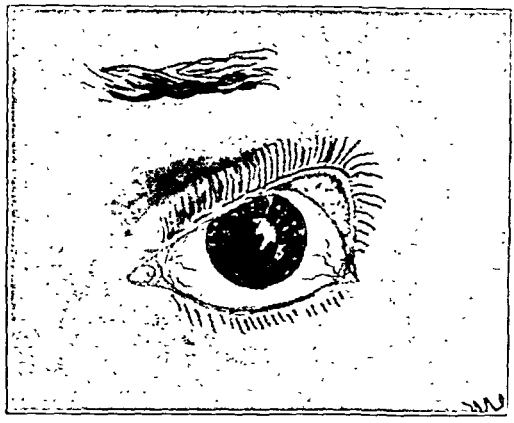

Fig. 1 (Case 1).—Scar tissue ectropion from loss of tissue of the upper lid with ulceration of the everted palpebral conjunctiva.

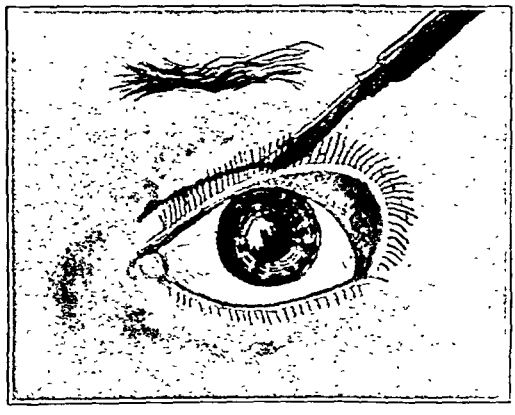

Fig. 2 (Case 1).—Line of incision made to allow lid margin to drop to its normal level.

apparently floating in position. No infection of any kind was present. Dry dressings were continued for two weeks, after which careful massage of this new upper lid was instituted. Immediately following the removal of the mold, the condition was over-corrected at least 50 per cent. Massage and the contraction that always follows Thiersch graft outlays soon brought the lid to normal size and position. The normal amount of movement in the new lid was most gratifying. One month following the Thiersch graft, two small free

grafts, about 1½ inches in length and one-fourth inch in width, were excised from the occipital scalp and placed in the supra-orbital region to replace the loss of the eyebrow. The artist has represented these as a solid Wolf graft in the illustration; but this is an error. The grafts were placed parallel within the skin with all fat tissue attached. A bridge of about one-fourth inch of normal skin intervened (Fig. 9). The condition, Aug. 20, 1920, when the patient



Fig. 3 (Case 1).—Lid margin released by dissection down to its normal level.

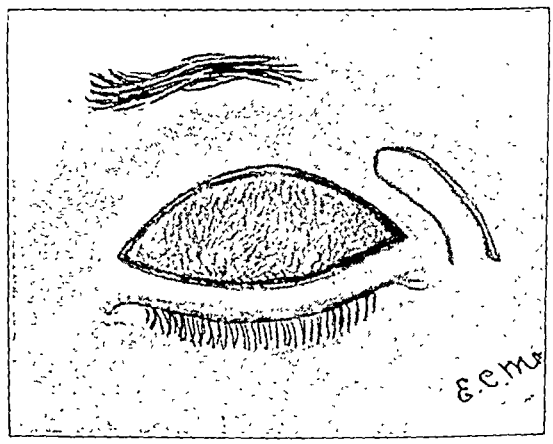

Fig. 4 (Case 1).—Line of incision to prepare pedicle flap for replacement of ulcerated conjunctiva.

was discharged from the hospital, leaves nothing to be desired. The pedicle flap thickened the upper lid to some extent, but not enough to cause concern. The keratitis e lagophthalmo was cured coincident with the removal of the mold and release of the upper lid. No further treatment for this complication was necessary.

Case 2.—Lieutenant J, aged 29, was admitted August, 1919. Physical examination was negative with the exception of that of the eyes and one ear, as well as a deformity of the skin over the bridge of the nose. The ear condi-

tion was a marked deformity and decrease in the size of the concha from scar tissue contraction with loss of substance. The eye condition was a bilateral scar tissue contraction ectropion of both the upper and lower lids. The causative agent in this case was a third degree burn from a phosphorus grenade explosion. The first operative work done on this patient was the taking of a pedicle flap from the forehead to repair the deformed skin over the bridge of

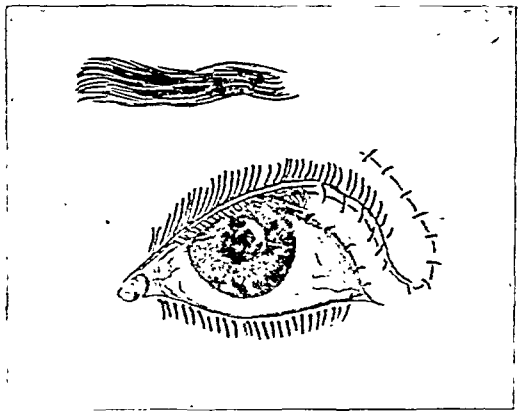

Fig. 5 (Case 1).—Pedicle flap in place.

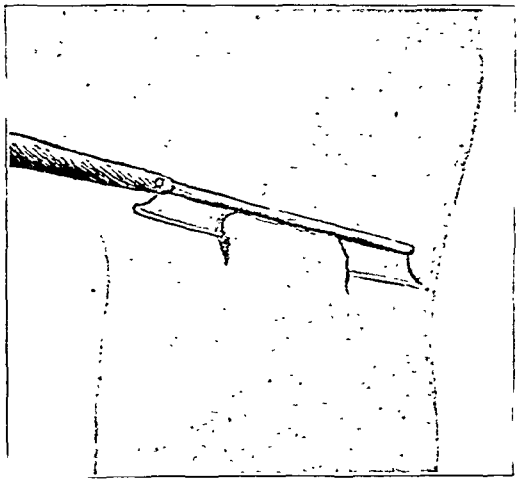

Fig. 6.—Thiersch graft cut from the inner aspect of the upper arm.

the nose. The condition was overcorrected to form a slight epicanthus. The next procedure was a plastic repair of the ear by pedicle flaps from the neck, and cartilage implants taken from the seventh costal cartilage. The results of these operations were satisfactory, but are not being considered in this paper. The condition of the left ear and the forehead is illustrated in Figure 10, which also illustrates the ectropion with lagophthalmus. Using the same procedure as in Case 1, and under the same anesthetic, an incision and a wide

grafts, about 1½ inches in length and one-fourth inch in width, were excised from the occipital scalp and placed in the supra-orbital region to replace the loss of the eyebrow. The artist has represented these as a solid Wolf graft in the illustration; but this is an error. The grafts were placed parallel within the skin with all fat tissue attached. A bridge of about one-fourth inch of normal skin intervened (Fig. 9). The condition, Aug. 20, 1920, when the patient



Fig. 3 (Case 1).—Lid margin released by dissection down to its normal level.

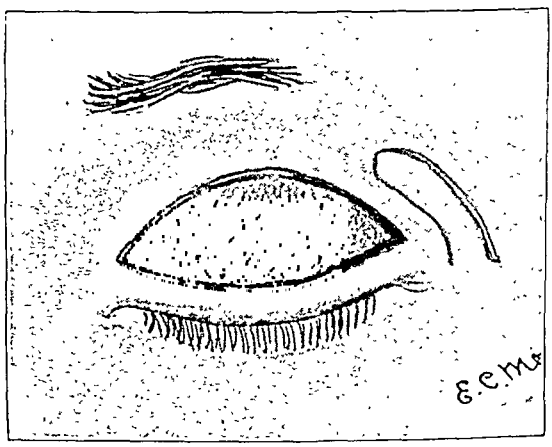

Fig. 4 (Case 1).—Line of incision to prepare pedicle flap for replacement of ulcerated conjunctiva.

was discharged from the hospital, leaves nothing to be desired. The pedicle flap thickened the upper lid to some extent, but not enough to cause concern. The keratitis e lagophthalmo was cured coincident with the removal of the mold and release of the upper lid. No further treatment for this complication was necessary.

Case 2.—Lieutenant J, aged 29, was admitted August, 1919. Physical examination was negative with the exception of that of the eyes and one ear, as well as a deformity of the skin over the bridge of the nose. The ear condi-

tion was a marked deformity and decrease in the size of the concha from scar tissue contraction with loss of substance. The eye condition was a bilateral scar tissue contraction ectropion of both the upper and lower lids. The causative agent in this case was a third degree burn from a phosphorus grenade explosion. The first operative work done on this patient was the taking of a pedicle flap from the forehead to repair the deformed skin over the bridge of

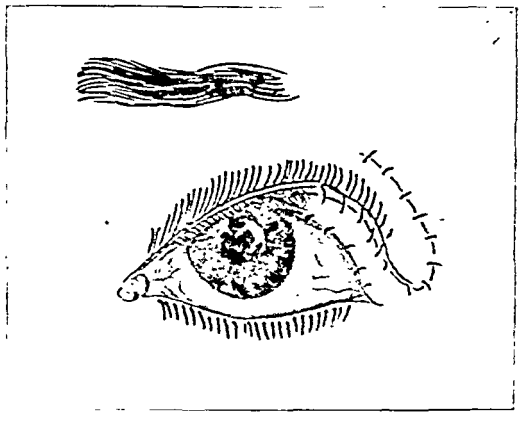

Fig. 5 (Case 1).—Pedicle flap in place.

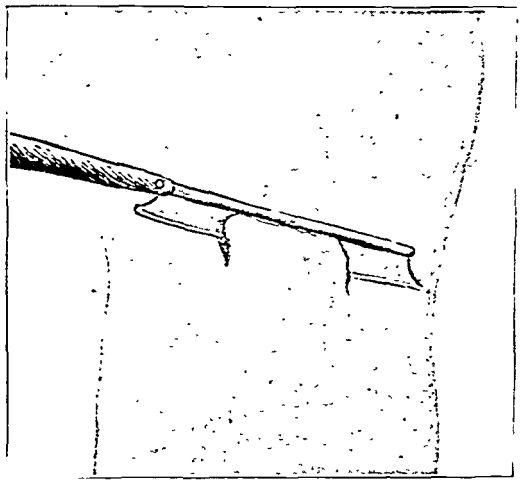

Fig. 6.—Thiersch graft cut from the inner aspect of the upper arm.

the nose. The condition was overcorrected to form a slight epicanthus. The next procedure was a plastic repair of the ear by pedicle flaps from the neck, and cartilage implants taken from the seventh costal cartilage. The results of these operations were satisfactory, but are not being considered in this paper. The condition of the left ear and the forehead is illustrated in Figure 10, which also illustrates the ectropion with lagophthalmus. Using the same procedure as in Case 1, and under the same anesthetic, an incision and a wide

dissection of both the upper and lower lids was performed, sufficiently extended to release the lid margins and bring them into an overcorrected position. Molds of sterile gutta percha were formed to fill the cavities caused by the relaxation of the lid margins to their normal positions (Fig. 11). The musculature and its nerve supply was carefully conserved in the dissection. Thiersch grafts were cut from the inner aspect of the arm, under procain and epinephrin and were wrapped around these molds. The molds were then sutured in place. The sutures and molds were removed the sixth and seventh days. The movement present in the reconstructed lids was of normal range. A month later the same type of Wolf graft was inserted into the supra-orbital region for the formation of a new eyebrow (Fig. 12). In this case as in the first case, the Thiersch graft dressing for the first twenty-four hours was saturated with warm physiologic sodium chlorid solution every four hours. Both eyes were bandaged for the first four days. In this case the repair of both the upper and lower lids of one eye was completed at one time. A subsequent operation was performed at the end of three weeks on the other eye.

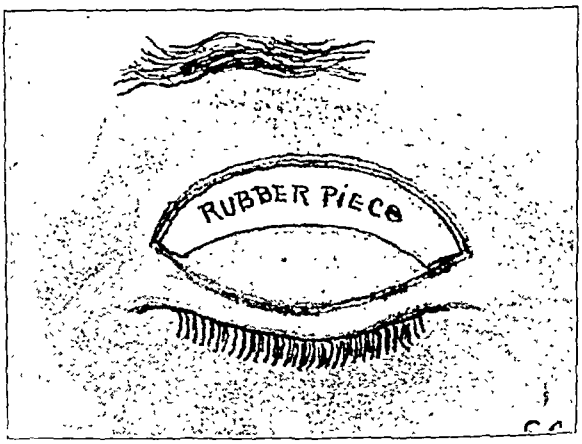

Fig. 7 (Case 1).—Fitting of gutta-percha mold in place.

The dressing for the Wolf graft also was saturated with warm physiologic sodium chlorid solution every four hours, and was continued for three days. Very few sutures were used in the placing of the Wolf graft.

The other three cases in this series are scar tissue deformities resulting from gunshot wounds about the eye.

Case 3.—Private S., aged 21, was admitted in October, 1919. Examination disclosed traumatic enucleation of the left eye with almost entire absence of a conjunctival sac. This was replaced by an unhealthy mass of granulations with some entropion of both upper and lower lids. Granulations and superficial infection cleared up under treatment with silver nitrate, dressings of surgical solution of chlorinated soda (Dakin's solution and packing the socket with gauze impregnated with a boric acid petrolatum ointment (U. S. P. Boric Acid Unguentum). Under general anesthesia, a deep incision was made posterior to the upper and lower lids. The line of incision followed that of the normal conjunctival culdesac. A sterile gutta-percha mold was fitted and wrapped with a Thiersch graft. The mold was made with an upper and lower half accurately fitted to facilitate the removal of the latter. The entire

cavity of the socket was freely curetted, and the mold with the graft was placed in position. The lid margins were freshened by excision of a very thin line of tissue and were then sutured together. Six days later, the mold was removed and a glass ocular prosthesis was furnished from the stock of standard reform eyes in the clinic.

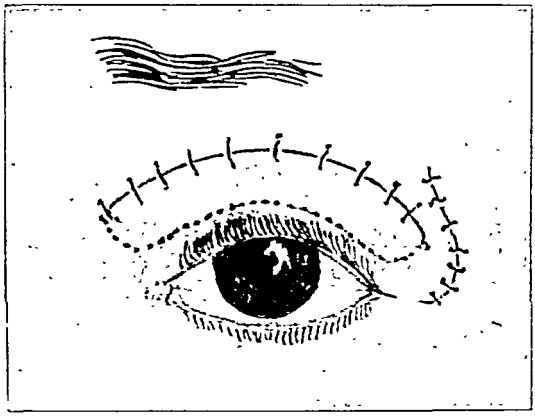

Fig. 8 (Case 1).—Sutures completed.

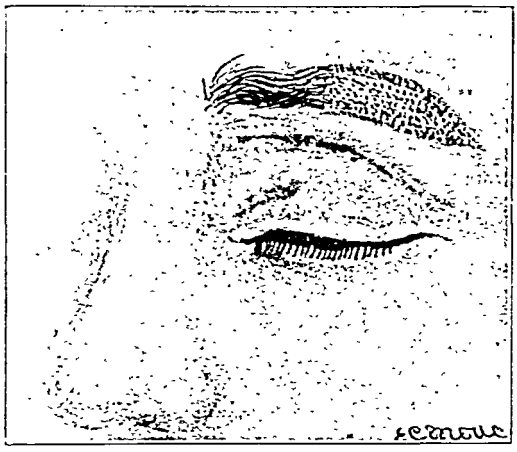

Fig. 9 (Case 1).—Final result of Thiersch graft and position of Wolf graft for repair of eyebrow.

CASE 4.—Private M., aged 27, was admitted in March, 1920. Examination revealed traumatic enucleation of the right eye with loss of bony tissue from the outer inferior edge of the supra-orbital area. The bony defect was 1 inch long and one-half inch in width. The skin over this area was adherent to the site of the bony defect, drawing the upper lid upward and outward. The upper lid was fixed, making all motion of it impossible and preventing the socket from retaining an ocular prosthesis. Under procain and epinephrin anesthesia, a skin incision was made below the supra-orbital margin, and by deep

undercutting, complete release of the upper lid was obtained. A very large cavity resulted. A mold of sterile gutta percha was fitted, wrapped with a Thiersch graft from the arm, and was sutured into the cavity made by the dissection. Six days later, the sutures were removed with the mold. At the time of removal of the sutures, some slight suppuration had formed inside the closed cavity without harming the graft in any way. The operation was satisfactory in so far as it furnished sufficient skin to relax the epidermal defect. One month later under general anesthesia, the bony defect was corrected with a cartilage implant. Cartilage was obtained from the seventh costal cartilage and was cut slightly oversize, but conformed to the shape of the defect. This was mortised into position immediately beneath the Thiersch graft. When dressings and sutures were removed, it was found that the last procedure had completed the correction of the original condition. The bony defect was filled in and the skin lay smoothly over its former position. The

Fig. 10 (Case 2).—Condition of the left ear and forehead.

lid was entirely relaxed. With the addition of a small canthoplasty which is to be performed at an early date, the socket will be in proper condition for the fitting of a glass eye.

Case 5.—Private D., aged 19, was first seen in October, 1919. Examination revealed traumatic enucleation of the left eye with an ectropion and contraction of the upper left lid, upward and outward. The cause of the deformity was the loss of soft tissue with a much contracted scar adherent to the outer edge of the supra-orbital region. The socket was able to hold a glass eye fairly well. Because of the poor cosmetic result, however, the patient refused to appear outside the hospital ward with his left eye uncovered. Under procain and epinephrin anesthesia, a horizontal incision was made through the center of the scar. By undercutting, complete relaxation was obtained above and below the incision. A sterile mold of gutta percha was fitted slightly oversize, wrapped with a Thiersch graft and sutured into the cavity. Six days later the sutures were removed. The result was entirely satisfactory to the patient as well as to the operator.

COMMENT

These cases are not unusual, nor should the results be considered extraordinary. Colonel McKee mentioned one thing that I must repeat because it is very important: "It is essential that the cavity be

Fig. 11 (Case 2).—All lid margins at their normal level as a result of incision and dissection, as illustrated by Figure 3.

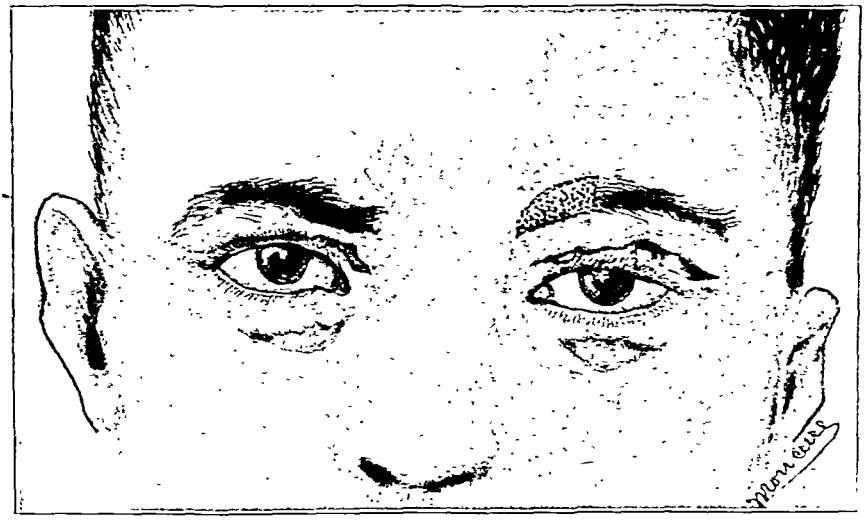

Fig. 12 (Case 2).—Completed result: normal motion in lids, ectropion cured and the Wolf graft in position.

made much larger than thought necessary. It will undoubtedly shrink some." In the fourth case of this series, the cavity made by the dissection was so large that if it had not been for the fact that I wanted

an excess of skin because of the cartilage implant that I planned to place subsequently, the result would have been a depression covered by a graft.

In work of this type, all scar tissue must invariably be released. In working on the lids, the undercutting should be close to the undersurface of the skin to save every fiber of muscle tissue remaining. It was found that from six to eight days was long enough for the mold to stay in the cavity. If it is not removed by that time it is almost certain to break out through the line of sutures, and the result is a ragged, puckered, uneven Thiersch graft and skin junction.

Fine black silk sutures were used in all the cases. It will be found that the original deformity will be present and exaggerated until the removal of the molds. This should, however, cause no alarm. As far as my experience goes, there is no reason why all pure Thiersch graft outlays cannot be performed under local anesthesia. A half of 1 per cent. procain with epinephrin, 1-25,000, is advised both for the dissection and for the cutting of the graft. No ill effects have followed this practice. Thiersch grafts should be cut as thin as possible.

These cases are selected to show what may be expected from the use of epithelial grafts.

ARCHIVES OF SURGERY

VOL. 2 MARCH, 1921 No. 2

RELATION OF CHRONIC FIBROSIS AND THROMBOPHLEBITIS OF THE SPLEEN TO CONDITIONS OF THE BLOOD AND OF THE LIVER

WILLIAM J. MAYO, M.D.
ROCHESTER, MINN.

All red-blooded animals have spleens: their removal from the body does not cause appreciable permanent disturbance. The spleen has few functions that can be determined accurately, and it is quite evident that other organs with which it is associated in function readily assume its work. The changes in the spleen found in general necropsy service are seldom characteristic of the disease which caused death. The spleen has no known internal secretion and its nerve connection consists of unimportant fibers from the sympathetic and parasympathetic systems. It contains a small amount of nonstriated muscle, which, as in other portions of the body, has the power to originate contraction, and, like the heart, the uterus and the intestine, it originates certain rhythmic contractions, noticeably during the digestive period.

The spleen, according to Gross,[1] has characteristics referable to age. In early life, the germinal foci in the malpighian corpuscles and endothelial buds resembling granulation tissue are most active. In middle age these tissues atrophy. The spleen is oversupplied with blood for its own nutrition, as are the kidneys, the liver and certain other organs, and like these organs its action relates to the constituents of the blood stream. The blood supply of an organ gives a hint, and only a hint, of its possible function. The splenic artery is the largest branch of the celiac axis, and from the celiac axis comes the blood supply of organs such as the liver, the spleen and the stomach, which are concerned in the preparation and conversion of food products into material for the nutrition of the organism. The spleen is closely associated in function with the liver. Rowntree[2] compares the spleen and the liver with the kidney, believing that the spleen acts as the malpighian bodies and the liver as the tubules, the one straining out certain substances from the blood and the other acting on the material

1. Gross, L.: Studies on the Gross and Minute Anatomy of the Spleen in Health and Disease, J. M. Research **39**:311-338 (Jan.) 1918-1919.
2. Rowntree, L. G.: Personal communication.

brought to its vital laboratories. The material which is strained through the kidneys passes out of the body as urine, the purified blood passing back into the general circulation through the renal veins. The material which is strained out of the blood by the spleen is carried to the liver for further action. The liver has power to destroy micro-organisms and to detoxicate poisons as well as to eliminate through the bile function. In typhoid fever, the typhoid bacillus is found in the spleen and in the bile; if quantities of bacteria are fed to experimental animals in whose intestinal tract ulcers have been produced, the same type of bacteria will be found in the bile. Here, however, the analogy ends, since the kidney tissue lacks the destructive power of the hepatic cell, and the kidney filter frequently becomes involved in the specific type of infection which it is attempting to eliminate, especially pyogenic and tuberculous infections, while the liver seldom fails to destroy or eliminate the microbic or other noxious agents. The portal circulation of the liver includes the blood that has been acted on by the spleen, just as it includes the blood from the mesenteric vessels which contains unfinished products of digestion, all of which are subjected to the action of the hepatic cells before it is passed through the hepatic veins into the general circulation. The spleen initiates certain processes which it cannot finish; it is tied to the liver. Approximately one fourth of the total blood in the portal circulation comes from the spleen. The spleen is the one organ of the body in which normally the blood comes directly in contact with its constituent pulp, and the pulp cells are essential to the strainer action of the spleen, although other specialized cells aid the process. In intra-uterine life, up to the fifth month, the spleen, the liver and the lymphoid and adenoid structures of the body actively participate in the formation of the cellular elements of the blood, both red and white, a function which, so far as the red cells are concerned, is usually lost by the liver and spleen before birth, to be carried on to a great extent by other hemolymph bodies and by the bone marrow. After birth the spleen in health undoubtedly produces white corpuscles and it is believed by some observers that in life-emergencies it may produce red corpuscles, as after a severe hemorrhage.

The function of the spleen reaches its height in puberty, and senescence begins; in this period its disorders become manifest, although they may have existed in a nonrecognizable form for a long time. In general, the spleen may be considered to have three functions: first, the filtering of micro-organisms and toxic substances from the blood; second, the production of lymphocytes, especially as a defense phenomenon, and third, the destruction of worn out red corpuscles, the end products of which make up the bilirubin of the bile.

FILTERING OF MICRO-ORGANISMS AND TOXIC SUBSTANCES FROM THE BLOOD

We know that during disease micro-organisms gain entrance to the blood in various ways. It would appear that under certain normal circumstances bacteria are permitted to enter the blood stream, and the reaction stimulates the development of lymphocytes and other forms of resisting agents. This vital process we speak of as immunization by the development of antibodies. The typhoid bacillus is at work during the prodromal period. What we call typhoid fever is the defense phenomenon following the development of specific antibodies. It is possible that the tonsils act as vaccinators in the maintenance of health,



Fig. 1 (Case 10324).—Photomicrograph of splenic tissue in splenic anemia.

permitting a few bacteria to enter the blood stream in the early stages of various diseases to start the immunizing process. These organisms may be eliminated from the blood by the urine without harm to the kidneys. When the elimination fails, the micro-organisms may be retained in the kidney filter, and the different varieties of hematogenous infections of the kidney result. Splenomegalia, occurring in chronic sepsis, typhoid, tuberculosis, malaria, syphilis and kala-azar, apparently is a result of the body's inability to send sufficiently rapidly to the liver for destruction the micro-organisms which the spleen has caught and is unable itself to destroy. A number of cases of chronic splenomegalia appear to be due to the hibernation of micro-organisms in the spleen, where, for some unknown reason, they may become more or less immune to even energetic and prolonged treatment and may become

a source of general reinfection because of our inability to reach them in the splenic pulp with remedies.

That white cells may pass out of the blood stream on the mucous surfaces of the body in health and return to the lymph channels is shown by the work of Stohrs and Adami,[3] who demonstrated that the leukocytes pass out in the duodenum and upper jejunum, picking up bacteria and particles of fat, and that the pigmented areas in the liver are derived from killed bacteria. Hiss[4] goes so far as to state that certain phagocytes of the body are dependent on specialized foods derived from micro-organisms, and thereby acquire, as a defense phenomenon against special micro-organisms, peculiar protective properties which may be retained for life. Each of the splenomegalias dependent on a type of micro-organism is specific, and the micro-organisms may be retained in the splenic pulp for long periods, perhaps for the life of the patient, as in tuberculosis and syphilis. Even if the micro-organisms eventually die, the changes in the spleen are permanent and the organ may continue unnecessarily to destroy the red cells and cause a grave secondary type of anemia, a true splenic anemia which at the time of subsequent discovery would be of unknown origin. That the spleen has definite reactions to specific organisms is well shown by the infrequency of abscess formation in septic splenomegalias. Yet the effect of the different organisms on the spleen is the production of a definite basic pathologic picture, fibrosis and thrombophlebitis, in addition to the specific changes due to the peculiar micro-organism which is responsible. This explanation is fair. The chronic anemia results from splenic fibrosis and thrombophlebitis without regard to the cause of the pathologic condition, and the terminal portal cirrhosis of the liver might be called a tertiary lesion resulting from the splenic anemia, itself secondary to a causative agent which may be no longer acting, while the accompanying bodily reinfections have their origin in an organism harbored by the spleen, as the organism of syphilis or of malaria.

We know much less concerning the ability of the spleen to filter toxins from the blood; our reasoning is largely an attempt to explain known phenomena. The group of so-called toxic splenomegalias is most interesting and includes the splenomegalias of unknown origin having the basic phenomena, however, of generalized fibrosis of the spleen and the thrombophlebitis, causing chronic anemias, and as a possible end-result, cirrhosis of the liver. These unexplained spleno-

3. Stohrs and Adami, quoted by Mayo, W. J.: The Relation of the Spleen to Certain Anemias, J. Ind. State M. A. **8**:499-504, 1915.

4. Hiss, P. H., Jr.: Some Problems in Immunity and the Treatment of Infectious Diseases, Arch. Int. Med. **4**:32-63 (July) 1909.

megalias comprise those conditions heretofore called splenic anemias, a lack of known etiology being one of the chief requisites for such classification. It should be borne constantly in mind that the basic pathology of the spleen, that is, generalized fibrosis and thrombophlebitis resulting in secondary anemia and liver changes, is essentially the same as the splenomegalias of known etiology such as syphilis, and the assumption of toxins acting to produce primary changes in the spleen and secondary changes in the liver is really an attempt to cover our ignorance of what the primary causes may be, or, it is only fair to say, have been. This is suggested by the similarity of the pathologic changes in the spleen in splenic anemia and in syphilis as shown by



Fig. 2 (Case 125899).—Photomicrograph of splenic tissue in syphilis of the spleen.

W. C. Chaney[5] (Figs. 1, 2, 3 and 4). Assuming that there are such toxins filtered from the blood, are we to assume that all the blood must pass through the spleen by chance, or is there a peculiar attraction between those chemical bodies or living micro-organisms which by some process of chemotaxis are diverted to the spleen? Rosenow[6] has shown experimentally that bacteria may be trained to attack certain organs, that organisms which have been found actively concerned in

5. Chaney, W. C.: Unpublished thesis.

6. Rosenow, E. C.: The Etiology of Cholecystitis and Gallstones and Their Production by the Intravenous Injection of Bacteria. J. Infect. Dis. **19**:527-556 (Oct.) 1916.

acute appendictitis or acute cholecystitis have, in many instances, appeared definitely to attack the appendix or gallbladder in animals.

The liver is the great agent of detoxication in the body. All the liver cells are alike and the pathologic processes of the organ are much simpler than of those organs containing various specialized cells which permit a wider range of pathologic variation. Detoxication of phosphorus, arsenic and chloroform, for instance, is found to take place in the liver, and if beyond the vital possibilities of the liver, ends in acute fatty degeneration of the hepatic cells; if the process is very acute, necrosis of the liver cells is the outstanding feature at necropsy. Chronic failure to detoxicate toxic material ends in portal cirrhosis which represents an attempt to encapsulate diffuse poisons which the liver no longer is able to render harmless and to eliminate. Cirrhosis of the liver in the terminal stage of splenic anemia is usually called Banti's disease, but does not differ in any important respect from cirrhosis of the liver without splenomegalia in chronic alcoholism. The alcohol cirrhoses as well as pepper cirrhosis of curry-eating persons of India are examples of poisons derived directly from the alimentary tract. We may with reason assume that unknown toxic products filtered out of the general circulation by the spleen produce the splenomegalia of splenic anemia and that the liver finally, unable further to detoxicate the poisons carried to it from the spleen, develops cirrhosis just as happens in the liver cirrhoses of alimentary origin. This would explain why removal of the spleen in some of the cases of splenomegalia of unknown cause results in betterment of the hepatic function by diverting the unknown toxin from the liver, although we are in a maze of speculation as to what becomes of the diverted toxic substance. It seems probable that the true explanation is that the chronic fibrosis and vascular changes in the spleen produce the agent which acts detrimentally on the liver cells without regard to the causes of the condition of the spleen. Another explanation which cannot be ignored is that by removal of the spleen the portal circulation is reduced by the amount of blood that the splenic vein carries to the liver, and there are sufficient uninvolved liver cells to care for the reduced volume. To the liver has been given the rare power of regeneration by cell hyperplasia. A considerable portion of the liver may be removed and hepatic regeneration take place, and this experiment can be repeated at intervals without causing death of the animal.

THE HEMATOPOIETIC FUNCTION OF THE SPLEEN

Hematologists differ widely in their views on the origin of the blood. The first blood in the fetus and the blood in lower animals that have only one kind contain only leukocytes. The spleen, in its adult function, has power to destroy the worn out erythrocytes, leukocytes and

blood platelets, as well as to manufacture lymphocytes. In some indirect way the spleen acts as a regulator of red-cell production. Stradomsky[7] suggests a twofold action of the spleen on the bone marrow. He believes that it inhibits the overproduction of red cells and stimulates underproduction, the two influences balancing each other.

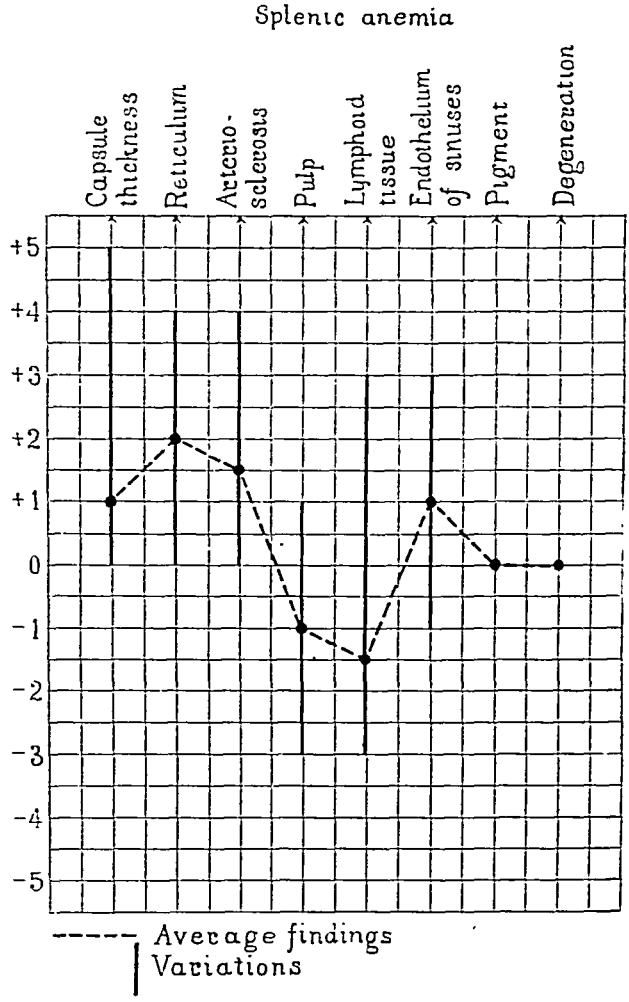

Fig. 3.—Histologic findings in seventy-two cases of splenic anemia. The pathologic processes are graded from + 1 to + 5 to show the degree of increase of the various tissues above normal, which is rated as zero, and from — 1 to — 5 to show the decrease (Chaney).

Johnstone,[8] working in the Mayo Foundation under Mann, has studied the blood following splenectomy in man and the bone marrow

7. Stradomsky, B. N.: The Spleen as a Regulator of Blood Production. Russk. Vrach. **15**:1122, 1916; abstr. J. A. M. A. **68**:885 (March 17) 1917.

8. Johnstone, E. M.: Unpublished thesis.

in splenectomized animals. He has obtained constant and comparable results in animals only by repeated studies on the bone marrow of the same animals, removed at various times following splenectomy. He has found that leukogenesis is very active immediately after splenectomy and reaches its maximum quickly. It decreases in from one to three months, until it has resumed its preoperative degree of activity. Erythrogenesis seems dormant at first in about half the animals. It then becomes more active until it exceeds the preoperative activity. In the other half of the animals, erythrogenesis begins almost immediately after splenectomy, but so slowly that it is difficult to determine. In both instances, it reaches its maximum in from three to four months, remains stationary for about two months longer, and then gradually decreases. The experimental marrow findings correspond to the blood picture after splenectomy. In disease, a disturbance of this balance takes place which promptly affects the blood picture. One might compare the splenic vein with the mesenteric venous radicles of the portal vein which pick up products and carry them to the liver, where final conversion into material for the body's needs is completed. According to this view it is assumed that the red corpuscles and other material strained out by the spleen have food value, which is undoubtedly true. On the theory once held that all the red corpuscles in the body are changed every seven days, it seems definitely established that the spleen does not indiscriminately destroy red corpuscles. Ashby,[9] working in the laboratories of the Mayo Foundation, has shown that the red cells of transfused blood may last from one to three months and that the elimination of transfused blood seems to depend more on an intermittent activity of the body than on the condition of the corpuscles. The splenic vein contains an excess of leukocytes and of iron, and no doubt the spleen is an active agent in iron metabolism and in storage.

Much experimental work has been done which has to do with the blood conditions produced by the removal of the spleen. It is believed by some observers that the liver is permanently enlarged after splenectomy. Hirschfeld and Weinert[10] found Howell-Jolly bodies nine years after splenectomy. Asher and Sollberger[11] found polycythemia

9. Ashby, Winifred: Some Data on the Range of Life of Transfused Blood Corpuscles in Persons Without Idiopathic Blood Diseases, M. Clin. N. America **3**:783-799 (Nov.) 1919; unpublished thesis.

10. Hirschfeld, H., and Weinert, A.: Klinische und experimentelle Untersuchungen über den Einfluss der Milz auf die erythroplastische Tätigkeit des Knochenmarks. Berl. klin. Wchnschr. **51**:1026-1028, 1914.

11. Asher, L., and Sollberger, H.: Beiträge zur Physiologie der Drüsen. XIX. Fortgesetzte Beiträge zur Lehre von der Funktion der Milz als Organ des Eiweissstoffwechsels. Ueber die Kompensationsvorgänge nach Milzextirpation. Biochem. Ztschr. **55**:13-44, 1913.

after splenectomy and believed that splenectomy overstimulates the hematopoietic system. Definite changes in the number and kind of white cells have been described after splenectomy, and eosinophilia has

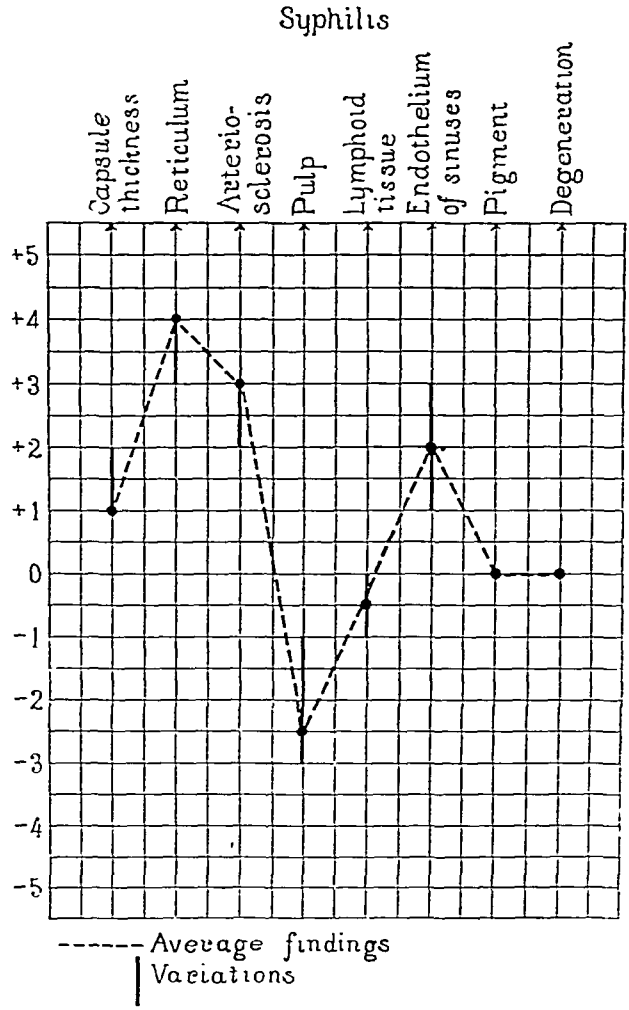

Fig. 4.—Histologic findings in six cases of syphilis of the spleen. The pathologic processes are graded from + 1 to + 5 to show the degree of increase of the various tissues above normal, which is rated as zero, and from — 1 to — 5 to show the decrease (Chaney).

been noted, usually after two years.[12] Stephan[13] produces evidence to show that roentgen ray and radium applied to the spleen shorten

12. Giffin, H. Z.: Persistent Eosinophilia with Hyperleukocytosis and Splenomegaly, Am. J. M. Sc. **158**:618-629 (Nov.) 1919.

13. Stephan, R.: Ueber die Pathologie der Blutgerinnung, Deutsch. med. Wchnschr. **46**:684-686, 1920.

the coagulation time of the blood. On the contrary, Pearce, Krumbhaar and Frazier[14] found that secondary anemia appeared after splenectomy, but disappeared in three or four months. It is evident that our knowledge of the exact relation of the spleen to the formation of the blood and of the maintenance of the blood in normal condition is in a confused state. But a large experience with splenectomies for injuries and acute diseases and the removal of the spleen for various pathologic conditions, sustains the view of Warthin[15] that the spleen is only one of the hemolymph bodies and various other tissues which have the power to destroy the worn out red cells and to develop white cells; and that its changed function in disease does not so much concern the character of the red cells which occur in pernicious anemia as their reduction in value. The spleen is concerned with excessive destruction of the red cells rather than with the disturbance of their creation, and the regulatory effect on the bone marrow about which so much has been said is probably indirect rather than due to the as yet undemonstrated hormone. The anatomic structures of the spleen are involved in certain diseases somewhat differently, sufficiently to give rise to microscopic and macroscopic pictures which have some value. Such morphology as is shown in generalized fibrosis and thrombophlebitis, for example, without regard to the cause, can be looked on as the agent at least whereby the secondary anemia and probably the portal cirrhosis are produced.

The effect on the liver is quite the same as those forms of portal cirrhosis which have their origin in the alimentary tract.

With our present knowledge, therefore, satisfactory classification of the diseases of the spleen which are concerned in the anemias is not possible. One of the great difficulties in arriving at satisfactory data concerning the splenomegalias is that ordinarily we are unable to know that the spleen is enlarged until the enlargement is sufficient to be palpable beyond the free margin of the ribs, approximately twice the normal size. Percussion is an unreliable and overrated means of determining the size of the spleen. Roentgen-ray examination of the oxygen-distended abdomen, of course, has value, but we will not often apply this method to the ordinary anemias. Much of what little knowledge I possess of the subject has come from routine examination of the spleen during abdominal operations. I have taken great pains to compare the size of the spleen under diverse conditions with the blood condition of the patient and with the liver,

14. Pearce, R. M.; Krumbhaar, E. B., and Frazier, C. H.: The Spleen and Anemia, Philadelphia, J. B. Lippincott Company, 1918.

15. Warthin, A. S.: The Changes in the Hemolymph Glands of the Sheep and Goat by Splenectomy, Contrib. Med. Research (Vaughan), Ann Arbor, 1903, pp. 216-236.

and have removed many specimens from livers to obtain as early information as possible of changes in the liver in cases in which I have found the spleen more or less enlarged. In many cases of secondary anemia, the spleen was definitely enlarged but not sufficient in size to be palpated, and I have carefully observed some of the patients for months or years afterward without finding that a palpable splenomegalia developed. Early evidence, therefore, of the primary manifestations which take place in the spleens eventually developing splenomegalia of palpable size can seldom be obtained. My information has been fragmentary and inconclusive, but the mass of material which has passed through my hands has left me with the impression that generalized splenic fibrosis and thrombophlebitis are the result of many causes, and the pathologic changes in the spleen, the liver and the blood are regularly developed without regard to the primary etiologic factors.

STUDIES IN EXHAUSTION

AN EXPERIMENTAL RESEARCH

G. W. CRILE
CLEVELAND

INTRODUCTION

The first purpose of this research has been to identify the organs and tissues which are affected by the various causes of exhaustion. It is at once obvious that these do not include the skin, the tendons, the connective tissue, the fat, the bones, the cartilage, the teeth, the hair, the organs of the digestive system or of the genito-urinary system, the lymphatic vessels or glands, the spleen, the sweat glands, the pancreas or the organs of common sensation. The organs and tissues in which one would expect to find signs of exhaustion are organs that are essential to life within the period of death from acute exhaustion.

The second purpose has been to ascertain whether or not all the known causes of exhaustion produce identical end-effects in the essential organs. That is to say, do insomnia, infection, exertion, emotion, asphyxia, exophthalmic goiter, iodism, anesthesia, the excision of organs, hemorrhage, etc., cause similar and identical changes in certain vital organs? The expectation that such an identity of change might be found was based on the identity of the essential symptoms of exhaustion—mental and physical prostration, rapid pulse, rapid respiration, falling blood pressure, sweating, etc.

The expectation that the physical changes might be identical was also based on the fact that whatever the cause of exhaustion, stimulants are of no value; that the period of time required for ultimate restoration is much the same; that want of sleep intensifies the degree of exhaustion; that sleep accelerates repair—is essential for ultimate restoration. In other words, in these researches, we have physical evidence of the identity of the lesions in exhaustion, no less than of the identity of the condition whereby restoration is achieved. This physical evidence embraces changes in histologic structure, changes in the hydrogen-ion concentration of the blood; changes in reserve alkalinity; progressive changes in the temperature and in the electric conductivity during the processes which lead to exhaustion. This evidence forms a foundation on which practical clinical methods are based.[1]

---

1. Throughout the prosecution of this research, an extensive study of the literature has been made by my collaborators and myself. Economy of space has forbidden the publication of an inclusive list. It should be added, moreover, that an adequate survey of the mass of literature in many languages which has been promulgated by the workers in the various fields with which these studies have been concerned would be a large research in itself.

I. Insomnia

In 1900, during an investigation into the cause of shock, I first became convinced that in shock the brain cells must show morphologic changes. A histologic study of the brains of animals after traumatic and emotional shock was therefore undertaken in my laboratory, in collaboration with Dr. D. H. Dolley.[2] These histologic studies were later extended, in collaboration with Drs. J. B. Austin and F. W. Hitchings, to include exhaustion from many other causes, such as exertion, infection, foreign protein reaction, acids, drug stimulants, excision of organs and activating secretions.[3] The identical effects produced in each instance on the histologic structure of the brain, the suprarenals and the liver, and the fact that in none of these studies could the primary cause of exhaustion be completely isolated, nor was it possible to determine exactly what fraction of the end-result was due to each contributing factor, led us to undertake an investigation of the exhaustion produced by the most normal type of energy transformation, involving neither an excessive drive nor any pathologic influence, namely, the exhaustion due to prolonged consciousness, or insomnia.

Since into the average normal conscious state enter various factors, such as muscular exertion, emotion and "mental work," it follows that these factors represent merely varying degrees of intensity of the colorless consciousness which runs along the quiescent border of sleep. Therefore, the organism may do as much work of an identical kind in a tense quarter of an hour of such concentrated consciousness, as is represented by a violent muscular exertion or an overwhelming emotion, as is done in several days of droning consciousness.

But if droning consciousness with its slower rate of energy transformation is continued long enough, without even a moment of restoring sleep, then a degree of exhaustion would be reached as profound as that produced by the drive of a violent muscular struggle, of an intense emotion, of physical injury, of infection, etc., and the histologic lesions wrought by insomnia would be identical with those wrought by exertion, emotion, infection, etc. Moreover, it would follow, that, if an animal is partially exhausted by insomnia, its complete exhaustion or death could be caused by less exertion, less emotion, less injury, less infection than would exhaust or kill a normal animal.

---

2. Dolley, D. H.: J. A. M. A. **68**:756-757, 1917; J. M. Research **34**:305-323, 1916; ibid. **22**:331-378, 1910; ibid. **24**:309-343, 1911; ibid. **21**:95-113, 1909. Dolley, D. H., and Crile, G. W.: J. M. Research **20**:275-295, 1909.

3. Crile, G. W.: Proc. Soc. Exper. Biol. & Med. **7**:87-88, 1909-1910; Tr. Am. Surg. A. **28**:553-559, 1910. Hitchings, F. W.: J. Exper. Med. **20**:595-598, 1914.

Figure 1

Fig. 1.—Classification of brain cells, showing progressive stages of exhaustion: *A*, Stage 1: The so-called hyperchromatic stage. The changes consist essentially in an increase in the chromatic material, both diffuse and in formed masses. The increase is not confined to the cytoplasm but occurs also in the nucleoplasm. *B*, Stage 2: The normal average amount of chromatin is present in the cell body, but it is beginning to disappear from the dendrite. Except for the latter change, this represents the practically normal cell. *C*, Stage 3: There is well marked disappearance of the chromatin. The tendency of that which remains is to collect peripherally in both the cytoplasm and the nucleoplasm. The cell and the nucleolus are somewhat swollen. *D*, Stage 4: The chromatin has almost entirely disappeared from the cytoplasm, which is beginning to show signs of disintegration. *E*, Stage 5: Except in the nucleolus, there is no chromatin inside the nucleus, and very little outside. Vacuolization and disintegration of the cytoplasm are very apparent. *F*, Stage 6: The chromatin in the nucleolus is all that is left. The nucleoplasm is vacuolated. *G*, Stage 7: The chromatin in the nucleolus is passing out into the cytoplasm. The nucleoplasm is still further degenerated. *H*, Stage 8. The process of disintegration is carried still further. *I*, Stage 9: The chromatin has disappeared even from the nucleolus. The nuclear membrane has almost disappeared. The cell membrane is extensively ruptured. The cell is dead.

Likewise, if the lesions in the brain, the liver and the suprarenals, which are produced by insomnia, are an index of the loss of physical power, and if the only normal antithesis of consciousness is *sleep*, then we should find that the histologic lesions of emotion, exertion and injury, like the lesions of insomnia, can be repaired only during sleep. Further, if reconstruction of the cells of the brain, the liver and the suprarenals occurs only during sleep, can a similar cellular reconstruction be accomplished by artificially produced states which resemble sleep? Is it possible to induce by artificial means a state in which restoration is effected without loss of consciousness in sleep—a state in which the respiration and pulse are slower, the body temperature diminished, histologic changes in the brain, the liver and the suprarenals are in part at least repaired and the body energy is in part at least restored?

If there is an artificially induced state in which these results are achieved, then, conversely, in a man or animal in that state, injury or infection would produce slighter histologic changes in the brain, the liver and the suprarenals, would cause less alteration of the pulse, temperature and respiration, and consequently should produce a slighter degree of exhaustion.

To test these hypotheses, our researches have included not only early and late histologic, biochemical, physical and clinical studies of animals subjected to varying degrees of insomnia, but also the effects of varying periods of sleep on the resultant lesions. We compared the restorative effects of sleep with those of substitutes for normal sleep, such as morphin and nitrous oxid. The study of diurnal sleep naturally suggested the study of seasonal sleep, and we added to our research histologic examinations of hibernating animals, before, during and after the period of hibernation.

Since every manifestation of energy transformation is in the final analysis but a more or less intensified consciousness, studies of normal consciousness and of sleep give the least complicated picture of the mechanism by which energy is transformed, as well as the most fundamental criterion for the study of all forms of intensified consciousness.

A. HISTOLOGIC STUDIES

Strong, healthy rabbits were chosen as the subjects of these experiments. They were kept awake by relays of medical students for periods ranging from 96 to 118 hours. They were given abundant food and water and were subject to the least disturbance that would suffice to keep them awake. Thus they existed without exercise, injury, infection or apparent emotion—*but without sleep.*

The Brain Cells.—The charts show the results obtained by plotting individual differential Purkinje cell counts [4] from seven rabbits in each of two series of experiments, in one series the recovery period being nine and one-half days, in the other sixteen days. A period of more than a year intervened between these two series of experiments; the differential counts were made at irregular intervals, and until the data were all in hand what its graphic expression would show was known to nobody (Fig. 2).

TABLE 1.—DIFFERENTIAL PURKINJE CELL COUNTS: NORMAL STANDARD FOR RABBITS *

	Active		Fatigued				Exhausted			
	Stage I	Stage II	Stage III	Stage IV	Stage V	Stage VI	Stage VII	Stage VIII	Stage IX	Stage X
Normal Rabbit 1....	30	32	26	8	4	0	0	0	0	0
Grouped.....	62%		38%				0%			
Normal Rabbit 2....	27	44	12	9	4	4	0	0	0	0
Grouped.....	71%		29%				0%			
Normal Rabbit 3....	16	48	21	11	3	1	0	0	0	0
Grouped.....	64%		36%				0%			
Normal Rabbit 4....	29	32	19	13	6	0	0	1	0	0
Grouped.....	61%		38%				1%			
Normal Rabbit 5....	29	35	20	8	4	3	0	1	0	0
Grouped.....	64%		35%				1%			
Normal Rabbit 6....	25	40	15	6	6	6	2	0	0	0
Grouped.....	65%		33%				2%			
Normal Rabbit 7....	35	30	22	4	5	2	0	2	0	0
Grouped.....	65%		33%				2%			
Normal Rabbit 8....	41	27	18	7	4	3	0	0	0	0
Grouped.....	68%		32%				0%			
Normal Rabbit 9....	37	29	19	6	6	3	0	0	0	0
Grouped.....	66%		34%				0%			
Normal Rabbit 10...	29	33	23	7	4	3	0	1	0	0
Grouped.....	62%		37%				1%			
Group average.....	64.8%		34.5%				0.7%			

* In this table and in Tables 2 and 3, the figures are derived from the careful study of 2,000 cells that were actually counted and of many more that were rejected because they had been cut through the nucleolus and axon.

It should be stated here that in general our experiments have shown that any activation produces nerve cell changes throughout the central nervous system, these changes being most marked in the cortex, less in the cerebellum and clearly demonstrable in the medulla and the cord. As the changes in the Purkinje cells closely parallel those in the cortical and other nerve cells, and as the Purkinje cells by reason of their distinctive size and shape most graphically portray the various stages of stimulation and exhaustion, they were used in making the differential cell counts described herewith, and we shall employ them for illustrative purposes throughout this discussion (Figs. 3 and 4).

4. Since accurate observations depended on the establishment of a standard of cell classification, a method of making differential cell counts was devised by Dr. Hitchings, and the arbitrary classification shown in Figure 1 was adopted by Dr. Dolley and Dr. Austin.

It will be seen that the period before the maximum increase and maximum decrease in the number of the active and fatigued cells, respectively, differed in the two series, in one being nine days and in the other three days. This difference is undoubtedly due to the fact that, owing to a combination of minor factors, the rabbits in one series

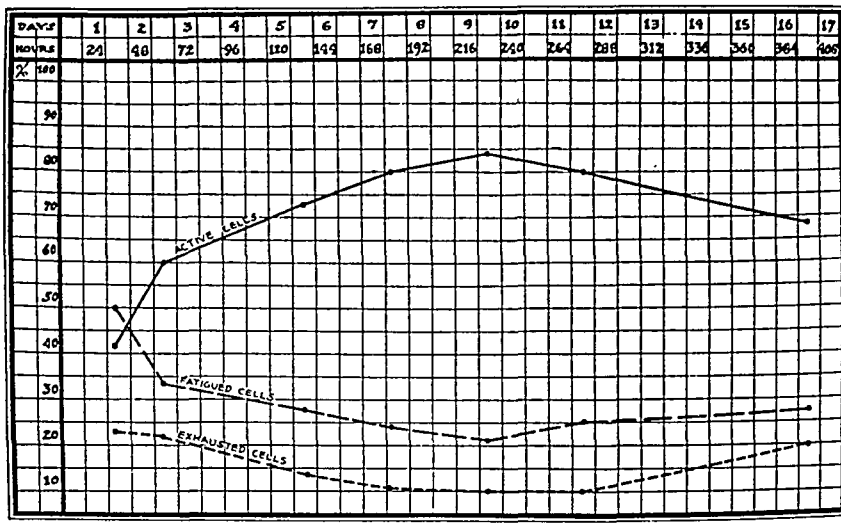

A

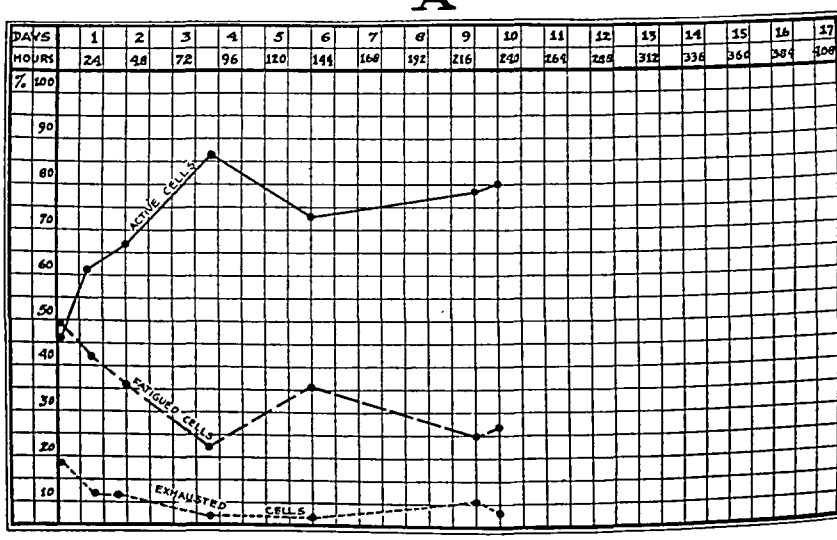

B

Fig. 2.—Progressive changes in the differential Purkinje cell count during recovery from insomnia.

were more affected than those in the other series. The corresponding difference in clinical behavior bears out this assumption.

It will also be seen that the maximum increase of the active cells is considerably above the average of 64.8 per cent. found in normal

rabbits (Table 1), so that there was apparently *a period of overreaction* (hyperchromatism).

In both series, the percentage of exhausted cells begins to increase again after the period of maximum reaction. In one series, every rabbit not killed by this time died soon after of a cause unexplained even after careful necropsies. We concluded, therefore, that the original "dose" of insomnia was really a fatal one, and that the apparently favorable reaction was only temporary, death doubtless being due to the fact that the brain cell destruction increased again until a nonsurvivable limit



Fig. 3.—Changes in the Purkinje cells of the cerebellum produced by long insomnia: *A*, section of normal cerebellum of rabbit; *B*, section of cerebellum of rabbit after insomnia of one hundred and nine hours' duration. The well stained, clearly defined Purkinje cells in *A* may be compared with the faint traces of the Purkinje cells which are barely visible in *B*. × 100.

had been reached. It is probable that no individual, man or animal, can survive the loss of 15 per cent. of his brain cells.

The Liver.—In observations on the livers from a series in which animals were killed at varying times after prolonged insomnia, the liver was found to be markedly altered five times, moderately altered once, and normal twice. In other words, it was more or less affected in six out of eight experiments.

The changes were most distinct near the peripheries of the lobules, and not only were the cell contents affected, but the cell walls also.

It will be seen that the period before the maximum increase and maximum decrease in the number of the active and fatigued cells, respectively, differed in the two series, in one being nine days and in the other three days. This difference is undoubtedly due to the fact that, owing to a combination of minor factors, the rabbits in one series

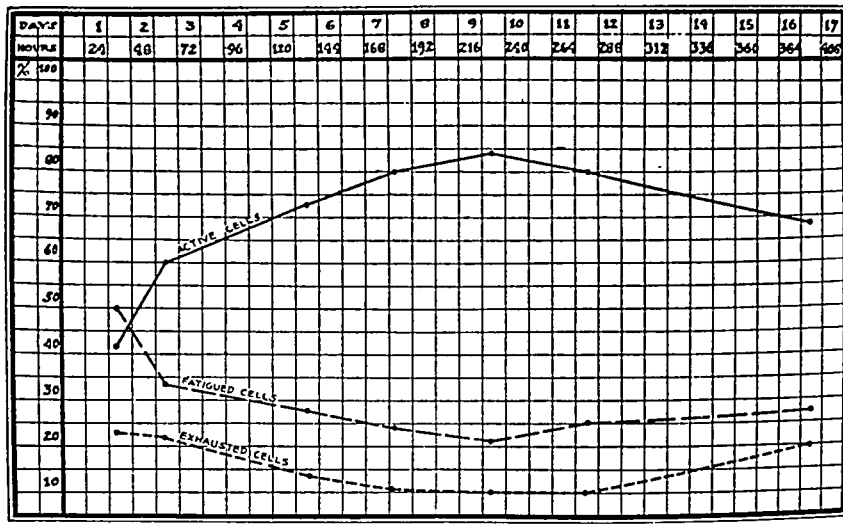

A

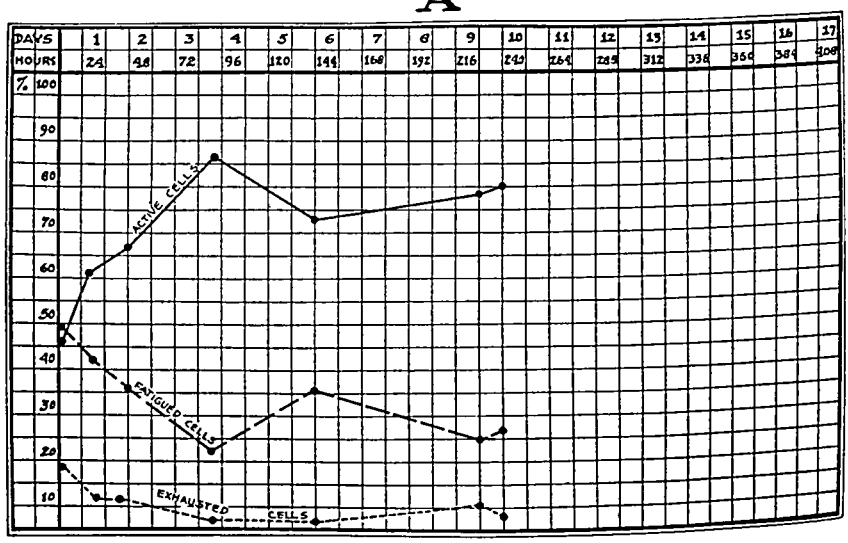

B

Fig. 2.—Progressive changes in the differential Purkinje cell count during recovery from insomnia.

were more affected than those in the other series. The corresponding difference in clinical behavior bears out this assumption.

It will also be seen that the maximum increase of the active cells is considerably above the average of 64.8 per cent. found in normal

rabbits (Table 1), so that there was apparently *a period of overreaction* (hyperchromatism).

In both series, the percentage of exhausted cells begins to increase again after the period of maximum reaction. In one series, every rabbit not killed by this time died soon after of a cause unexplained even after careful necropsies. We concluded, therefore, that the original "dose" of insomnia was really a fatal one, and that the apparently favorable reaction was only temporary, death doubtless being due to the fact that the brain cell destruction increased again until a nonsurvivable limit

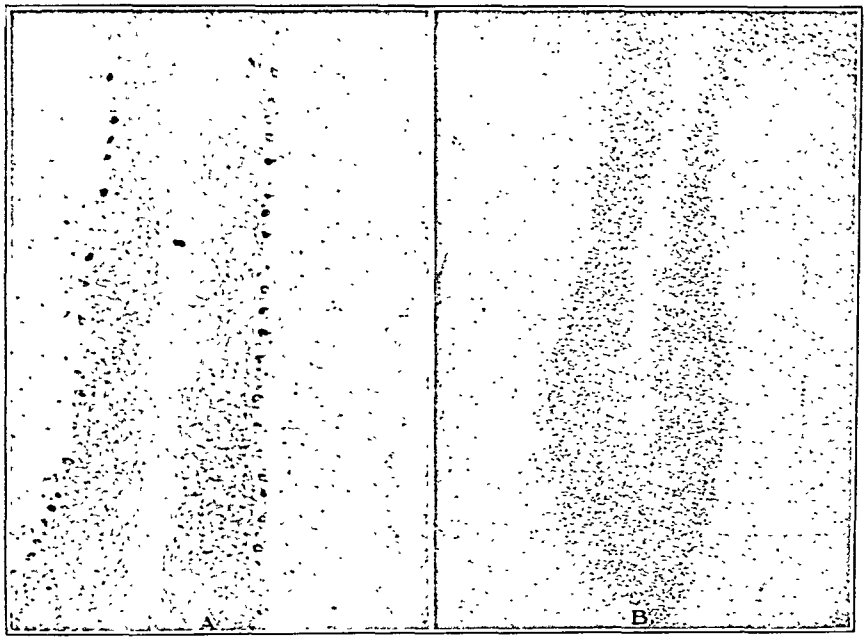

Fig. 3.—Changes in the Purkinje cells of the cerebellum produced by long insomnia: *A*, section of normal cerebellum of rabbit; *B*, section of cerebellum of rabbit after insomnia of one hundred and nine hours' duration. The well stained, clearly defined Purkinje cells in *A* may be compared with the faint traces of the Purkinje cells which are barely visible in *B*. × 100.

had been reached. It is probable that no individual, man or animal, can survive the loss of 15 per cent. of his brain cells.

The Liver.—In observations on the livers from a series in which animals were killed at varying times after prolonged insomnia, the liver was found to be markedly altered five times, moderately altered once, and normal twice. In other words, it was more or less affected in six out of eight experiments.

The changes were most distinct near the peripheries of the lobules, and not only were the cell contents affected, but the cell walls also.

The nuclei were often eccentric, sometimes distorted in shape and in many instances had disappeared entirely. The granules were diminished in number or had practically disappeared in many cells. There were vacuoles in many cells. The most striking change, however, was the marked swelling of the cells as a whole. In many cells, this was so extreme that it obliterated the normal linear arrangement of the cells and occluded the lymph and venous spaces between the rows (Figs. 5 and 6).

TABLE 2.—CHANGES IN THE LIVER AFTER VARYING PERIODS OF RECOVERY FROM PROLONGED INSOMNIA

Time of Recovery After Insomnia	Effect on Liver
Immediately after	Markedly altered
Immediately after	Markedly altered
18½ hours	Normal
36½ hours	Markedly altered
68½ hours	Markedly altered
5½ days	Slightly altered
9 days	Moderately altered
9½ days	Normal
12½ days	Markedly altered

TABLE 3.—CHANGES IN THE SUPRARENALS AFTER VARIOUS PERIODS OF RECOVERY FROM PROLONGED INSOMNIA

Time of Recovery After Insomnia	Cortex	Medulla
Immediately after	Markedly altered	
Immediately after	Slightly altered	Normal
18½ hours	Normal	Normal
36½ hours	Slightly altered	Normal
68½ hours	Slightly altered	
5½ days	Normal	Normal
9 days	Slightly altered	Normal
9½ days	Slightly altered	

In a few instances, especially prepared liver sections stained by Best's carmin method showed that in the cases in which much damage had been done to the liver there was a corresponding decrease in the glycogen content. Apparently, therefore, the organic changes were accompanied by loss of functional power, at least in this one particular.

The Suprarenals.—The histologic changes in the suprarenals can be grouped according to their occurrence in the medullary or the cortical portion. Those in the medullary portion were negligible, in five out of six observations the medulla being well stained and otherwise normal, while in the sixth case there was but slight alterations. As for the cortex, on the other hand, in eight cases, six cortices showed alteration, while two were normal. In the former, not only were the cell contents affected, but in many instances the cell walls themselves. Many of the nuclei were irregular in shape and eccentric, while in some cells the nuclei had disappeared. The cytoplasm was frequently vacuolated, and



Fig. 4.—Changes in the Purkinje cells of the cerebellum produced by prolonged insomnia: *A*, section of normal cerebellum of rabbit; *B*, section of cerebellum of rabbit after insomnia of one hundred and nine hours' duration. × 1600. In *A* may be noted the clearly defined outline, the well defined nucleus and general distribution of the chromatin in the Purkinje cell, indicating that the cell is in a normally active stage. Contrast this with *B*, noting the disappearance of the cell membrane, chromatolysis, and the faint nucleus and nucleolus in the only Purkinje cell.

in many cells the walls were ruptured, often in several places (Figs. 7 and 8). We can offer no explanation for the localization of the histologic changes in the cortex, rather than in the medulla, of the suprarenals.

The Thyroid.—In five observations on the thyroid, nothing abnormal was found. The colloid material varied in amount in individual

experiments, but was neither particularly increased nor diminished. In certain instances, there was an increase in the interstitial connective tissue. There was no consistent tendency toward any kind of structural change.

The Pancreas.—Five observations on the pancreas were as negative as those on the thyroid.

The Kidneys.—In six out of seven observations, the kidneys were normal. In the one exception the alteration was slight.

TABLE 4.—HISTOLOGIC CHANGES PRODUCED BY INSOMNIA

Exp. No.	Animal	Activator	Duration of Activation	Brain Cells, Condition Per Cent.	Suprarenals	Liver
5	Rabbit	Insomnia	96 hours; killed immediately	Active.....51 Fatigued...35 Exhausted..14	Cortex: great loss of cytoplasm and vacuolation. Medulla: affected but not so much as cortex	Condition bad: cytoplasm almost gone; nuclei eccentric and not well stained; cells contained large empty spaces
14	Rabbit	Insomnia	105 hours	Active.....28 Fatigued...60 Exhausted..12	Cortex: marked loss of cytoplasm and vacuolation throughout	Marked uniform loss of cytoplasm throughout; great dilatation of capillaries; stain pale
15	Rabbit	Insomnia	105 hours	Active.....28 Fatigued...53 Exhausted..19	Cortex: almost normal; a few cells showed slight loss of cytoplasm Medulla: marked loss of cytoplasm and vacuolation; nuclei deeply stained; cytoplasm very lightly stained	Normal; no loss of cytoplasm
1	Rabbit	Insomnia	109 hours	Active.....53 Fatigued...33 Exhausted..14	Cortex: marked loss of cytoplasm in outer ⅓ of cortex; vacuolated	Loss of cytoplasm with small vacuoles in all cells, but more marked around periphery of lobules
20	Rabbit	Insomnia	118 hours	Active.....42 Fatigued...44 Exhausted..14	Cortex: marked loss of cytoplasm but with some normal cells in rows Medulla: normal	All cells swollen, vacuolated and with great or even total loss of cytoplasm
27	Rabbit	Insomnia	118 hours	Active.....47 Fatigued...28 Exhausted..25	Cortex: most cells normal; narrow strip of outer portion shows slight loss of cytoplasm Medulla: normal	Great loss of cytoplasm in all cells; cells swollen, vacuolated, irregular in outline with eccentric nuclei

The Spleen.—In five observations the spleen was normal.

The Stomach and Intestines.—In thirteen observations, unevenly distributed among the stomach and small and large intestines, no abnormal condition was found.

Restoration of the Cells Exhausted by Insomnia.—In order, if possible, to discover a clue to the manner in which cells exhausted from

TABLE 5.—EFFECT OF VARYING PERIODS OF RECOVERY ON THE HISTOLOGIC CHANGES PRODUCED BY INSOMNIA

Exp. No.	Animal	Activator	Duration of Activation	Brain Cells, Condition Per Cent.	Suprarenals	Liver
28	Rabbit	Insomnia Recovery	100 hours; killed 18½ hours after termination of insomnia	Active.....56 Fatigued...37 Exhausted.. 7	Cortex: normal Medulla: normal	Normal; no loss of cytoplasm
29	Rabbit	Insomnia Recovery	100 hours; killed 36½ hours after termination of insomnia	Active.....62 Fatigued...31 Exhausted.. 7	Cortex: slight loss of cytoplasm in scattered areas Medulla: normal	Loss of cytoplasm in almost all cells and vacuolation in many
30	Rabbit	Insomnia Recovery	100 hours; killed 68½ hours after termination of insomnia	Active.....81 Fatigued...17 Exhausted.. 2	Cortex: slight uniform loss of cytoplasm with occasional vacuolated cells Medulla: slight uniform loss of cytoplasm	Extreme loss of cytoplasm and vacuolation in almost all cells; a few cells around central veins contained more cytoplasm
31	Rabbit	Insomnia Recovery	100 hours; killed 5½ days after termination of insomnia	Active.....68 Fatigued...31 Exhausted.. 1	Cortex: normal Medulla: normal	Cells normal around periphery of lobules; some loss of cytoplasm around central veins
32	Rabbit	Insomnia Recovery	100 hours; killed 9 days after termination of insomnia	Active.....74 Fatigued...20 Exhausted.. 6	Cortex: slight loss of cytoplasm in outer ⅓	Loss of cytoplasm in all cells but less around central veins
33	Rabbit	Insomnia Recovery	100 hours; killed 9½ days after termination of insomnia	Active.....75 Fatigued...21 Exhausted.. 4	Cortex: slight loss of cytoplasm and vacuolation in outer cells Medulla: normal	Normal
16	Rabbit	Insomnia Recovery	105 hours; killed 36 hours after termination of insomnia	Active.....32 Fatigued...53 Exhausted..15	Cortex: occasional cell in outer 1/22 shows loss of cytoplasm and vacuolation Medulla: pale; loss of cytoplasm and vacuolation	Normal; no loss of cytoplasm
17	Rabbit	Insomnia Recovery	105 hours; killed 8½ days after termination	Active.....50 Fatigued...33 Exhausted..17	Cortex: a few cells vacuolated in outer ⅓; otherwise normal Medulla: normal	Normal
18	Rabbit	Insomnia Recovery	105 hours; killed 12½ days after termination of insomnia	Active.....60 Fatigued...30 Exhausted..10	Cortex: normal Medulla: pale; less chromophil than normal	Marked loss of cytoplasm with vacuolation in some cells; nuclei almost all eccentric
19	Rabbit	Insomnia Recovery	105 hours; killed 25½ days after termination of insomnia	Active.....32 Fatigued...51 Exhausted..17	Cortex: slight loss of cytoplasm in a few cells; mostly normal	Almost all cells markedly vacuolated and with total loss of cytoplasm in some cases
7	Rabbit	Insomnia Recovery	118 hours; killed 28¾ hours after termination of insomnia	Active.....37 Fatigued...45 Exhausted..18	.....	No loss of cytoplasm or vacuolation; normal
8	Rabbit	Insomnia Recovery	118 hours; killed 53½ hours after termination of insomnia	Active.....55 Fatigued...28 Exhausted..17	.....	No loss of cytoplasm or vacuolation; normal
9	Rabbit	Insomnia Recovery	118 hours; killed 126½ hours after termination of insomnia	Active.....68 Fatigued...23 Exhausted.. 9	.....	No loss of cytoplasm or vacuolation; stain pale

TABLE 5.—EFFECT OF VARYING PERIODS OF RECOVERY ON THE HISTOLOGIC CHANGES PRODUCED BY INSOMNIA—(*Continued*)

Exp. No.	Animal	Activator	Duration of Activation	Brain Cells, Condition Per Cent.	Suprarenals	Liver
10	Rabbit	Insomnia Recovery	118 hours; killed 174½ hours after termination of insomnia	Active.....75 Fatigued...19 Exhausted.. 6	Cortex: no loss of cytoplasm or vacuolation; normal	Large vacuoles and loss of cytoplasm in extreme periphery of lobules only; otherwise normal
11	Rabbit	Insomnia Recovery	118 hours; killed 222 hours after termination of insomnia	Active.....79 Fatigued...16 Exhausted.. 5	.....	Marked loss of cytoplasm and large vacuoles present in the lobules
12	Rabbit	Insomnia Recovery	118 hours; killed 270½ hours after termination of insomnia	Active.....75 Fatigued...20 Exhausted.. 5	Cortex: normal except for occasional cell toward periphery with slight loss of cytoplasm Medulla: same as cortex	
13*	Rabbit	Insomnia Recovery	118 hours; killed 390 hours after termination of insomnia	Active.....63 Fatigued...22 Exhausted..15	.....	No loss of cytoplasm or vacuolation

* The nuclei of many brain cells were very small, especially those in Stages 3 and 4, inclusive.

TABLE 6.—EFFECT OF SLEEP ON THE HISTOLOGIC CHANGES PRODUCED BY INSOMNIA

Exp. No.	Animal	Activator	Duration of Activation	Brain Cells, Condition Per Cent.	Suprarenals	Liver
6	Rabbit	Insomnia Sleep	96 hours; killed after 8 hours sleep	Active.....67 Fatigued...21 Exhausted..12	Cortex: slight loss of cytoplasm Medulla: about normal	Condition fair; nuclei pale, shrunken only in an occasional cell in which there was vacuolation and the cytoplasm was diminished; in most cells cytoplasm dense and normal
2	Rabbit	Insomnia Sleep	109 hours; killed after 6½ hours sleep	Active.....68 Fatigued...18 Exhausted..14	Cortex: very marked loss of cytoplasm; large vacuoles present	

any cause are restored, experiments were performed (*a*) in which varying periods of recovery were allowed; (*b*) in which a definite period of sleep was allowed immediately after the period of insomnia, the animal being killed at the end of the period of sleep; (*c*) in which various agents were administered during the period of insomnia or at its termination. The results of these experiments are given in Tables 4, 5, 6, 7 and 8. The restorative value of sleep is clearly shown, as is the efficiency of nitrous oxid-oxygen as a sleep substitute.

TABLE 7.—EFFECT OF NITROUS OXID-OXYGEN ANESTHESIA ON HISTOLOGIC CHANGES PRODUCED BY INSOMNIA

Exp. No.	Animal	Activator	Duration of Activation	Brain Cells, Condition Per Cent.	Suprarenals	Liver
4	Rabbit	Insomnia; intermittent nitrous oxid anesthesia	109 hours; during this period oxid was given for one hour out of every six	Active.....94 Fatigued... 5 Exhausted.. 1		
3	Rabbit	Insomnia; continuous nitrous oxid anesthesia	109 hours; killed after 6½ hours sleep	Active.....27 Fatigued...46 Exhausted..27	Cortex: slight loss of cytoplasm and moderate vacuolation of some cells; occasional cell totally vacuolated Medulla: slight loss of cytoplasm and vacuolation	Most cells normal; only slight loss of cytoplasm in an occasional cell

TABLE 8.—EFFECTS OF VARIOUS AGENTS ON THE HISTOLOGIC CHANGES PRODUCED BY INSOMNIA

Exp. No.	Animal	Activator	Duration of Activation	Brain Cells, Condition Per Cent.	Suprarenals	Liver
20	Rabbit	Insomnia; no sleep; epinephrin, 1/1000, mV every 4 hours hypodermically	112 hours	Active.....22 Fatigued...59 Exhausted..19	Cortex: normal Medulla: normal	Cells around central vein normal; all others greatly vacuolated and with eccentric nuclei
21	Rabbit	Insomnia; no sleep; sodium bicarbonate, 10 c.c. saturated solution by rectum twice a day	112 hours	Active.....48 Fatigued...38 Exhausted..14	Cortex: normal Medulla: normal	Great loss of cytoplasm; all cells vacuolated, nuclei large, well stained eccentric
22	Rabbit	Insomnia; no sleep; dextrose 10 c.c. 2% solution by rectum, twice a day	112 hours	Active.....35 Fatigued...49 Exhausted..16	Cortex: slight loss of cytoplasm throughout but more marked peripherally Medulla: normal	Marked loss of cytoplasm in peripheral cells of lobules with vacuolation in some cells; cells around central veins normal*
23	Rabbit	Insomnia; no sleep; sodium bicarbonate saturated solution 5 c.c. and dextrose 2% solution 10 c.c. by rectum twice daily; also epinephin mV every 4 hours	112 hours	Active.....38 Fatigued...46 Exhausted..16	Cortex: general loss of cytoplasm; no vacuolation Medulla: normal	In most cells only slight loss of cytoplasm but in some around the periphery of the lobules there was marked loss
24	Rabbit	Insomnia; no sleep; morphin ¼ grain given during the 6 hours after insomnia ended; rabbit moved just as if awake during this time	112 hours insomnia and 6 more under morphin	Active.....47 Fatigued...45 Exhausted.. 8	Cortex: Most of the cortex showed loss of cytoplasm Medulla: normal	All cells showed great or complete loss of cytoplasm; nuclei eccentric
25	Rabbit	Same as Exp. 24	Same as Exp. 24	Active.....55 Fatigued...38 Exhausted.. 7	Cortex: Marked loss of cytoplasm everywhere Medulla: stained poorly	Marked loss of cytoplasm but less marked than in Exp. 22 (see Table 5)

* Glycogen test showed corresponding loss of glycogen.

TABLE 5.—EFFECT OF VARYING PERIODS OF RECOVERY ON THE HISTOLOGIC CHANGES PRODUCED BY INSOMNIA—(*Continued*)

Exp. No.	Animal	Activator	Duration of Activation	Brain Cells, Condition Per Cent.	Suprarenals	Liver
10	Rabbit	Insomnia Recovery	118 hours; killed 174½ hours after termination of insomnia	Active.....75 Fatigued...19 Exhausted.. 6	Cortex: no loss of cytoplasm or vacuolation; normal	Large vacuoles and loss of cytoplasm in extreme periphery of lobules only; otherwise normal
11	Rabbit	Insomnia Recovery	118 hours; killed 222 hours after termination of insomnia	Active.....79 Fatigued...16 Exhausted.. 5	.....	Marked loss of cytoplasm and large vacuoles present in the lobules
12	Rabbit	Insomnia Recovery	118 hours; killed 270½ hours after termination of insomnia	Active.....75 Fatigued...20 Exhausted.. 5	Cortex: normal except for occasional cell toward periphery with slight loss of cytoplasm Medulla: same as cortex	
13*	Rabbit	Insomnia Recovery	118 hours; killed 390 hours after termination of insomnia	Active.....63 Fatigued...22 Exhausted..15	.....	No loss of cytoplasm or vacuolation

* The nuclei of many brain cells were very small, especially those in Stages 3 and 4, inclusive.

TABLE 6.—EFFECT OF SLEEP ON THE HISTOLOGIC CHANGES PRODUCED BY INSOMNIA

Exp. No.	Animal	Activator	Duration of Activation	Brain Cells, Condition Per Cent.	Suprarenals	Liver
6	Rabbit	Insomnia Sleep	96 hours; killed after 8 hours sleep	Active.....67 Fatigued...21 Exhausted..12	Cortex: slight loss of cytoplasm Medulla: about normal	Condition fair; nuclei pale, shrunken only in an occasional cell in which there was vacuolation and the cytoplasm was diminished; in most cells cytoplasm dense and normal
2	Rabbit	Insomnia Sleep	109 hours; killed after 6½ hours sleep	Active.....68 Fatigued...18 Exhausted..14	Cortex: very marked loss of cytoplasm; large vacuoles present	

any cause are restored, experiments were performed (*a*) in which varying periods of recovery were allowed; (*b*) in which a definite period of sleep was allowed immediately after the period of insomnia, the animal being killed at the end of the period of sleep; (*c*) in which various agents were administered during the period of insomnia or at its termination. The results of these experiments are given in Tables 4, 5, 6, 7 and 8. The restorative value of sleep is clearly shown, as is the efficiency of nitrous oxid-oxygen as a sleep substitute.

TABLE 7.—EFFECT OF NITROUS OXID-OXYGEN ANESTHESIA ON HISTOLOGIC CHANGES PRODUCED BY INSOMNIA

Exp. No.	Animal	Activator	Duration of Activation	Brain Cells, Condition Per Cent.	Suprarenals	Liver
4	Rabbit	Insomnia; intermittent nitrous oxid anesthesia	109 hours; during this period oxid was given for one hour out of every six	Active.....94 Fatigued... 5 Exhausted.. 1		
3	Rabbit	Insomnia; continuous nitrous oxid anesthesia	109 hours; killed after 6½ hours sleep	Active.....27 Fatigued...46 Exhausted..27	Cortex: slight loss of cytoplasm and moderate vacuolation of some cells; occasional cell totally vacuolated Medulla: slight loss of cytoplasm and vacuolation	Most cells normal; only slight loss of cytoplasm in an occasional cell

TABLE 8.—EFFECTS OF VARIOUS AGENTS ON THE HISTOLOGIC CHANGES PRODUCED BY INSOMNIA

Exp. No.	Animal	Activator	Duration of Activation	Brain Cells, Condition Per Cent.	Suprarenals	Liver
20	Rabbit	Insomnia; no sleep; epinephrin, 1/1000, mV every 4 hours hypodermically	112 hours	Active.....22 Fatigued...59 Exhausted..19	Cortex: normal Medulla: normal	Cells around central vein normal; all others greatly vacuolated and with eccentric nuclei
21	Rabbit	Insomnia; no sleep; sodium bicarbonate, 10 c.c. saturated solution by rectum twice a day	112 hours	Active.....48 Fatigued...38 Exhausted..14	Cortex: normal Medulla: normal	Great loss of cytoplasm; all cells vacuolated, nuclei large, well stained eccentric
22	Rabbit	Insomnia; no sleep; dextrose 10 c.c. 2% solution by rectum, twice a day	112 hours	Active.....35 Fatigued...49 Exhausted..16	Cortex: slight loss of cytoplasm throughout but more marked peripherally Medulla: normal	Marked loss of cytoplasm in peripheral cells of lobules with vacuolation in some cells; cells around central veins normal*
23	Rabbit	Insomnia; no sleep; sodium bicarbonate saturated solution 5 c.c. and dextrose 2% solution 10 c.c. by rectum twice daily; also epinephin mV every 4 hours	112 hours	Active.....38 Fatigued...46 Exhausted..16	Cortex: general loss of cytoplasm; no vacuolation Medulla: normal	In most cells only slight loss of cytoplasm but in some around the periphery of the lobules there was marked loss
24	Rabbit	Insomnia; no sleep; morphin ½ grain given during the 6 hours after insomnia ended; rabbit moved just as if awake during this time	112 hours insomnia and 6 more under morphin	Active.....47 Fatigued...45 Exhausted.. 8	Cortex: Most of the cortex showed loss of cytoplasm Medulla: normal	All cells showed great or complete loss of cytoplasm; nuclei eccentric
25	Rabbit	Same as Exp. 24	Same as Exp. 24	Active.....55 Fatigued...38 Exhausted.. 7	Cortex: Marked loss of cytoplasm everywhere Medulla: stained poorly	Marked loss of cytoplasm but less marked than in Exp. 32 (see Table 5)

* Glycogen test showed corresponding loss of glycogen.

Summary of Histologic Findings.—Prolonged insomnia causes demonstrable histologic changes in three organs only: the brain, the liver and the suprarenals.

(*a*) *Brain-Cell Changes Produced by Insomnia:* 1. Insomnia of more than 100 hours' duration caused histologic changes in all parts of the central nervous system, these changes being most marked in the cortex and cerebellum, but clearly demonstrable also in the medulla and the cord. On account of the comparative ease of application of differential counts of the Purkinje cells, the changes produced in these

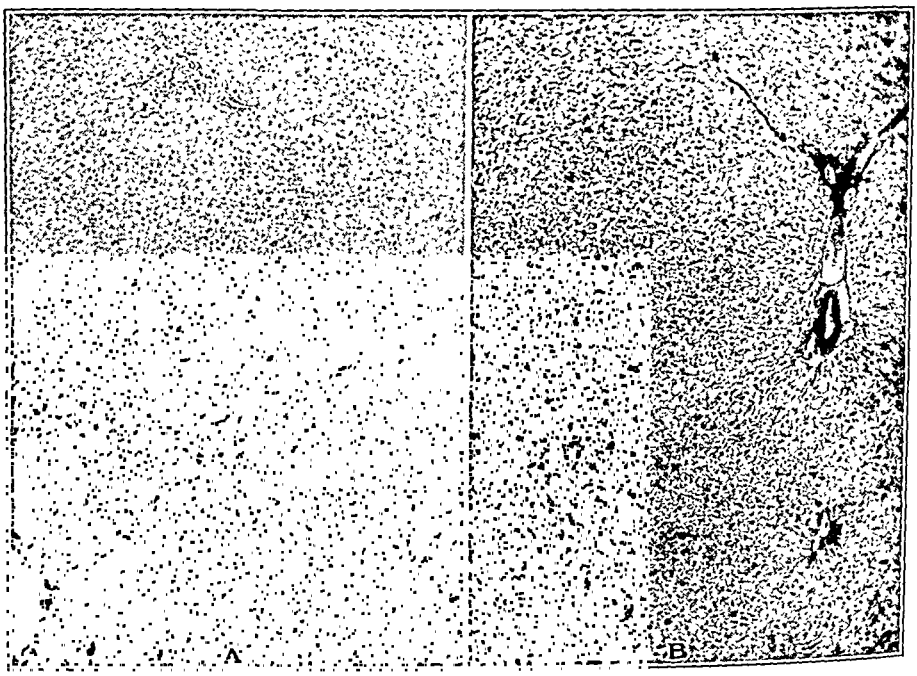

Fig. 5.—Changes in the cells of the liver produced by prolonged insomnia: *A*, section of normal liver of rabbit; *B*, section of liver of rabbit after insomnia of one hundred and nine hours' duration. × 100. The general disappearance of cytoplasm may be noted in *B*.

cells have been taken as an index of the changes in other parts of the central nervous system.

2. The brain-cell changes consisted in chromatolysis; alteration of the nucleoplasm relation; eccentric position of many nuclei; enlargement of many cells with rupture of their cell and nuclear membranes, and disintegration and death of many cells.

3. One seance of sleep restored all the cells except those in which the destructive process had progressed to the disintegration of the nucleus.

4. In eleven cases in which the animals died apparently as a result of the insomnia alone, differential cell counts demonstrated that 15 per cent. of the cells were exhausted. It would appear, therefore, that life does not continue after approximately 15 per cent. of the brain cells have become fully exhausted.

5. In those animals, which instead of being allowed natural sleep were placed for the same length of time under nitrous oxid-oxygen anesthesia, 90 per cent. of the brain cells became hyperchromatic—a

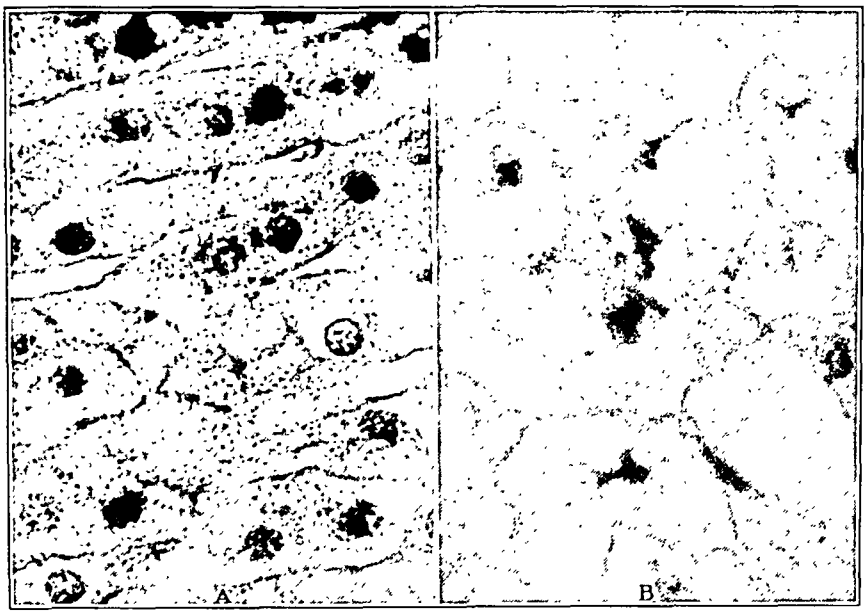

Fig. 6.—Changes in the cells of the liver produced by prolonged insomnia: *A*, section of normal liver of rabbit; *B*, section of liver of rabbit after insomnia of one hundred and nine hours' duration. × 1600. The disappearance of some nuclei in *B* and the misshapen and eccentric appearance of the rest may be noted.

significant fact, the logical sequence of which will be elaborated elsewhere.

6. Apparently the exhausted cells are removed by phagocytic action (Fig. 9).

(*b*). *Histologic Changes in the Liver Produced by Insomnia:* 1. Insomnia for more than 100 hours caused demonstrable histologic changes in the liver, these changes being most marked near the periphery of the lobules.

2. The cell changes in the liver consisted in the enlargement or swelling of the cells; general disappearance of cytoplasm; the presence

of vacuolated spaces, and the displacement and occasional disappearance of nuclei.

3. One seance of sleep restored nearly to normal all cells except those in which the nuclei had disappeared.

(*c*) *Histologic Changes in the Suprarenals Produced by Insomnia:* 1. Insomnia for more than 100 hours caused demonstrable histologic changes in the suprarenal cortex.

2. The changes in the suprarenal cortex consisted in enlargement of the cells with occasional rupture of the cell wall; distortion of the cell outlines; eccentric displacement of the nuclei which were often crenated, and general disappearance of cytoplasm.



Fig. 7.—Changes in the cells of the suprarenals produced by prolonged insomnia: *A*, section of normal suprarenal of rabbit; *B*, section of suprarenal of rabbit after insomnia of one hundred and nine hours' duration. ×100. The vacuolated spaces and the general disappearance of cytoplasm in *B* may be noted.

B. PHYSICOCHEMICAL STUDIES—HYDROGEN-ION DETERMINATIONS

The intravenous injection of acid, such as acid sodium phosphate and hydrochloric acid, causes lesions in the brain, the suprarenals and the liver identical in appearance with the lesions of exhaustion from insomnia, exertion, emotion, infection, etc. Therefore, it seemed advisable to determine whether or not the H-ion concentration is increased by insomnia and whether or not the H-ion concentration is altered by

sleep. H-ion determinations were, therefore, made in our laboratory by Dr. M. L. Menten, who had worked for a year with Michaelis and used his gas-chain method.[5]

(*a*) Determinations of the H-ion concentration of the blood of six rabbits, before and after insomnia for ninety-six hours are given in Table 9.

(*b*) Determinations of the H-ion concentration of the blood of six rabbits after insomnia for one hundred hours followed by sleep for twelve hours are given in Table 10.

TABLE 9.—HYDROGEN-ION CONCENTRATION BEFORE AND AFTER INSOMNIA

	Before Insomnia		After Insomnia	
Rabbit 1	p_H—7.67	7.66	p_H—7.62	7.65
Rabbit 2	7.66	7.66	7.68	7.68
Rabbit 3	7.61	7.60	7.70	7.68
Rabbit 4	7.61	7.61	7.65	7.67
Rabbit 5	7.57	7.58	7.70	7.70
Rabbit 6	7.64	7.60	7.66	7.68
Average	7.63	7.62	7.67	7.68

TABLE 10.—HYDROGEN-ION CONCENTRATION AFTER INSOMNIA FOR ONE HUNDRED HOURS FOLLOWED BY SLEEP

Rabbit 1	p_H—7.66	7.67
Rabbit 2	7.61	7.61
Rabbit 3	7.66	7.66
Rabbit 4	7.69	7.64
Rabbit 5	7.64	7.64
Rabbit 6	7.64	7.64
Average	7.65	7.64

We may conclude from these studies that prolonged insomnia alone produces relatively slight or no appreciable alteration in the H-ion concentration of the blood.

(*c*) Determinations of the H-ion concentration *during* sleep: —While on duty at the American Ambulance in Paris during the first year of the war, we had under our care patients with total cross lesions of the spinal cord. The resultant sensory paralysis gave us a long desired opportunity for making H-ion determinations of blood taken from the subject *during sleep*.

5. Menten, M. L., and Crile, G. W.: Am. J. Physiol. **38**:225-232, 1915 Michaelis, Leonor: Einfuhrung in die Farbestoffchemie, Berlin, 1902: Die Wasserstoffionen-konzentration, Berlin, 1914. Crozier, W. J., Rogers, W. B., and Harrison, B. I.: Surg., Gynec. & Obst. **21**:722-727, 1915.

Tests of blood taken from these patients were made for me by Dr. W. J. Crozier, who found no appreciable difference between the H-ion concentration of the blood taken *during sleep* and that taken when the patients were awake.

C. ELECTRIC CONDUCTIVITY MEASUREMENTS

The histologic changes which our previous researches had shown were characteristic of exhaustion from any cause, in particular the changes in the cells of the brain and of the liver, led us to expect that the electrolyte content of the cells, and consequently their conductivity, must be altered. This supposition was strengthened by the studies of the permeability of living cells which have been made by Osterhout,[6] Galeotti,[7] Lillie,[8] Loeb[9] and others.

TABLE 11.—CHANGES IN THE ELECTRIC CONDUCTIVITY OF THE BRAIN AND SPINAL CORD

	Cerebrum	Cerebellum	Spinal Cord
Average normal conductivity	0.00189	0.00164	0.00180
Average conductivity after insomnia; 96 hours	0.00185	0.00149	0.00138
Average conductivity after insomnia; 96 hours followed by 6 hours rest	0.00188	0.00141	0.00150
Average conductivity after insomnia; 96 hours followed by rest from 7-14 days	0.00203	0.00157	0.00159

To determine this point, in the spring of 1917, a research was initiated in collaboration with G. B. Obear of the Case School of Applied Science. The research was interrupted by the war, but was resumed in the fall of 1918, in collaboration with Miss Helen R. Hosmer and Miss Amy F. Rowland.

In this research, we have measured the conductivity of 4,798 sections of various tissues from 436 rabbits and 137 clinical specimens. The tissues have included the cerebrum, the cerebellum, and the liver of every rabbit studied; and in many of them also the spinal fluid, the blood, the suprarenals, the thyroid, the spleen, the pancreas, the kidneys and the voluntary and involuntary (heart) muscle.

After establishing the apparent range of conductivity of these tissues, especially the brain and the liver, in normal animals, under varying

6. Osterhout, W. J. V.: Science **35**:112-115, 1912; ibid. **34**:187-189, 1911; J. Biol. Chem. **31**:585-589, 1917; J. General Physiol. **1**:515-519, 1919.

7. Galeotti, G.: Ztschr. f. Biol. **45**:65-78, 1904; ibid. **43**:289-340, 1902.

8. Lillie, R. S.: Biol. Bull. **33**:135-186, 1917; ibid. **17**:188-208, 1909; Science **30**:245-249, 1909; Am. J. Physiol. **29**:372-397, 1912; Am. J. Physiol. **41**:126-136, 1916.

9. Loeb, J.: J. Biol. Chem. **27**:363-375, 1916; ibid. **28**:175-184, 1916; The Organism as a Whole, from a Physico-Chemical Viewpoint, New York, G. P. Putnam's Sons, 1917; Loeb, J., and Bentner, R.: Biochem. Ztschr. **41**:1-26, 1912.

conditions—varying lengths of confinement, different seasons, etc.—groups of rabbits were subjected to exhaustion from various causes: prolonged insomnia, extreme fright, physical trauma (surgical shock), infection, hydrochloric acid injection, thyroid feeding, iodoform poisoning, strychnin poisoning, prolonged ether anesthesia, prolonged nitrous oxid anesthesia. We have observed also the effect on the electric conductivity of the brain and the liver of the inceptive stage of surgical shock, of toxic shock, of strychnin and epinephrin shock. We have observed also the effects of sleep and of rest after prolonged insomnia,



Fig. 8.—Changes in the cells of the suprarenals produced by prolonged insomnia: *A*, section of normal suprarenal of rabbit; *B*, section of suprarenal of rabbit after insomnia of one hundred and nine hours' duration. × 1600. The eccentric and irregularly shaped nuclei and the generally disorganized appearance of the cells in *B* may be noted.

and of morphin in the presence of infection. We have measured the conductivity of the brain and of the liver in fetuses, in new-born and in young rabbits.

The pathologic tissues measured have included exophthalmic goiters, adenomas, colloid goiters, malignant thyroids, roentgen-ray burns, uterine fibroids, breast cysts and various types of carcinoma and sarcoma.

Our findings in each of these studies will be reported in the appropriate sections of these "Studies in Exhaustion."

The findings in the studies on insomnia are given in detail in Table 11 and in the charts. The subjoined findings are of especial significance as they parallel the histologic findings:

1. Prolonged insomnia, ninety-six hours, decreased the conductivity of the central nervous system—cerebrum, cerebellum and spinal cord (Fig. 10).

2. When prolonged insomnia, ninety-six hours, was followed by a short period of rest, 6 hours, the conductivity of the cerebrum and of the cerebellum was decreased still more than at the close of the

Fig. 9.—Exhausted Purkinje cells surrounded by phagocytes.

insomnia period. The conductivity of the spinal cord began to return toward the normal (Fig. 11).

3. When prolonged insomnia, ninety-six hours, was followed by a prolonged period of rest, from nine days to two weeks, the conductivity of the cerebrum was increased above the normal, and the conductivity of the cerebellum and of the spinal cord approached the normal (Fig. 11).

D. CLINICAL FINDINGS

In each experiment at the end of the period of insomnia, every gross clinical sign indicated that the animal was in a condition of extreme exhaustion.



Fig. 10.—Comparative changes above and below the normal in the electric conductivity of various tissues, produced by prolonged insomnia.

Temperature.—In twenty-two out of forty-two cases, the temperature rose an average of 1.5 F. (minimum 0.2, maximum 5.3) during the period of insomnia. In fourteen cases it fell an average of 0.9 F. (minimum 0.4, maximum 2.0). In the remaining six cases it neither fell nor rose. In general, therefore, the temperature tended to rise. It may again be emphasized here that none of the rabbits selected for these experiments showed any sign of disease before or during the period of insomnia. Apparently, therefore, the increased temperature was purely a work phenomenon.

Respiration.—In six out of forty-two cases, the respiratory rate showed an average increase of 47 per minute (minimum 12, maximum 102) during the period of insomnia. In thirty-one cases, it showed an average decrease of 46 per minute (minimum 11, maximum 129). In five cases it was unchanged.

Weight.—In twenty-three out of forty-two cases, there was an average gain in weight of 107 gm. (minimum 5, maximum 588) during the period of insomnia. In eighteen cases, there was an average loss of 107 gm. (minimum 2, maximum 432). In one case, the weight was unaltered. The rabbits ate when they wished, having access to food and water all the time, and were weighed at regular intervals. Chance and individual differences were doubtless the chief factors in determining gain or loss in weight.

Urine.—In seventeen cases, the urine was tested for diacetic acid and acetone before and after the insomnia period, but in no case was either found. A few tests for albumin and sugar were negative.

Summary of Experimental Clinical Findings.—(*a*) Prolonged insomnia as evidenced by these experiments tends to produce a rise in temperature.

(*b*) The respiratory rate tends to fall during prolonged insomnia. This observation is significant in view of the fact that the H-ion concentration was not increased by insomnia, since increased acidity invariably causes an increased respiratory rate.

(*c*) No consistent changes in weight were demonstrated by these experiments.

GENERAL SUMMARY

1. Prolonged insomnia produces histologic lesions in the central nervous system, the liver and the suprarenals.

2. Prolonged insomnia produces no appreciable alteration in the H-ion concentration of the blood.

3. Prolonged insomnia decreases the electric conductivity of the central nervous system—cerebrum, cerebellum and spinal cord.

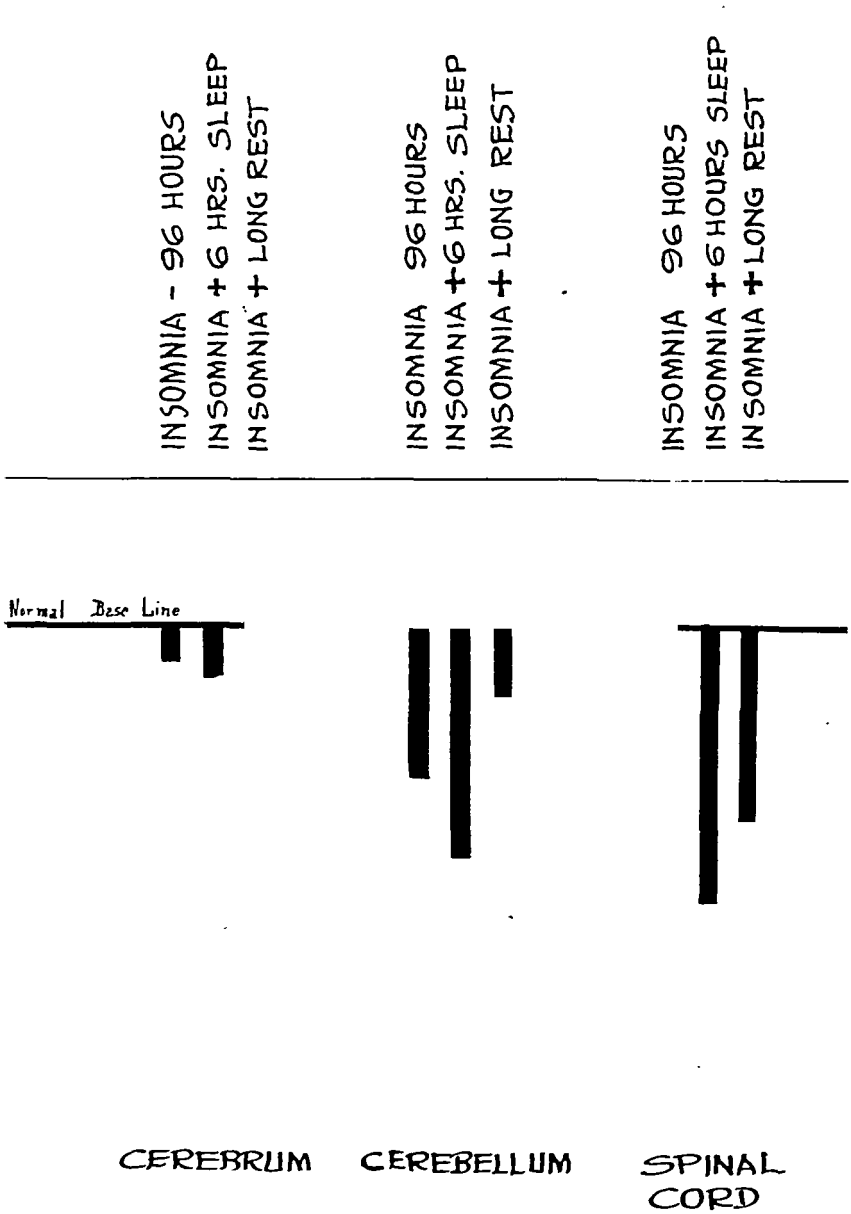

Fig. 11.—Comparison of the variations in electric conductivity of the cerebrum, cerebellum, and the spinal cord produced by insomnia, and by insomnia followed by periods of rest.

4. Sleep repairs the histologic lesions in the central nervous system and in the liver in all cells except those in which the nucleus has become disintegrated.

5. Sleep and rest, if sufficiently prolonged, increase the electric conductivity of the cells of the central nervous system to, or above, the normal.

6. Nitrous oxid-oxygen to some extent appears to be an efficient substitute of sleep in its restorative effect on the brain cells.

1021 Prospect Avenue.

OPERATION FOR EPIPHYSITIS OF THE HEAD OF THE FEMUR (PERTHES' DISEASE)

FINDINGS AND RESULT

D. B. PHEMISTER, M.D.
CHICAGO

The case herewith reported throws some light on the pathology and treatment of a lesion of the epiphysis of the femur in the young, the exact nature and proper therapeutics of which have been the subject of much recent discussion.

REPORT OF CASE

History.—C. P., a boy, aged 10 years, who entered the Presbyterian Hospital, March 1, 1920, complained of limited motion in the right hip; this had begun five months previously with pain in the hip and a slight limp. The pain, which was of a dull, aching character, was worse in the daytime. He was not confined to bed and had no constitutional symptoms. A physician had been called three weeks after the onset of symptoms, whereupon the patient was put to bed for three months, with the leg maintained in extension by weights. The pain disappeared and had not returned in the last six weeks, during which time he had been walking on the leg. The past and family histories were negative. There was no history of tonsillitis.

Physical Examination.—The patient was fairly well nourished. He walked with a moderate limp in the right leg. Examination outside the region complained of was negative, aside from moderate enlargement of the tonsils and slight enlargement of the lymphatic glands of both submaxillary regions. The muscles of the hip and thigh of the right leg were slightly atrophic. The legs were of equal length. Palpation of the right hip revealed no tenderness nor enlargement. Flexion of the hip was almost normal; abduction was markedly limited, and rotation was moderately limited. Pulse, temperature, respiration, blood and urine were normal. Roentgen-ray examination of the right hip (Fig. 1) disclosed flattening of the center of ossification in the epiphysis with a small area of greatly reduced density just mesial to its central portion and a larger ovoid dense area lateral to this. The outline of the shadow cast by the flattened head was slightly uneven, as was also that of the iliac portion of the articular surface of the acetabulum and the margin of the neck bordering on the epiphyseal line. Otherwise there were no changes.

Diagnosis.—The diagnosis of Perthes' or Legg's disease was made, and the patient was discharged without treatment. He returned to the hospital, June 27, 1920, stating that the hip was still painless, but that the limp had slightly increased. Physical examination revealed slight decrease in all the movements of the right hip joint. Otherwise there were no changes in the findings. Roentgen-ray examination of the hip (Fig. 2) disclosed marked progression of the changes in the head of the femur. The mesial part of its center of ossification was little changed, but the lateral portion showed more flattening. The central area of rarefaction was much larger than in the previous

roentgenogram and had completely severed the two bony halves of the epiphysis. Lateral to it, in the flattened portion of the head, were two pea-sized, dense shadows suggesting sequestrums. The epiphysis bulged laterally, overhanging slightly the margin of the neck of the femur.

Treatment.—An operation was decided on in order to determine the nature of the changes in the joint and epiphyseal head and the effect of cleaning out the diseased focus. June 28, 1920, an anterior incision was made along the lateral margin of the sartorius muscle exposing the hip joint. Aspiration yielded 5 c.c. of a slightly turbid straw-colored fluid. The joint was then opened by a crucial incision, when more fluid escaped. There was a mild synovitis with a few small



Fig. 1.—Flattening of head of femur and cavity formation, five months after onset of epiphysitis.

villous tags attached to the synovial lining, one of which was excised for examination. The articular surface of the head was smooth and shining, but the contour was greatly changed, there being a marked flattening of the surface opposing the iliac portion of the acetabulum and slight lateral bulging beyond the upper acetabular margin. A window, about 1 cm. by 1¼ cm., was excised from the anterior surface of the head, extending into the center of ossification and including a small portion of the epiphyseal line. It was then seen that the center of ossification in the epiphysis was almost entirely broken down in its lateral portion, forming a cavity which was filled partly by granulation tissue

and partly by necrotic débris which included several various sized sequestrums, most of which were sandlike but two of which were as large as a small pea and dense in structure. The cavity was thoroughly curetted, after which the joint capsule and skin incisions were closed and a plaster-of-Paris spica applied. Bouillon and blood agar cultures were made of the fluid, of the ground tissues of the villous mass from the synovia and of the scrapings from the broken down area in the epiphysis. No anaerobic cultures were made. There was no growth on any of the media. Guinea-pig inoculations were made with tissues from the epiphysis, which were found later to be negative for tuberculosis.

Histologic Examination.—The synovial tag consisted of hyperplastic connective tissue elements with a few areas of round cell infiltration and a thickened synovial covering rich in nuclei (Fig. 3). The excised window from the head

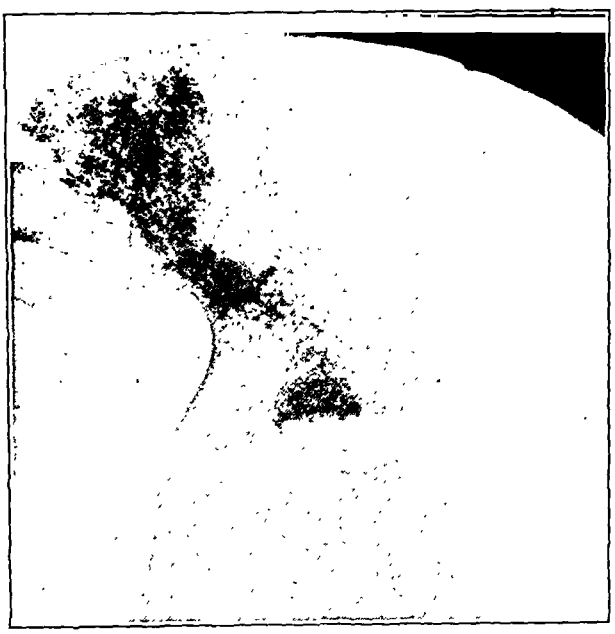

Fig. 2.—Further flattening of head of femur with lateral bulging, and cavity and sequestrum formation, nine months after onset of epiphysitis.

showed a layer of cartilage about 0.5 cm. thick, which was normal except in its inner portion where it formed the wall of the broken down bony center. Nearly all of the adjacent cortical bone had been destroyed and replaced by connective tissue in varying degrees of organization, from mature fibrous tissue to loose granulations (Figs. 4 and 5). Areas of old living bone were present in places, but showed some evidence of caries along the inner surface. There were a few cortical areas of newly formed bone. Small islands of dead bone undergoing lacunar absorption were scattered throughout the fibrous lining. In some areas, cartilage was being absorbed from within outward. An examination of the material curetted from the cavity disclosed a mixture of organizing connective tissue, granulation tissue and necrotic débris, in which were contained small sequestrums undergoing absorption (Fig. 6). About the sequestrums were giant

cell osteoclasts, but this was the only type of giant cell found. The largest sequestrum showed complete necrosis of its soft parts but retention of its interior trabeculae, which accounted for the dense shadow which it cast in the roentgen ray. A section through the small portion of the excised cartilaginous epiphyseal line showed destruction of the bone on the epiphyseal side, but little change in the cartilage. There was some degeneration in the zone of cartilage growth. The marrow of the adjacent cancellous bone of the neck was slightly fibrous (Fig. 7).

Result.—The pathologic picture was that of an old, probably pyogenic infection, which had destroyed most of the bony center in the head of the femur.

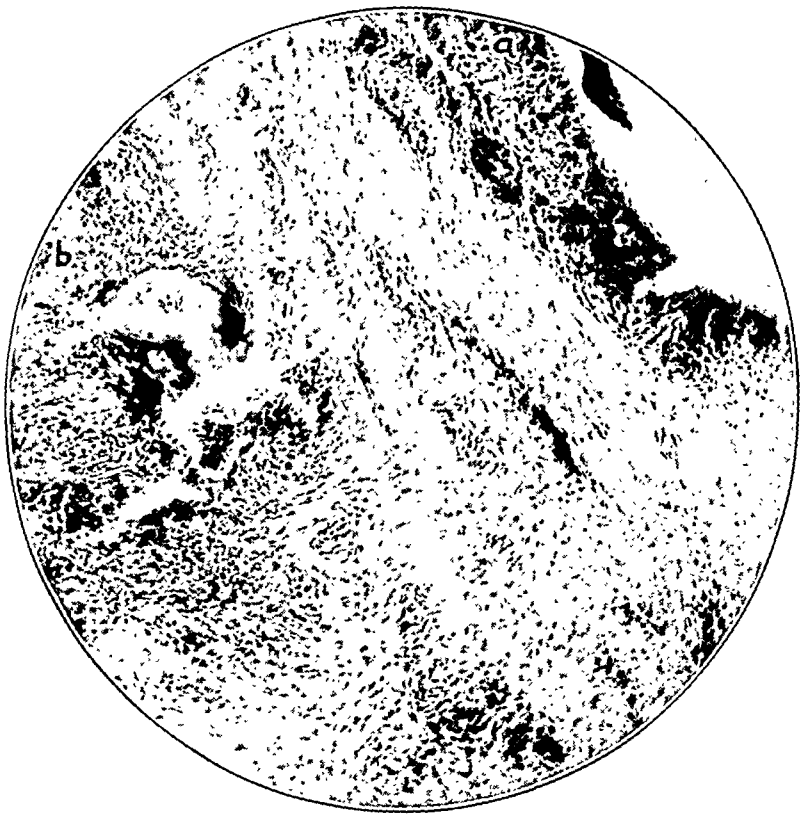

Fig. 3.—Section of synovial villus: *a*, hyperplastic lining; *b*, round cell infiltration.

The hip was immobilized for two months, after which a roentgenogram showed a more even and rounded contour to the bony center and filling in of a considerable portion of the defect with new bone. The patient was then allowed to walk. A second roentgenogram, made five and three-fourths months after operation (Fig. 8), showed the defect entirely filled out with new bone and the size of the bony center slightly increased over that shown by the previous roentgenogram. Motion in the hip joint six months after operation was slightly less than before, but was gradually increasing. The joint felt strong and had been entirely free from pain. Confinement to bed during the period of regeneration, without immobilization, would probably have been a better procedure.

COMMENT

The outstanding feature of this case is the improvement brought about in the center of ossification of the head of the femur by the operation. Instead of further destruction and collapse, as is the usual occurrence, it regained part of its original thickness, the contour of the articular surface became more even and the interior almost completely filled out with new bone. This is so far a better result from the standpoint of preservation of the head of the femur than that

Fig. 4.—Section through junction of cartilage (*a*), the broken down center of ossification with wall of organizing inflammatory tissue (*b*) and the necrotic surface (*c*).

reported in any of the cases treated by nonoperative measures. However, the disease had existed for nine months, during which time extensive destruction had taken place, most of which might have been obviated by an earlier operation. The objection to such a transarticular epiphysotomy, if done early, lies in the danger of setting up infection in the hip joint; but it is possible that if the operation were performed two or three months after the onset, when the symptoms have considerably subsided and the virulence of the infection has been reduced, arthritis would not occur and a cure might be effected without extensive

alterations in the head and neck of the bone and the marked disturbances in function which are the usual consequence. The danger from cleaning out the focus in the head, without opening the joint, by tunneling through the neck from the side at the base of the great trochanter, is that the epiphyseal line between head and neck would be extensively destroyed and longitudinal growth arrested.

The pathologic examination indicates strongly the infectious nature of the disease. The extensive bone destruction, the sequestrum forma-

Fig. 5.—High power magnification of portion of section shown in Figure 4: *a*, cartilage; *b*, fibrous wall; *c*, granulations surrounding necrotic bone (*d*), and *e*, detritus.

tion and the presence of granulations and organizing fibroblasts constitute a picture which is frequently seen in quiescent osteitis of the shaft. Failure to obtain bacterial growth does not rule out infection, as it is a common experience to obtain negative cultures from cases of mild localized osteitis in the metaphysis or shaft of bone that have persisted for several months before operation and taking of cultures.

The restricted nature of the infection can be accounted for by the anatomic arrangements. The center of ossification in the head is

everywhere surrounded by a wall of cartilage, which is not easily penetrated by an inflammatory process. The layer of cartilage between the bony center and joint surface is very thick during the first decade and serves as a barrier against the spread of infection to the joint. After months of confinement, the process may penetrate the epiphyseal line, which is thinner, and produce changes in the adjoining portion of the neck, as has been noted roentgenologically in a number of instances. This cartilaginous enclosure of the affected center also explains the

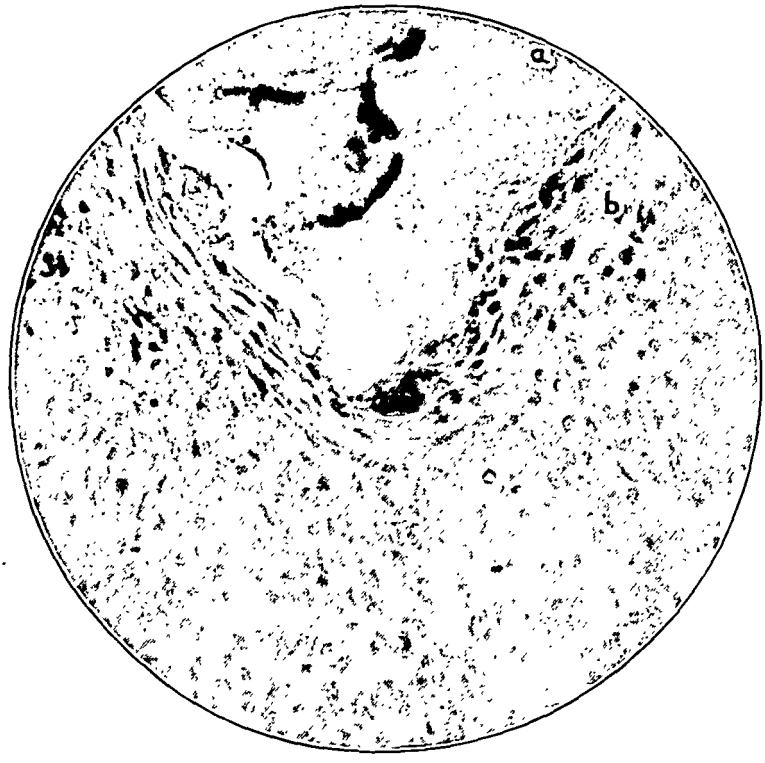

Fig. 6.—Section of scrapings: *a*, small sequestrum being absorbed by granulation tissue (*b*).

mildness of the subjective symptoms. There is no nerve supply to the center of ossification, as cartilage is not penetrated by nerve fibers, consequently the relative insensitiveness of the joint. There is also little absorption of toxins, which accounts for the mildness or absence of constitutional symptoms.

Our previous knowledge of this condition has been derived almost entirely from clinical and roentgenologic studies, which have led to a great deal of speculation as to the etiology and pathologic changes.

Pathologic studies[1] of postmortem and operative specimens, made before Perthes' clinical and roentgenologic observations were published, led to the view that a destructive condition occurred in the center of ossification of the head which was somewhat similar to the subchondral bone destruction in arthritis deformans of adults. Since then the only microscopic pathologic report on the lesion in the head is that by Perthes,[2] in which he examined an excised portion of the lateral projection of the head and the synovial membrane removed at



Fig. 7.—Section through epiphyseal line: *a*, partially necrotic center of ossification in epiphysis; *b*, cartilaginous line little affected; *c*, juxta-epiphyseal trabeculae with small amount of fibrous marrow.

operation. The synovial membrane showed no change. The layer of cortical epiphyseal cartilage was between 3 and 4 mm. in thickness and showed no changes. The underlying bone was partly destroyed and replaced by buds of cartilage which had grown inward from the peripheral cartilaginous covering. Some of the bony areas were extremely

1. Deutsch. Ztschr. f. Chir. **57**:111, 1910.
2. Perthes: Arch. f. klin. Chir. **60**:779, 1913.

porous and the cancellous spaces filled with fatty marrow. There were no signs of active inflammation in the area.

Evidently the excised portion of the head did not include any of the broken down central area, but consisted of the newly formed overhanging ledge at the superior lateral portion of the head. Hence it is not surprising that signs of inflammation were not found.

Fig. 8.—Hip five and three-fourths months after operation. Center of ossification markedly reconstructed, leg externally rotated.

Legg [3] and Kidner [4] each reported a case in which the epiphyseal line was perforated and a broken down focus was curetted from the adjacent neck of the femur, which on culture showed the staphy-

3. Legg, A. T.: An Obscure Affection of the Hip-Joint, Boston M. & S. J. **162**:202, 1910.

4. Kidner, F. C.: Perthes' Disease Am. J. Orthop. Surg. **14**:339 (June) 1916.

lococcus, but no histologic examination is recorded. Legg's reported case, a boy, aged 6 years, was a patient of Goldthwait's who one year previously had suffered a trauma of the hip and was lame for one week. He apparently recovered, but seven months later, following otitis media, developed a limp with indefinite pains in the left groin and restlessness at night. The roentgen ray showed a flattening of the head of the femur and a large circumscribed area of rarefaction in the lateral juxta-epiphyseal portion of the neck. The focus was curetted through a tunnel in the neck from the subtrochanteric region without entering the joint. A culture of the necrotic material showed staphylococci. Kidner reported the case of a boy, 5 years of age, whose symptoms were of two months' standing, although eight months before he had pain in the hip for a week following trauma. There were mild fever and muscle spasm at the time of examination. The roentgen ray disclosed collapse of the head and a sharply demarcated area of rarefaction in the juxta-epiphyseal portion of the neck of the femur. By the tunneling operation, just described, grayish-red débris was curetted from the focus in the neck, cultures of which showed *Staphylococcus pyogenes aureus* of low virulence. The head of the femur was not opened. Kidner believes that the process is primarily a subepiphyseal hematogenous infection of the neck, which interferes with the circulation of the head of the femur and leads to secondary involvement with breaking down of that structure.

Since in this disease there is always evidence of an extensive lesion in the head and rarely a focus of bone destruction of appreciable size in the neck, it is highly probable that the former is the primary lesion and that the latter is the occasional result of subsequent extension of the process through the epiphyseal line. The important rôle of trauma in the localization is definitely established.

SUMMARY

The pathologic picture presented at operation was that of a mild synovitis of the hip joint and an old quiescent epiphysitis of the head of the femur with extensive alterations in shape, resulting from breaking down of its center of ossification. The result of operation with curettage of the broken down focus in the head was the gradual filling out of the diseased area by new bone with the disappearance of the roentgenologic signs of active epiphysitis. This indicates the value of operative treatment of the disease. Or if nonoperative treatment is carried out, there should be no weight bearing for many months, because of the collapse which it produces secondary to the broken down center of ossification in the head.

122 South Michigan Avenue.

THE PROGNOSIS IN PROSTATECTOMY

JOHN B. DEAVER, M.D.
John Rhea Barton Professor of Surgery, University of Pennsylvania School of Medicine; Surgeon-in-Chief to the Lankenau Hospital

AND

LEON HERMAN, M.D.
Urologist to the Methodist Episcopal Hospital; Instructor in Urology, University of Pennsylvania School of Medicine; Assistant Surgeon, Pennsylvania Hospital

PHILADELPHIA

The subject matter of this article, while largely statistical, has proved most instructive to us, and it is presented with the hope that the proverbial dryness of figures will be less arid in this instance, because of their importance. The material is based for the most part on data which we have collected in the preparation of the chapter on prognosis for the second edition of the monograph "Hypertrophy of the Prostate" by the senior author.

In contrasting the chapter on prognosis in the previous edition of the work with the present one, an interval of fifteen years having elapsed, one is immediately impressed with the vagueness, the uncertainty and the misgivings with which prostatectomy was viewed only a comparatively few years ago. Then it was a procedure to be adopted only after palliative treatment had been tried unsuccessfully. It is not necessary to review the developmental steps in our knowledge of the pathologic physiology of the genito-urinary system, and the technical problem involved in prostatectomy, whereby operation has become a far safer procedure than palliation in the form of catheterism. We no longer concern ourselves with proofs for or against operation as contrasted with the nonoperative forms of treatment. Time having solved these problems for us, it remains to determine by statistical and other studies, how best to select cases for operation, and how to standardize the mechanics involved in prostatic surgery in such a way that the primary mortality and the postoperative morbidity will be reduced to the minimum.

With so many forms of operation at our disposal, it becomes our first task in attempting to estimate the prognosis of prostatectomy, to contrast the results obtained with the several operations in vogue.

It is too early perhaps to speak authoritatively of the value of the two-stage operation. That it seems to be a decided step in advance in the treatment of certain cases, no one with experience will question; that

it deserves routine adoption, as some urge, is, we believe, extremely questionable. It is undoubtedly the superior method, from a mechanical point of view, of providing bladder drainage; it is, however, not always necessary, or even desirable, to open the bladder suprapubically in certain cases in which drainage is, nevertheless, indicated.

The indications for the two-stage operation recognized in our work are:

(*a*) In cases of acute retention due to prostatic hypertrophy, uncomplicated by stricture of the urethra, it is indicated. In a very few instances, the indwelling catheter may be used advantageously when the passage of the instrument is accomplished with ease and gives rise to no discomfort. But as a rule, these patients arrive at the hospital with badly traumatized urethras, as the result of long and futile attempts to pass instruments. With this class of patients, we lose no time in providing suprapubic drainage. A de Pezzer catheter may be introduced into the bladder at its summit, under local anesthesia, if the surgeon prefers this to ether or nitrous-oxid and oxygen. The catheter may be introduced through a small incision, so that but little urine is lost, and the bladder is subsequently emptied intermittently.

(*b*) In most cases in which there are great quantities of residual urine it is indicated. In many instances, the operation is preceded by a few days of intermittent catheterization.

(*c*) All patients with badly infected bladders—this includes the majority of cases complicated by calculus—should be treated by the two-stage operation. In the two latter groups of cases, we prefer drainage tubes of large caliber rather than the de Pezzer catheter. Subsequent removal of the prostate is thus simplified.

(*d*) The two-stage operation is especially indicated in that small group of cases in which drainage is necessary, but in which bleeding from the prostate prevents the otherwise indicated indwelling catheter.

The foregoing indications for the two-stage operation are by no means universally recognized; many of the surgeons whom we consulted in the matter, believe that this operation should be used as a routine. Others employ it only when catheterism is impossible. Freyer is most conservative in his recommendations concerning preliminary cystostomy, having employed it only seventy-three times in 1,550 prostatectomies. He does not mention acute retention as an indication, but adds to the reasons which we have mentioned, secondary infection of the kidneys, and urinary fever following the first catheterization.

It is extremely difficult to state precisely what influencce the two-stage operation has had on the general prognosis in prostatic surgery. We believe that it is not only a life-saving measure in that group of cases urgently in need of palliative treatment but in which the catheter

is ill-borne, but also in many cases in which the cathet
with apparent success in the past. Preliminary cystos
doubt, the most efficient means of preventing kidney br
spread of septic infection. It minimizes hemorrhag
enucleation of the prostate and thus promotes rapid co
practice preliminary drainage, however, when prelimi
unnecessary, as is the routine practice of some surgeon
logical.

We have found it impossible to separate the statisti
the many modifications of the suprapubic and infrap
the remarks that follow are based, therefore, on data
modifications.

PRIMARY MORTALITY

It is the consensus among surgeons that the primar
is slightly less following perineal prostatectomy tha
suprapubic operation. In this opinion we concur, not
fact that our series of collected cases fails to confirm th
belief. These statistics were collected from many sour
the results of operators of both great and small experi
edly, the primary mortality rate is as much, or more, d
care with which cases are selected for operation, and o
ness with which preoperative treatment is carried out, a
operation selected, or the skill of the individual who per

Our list includes approximately 2,500 cases, but it
the published statistics of the recognized leaders in
infrapubic prostatectomy. We have purposely omitte
the work of these few men, for the reason that we are
to ascertain the average mortality of the operation as
throughout the country.

There exist only slight differences in the operative n
ing the two types of operation in the hands of the m
men. The suprapubic operation is a much safer pr
occasional operator than is perineal prostatectomy, a
trated by the much higher mortality rate for the 1
reported by surgeons working in smaller communities.

Freyer has recently reported a series of 1,550 prost
a general mortality of 5.33 per cent. The death rate
hundred cases in this series was 10 per cent., while am
cases, it has been only 3 per cent. Young's mortality
perineal operation, is slightly less than 4 per cent. I
collected cases, the death rate following the perineal o
per cent., in contrast to the 6.9 per cent. mortality follo
prostatectomy.

Although fully cognizant of the unreliability of statistics, we are inclined to believe that these figures express, in a general way, the relative dangers of the two operations in the hands of the average surgeon. Statistics collected from other sources would undoubtedly yield different results, but we believe that these figures are approximately correct.

TABLE 1.—MORTALITY IN SUPRAPUBIC PROSTATECTOMY

Operator	No. of Cases	Mortality (Per Cent.)
Gile	24	46
Tenney and Chase	396	9.8
Deaver and Herman (collected series)	1734	6.9
Freyer	1550	5.33
Dillingham	85	2.4
Watson	50	12
Kelley	75	20
Watkin	60	10
Scherck	150	8
Denslow	200	6
Gardner	218	4.1
Walker	112	5

TABLE 2.—MORTALITY IN PERINEAL PROSTATECTOMY

Operator	No. of Cases	Mortality (Per Cent.)
Gile	38	10.5
Deaver and Herman (collected series)	676	10.9
Dillingham	15	6.6
Watson	110	6.3
Kelley	150	10
Watkin	100	3
Scherck	20	20
Gardner	84	19
Young	450	3.77
Legueu (collected series)	1026	8
Tenney and Chase (collected series)	617	7.6

If the patients operated on by the more experienced men among the group, who were good enough to furnish us with data, that is, if all series of 100 or more cases are eliminated from the calculation, the average mortality rate rises to between 20 and 30 per cent. The latter is in keeping with the figures of Page, who reported a mortality rate of 21.5 per cent. for four London hospitals between the years 1906 and 1910. During the same time interval, sixty-nine suprapubic prostatectomies were performed in St. Thomas' hospital, with a mortality rate of 20.3 per cent. Wade gives the astonishing information that the mortality rate in one of the largest hospitals of Scotland for a ten-year period was 35.4 per cent.

A most interesting study of the subject has been made by Whiteside, who, in 1905, read an article before the Section on Genito-Urinary

Diseases of the American Medical Association, in which he stated that the average mortality following prostatectomy was 20 per cent., with only 30 per cent. of cures. In a second article, read ten years later (1915) before the same association, he reviews the work of thirty-four surgeons, giving data from 1,423 cases. In the latter series, about half of the surgeons, contributing more than half (820) of the 1,423 reports of cases, were men experienced in either the suprapubic or perineal operation. The primary mortality rate was less than 3 per cent. in the hands of these men, while in the hands of the inexperienced, it was 26 per cent.

CAUSES OF PRIMARY MORTALITY FOLLOWING PROSTATECTOMY

The chief causes of death immediately following prostatectomy, in the order of frequency in our collected series, are given in Table 3.

TABLE 3.—CAUSES OF PRIMARY MORTALITY FOLLOWING PROSTATECTOMY

Causes of Death	No. of Cases
Uremia	39
Hemorrhage	32
Shock	18
Sepsis	13
Cardiovascular disease	10
Pyelitis and pyonephrosis	8
Asthenia	7
Pulmonary complications	6
Embolus	5
Diabetes	3
Extravasation of urine	2
Acute dilatation of stomach	2
Air embolus	1
Intestinal paresis	1
	147

These figures indicate that 69 per cent. of all deaths following prostatectomy, are due either to uremia, hemorrhage, shock or sepsis. The relative incidence of the causes of death as given in Table 3 is contradicted by some writers whose experience leads them to believe that sepsis is the most frequent cause of death after the suprapubic operation. In almost all of the larger series of collected statistics, whether dealing with the suprapubic or the perineal operation, uremia is placed at the head of the list of lethal factors. The unusually high percentage of occurrence of fatal hemorrhage is difficult to explain except in the cases of imperfect hemostasis; in other words, a fault in technic. Freyer does not mention hemorrhage as a cause of death in any of the fifty-seven fatal cases among a series of 1,036 suprapubic prostatectomies which he reported.[1]

1. Freyer, P. J.: Lancet **1**: 1018-1021 (April 12) 1913.

Table 5 gives in the order of their frequency, the causes of death in a series of thirty-six fatal cases of suprapubic prostatectomy in which operation was in the Lankenau Hospital of Philadelphia.

TABLE 4.—CAUSES OF DEATH FOLLOWING PROSTATECTOMY (FREYER)

Causes of Death	No. of Cases
Uremia	24
Heart Disease	9
Shock	7
Exhaustion	3
Septicemia	3
Mania	2
Malignant disease of liver	2
Bronchitis	2
Pneumonia	1
Heat stroke	1
Pulmonary embolus	1
Cerebral hemorrhage	1
Acute pancreatitis	1
	57

TABLE 5.—CAUSES OF DEATH FOLLOWING PROSTATECTOMY (LANKENAU HOSPITAL OF PHILADELPHIA)

Causes of Death	No. of Cases
Uremia	8*
Pulmonary complications	7
Shock	5
Myocarditis	4
Sepsis	4
Asthenia	3
Peritonitis	3
Meningitis	1
Gastro-enteritis	1
	36

* 22.2 per cent.

Tenney and Chase have given the causes assigned for death in a series of forty-six fatal cases (Table 6).

Pauchet, who strongly advocates the two-stage operation, mentions infection, renal insufficiency, and narcosis as the prominent causes of death. He reports four series of 100 cases, each with this mortality rate: first 100 cases, 10 per cent.; second 100 cases, 8.1 per cent; third 100 cases, 6.5 per cent., and, fourth 100 cases, 4 per cent.

This progressive improvement, Pauchet attributes to an improvement in operative technic and to better preoperative and postoperative care of patients. The two-stage operation finds a strong champion in this writer, who advocates preliminary cystostomy from three weeks to

several months in advance of the prostatectomy, according to the exigencies of the case.

In reviewing any series of fatalities following prostatectomy, it will be noted that there are fatal periods, a fact to which Tenney and Chase have called attention. Their observations concur, for the greater part, with our own. In their series of seventy-three fatal cases, there were twenty-three deaths during the first forty-eight hours after operation; twelve deaths occurred during the seventh, eighth and ninth days after operation, while the third fatal period is the end of the second week, when six deaths occurred. From the twentieth to the twenty-second day inclusive, there were seven deaths. Two-thirds of all deaths occurred during these fatal periods.

TABLE 6.—CAUSES OF DEATH FOLLOWING PROSTATECTOMY (TENNEY AND CHASE)

Causes of Death	No. of Cases			
	Within Forty-Eight Hours		Within Twelve Days	
	Suprapubic	Perineal	Suprapubic	Perineal
Uremia	2	5	9	9
Shock and hemorrhage	4	1	4	2
Pulmonary complications	2	0	5	1
Sepsis	0	2	1	3
Cardiac disease	2	2	2	3
Collapse	0	0	1	2
Anesthesia	1	2	1	2
Unknown	0	0	0	1
	11	12	23	23

Among the most distressing and usually unavoidable accidents after prostatectomy are cerebral embolism and apoplexy. These accidents are fortunately rare. A not inconsiderable number of patients die within the first year after leaving the hospital of causes that are directly or indirectly attributable either to the operation or to the progressive development of complications that existed at the time of operation, and which the latter failed to cure. Thus, we find that 4.2 per cent. of the patients in our collected series, on whom perineal prostatectomy had been performed, died within one year from the time of their discharge from the hospital, while 2.5 per cent. of the patients on whom suprapubic prostatectomy had been performed died during the same time interval. Unfortunately, we have no data regarding the state of the patients' health and comfort during this brief postoperative period.

The late results of prostatectomy are well shown, and we believe with comparative accuracy, in our series. We have obtained the end-results of 372 perineal prostatectomies and of 814 suprapubic prostatectomies. Of these patients 70 and 76 per cent., respectively, are reported as being completely cured. Seventy-eight per cent. of the patients that had undergone perineal prostatectomy and 79.4 per cent. of those that

had undergone suprapubic prostatectomy were alive and free from bladder symptoms, two years after operation. Seventy-two per cent. of the patients operated on in the Lankenau Hospital of Philadelphia are alive and well two or more years after operation, and 8 per cent. are living but are not completely cured.

In a most instructive and valuable article, Judd has given the results of 542 prostatectomies performed in the Mayo Clinic prior to April, 1911. Of these, 461 operations were performed for benign hypertrophy of the prostate, seventy-four for cancer and seven for tuberculosis. The series includes a number of partial prostatectomies and the results obtained are excellent, especially since these operations were performed in what may now be considered the comparatively early days of prostatic surgery. Sixty per cent. of the patients were "living and enjoying reasonably good health" at the time of this report. Fourteen patients of the series returned for the removal of vesical calculi; twenty-nine died of kidney disease before the end of the second postoperative month; eighty-one patients died after leaving the hospital, and of these, thirty had carcinoma and twenty died of intercurrent disease without reference to the urinary system. A most interesting feature of this report is the record of the necropsy findings in the patients that died of renal complications in all of which it was possible to demonstrate acute nephritis superimposed on a chronic disease of the kidneys.

In estimating the prognosis in any given case of prostatic hypertrophy, the physical condition of the patient is of major importance and the average result of operation is of only relative importance. However, if the patient desires statistical information, he can be assured that his chances for recovery from the operation, in company with that of fellow sufferers, are more than 90 per cent. and that the probabilities of continued life and entire comfort are more than 70 per cent. Seventy-two per cent. of our own patients are alive and well at periods ranging from one to twelve years after the operation.

PREDETERMINING FACTORS IN THE MORTALITY RATE OF PROSTATECTOMY

Of the many factors that play an important part in determining the mortality rate of prostatectomy, age per se has relatively little influence. With increasing age, the reserve powers of the vital organs naturally diminish, so that the older the patient, the less likely is he to withstand the shock of operation and the evil effects of confinement to bed. The aged remain, therefore, a poorer operative risk for many reasons, among the most important of which is their greater susceptibility to complications, especially of the pulmonary and cardiorenal types. The

effects of hemorrhage and infection are disastrous to the aged, although operative shock unassociated with hemorrhage is borne with surprising success by very old men. Old age in itself is not a contraindication to operation, and many brilliant successes are obtained with prostatectomy in men between the ages of 75 and 85.

This series (Table 7) would indicate that the death rate steadily increases with advancing years, which is probably the case, although it is not true in our experience, since 37.7 per cent. of our fatalities occur in patients between the ages of 70 and 80, while 39.6 per cent. of all fatalities occur in patients between the ages of 60 and 70 years.

As a general rule, the convalescence of very aged patients after prostatectomy is stormy in comparison to the smoother, uncomplicated recovery of the average younger patient.

TABLE 7.—DECADE MORTALITY FOLLOWING PROSTATECTOMY (COLLECTED SERIES)

No. of Cases	Ages	Mortality (Per Cent.)	Decade Mortality (Per Cent.)
8	39-49	0	
31	50-54	10	5.8
89	55-59	4.5	
201	60-64	7	9.5
221	65-69	11.3	
175	70-74	13	
65	75-79	18.5	15
24	80-84	8	
0	85-89	0	
2	90-94	50	

The duration of the disease is an important prognostic factor, as is the type of preoperative treatment, and the local complications, such as acute urinary retention, from which he has suffered in the past.

These factors, however, together with more remote influences, including personal habits, occupation, previous diseases, and the like, are of prognostic significance so far as they influence the organs and tissues on which the recuperative powers of the patient depend. The postoperative complications leading to fatalities in prostatectomy are usually exaggerations of preexistent diseases, usually of the kidneys; less often they are dependent on technical errors in the operative treatment. These complications we shall discuss, attempting in each instance to establish their prognostic significance.

COMPLICATIONS OF PROSTATECTOMY

In considering the complications which lead directly to a fatal result following prostatectomy, we shall pay special attention to the more common types, and to those which are more or less peculiar to this condition.

Pulmonary complications, which stand eighth in our list of lethal factors, might at first be looked on as more common in aged patients. Undoubtedly, lung complications after prostatectomy are more common than these figures indicate, but they are, for the most part, congestive in type and are quickly recovered from with proper treatment. Pulmonary embolism is a rare cause of postoperative death.

Diabetes, which is given as the cause in three fatalities, is a positive contraindication to operation unless the disease improves markedly under medical treatment. Diabetes must be so relieved that wound healing can be anticipated with reasonable assurance, and that there is only a remote danger of fatal acidosis supervening on operation.

Cerebral hemorrhage cannot always be prevented, but an unusually high blood pressure and very marked arteriosclerosis are danger signals that must be heeded. Acute dilatation of the stomach and intestinal paresis result from toxemia. They are rare, although usually fatal, complications of prostatectomy. In our series of collected cases, renal failure and hemorrhage are by far the most prominent fatal complications of the operation, while in our personal experience, fatal bleeding has been exceedingly rare.

Fatal pelvic cellulitis and wound infection are likewise rare fatal factors in our prostatic work. Uremia, pulmonary complications and shock are the common postoperative complications which present themselves to us. Wade, on the contrary, quoting the figures of Page, speaks of these as coinciding with his own and states that by far the most common cause of death is septic absorption arising from wound infection, and that renal diseases occupy second place among the lethal factors. The prognosis is undoubtedly influenced by the presence of a foul cystitis, not only as regards the primary mortality rate, which is much higher in this class of cases than in mildly infected ones, but also in respect to the likelihood of postoperative complications such as pyelonephritis, epididymitis, pelvic cellulitis, wound infection and embolic or thrombotic involvement of the veins and lungs. Vesical calculi are frequently found in association with the infected cases, and this combination has long been supposed to exert a favorable influence on the prognosis. This erroneous belief had been handed down from writer to writer until, with the collection of large numbers of statistics, its fallacy became apparent. In 1913, Freyer reported 190 cases of enlarged prostate complicated by calculus, with a mortality rate of 8.42 per cent., as contrasted with a mortality rate of 4.84 per cent. among 846 cases unassociated with vesical calculi. In a more recent contribution, the same author reports 274 cases of enlarged prostate associated with stone, with a mortality rate of 7.25 per cent.; the general mortality rate in 1,550 cases is 5.33

per cent. According to our figures, stone is found in 9.8 per cent. of patients with enlarged prostates. In the belief of twenty-four of the thirty-four surgeons whom we consulted in the matter, the presence of stone has no influence whatsoever in prognosis. According to Tenney and Chase, who report 107 cases of prostatic hypertrophy complicated by stone in the bladder, the relative mortality of those with and without stone is 12 to 8.6. These figures indicate the more hazardous nature of prostatectomy when calculi complicate the enlargement of the prostate. Especially when the prostate and stone are removed through the perineum is the operative mortality greater.

The least of the infectious complications, such as epididymitis, may be the deciding factor in causing the death of a debilitated patient. Every effort should be made, therefore, before, during and after the operation, to minimize the chances of bacterial growth and dissemination. Epididymitis may occur before operation and especially after instrumentation, but more commonly succeeds it. McDonald has reported forty-five cases of epididymitis among 118 patients (27.5 per cent.), fourteen of whom developed the complication before operation, twenty-seven while the patient was convalescing in the hospital and four after the patients had been dismissed from the hospital.

It is, indeed, a distressing experience to have a patient develop suppurative epididymo-orchitis necessitating orchidectomy. Especially is this true when it occurs prior to prostatectomy, for which he entered the hospital. The condition is usually unilateral, although infection of the opposite side may follow at varying intervals of time. It is advisable in the case of patients whose bladders are badly infected, or in whom there is the history of recurrent epididymitis, to expose the vasa at the base of the scrotum, remove a small segment from each one and ligate them before proceeding with the removal of the prostate.

Phlebitis is a rare sequel of the operation, and is usually not serious in itself, although it may necessitate longer confinement of the patient to bed than would otherwise be necessary.

Surface wound infection is commonly encountered, but it is of little clinical significance in comparison to infection of the deep wound of the prostatic bed. Serious infection is more likely to occur here than in the space of Retzius. We are inclined to believe that many of the fatal cases of pericystic infection take origin here, rather than in the prevesical space. Peritonitis sometimes follows infection that has gained entrance through an accidental wound of the peritoneum.

Cystitis is not in itself an important complication of the operation, but it is a fruitful source of bacteria which give rise to much concern when they become transplanted to other and more fertile fields. Among the most important of the infectious complications is pyelonephritis.

Pyonephrosis, when present, has almost invariably existed prior to operation. These two infectious processes stand sixth in the list of fatal factors after prostatectomy. Chronic pyelonephritis is a common preoperative complication of prostatic hypertrophy and is a prominent cause of kidney destruction that so often results after operation in fatal uremia. This, as well as pyonephrosis with total unilateral kidney destruction, may be easily overlooked before operation, especially in cases in which ureteral catheterization is impossible. However, with the aid of the various kidney functional tests, chromo-ureteroscopy and cysto-ureteropyelography, these mistakes are rarely made in well organized clinics.

Acute postoperative pyelonephritis is rarely fatal if uncomplicated by preexistent renal disease.

Hemorrhage, either immediate or delayed, is a rare cause of death following prostatectomy in our experience, although the majority of cases of fatal shock are due, in part at least, to loss of blood.

A safe rule of practice is to be sure that all gross bleeding is arrested before the patient is sent from the operating table. In all doubtful cases, in which bleeding continues despite the usual efforts to stop it, it is the practice of the senior author to pack the prostatic bed with gauze, which is held in place by means of a purse string suture placed around the margins of the prostatic bed.

Hemorrhage may occur later in the course of an otherwise normal convalescence, and is either a true secondary bleeding which has resulted from sloughing of the prostatic bed, or is the result of trauma incident to the removal of the packing. Whiteside reports two cases of fatal bleeding due to the passage of the rectal tube several days after prostatectomy; the Murphy drip is, therefore, he thinks, not entirely without danger. Certainly the tube should be introduced with great care and gentleness. Secondary bleeding occurs as a rule during the latter part of the first week of convalescence; it is rarely alarming. The blood is discharged both by way of the suprapubic wound and the urethra. Only in the rarest instances is it necessary or advisable to reopen the bladder to stop late secondary hemorrhage. Rather profuse bleeding follows instrumentation, in some instances as late as the fourth week after operation. It is rarely alarming in amount.

Uremia usually comes as the result of the added strain incident to anesthesia and operation on kidneys already injured. This is the commonest cause of death after prostatectomy (26.5 per cent.). In some instances, the preoperative studies have shown good functional reserve power of the kidneys, notwithstanding which the patient dies with uremic symptoms following acute suppression of urine. For these cases, which are fortunately rare, there is little hope of predetermining

the condition or of restoring kidney function once it has completely failed. The condition is due, in all probability, to acute congestion of the renal parenchyma with total inhibition of function. By far the greatest proportion of postoperative uremias are dependent on antecedent nephritis of the chronic interstitial type, or chronic infection of the kidneys, both of which can be demonstrated to exist before operation. It is in these two classes of cases, and especially in those due to infectious causes that careful, and often prolonged treatment is necessary before operation can be undertaken with safety. Indeed, no patient with prostatic hypertrophy should be operated on until the maximum reserve functional power of the kidneys is established; this can only be accomplished through decompression of the kidneys either through palliative measures or by cystostomy.

The cardiovascular complications stand fifth in the order of frequency among the causes assigned for death in our collected series. Many of these patients would have been saved, in all probability, had they received appropriate preoperative treatment. Chronic lesions of the heart, if compensated, need cause little or no concern, although it is not always possible to detect the degree of myocardial degeneration. Acute dilatation of the heart will follow operation in a small percentage of cases despite the greatest preoperative care.

In asthenic cases with poor circulatory activity, much may be accomplished before operation by rest and the use of heart tonics. Excessively high blood pressure is a contraindication to operation, unless it is clearly a compensatory measure. Under all circumstances, it must be taken into account in the selection of the anesthetic, the choice of operation and especially in the preoperative treatment of the patient.

The question of malignancy does not play a part directly in the primary mortality rate, for the reason that early cases of cancer of the prostate recover from operation quite as well as the benign cases. This group comprises 7.42 per cent. of the total, so that this factor has some prognostic significance.

MORBIDITY FOLLOWING PROSTATECTOMY

It is extremely difficult to ascertain the average of complete cures attained by prostatectomy, but we believe a conservative estimate would fix the number of patients who are not completely cured by operation, between 20 and 30 per cent. The great majority of these patients are improved, however; rarely is a patient's condition made worse by operation. Much has been written about postoperative urinary fistula; and while it is doubtless rare, it is not an unlikely complication of perineal prostatectomy. Wade has collected 1,423 cases of prostatic enlargement, among which there were fourteen instances of fistula (urethro-

rectal) and twenty-four instances of complete incontinence, all of which followed the perineal operation. Young reports only two instances of urethrorectal fistulas in a series of 482 prostatectomies. Practically all other writers agree, however, that there is considerable danger of fistula following the perineal operation. Judd has noted but few fistulas in his work.

In our series of collected cases, fifty cases (2.9 per cent.) of fistula are reported as following the suprapubic operation, but ten of these are reported by one man who states that they all occurred before the high incision in the bladder wall was adopted. In thirty-five (5.3 per cent.) of 656 cases, fistulas followed the perineal operation. Judd states that only six fistulas occurred after 373 perineal prostatectomies, 50 per cent. of which were performed for carcinoma, and that in four instances, the perineal wound had completely closed and then reopened.

In the hands of the expert prostatectomist, permanent fistula is a rare complication of either the suprapubic or the perineal operation; but even in the hands of the most expert, it has a greater incidence following perineal prostatectomy.

In our series, ten vesicorectal fistulas are reported as having followed the perineal operation. Incontinence of urine in the absence of fistula may follow both the suprapubic and perineal operations, but is far commoner after perineal prostatectomy. True incontinence may exist prior to operation, although the dribbling of prostatics is commonly an overflow of retention. True incontinence may be improved by operation, but it is usually made worse, and prostatectomy should never be undertaken in this class of patients until the possibility of tabes is ruled out by a complete neurologic examination, including spinal fluid studies. Cystoscopic examination is especially indicated in this group of cases.

Not one case of complete incontinence is said by Young to have occurred in a series of 331 perineal prostatectomies; and only three patients had partial incontinence. In our series of suprapubic cases, this complication is mentioned forty-six times (2.6 per cent.), but of these forty-six patients, forty are said by one correspondent to have occurred among seventy-five cases. We have not had the opportunity of verifying these extraordinary figures. In thirty-six instances (5 per cent.), incontinence followed the perineal operation.

The figures of Whiteside, who reports twenty-four cases of urinary incontinence, all of which followed perineal prostatectomy, are given elsewhere.

Complete retention of urine occurred five times more frequently after the suprapubic than after the perineal operation in our series, of which latter, only two were followed by complete inability to void.

Four instances of complete retention followed 482 perineal prostatectomies reported by Young.

About 8 per cent. of all patients continue to have considerable amounts of residual urine after operation. Frequency of urination is commonly experienced after operation, but this improves steadily and with the complete healing of the prostatic bed disappears, often entirely. The presence of small amounts of residual urine, a mild cystitis or interstitial nephritis, are the common causes of the nocturia with which many patients are troubled after operation.

Prostatism, with or without complete retention, following suprapubic prostatectomy, is due usually to the presence of tabs of mucosa so situated as to obstruct in part, or completely, the vesical outlet. In perineal cases, contracture of the vesical neck commonly explains urinary retention succeeding operation.

The question of sterility following prostatectomy is not an important one, but the surgeon is frequently asked by the patient the probable effect of the operation on his sexual powers. If loss or gradual failure of the latter has occurred, the operation will, in all likelihood, have no effect in restoring the function, although potency has been restored in certain rare instances after the suprapubic operation. This is difficult to explain except on the grounds that the relief of pressure on the displaced ejaculatory ducts permits the reestablishment of the normal reflex.

The sexual powers are rarely destroyed by suprapubic prostatectomy if the patient is normal prior to operation. Young has given in detail, the effects of perineal prostatectomy on the sexual powers. Among 133 patients whose sexual powers were about normal before operation, seventy-eight (59 per cent.) stated that there was a complete return of sexual power, while 100 (75 per cent.) stated that erections returned after operation. In twenty-four cases (18 per cent.) there was complete and permanent loss of sexual power. An analysis of these twenty-four cases shows that thirteen patients are now more than 70 years of age; two have tabes dorsalis, and in five the ejaculatory ducts were unintentionally injured during operation. This is a somewhat greater proportion than follows the suprapubic operation.

One of the rarer of the late complications of prostatectomy is the occurrence, or recurrence of calculi situated either in the bladder or in the prostatic pouch, or, rarely, in both positions. This, in our experience, occurs in less than 1 per cent. of cases, although Judd reports fourteen instances among 542 cases.

PELVIC ABSCESS

A STUDY BASED ON A SERIES OF SEVEN HUNDRED AND SIXTEEN CASES *

LAWRENCE R. WHARTON, M.D.
Resident Gynecologist, the Johns Hopkins Hospital
BALTIMORE

I. The history of the treatment of pelvic abscess.
II. Vaginal incision and drainage: a description of the operation and the immediate postoperative care.
III. The clinical aspects of pelvic abscess.
IV. Deaths in cases of pelvic abscess following vaginal incision and age, and the pathology of the disease.
V. General summary and conclusions.

I. THE HISTORY OF THE TREATMENT OF PELVIC ABSCESS

The history of the treatment of pelvic abscess carries the student back to the very beginnings of gynecology and surgery. It tells the story of painful surgical operations which were hesitatingly performed at extreme hazard, decades before Morton [1] introduced general anesthetics or Lister [2] applied the principles of Pasteur. It takes one back to an age when there were no surgical specialties. Overcoming national prejudice, it links into a common chain the names of men who, during the past century, have laid the foundations of operative gynecology and pathology.

Howard A. Kelly [3] has said, "The history of the treatment of pelvic abscess is fraught with the deepest interest, for it exhibits in miniature all the phases of the growth of gynecology at large." The earliest efforts in treatment were marked by the extreme conservatism which always accompanies unfamiliarity with the pathologic lesions present. Misconceptions as to the nature of the unknown disease formed the basis for interminable discussions in the literature and misguided the treatment until nearly 1880. With the "vulgarization" of abdominal operations by Lawson Tait, there was born an era of

---

* From the Department of Gynecology, the Johns Hopkins Hospital and University.

1. Morton, W. T. G., quoted by Bigelow, H. J.: Boston M. & S. J. **35**:309, 379, 1846-1847.

2. Lister, Joseph: On the Antiseptic Principle in the Practice of Surgery, Lancet **2**:95, 353, 668, 1862.

3. Kelly, H. A., and Noble: Gynecology and Abdominal Surgery, Philadelphia, W. B. Saunders Company, 1910 **1**:651 et seq.

radicalism which, although shocking to those who had practiced conservatism, was destined to be followed by a period of ultraradicalism characterized by ideas and practices as unscientific and extreme as they were ruthlessly mutilating and repulsive. Fortunately, these extreme practices neither became widely popular nor did they have long life. Two contributions of definite worth, however, were made by this school of radicalism: in the treatment of pelvic inflammatory disease a new method of approach was instituted, and as a result, for the first time men had the opportunity to see with the naked eye the real lesions of a disease, the pathology of which had heretofore been shrouded in misconceptions.

With the development of pathology, surgical practices which were the relics of previous epochs or were based on theory began to give way to procedures which had true scientific foundation and reasonable clinical indication. Thus began to be developed the modern attitude of conservatism with indicated radicalism, which, although still far from perfect in either theory or practice, has nevertheless been purged to a certain extent of the misconceptions and mistakes of a turbulent past.

In attempting to outline the history of the treatment of pelvic abscess, we find that it might be divided somewhat roughly into five phases, each reflecting the current opinion of a group of men whose influence was temporarily more or less predominant. In brief, these periods might be represented in the following manner:

A. 1820-1870.—Period of timidity and innovation. The introduction of the vaginal speculum and the bimanual method of pelvic examination
(Récamier, Bourdon, Lisfranc, Chassaignac, Marion Sims, etc.)

B. 1870-1890.—Period of early conservatism. Vaginal drainage
(Emmett, Laroyenne, Goullioud, etc.)

C. 1880-1890.—Period of early radical treatment. Laparotomy
(Lawson Tait)

D. 1890-1891.—Period of ultraradicalism. Vaginal panhysterectomy
(Péan, Segond)

E. Modern Period.—Conservatism with indicated radicalism

Although discussions of the inflammatory diseases of the female pelvic organs are found in the clinical dissertations of ancient times, it was not until the early part of the nineteenth century that their treatment began to be seriously attempted. By this time, it was generally recognized that the presence of pus was usually an indication for its evacuation; nevertheless, physicians were not as ready to apply this principle to intra-abdominal conditions as they were to those which were superficially located and hence more readily accessible. One is not surprised, therefore, to see that the earliest surgical procedures

which were instituted in the treatment of pelvic abscess were proposed with fear and carried out with trembling.

It is to France that we turn for our earliest clear records on this subject. Historians generally accord to Récamier [4] the distinction of being the first to make a systematic effort to treat pelvic abscess. Between 1830 and 1840, he practiced the vaginal incision and drainage of such collections of pus as could be reached by this route. This was before the days of anesthesia, a decade before Marion Sims [5] popularized his speculum and thirty years before Lister [2] applied to surgery the principles enunciated by Pasteur. Although Récamier himself seems to have left very few written records, he inspired his pupil Bourdon to carry out his work with the result that in 1841 Bourdon [6] collected and published it, giving the histories of a few patients on whom they had operated and the results they had achieved. Thus the most simple and perhaps most ancient of the operations for the treatment of pelvic abscess had its beginning.

During the thirty or forty years which followed the publications of Récamier and Bourdon, this operation gradually became known. Because of bitter experience with all surgical procedures and a natural dread of the pain and danger which had attended their performances in the past, the clinicians of 1850 to 1870 were very loath to adopt the new operation. The utter lack of any knowledge of, and the prevalence of gross misconceptions concerning, the pathology of the disease proved the greatest stumbling blocks to any progress during this period, and it was not until the days of Lawson Tait that these difficulties began to be overcome. The other hindrances were mechanical—the lack of proper diagnostic methods, the inability to control hemorrhage, the absence of anesthesia, and the dangers of infection. During this early period, these problems gradually began to be solved. Morton [1] introduced general anesthetics in 1846, and Lister opened the antiseptic era in 1867, while surgeons were inventing hemostats and retractors, ligatures and trocars. Applied directly to the development of the treatment of pelvic abscess, the two most noteworthy mechanical contributions were the development of the method of bimanual examination of the pelvic organs and the use of the vaginal speculum. Both of these mechanical procedures far antedated this era, but both had been neglected. Pozzi [7] states that Puzos introduced bimanual palpation into France in 1753, and that the vaginal speculum was known to the surgeons of antiquity, being illustrated in the works

4. Récamier: Gaz. d. hôp., 1831, p. 93.

5. Sims, J. M.: Am. J. Med. Sc., January, 1852.

6. Bourdon: Tumeurs fluctuantes du petit bassin, Rev. méd. 3:5, 161, 321, 1841.

7. Pozzi, S.: Traité de gynécologie, clinique et opératoire, Ed. 3, Paris, Masson et Cie, 1897.

of Ambrose Paré. However that may be, it is certain that the value of bimanual examination of the pelvis as a diagnostic adjunct was not appreciated until the first half of the nineteenth century and that theretofore pelvic examination had been in reality limited to a superficial palpation of the vaginal walls by the use of the finger of one hand. Furthermore, it remained for Marion Sims [5] to apply the principle of the vaginal speculum in devising and popularizing an instrument which still finds daily use and bears his name.

In France, in 1843, Lisfranc [8] mentioned "suppurations in the pelvis," which he ascribed to the ovary, noted that they ruptured spontaneously in some instances, and recommended that they should be punctured by means of a bistoury. Chassaignac, Dumarquay [9] and Nonat [10] soon afterward published similar observations. Each of these men also described a special instrument similar to a trocar, which he used in performing the operation. Chassaignac also advised that drainage should be employed to keep the vaginal puncture tract open. The example of these men, however, was not convincing, for at that time there were not many in France who believed that pelvic abscesses should be opened.

In Germany, Schroeder was at first opposed to all intervention, and Hegar declared that he would operate only when forced by grave complications. In England, Spencer Wells and Savage were the pioneers of this early period, both treating pelvic abscesses by vaginal drainage. In America, Marion Sims and his pupil, Thomas Emmett,[11] together with Gaillard Thomas [12] and D. Warren Brickell,[13] led the way. The work of these four men, at first hesitating, soon became clear cut and decisive. As a result, it attracted attention throughout the medical centers of Europe, for in the gynecologic literature of this period there are no clearer or more definite clinical writings on pelvic abscess than came from these men. In 1852, by introducing and popularizing the vaginal speculum as a means of obtaining exposure, Marion Sims,[5] of New York, undoubtedly made one of the most noteworthy contributions to the mechanics of pelvic surgery. Although Marion Sims was not so decisive in advocating the use of operative procedures in the treatment of pelvic abscess as were his younger contemporaries and pupils, Emmett, Thomas and Brickell, his

8. Lisfranc, quoted in Congrès périod. internat. de gynéc. et d'obst., Brussels, 1892, p. 166.

9. Dumarquay: Gaz. d. hôp., 1857.

10. Nonat: Traité pratique des maladies de l'utérus, 1860.

11. Emmett, T. A.: Principles and Practice of Gynecology, Philadelphia, 1879.

12. Thomas, T. G.: Diseases of Women, Ed. 5, Philadelphia, 1880, p. 505.

13. Brickell, D. W.: Am. J. Med. Sc., April, 1877; also quoted by Thomas, T. G., Footnote 12.

experience and genius served as the foundation on which they built. In 1877, Brickell[13] stated that collections of pus and serum which resulted from pelvic suppuration should be evacuated per vaginam and contended that local applications were futile. Two years later Emmett[11] said that "the rule is as applicable here as in general surgery, to open freely a collection of pus as soon as it can be detected. I do not regard it as sound practice to wait until the pus finds an outlet for itself." He also recommended the irrigation of the cavity of the abscess with mild antiseptics, giving warning at the same time of the danger which attended this procedure and citing two cases of general peritonitis and death which had resulted from its unwise application. T. Gaillard Thomas[12] stated in 1880, "It is to surgery that we must look confidently for aid. . . . If the pus can be certainly reached, it should be evacuated." By 1880, vaginal drainage had become definitely established in many clinics as the indicated treatment of "pelvic suppuration," as it was called, and had already been practiced to a considerable degree by many of the leading clinicians in both Europe and America.

Thus, through half a century of trepidation, we have traced the slow evolution of a simple surgical procedure. Although it was probably not in general use in 1870, it had been recognized and adopted by the vanguard of gynecologists, especially in France and America. Throughout this entire period, however, therapeutic efforts had been misguided by gross misconceptions in pathology. These continued to persist throughout the next ten years. It was not until 1885 or 1890 that the nature of salpingitis and its relation to pelvic abscess began to be appreciated. This ignorance of the pathology of the disease not only retarded the development of operative gynecology during this early period, but even after the introduction of laparotomy, it was largely responsible for the wild excesses which stigmatize the gynecologic surgery of 1880-1892 and which may at times be seen even today.

B. Period of Early Conservatism, 1870-1890.—The early conservatists held the field in France from 1880 until 1890, and made one of the first and greatest of all the contributions to the development of the proper treatment of pelvic abscess—the necessity of prolonged drainage after the evacuation of the pus cavity. In 1886, Laroyenne[14] described his operation, which consisted of the vaginal puncture of the abscess by a spear pointed trocar, the dilation of the drainage tract so as to admit one or two fingers, the insertion of a two-way rubber tube for drainage and daily irrigation of the abscess cavity. During the next five years, several articles appeared in the French literature from

14. Laroyenne: De la péritonite chronique compliquée d'un epanchement latent de nature purulente, séreuse ou hématique, Lyons méd., Feb. 21, 1886.

the clinic of Laroyenne, written by his pupils Blanc,[15] Vallas and Goullioud.[16] The most comprehensive of these was by Goullioud,[16] consisting of a series of communications which ran from August until November, 1891, in which he presented in great detail the work which had been conducted under the direction of his master. As a consequence, the operation of Laroyenne was tried in several of the other French clinics, with varying success, however; the consensus being that although in the hands of its originator it had been successful, in the hands of those not so adept, its use was so fraught with the possibility of dangerous accidents that it should be abandoned. And although Laroyenne's particular procedure was thus rejected, the contribution of worth which he made was accepted—the necessity of long continued drainage. Moreover, among the gynecologists of the decade from 1885 until 1895, Laroyenne and his pupils stood out clearly as exponents of conservatism in a time when radicalism was in the height of its popularity.

C. Period of Early Radicalism, 1880-1890.—Although these dates are chosen more or less arbitrarily, it was during this decade that the operative methods with which these paragraphs deal came into more or less general use.

While the various methods of vaginal drainage of pelvic abscesses were consuming gynecologic attention in France, a wholly new and different factor was being introduced, due to an influence indeed distant. From "one of the outposts of civilization," as Kelly [3] puts it, came the record of Ephraim McDowell,[17] a country practitioner of Danville, Kentucky. In 1809, he had operated on a patient for an ovarian cyst. This first attempt was attended by complete success. He later performed abdominal section thirteen times, with eight recoveries, and left permanent record of his work in a manuscript which he sent to his preceptor, John Bell of Edinburgh. This introduced to Europe the new method of approach in the treatment of pelvic infections. The operation of McDowell, ovariotomy, was introduced into English surgery by Charles Clay (1801-1893) and Sir Spencer Wells [18] (1818-1897); into France and the European continent by Auguste Nélaton [19] and Eugène Koeberlé.[20] If these men

15. Blanc, E.: Thèse de Lyon, 1887.

16. Goullioud, P.: Débridement vaginale des collections pelviennes, Arch. de tocol. et de gynéc. **18**:561-576, 1891.

17. McDowell, Ephraim: Eclect. Repert. Philadelphia **8**:242, 1817. Garrison: History of Medicine. Thompson, W. N.: The Grave of Jane Crawford, the First Subject of Ovariotomy, J. A. M. A. **60**:67 (Jan. 4) 1913.

18. Wells, Spencer: Diseases of the Ovaries, 1865.

19. Nélaton, Auguste: Pelvic Hematocele, Gaz. d. hôp. **3**:573, 1851.

20. Koeberlé, Eugène: Mém. Acad. de méd. Paris **25**:371-472, 1862-1863.

blazed the trail for the new path, it was Lawson Tait[21] who transformed it into a beaten highway. "He performed his first ovariotomy, July 29, 1869; removed an ovary for an abscess, Feb. 2, 1872. These operations," to quote Howard A. Kelly,[3] "opened the whole field of pelvic operations for diseases of the organs other than gross ovarian and fibroid tumors." For the first time exposed to direct vision, "the peri-uterine phlegmons of Emmett and Thomas became recognized as tubal inflammations and abscesses." Lawson Tait counted his operations by the thousand, and his name was prominent in all gynecologic and surgical societies of his day. He was probably the first to emphasize the point that patients with chronic salpingitis could be cured only by salpingectomy,[22] he probably overemphasized it. Moreover, he performed bilateral salpingectomy and oophorectomy in these cases, even though the lesions might seem to be unilateral. When the pyosalpinx or the abscess sac was so adherent that it could not be removed, he recommended that it should be sutured to the anterior abdominal wall and thus drained—marsupialization.

This was, indeed, a new departure in the treatment of pelvic abscess. Radical in the extreme as compared with all previous methods, it was not long before his contemporaries attempted to put his ideas into practice. In Germany, Hegar attempted his first ovariotomy in 1872, and the patient died. So chagrined was he that he did not make his second trial until 1876. By the year 1890, the abdominal route had been adopted in many clinics as the best method of approach in the treatment of most suppurative diseases of the pelvic organs, even though a relatively high mortality attended these efforts.

D. Period of Ultraradicalism, 1890-1891.—Although the methods of Lawson Tait seemed extremely radical to many of his contemporaries, they were to witness the introduction of a form of treatment of pelvic abscess and pelvic inflammatory disease which was even more radical—the Péan-Segond vaginal panhysterectomy. Péan[23] first described his operation in 1890. In a very illuminating article, he depicted the clinical characteristics of large pelvic abscesses which might be mistaken for malignant tumors, being hard, nodular and adherent. In these cases, Péan performed his vaginal panhysterectomy with removal of all the pelvic organs. When he could not remove the uterus in toto, he dug it out piecemeal, morcellement. Hemostasis he obtained by clamps, which he left in place for forty-eight hours. Irrigation of the pelvic cavity was started as soon as the clamps were removed. Péan reported fifty cases in 1890, without a death.

---

21. Tait, Lawson: New York M. J. Oct. 18, 1884, p. 421.

22. Tait, Lawson: On the Results of Unilateral Removal of the Uterine Appendages, Am. J. Obst., 1887, p. 478.

23. Péan: Bull. de l'Acad. de méd. de Paris, July 8, 1890.

Very little favor greeted this new procedure of Péan. His contemporaries called it "a disgrace to France" and "a lapse into barbarism." Even Segond,[24] who later became his most enthusiastic admirer, could not view the new operation with approval. After the first repulsion had worked away, however, the procedure gradually came into limited use, but it was never widely accepted.

E. The Modern Period.—As a result of these innovations in the treatment of pelvic abscess and chronic pelvic inflammatory disease, there were three distinct major schools of gynecologic practice by the year 1890, each advocating its own methods of procedure. There were: (1) the advocates of conservative vaginal incision and drainage; (2) the advocates of laparotomy, with radical extirpation of the adnexa, and (3) the advocates of vaginal panhysterectomy with removal of the lateral organs.

In addition to these methods, others of less note were also advanced, such as drainage of the abscess per rectum, vaginal drainage by the two-stage operation of Wiedow,[25] and drainage by the sacrococcygeal route.

The first International Congress of Gynecologists and Obstetricians convened in Brussels in September, 1892.[26] Delegates from practically all the gynecologic and obstetric societies of Europe and America were present. The three chief topics for discussion were: pelvic suppuration; extra-uterine pregnancy, and placenta praevia.

The exponents of each of the various methods of the treatment of "pelvic suppuration" were present, and it seems that in this clearing house of ideas and experience the modern attitude was born. From now on the literature exhibits a waning tendency toward the exclusive use of any particular form of treatment and an increasing tendency to favor the selection of operative procedures which are indicated by the case at hand. This was made possible only by the experience gained during the preceding years of trial and innovation. As the records of this Congress indicate, this tendency had already become distinctly manifest.

The Congress was called to order with Péan in the chair. Segond, of Paris, opened the discussion of the treatment of pelvic inflammatory disease by presenting the operation of Péan, advocating the use of this operation in all cases in which the lesions were clinically bilateral. Péan then opened the general discussion in support of his

24. Segond: Del'hystérectomie vaginale dans le traitement des suppurations pelviennes, Rév. de chir. 4:350-431, 1891.

25. Wiedow: Zur operativen Behandlung des Pyosalpinx, Centralbl. f. Gynäk., 1885, p. 145.

26. Congrès périodique internationale de gynécologie et d'obstetrique, First Session, Brussels, 1892.

own work. William Travers, of London, said, "I would strongly urge, and I feel certain I am expressing the views of most British surgeons, that laparotomy be the method chosen." Sänger, of Leipzig, wisely remarked that as there were many roads that lead to Rome, so there were many methods of treating the different forms of purulent pelvic collections. Although he admitted that the Péan-Segond operation had enriched the gynecologic repertoire, he maintained that it should not be used exclusively. Goullioud, of Lyons, arose to speak a word of favor in defense of the method of his master, Laroyenne, admitting that his position had been somewhat modified in that he had been making use of the more radical operations that had just recently been devised when the drainage of the abscess per vaginam had not been curative.

Thus, through long and historically interesting hours, the Congress proceeded to its close. Although a few of the older men were still championing the exclusive use of their own methods, it was perfectly clear that the day of ultraconservatism and ultraradicalism was gone.

Since 1892, the outstanding features in the literature on the treatment of pelvic abscess have been the indications for the operation, the extent to which conservatism should be carried out, the development of the operative technic, the question of irrigation and the value of the operation as judged by its end-results.

The question of irrigation goes farther back than 1892. In 1879, Emmett[11] recommended the use of mildly antiseptic solutions for irrigating the abscess sac following vaginal drainage. Laroyenne[14] and Goullioud,[16] with their contemporaries Vallas and Blanc,[15] developed this procedure to a high degree. Landau[27] recommended irrigation in 1891 and again in 1892. In 1895, Rodriguez[28] described a two-way rubber drainage tube which was held in place in the abscess sac by sutures placed through the posterior lip of the cervix or the edge of the vaginal incision. One year later, in 1896, La Bonnardiere[29] recommended a procedure similar in principle to that of Rodriguez. Vincent, of Lyons, in whose clinic La Bonnardiere was engaged, irrigated through this two-way tube until the returning fluid was clear, and repeated these daily irrigations until the temperature became normal. Then the tube was removed and iodoform packs were inserted. La Bonnardiere stated that they had used simple iodoform packs instead of rubber irrigating tubes in several cases, and that in these patients

27. Landau: Ueber Tubensäcke, Arch. f. Gynäk., 1891, and Centralbl. f. Gynäk., 1892.

28. Rodriguez, I.: De l'incision du cul-de-sac postérieure et du drainage para-utérin dans les suppurations et hématomes pelviens, Thèse 281, Paris, 1895.

29. La Bonnardiere: Du traitement des collections pelviennes par l'elytrotomie postérieure interligamentaire, et le drainage par un drain double à pavillon d'arrêt. Ann. de gynéc. et d'obst. **45**:126, 1896.

the convalescence had been marked by high fever, while in those who were treated by irrigation this high postoperative pyrexia did not occur. The average length of convalescence of his patients was from four to eight weeks. Some of the patients of Laroyenne were confined to the hospital for eight months.

In 1902 Montgomery,[30] of Philadelphia, advised thorough irrigation of the abscess sac. In this clinic under the direction of Howard A. Kelly, irrigation was practiced in the first few years. Since that time we have not used it. Our results, both with and without irrigation, and the reasons which induced us to abandon it will be given in the following sections of this paper.

During the decade following 1892, Fernand Henrotin,[31] of Chicago, and Joseph Price,[32] of Philadelphia, wrote very clearly on the treatment of pelvic infections. Henrotin,[33] by his operative conservatism, his unqualified condemnation of the common practice of performing the easiest operation (a radical excision of the pelvic organs), by his method of treating puerperal pelvic cellulitis and localized pelvic collections, undoubtedly made contributions of definite worth. Although in many instances the practices which he advised are accepted today, it is only to be expected that more recently acquired knowledge should have demonstrated that some of his empiric deductions were based on insufficient grounds. It is thus interesting to observe that he stated that the uterus should always be thoroughly curetted and packed in all cases of pelvic infection. Also he recommended the routine operative treatment of acute pelvic inflammatory disease, and in many instances apparently performed radical extirpative procedures per vaginam when today we would recommend conservative measures through an abdominal incision.

Throughout this period in America, there was still a distinct tendency to lay stress on pet operative procedures and not on operative indications. This was undoubtedly a natural result of the important contributions that had recently been made in operative technic and is exactly the same situation which had existed in Europe before this time. In this respect, the meeting of the Chicago Gynecological Society, held on Sept. 16, 1898, was almost a replica of the International Congress of Gynecologists and Obstetricians [26] which had convened in

30. Montgomery, E. E.: Vaginal Section in Suppurative Disease of the Pelvic Structures. Indications and Technique, Am. Med. **4**:896, 1902.

31. Henrotin, Fernand: The Operation of Choice in Pelvic Disease, with Especial Reference to the Early Vaginal Incision, Brit.. M. J. **2**:1159-1164, 1897.

32. Price, Joseph: Abdominal Versus Vaginal Section in Pelvic Surgery, Am. Gynec. and Obst. J. **13**:522-529, 1898.

33. Henrotin, Fernand: The Indication for Interference by Way of the Vagina in Pelvic Diseases: An Answer to Joseph Price, Am. Gynec. and Obst. J. **13**:529-536, 1898.

Brussels six years before. In this discussion, Joseph Price,[32] of Philadelphia, and Franklin H. Martin,[34] of Chicago, were of the same opinion as the British surgeons and Fernand Henrotin [33] defended the position formerly held by Laroyenne, Péan, Segond and the French school. As we look back at the records of this and other such meetings, we are impressed with the definite progress that has since been made in the treatment of pelvic infections. This, we feel, has been due in no small part to the achievements of Howard A. Kelly and his pupils.

We have thus hurriedly traced from its very beginning the history of the treatment of one of the commonest of maladies, salpingitis, and in particular, pelvic abscess. We have observed the uncertain steps of the earliest clinicians as they honestly groped about in a maze of doubt and misinformation in their efforts to solve the problems that confronted them. With the development of bacteriology, asepsis, pathology, anesthetics and operative technic, we have watched the gradual passing of the hypotheses of a former generation and the evolution of a new pathology which has placed the treatment of pelvic inflammatory disease on a scientific and rational basis.

II. THE OPERATION

The manual technic of the operative procedure which is employed in this clinic is simple and easy of performance. We follow in general the plan of operation which was laid out by Howard A. Kelly.[3] This work has not been revised since 1907; if it had been, it is quite probable that some of the modifications which we suggest here would have been incorporated.

Given a pelvic mass which can be drained by the vaginal route, the one factor which is essential to and will contribute more toward the success of the operation than any other is a careful examination of the pelvis, made bimanually per vaginam and per rectum. This examination should be made by the operator himself and should be performed immediately before the operation is begun, after the patient has been anesthetized and catheterized. It is necessary to use great care in examining a pelvic abscess bimanually, and especially per rectum, as in some cases the abscess wall may be ruptured, thus giving rise either to general peritonitis or to rectoperitoneovaginal fistula. This ether examination should always be preceded by a similar investigation made before the patient is anesthetized, as it is just as important to eliminate the possibility of the presence of an early peritonitis as it is to establsih the diagnosis of pelvic abscess. Having thus convinced himself that there is no immediate indication for an abdominal operation, provided the pelvic mass can be opened and drained successfully per vaginam, having established the anatomic relationship of the abscess to the

34. Martin, F. H.: Discussion. Am. Gynec. and Obst. J. **13**:594-597, 1898.

uterus, the bladder, the broad ligaments and the rectum, and having also determined its most easily accessible and most dependent part as well as any point of fluctuation, the operator is in possession of all the information necessary to the successful performance of the operation.

It is always well to employ the same preoperative preparation of patients with pelvic abscess as would be used preceding a laparotomy, for in these cases one can never be absolutely assured that a laparotomy will not be necessary. The patient is shaved, catheterized, the external genitalia, vagina and perineum are thoroughly washed with soap and water, flushed freely with sterile water, mercuric chlorid solution (1-1000) and alcohol. This completes the vaginal and perineal cleaning.

The first step in the operation consists in obtaining the proper exposure of the cervix and the posterior vaginal vault by means of Sims' posterior vaginal speculum and by grasping the posterior lip of the cervix firmly with a toothed clamp, such as Jacob's. Gentle traction on the cervix by means of this clamp and on the posterior vaginal wall by means of the speculum puts the posterior vaginal vault under light tension. A transverse incision is then made at the junction of the posterior vaginal mucosa with the firm tissue of the cervix. This preliminary incision should extend only through the vaginal mucosa, exposing the peritoneum of the culdesac of Douglas and should be about 2 cm. in length. The location of the incision, its length and its relation to the cervix are shown clearly by Figure 319 on page 655, in Kelly and Noble's Gynecology and Abdominal Surgery. Sharp and pointed instruments are now discarded entirely. If the mass lies in the midline, the peritoneum is opened by piercing it with a long Kelly clamp or a uterine dilator, the instrument being pointed upward along the posterior wall of the fundus of the uterus and not downward toward the rectum. When the abscess is very low in the culdesac and is close to the rectum, it may be wise to have an assistant guide the operator throughout the whole operation by keeping a finger in the rectum. In these cases, Dr. Howard A. Kelly [35] recommends what he calls his "straddling manoeuvre." In this procedure, the operator acts as his own guide by placing the index finger of his left hand into the vagina and the middle finger into the rectum, thus straddling the perineum and orienting himself absolutely as to the relations of the rectum and the pelvic abscess. In many instances, as soon as the operator introduces the clamp through the peritoneum, there will be a gush of pus or fluid, indicating that an abscess has been opened (Fig. 1). The clamp should now be spread open, as the widening of its jaws will open the drainage tract into the abscess. Cultures and slides of the fluid can be made for bacteriologic examination. As long

35. Kelly, H. A.: Personal Communications, 1920.

as the pus continues to flow, there is no advantage to be gained by withdrawing the clamp. After the flow has ceased, the clamp is removed and the finger introduced. With one hand on the abdomen, a bimanual examination of the abscess sac and the pelvis is made, in order to determine whether the main mass has been thoroughly drained and whether there are accessory pockets which ought to be opened. During this examination, care should be exercised not to break up adhesions

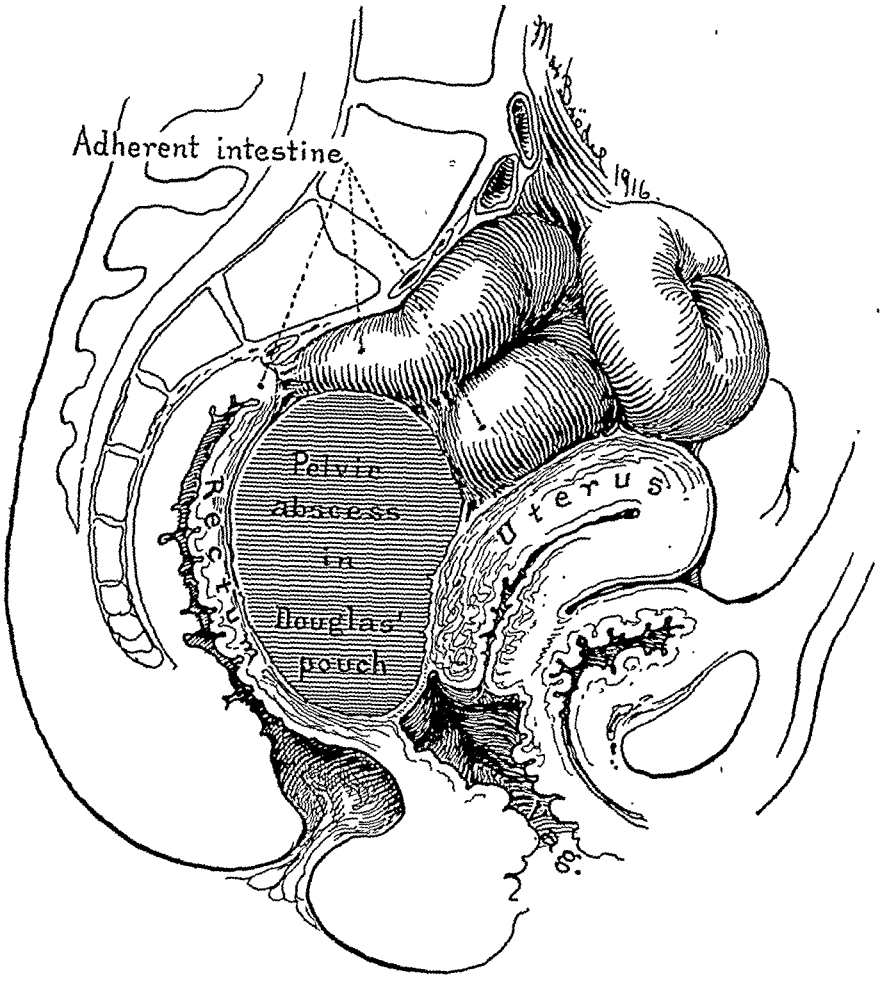

Fig. 1.—A unilocular pelvic abscess, the simplest type of pelvic abscess. The ease with which such a collection could be drained per vaginam is evident. As a rule, however, pelvic abscesses are far more complex than this, and are more apt to conform to the findings shown in Figure 2.

which may be separating the general peritoneal cavity from the abscess sac. If no other masses are found, the operator is ready to insert the drains, should there be accessory pockets (Fig. 2). Their point of closest connection with the main mass should be determined and at this point each one should be opened and drained. In this way, sub-

sidiary abscesses can be evacuated without soiling or entering the free pelvic cavity.

In the ordinary case of pelvic abscess of the gonorrheal type, soiling the peritoneal cavity is not so serious a matter as it is in the puerperal pelvic abscess. The important fact to remember is that if the peritoneum is accidentally opened, this opening should be immediately enlarged widely and thoroughly drained, for paradoxical as it

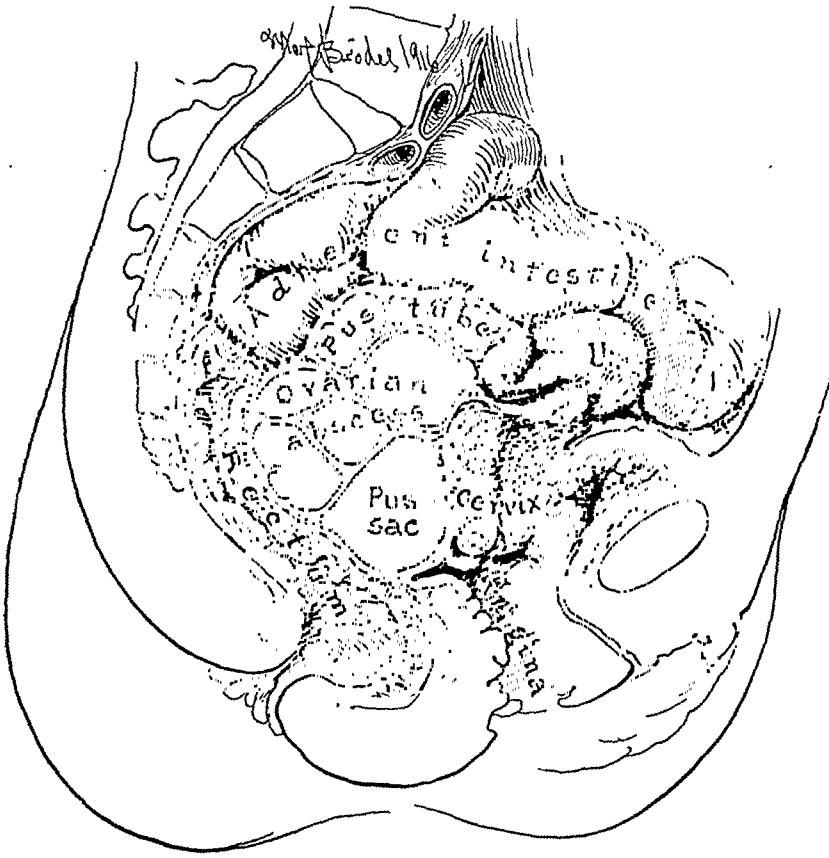

Fig. 2.—A multilocular pelvic abscess. Between the simplicity of a unilocular pelvic abscess (Fig. 1) and the complexity of this type of abscess, one finds innumerable gradations. One can readily imagine the many dangers and difficulties which would be encountered in attempting to remove these masses through an abdominal incision. In such cases as this, vaginal incision and drainage is often a life-saving procedure.

may seem, a small opening into the peritoneum in the presence of infection is far more dangerous than a large one. Should the abscess be sharply circumscribed, Kelly [35] states that he occasionally introduces a small piece of gauze into the sac after it has been thoroughly opened

and emptied and wipes out the interior of the sac very gently. By this means he is at times able to bring out an infected membrane which otherwise would have to be absorbed. He adds the warning that this procedure must not be practiced indiscriminately or without great care.

For drainage material, we use washed iodoform gauze, in strips 3 or 4 inches wide, either free or rolled into the form of cigarets by means of sheets of thin rubber protective. As a general rule, abundant drainage should be used. We frequently use three iodoform gauze drains, two of which are rolled into the form of cigarets and the other free. The cigaret drains are inserted first, one into each upper angle of the abscess cavity; the loose gauze strip is then placed lightly between them, passing well up into the cavity also. If there is any point of oozing at the edge of the vaginal incision, the iodoform gauze can be placed directly in contact with it. Should the drainage tract become plugged, one of these drains can be withdrawn at any time without interfering with the others. Generally, the drains are not touched until the sixth or seventh day, when, by means of a twisting motion, they are gradually loosened and moved about 2 cm., this being repeated on each successive day until they are completely romoved. It is dangerous to irrigate the pelvic cavity, either during the course of the operation or the convalescence.

With the patient in high Fowler's position, drainage should be free. Since it is necessary to build up the general condition of these patients, rest and hygienic measures are essential. We, therefore, recommend as a routine that these patients should be kept in bed for ten days or more until the pain is entirely gone, the temperature and pulse are normal and the general strength much increased. One will rarely make a mistake in following out this procedure. In some instances, in which the pelvic abscess is definitely circumscribed, low in the culdesac, not accompanied by any complications, and when the general condition is good, Cullen allows his patients to sit up in a chair on the day after operation in order to facilitate drainage. He does not recommend that this practice should be used indiscriminately, however, but considers it applicable only when the local and general conditions are definitely satisfactory.

In many instances after the operator has opened the peritoneum, he does not find pus immediately. In these cases it is unwise to explore the pelvis indiscriminately with an instrument. Such a procedure is unsafe and at times will lead to disaster. The operator should enlarge the opening into the culdesac, insert the index finger and locate the mass accurately, determine whether it is cystic, whether it can be drained satisfactorily per vaginam and whether there are additional masses. It is a safe rule that if a mass cannot be punctured easily, it

should not be punctured at all, because extensive instrumentation in the dark, in close proximity to loops of small bowel and the rectum is apt to be dangerous. If, therefore, the mass is situated so high in the pelvis that it cannot readily be reached and opened per vaginam, the attempt should be abandoned immediately, the vaginal incision should be temporarly packed lightly and the mass should be removed by an abdominal operation. In such case, the vaginal incision has done no harm; on the contrary, it has been of aid in establishing the diagnosis accurately, making the surgical indication clear and saving the time necessary to make a drainage opening later in the operation.

Occasionally, on the other hand, an operator will open an abdomen under the impression that he is dealing with a myoma of the uterus or an ovarian tumor, and find on inspection that the mass is a pelvic abscess which chokes the pelvis, is densely adherent on every side and could not be removed except at great risk. Under such conditions an abdominal operation would almost of necessity be extremely radical, attended with severe shock and possibly followed by very undesirable sequelae. Here it would be the part of wisdom for the operator to consider the possibility of draining the abscess per vaginam and abandoning the abdominal operation temporarily. This has happened in numerous instances in this series of cases. Under these circumstances the vaginal drainage can be carried out with extreme accuracy and thoroughness, for guided by an assistant who keeps one hand in the abdomen, the operator can open every pocket with safety. Although some of our most brilliant results have been obtained in patients who have been treated in this manner, we do not recommend that this should be done as a routine procedure for we do not believe it is either necessary or wise to open the abdomen in order to drain a localized pelvic abscess per vaginam.

A pelvic abscess may be enclosed entirely within the leaves of the broad ligaments and therefore be wholly extraperitoneal. In such cases, it would be extremely unwise to open the peritoneum by any method, either vaginal or abdominal. This type of abscess is particularly common in connection with puerperal infections, and in these the organism is usually virulent.

The accepted method of draining abscesses in this location is extraperitoneally through the groin. This method of approach in the treatment of broad ligament infections was apparently described first by Hegar,[36] in 1881. Five years later Pozzi[37] read a communication before the Society of Surgery of Paris in which he reported having

36. Hegar. Vortag a. d. Oberhein Aertztetag, Freiburg, 1881.

37. Pozzi, S.: De la laparotomie sous-péritonéals. Bull. et mém. Soc. de chir. de Paris **12**:294-312 (April 14) 1886.

performed this operation five times with success. It is evident that by this time this procedure was beginning to be used, for during the discussion of Pozzi's paper, Trélat, Bouilly and Lucas-Championière stated that they also had utilized it several times with varying success. The indications for this operation in the treatment of collection of pus in the pelvis had not as yet been clearly established, however. Pozzi [7] again described this operation in 1897, presenting a particularly clear résumé of the clinical indications and the operative technic. Since that date the various modifications have been duly recorded in the current literature, one of the most recent as well as most clear expositions of the extraperitoneal method of drainage being contained in an article by Cullen.[38] In the same paper, he outlined the various surgical methods of treating pelvic infections in which laparotomy is indicated. He also calls attention to the fact that during laparotomy for severe pelvic inflammatory disease, the pulse of the patient often becomes very rapid, ranging from 120 to 160 per minute, and states that this need be no cause of immediate alarm provided the quality of the pulse remains good and the general condition satisfactory. In patients of this type, we make it a rule to start a hypodermoclysis as soon as the patient is anesthetized. We also believe that the resistance of these patients is limited and that the operative shock and mortality can be greatly lessened by a well directed preoperative course of treatment including tonics, regulation of diet, transfusion when necessary and local treatments. For this reason, the operative treatment of severe grades of pelvic inflammatory disease requires no small amount of preoperative consideration and at times well directed operative expedition.

There is another method of draining broad ligament abscesses which has been described by Kelly,[39] and ascribed by him to Hunner. This method seems to be applicable only in those instances in which the abscess is low in the base of the broad ligament and can be easily felt per vaginam. In these cases, Hunner has used his extraperitoneal vaginal drainage, making an incision posterior to the cervix as one would to drain a pelvic abscess. The peritoneum must not be opened, however. As soon as the mucosa of the vaginal vault has been incised, the peritoneum is gently pushed back by the finger, the dissection being carried out laterally and posteriorly until the base of the broad ligament is reached and the abscess opened. In performing this operation, one is working in the immediate region of both the ureter and the uterine vein and artery; consequently great care must be exercised in

38. Cullen, T. S.: The Surgical Methods of Dealing with Pelvic Infections, Surg., Gynec. & Obst. **25**:2, 134-146, 1917.

39. Kelly, H. A.: Operative Gynecology, New York, D. Appleton & Co. **2**:208-210, and Footnote 3.

order to avoid injuring these structures. With this in view, Hunner states that the dissection must be carried posteriorly, keeping behind the uterine vessels and the uterovesical plexus. It is evident that this procedure is limited to those instances in which the abscess is situated low in the base of the broad ligament and in which extensive dissection will not be necessary.

The operative methods of handling anteuterine pelvic abscesses were clearly presented by Howard A. Kelly,[40] in 1910. After reviewing the pathology, he outlines three methods of draining abscesses of this unusual type: (1) drainage through the anterior vaginal vault by an anterior colpotomy; (2) drainage through the abdomen and anterior vaginal vault combined; (3) sequestration of the abscess by suturing the round ligaments and the uterus to the anterior abdominal wall and then draining through the anterior vaginal vault and the lower angle of the abdominal incision.

III. THE CLINICAL ASPECTS OF PELVIC ABSCESS

This section of the paper is devoted to a study of cases of pelvic abscess in which treatment by vaginal incision and drainage has been employed. There are two objects of this study:

1. To summarize our experience with cases of pelvic abscess and similar purulent pelvic collections, with reference to the preoperative clinical findings, complications, treatment, operative accidents, convalescence, immediate and ultimate results following treatment by vaginal incision and drainage.

2. On the basis of the above summary, to determine the proper rôle of vaginal incision and drainage as an operative procedure in the treatment of the purulent forms of chronic pelvic inflammatory disease.

This report is based on the histories of patients that were operated upon in the gynecologic department of the Johns Hopkins Hospital between 1892 and June, 1915.[41] During this period of about twenty-four years, 716 patients were treated by vaginal incision and drainage. The material under this heading will be presented in conformance with this outline:

A. The diagnosis of pelvic abscess.

B. General clinical summary: race, age, clinical classification, temperature, pulse, leukocytosis, preoperative complications, operative treatment and mortality.

---

40. Kelly, H. A.: The Treatment of Ante-Uterine Pelvic Abscess by Sequestration and Drainage, Am. J. Obst. **61**:921-925, 1910.

41. This work was begun before we entered the war. It was temporarily dropped in 1917 and was not resumed until 1919, when the author was discharged from military duty. Hence the cases since 1918 have not been included.

C. Pelvic abscess complicated by conditions existing before operation or arising during convalescence which required abdominal operation, 170 cases.

D. Postoperative pelvic abscess, forty cases.

E. Pelvic abscess and purulent pelvic collections treated by vaginal incision and drainage only, without fatality, 462 cases:

(*a*) Diagnosis and preoperative complications.
(*b*) Operative accidents.
(*c*) Convalescence.
(*d*) Immediate results.
(*e*) Ultimate results

F. Deaths following treatment by vaginal incision and drainage, forty-four cases.

G. Conclusion and summary: the rôle of vaginal incision and drainage as an operative procedure in the treatment of pelvic abscess and similar purulent collections in chronic pelvic inflammatory disease.

A. The Diagnosis of Pelvic Abscess.—From the standpoint of diagnosis, the clear presentation of the subject of pelvic abscess must involve the presentation of all cases with which this condition has been confused and in which vaginal drainage was attempted, whether with success or not. In ninety-one cases out of this series of 716, vaginal incision and drainage was attempted, but pelvic abscess was not found. The fact that vaginal drainage was attempted presupposes in most of these cases that the operator found himself in the presence of a pelvic mass which, in his opinion, was probably inflammatory in origin and contained fluid which could be evacuated per vaginam. In some of these instances, this operation was performed merely as a diagnostic procedure. The ninety-one cases tabulated below present the diagnostic problems that have been encountered in the treatment of this series of pelvic abscesses, and every gynecologist knows how difficult at times these problems are. It is for this reason that these cases are included here. In the clinical study of pelvic abscess itself, these cases will not be considered.

The list of diagnoses of all the cases that are included in the scope of this article are given in Tables 1 and 2: first, the cases of pelvic abscess and pelvic mass of inflammatory origin containing fluid, and, secondly, the list of cases in which vaginal incision was made, but in which pelvic abscess was not found.

B. General Clinical Summary.—We shall promptly drop out of consideration the ninety-one cases in which the main pelvic masses were not of inflammatory origin, and proceed to make a study of the 625 cases of pelvic abscess or similar purulent collection.

1. Race: We found pelvic abscess about twice as common in the black as in the white race.

2. Age: This condition occurs almost exclusively in the period of sexual activity. Fifty-three per cent. of our patients were between the ages of 20 and 30. Twenty-seven per cent. between 30 and 40. The age of the oldest patient was 54, the youngest 13.

TABLE 1.—DIAGNOSIS IN CASES OF PELVIC ABSCESS OR SIMILAR INFLAMMATORY MASSES CONTAINING FLUID

Diagnosis	No. of Cases
Pelvic abscess (neither tuberculous nor puerperal)	463
Pelvic abscess, tuberculous	9
Pelvic abscess, puerperal	45
Pelvic abscess, appendiceal	1
Pyosalpinx	64
Tubo-ovarian abscess	38
Ovarian abscess	5
Total	625

TABLE 2.—DIAGNOSIS IN CASES IN WHICH VAGINAL INCISION WAS MADE BUT PELVIC ABSCESS WAS NOT FOUND

Diagnosis	No. of Cases
Extra-uterine pregnancy, ruptured, old	28
Myomata uteri, with salpingitis	13
Chronic pelvic inflammatory disease with acute pelvic peritonitis	17
Subacute pelvic inflammatory disease	2
Acute pelvic inflammatory disease	2
Ovarian cysts, multilocular, with chronic pelvic inflammatory disease	10
Dermoid cysts, with adhesions and pyosalpinx	6
Adenocarcinoma of ovary	3
Postoperative hematoma	8
Postoperative serum collection	1
Postoperative extravasation of urine	1
Total	91
Total pelvic abscess and purulent collections	625
Total pelvic masses not of inflammatory origin	91
Total	716

3. Classification: It would be highly desirable to be able to divide these cases into groups on the basis of bacteriologic findings. Because of the wide variety of atypical organisms found and for other reasons, such a classification at present is not feasible. I am dividing them into three clinical groups: puerperal, tuberculous and abscesses of other origin. This classification is extremely unsatisfactory and unscientific, I admit. It corresponds to the clinical types fairly well, however, and affords a working basis. The pelvic abscesses which I have called of uncertain origin are said to be usually gonorrheal. Although this is probably true, bacterial examinations, when positive, are very much

more likely to show secondary invaders, such as the colon bacillus, atypical streptococci, staphylococci, and unclassified anaerobic organisms. This group far outnumbers both the other two; five sixths of our cases were of this type. For a résumé of the bacteriologic findings in cases of pelvic abscess and pelvic inflammatory disease, the reader is referred to Howard A. Kelly's Operative Gynecology.[39] The bacteriology of pelvic infections is a subject, however, which has not yet been completely investigated. Arthur H. Curtis[42] has recently made some valuable contributions to our knowledge concerning this field.

4. Temperature: Patients with pelvic abscess usually show an elevation of temperature which may at times be very high. The temperature findings in patients with abscess of the gonorrheal type are given in summary in Table 3.

The highest temperature, 107.8 F., and the lowest, 96.8, were both found in patients with abscesses of this type.

TABLE 3.—TEMPERATURE FINDINGS IN PATIENTS WITH ABSCESS OF GONORRHEAL TYPE

Temperature	Cases, Per Cent.
98.6 F. or below	6.0
98.6 to 99	3.1
99 to 100	27.7
100 to 101	26.5
101 to 102	16.5
102 to 103	11.4
103 to 104	6.2
104 to 105	1.6
Over 105	1.0
	100.0

In cases of puerperal pelvic abscess, as a rule, the temperature is higher than in any other type. In 57 per cent. of these cases, the temperature on admission was between 101 and 103 F., in only 24 per cent. was the temperature below 101. Tuberculous abscesses have usually been accompanied by low fever, in no instances being below 99, and in only one above 102.

5. Pulse: The pulse rate was almost always above 100 to the minute in all types of cases. This point should be of diagnostic importance in the differentiation of pelvic masses of uncertain origin.

6. Leukocytosis: The white blood count was made in 124 cases of pelvic abscess. In 28 per cent., the counts were between 10,000 and 15,000; in 26 per cent. between 15,000 and 20,000; in 24 per cent.

42. Curtis, A. H.: A Combined Bacteriological and Histological Study of the Endometrium in Health and in Disease. Surg., Gynec. & Obst. 26:178-188. 1916.

between 20,000 and 30,000. The lowest count was 6,280; the highest 62,800. Although the white blood count usually followed the temperature in elevation, there were notable exceptions. The patient that had the highest temperature (107.8 F.) had the lowest white blood count (ranging from 6,280 to 9,400) and recovered (Gyn. No. 15903).

7. Preoperative Complications: Since it is impossible to understand the subject of pelvic abscess without knowing its complications, a list of the complications that have been noted in our cases are given in Table 4.

8. The Operative Treatment and Mortality: In the treatment of these 716 cases, vaginal incision and drainage was employed 871 times, and 286 laparotomies were performed—a total of 1,157 operative procedures. Fifty-six of these patients were admitted at least twice to this hospital, a total of 771 admissions, and in several instances operative procedures were repeated. The mortality in cases of pelvic abscess was 5.1 per cent.

From the operative point of view, these cases fall into three main groups:

(a) Patients treated by both vaginal incision and drainage and also abdominal operation—170 cases.

(b) Patients treated by vaginal incision and drainage for postoperative pelvic collections, following operations of a more or less unrelated nature—forty cases.

(c) Patients with pelvic abscess or purulent forms of chronic pelvic inflammatory disease treated by vaginal incision and drainage only —462 cases.

Since the object of this paper is to present the results obtained in the treatment of pelvic abscess and similar purulent collections by vaginal incision and drainage, the last group of cases is of chief concern to us. The first two groups are closely related and will be presented briefly. The presentation of these three groups of cases will be followed by an analysis of the cases of the patients that died.

C. Group 1.—*Pelvic abscess complicated by conditions existing before operation or arising during convalescence, the treatment of which required abdominal operation, 170 cases.*

This group is presented because it exhibits types of pelvic abscess in which complications rendered vaginal incision and drainage insufficient as preliminary therapy. To that extent it will show some of the limitations of the operation. It must be said, however, that in the majority of these cases the vaginal drainage of the main pelvic collection rendered the abdominal operation both simpler and safer.

In the treatment of these 170 patients, vaginal incision and drainage was used 225 times, laparotomy, 198 times. Laparotomy was resorted to usually for one of two reasons: (1) preoperative compli-

cations which rendered vaginal incision and drainage insufficient; (2) complications developing during convalescence which required laparotomy.

The preoperative complications which rendered the vaginal operation unsatisfactory fall into three groups: (*a*) those in which the main

TABLE 4.—COMPLICATIONS NOTED IN CASES OF PELVIC ABSCESS

Complications	No. of Cases
Pelvic abscess complicated by:	
Rupture into bladder before operation	3
Rupture into rectum before operation	10
Rupture into both rectum and bladder before operation	1
Rupture into vagina before operation	2
Rectum passed through abscess	1
Intestinal obstruction due to pressure of abscess on rectum and sigmoid	2
Rectal stricture	5
Pelvic abscess, anteuterine	3
Vesicovaginal fistula	5
Peritonitis, encysted, pelvic	8
Peritonitis, pelvic, spreading	6
Peritonitis, general, purulent	13
Peritonitis, general, tuberculous	2
Vaginitis, acute	1
Pyosalpinx, bilateral	12
Tubo-ovarian abscess, bilateral	4
Myomata uteri	17
Myomata uteri, suppurating	1
Ovarian cyst (in one case with twisted pedicle)	5
Dermoid cyst	2
Pyometra, without carcinoma	2
Carcinoma cervix, inoperable	2
Carcinoma cervix, operable	1
Carcinoma fundus, inoperable	1
Carcinoma ovary, inoperable	1
Hydronephrosis, bilateral	1
Acute appendicitis	3
Subacute appendicitis	6
Chronic appendicitis, involved in pelvic abscess	30
Double vagina, double uterus	1
Congenital absence of tube, unilateral	1
Chronic nephritis	1
Diabetes mellitus	1
Pulmonary tuberculosis	1
Pyosalpinx complicated by:	
Myomata uteri	1
Myomata uteri, degenerating	1
Ovarian cyst, gangrenous	1
Pelvic peritonitis	4
Hydrosalpinx complicated by:	
Encysted pelvic peritonitis	1
Encysted peritonitis and dermoid cyst	1
Tubo-ovarian abscess complicated by:	
Encysted peritonitis	2
General peritonitis	1
Spreading peritonitis, pelvic	1
Puerperal pelvic abscess complicated by:	
Retained membranes, with bleeding	1
Abscess of abdominal wall	1

pelvic collection was inaccessible because of its position in the pelvis; (*b*) those in which an accessible main collection was accompanied by subsidiary abscesses which were inaccessible, and (*c*) cases of pelvic abscess complicated by conditions which by nature could not be treated by vaginal incision and drainage.

In thirty-nine instances, the vaginal operation was attempted but failed to reach the main abscess mass. In twenty, although the main abscess was successfully opened by the vaginal route, the inaccessibility of the subsidiary collections of pus made abdominal operation necessary (Table 5)

Complications which could not be treated by vaginal incision and drainage were found in forty-five instances (Table 6).

TABLE 5.—CASES IN WHICH SUBSIDIARY COLLECTIONS OF PUS MADE ABDOMINAL OPERATION NECESSARY

Collection of Pus	No. of Cases
Pyosalpinx	12
Tubo-ovarian abscess	3
Encysted peritonitis	3
Abscess of abdominal wall	1
Ovarian abscess	1

TABLE 6.—COMPLICATIONS NOT SUSCEPTIBLE OF TREATMENT BY VAGINAL INCISION AND DRAINAGE

Complications	No. of Cases
Myomata uteri	13
General purulent peritonitis	8
Pelvic peritonitis	6
Ovarian cyst (one with twisted pedicle)	5
Subacute appendicitis	5
Acute appendicitis	3
Dermoid cysts	3
Tuberculous peritonitis	1
Tubal pregnancy, unruptured	1

The frequency with which the appendix is involved in pelvic abscess had been observed before. In nineteen of these 170 patients, the appendix was definitely involved in the pelvic abscess, though not causing it. Coopman [43] stated in 1915 that the appendiceal involvement in cases of chronic purulent pelvic inflammatory disease in itself often justified laparotomy. Norris,[44] who has investigated this subject in detail, has emphasized the frequent association of appendicitis with pelvic peritonitis. This is borne out by our findings.

43. Coopman, H. L.: Ueber konservierende und operative Behandlung chronischer Adnexerkrankungen, Zentralbl. f. Gynäk. **39**:257-261, 1915.

44. Norris, C. C.: Gonorrhea in Women, Philadelphia, W. B. Saunders Company, 1913, p. 302.

Two congenital anomalies of rather unusual character were found in this series of cases. One patient had congenital absence of one tube with a calcareous ovary on the same side. The function of the other side had been normal, however, as she had had several normal pregnancies. Another patient (Gynecology No. 4887) had a double vagina with double uterus. She had always had severe dysmenorrhea, had been married twenty-six years, and had had six pregnancies. Three of the pregnancies had continued to term; three had ended in miscarriages at the end of the sixth, fourth and third months, respectively. Examination revealed that the left hymen was unruptured, all sexual activity having taken place on the right side. There were two separate vaginas, the vaginal mucosa on the right side having been smoothed out by labor, on the other side the normal virginal rougie were present. There were two cervices, each leading into a separate uterine cavity. The patient had an abscess which occupied the left side of the pelvis and also a complicating rectal stricture.

Thirty-four patients were subjected to laparotomy for complications arising during convalescence after vaginal incision and drainage (Table 7).

TABLE 7.—CASES IN WHICH LAPAROTOMY WAS PERFORMED FOR COMPLICATIONS DURING CONVALESCENCE

Complications	No. of Cases
Febrile course, not relieved by vaginal incision and drainage	27
General peritonitis	3
Intestinal obstruction	2
Severe bleeding from vaginal drainage tract	1
Intra-abdominal rupture of abscess during examination	1

The abdominal operations in these 170 patients consisted of either more or less radical extirpative procedures or abdominal drainage. In the early years in this clinic, it was not an uncommon practice to treat pelvic abscess by mere abdominal drainage, somewhat after the manner of Lawson Tait.[21] This method has long since been abandoned.

No attempt has been made to determine the ultimate results obtained in the treatment of this series of 170 patients. About 50 per cent. of those that were subjected to no radical extirpative operation but who were treated only by combined abdominal and vaginal drainage have returned to this hospital without having been permanently relieved. This seems to demonstrate that in many cases mere drainage of a pelvic abscess, no matter how performed, will not give the patient permanent relief. It is our belief that if an abdominal operation is performed, it should under ordinary circumstances be of a curative nature, conservative when possible, radical when indicated. In order to be able to achieve this end, the preliminary drainage of any abscesses in the pelvis by the vaginal route is a great aid.

D. GROUP 2.—*Postoperative pelvic collections, forty cases.*

These patients developed postoperative pelvic collections following a variety of operations. All of these collections were drained by vaginal incision; in one instance it was also necessary to perform an abdominal operation in order to check a postoperative hemorrhage. The importance of these cases is found chiefly in the cause of the postoperative collections.

The diagnoses of these forty cases are given in Table 8.

TABLE 8.—DIAGNOSIS IN FORTY CASES OF PUS COLLECTION

Diagnosis	No. of Cases
Postoperative pelvic abscess	29
Postoperative hematoma	8
Postoperative serum collection	1
Postoperative extravasation of urine	1
Postoperative pelvic peritonitis	1

Of the twenty-nine cases of postoperative pelvic abscess, twenty-three developed in patients who had been operated upon for conditions which were primarily of an infected nature, and six developed in what were apparently "clean" cases. Of the twenty-three "dirty" cases, seven had been drained through the culdesac of Douglas and sixteen had not. Of these sixteen, five had had abdominal drainage. Drainage had not been employed in any manner in any of the six "clean" cases The operations in these six cases had been myomectomy, two cases; carcinoma of the ovary, two cases, and hysteromyomectomy, two cases. The case of extravasation of urine followed a ureteral anastamosis which had been performed during the radical operation for the cure of carcinoma of the cervix. Occasionally, following hysterectomies, small postoperative abscesses will form just above the stump of the cervix and beneath the bladder peritoneum which has been thrown over it. Cullen [45] has described and illustrated this form of complication.

Most of the cases of postoperative pelvic abscess developed in patients in whom the question of drainage was a matter of doubt or in whom pelvic drainage had not been used. On these occasions, the decision not to drain proved to be unfortunate. This is true not only of the "dirty" cases, but also of four of the "clean" cases—two myomectomies and two operations for the cure of carcinoma of the ovary.

These cases emphasize the value of pelvic drainage in pelvic infections. After the removal of a pyosalpinx, ovarian abscess or a similar purulent collection where there has been contamination of the operative field, in the presence of uncontrollable oozing after extensive pelvic

45. Cullen, T. S.: Johns Hopkins Hosp. Rep. 6:143-144, 1897 (Figs. 1 and 2).

dissections, after operations for carcinoma of the pelvic organs, after practically all panhysterectomies, in short, whenever drainage of the pelvis has been indicated, it has been almost a rule in this clinic to obtain it through an incision in the posterior vaginal vault, or in cases of panhysterectomy through the vaginal cuff. The advantages of this method of drainage are almost self-evident. With the patient in Fowler's position, the pelvis forms the basin toward which fluids tend to gravitate; hence, drainage through the floor of the pelvis perforates this basin at its most dependent point and allows these fluids to escape. It is well known that abdominal drainage can rarely achieve this result. By the use of vaginal drainage, moreover, the danger of developing hernia in the incision, postoperative obstruction and vicious adhesions is reduced almost to nil. By closing over the raw areas as completely as possible and placing the drain loosely against such areas as cannot be closed over, and by throwing the redundant coils of the rectum and sigmoid over the whole field of the operation, the operator excludes loops of small bowel from the pelvis, localizes and gives drainage to the infection. It is our experience that patients who have been treated in this manner have a remarkably smooth and short convalescence and avoid the danger of postoperative pelvic collections, granulating abdominal wounds, distention and hernias.

In advocating this type of drainage in pelvic infections, I would not give the impression that other methods are not at times clearly indicated. This is particularly true in cases of pelvic abscess with spreading peritonitis or secondary abdominal collections which can often best be drained through the abdominal incision. Broad ligament abscesses, moreover, which are secondary to puerperal infections, can best be approached and drained extraperitoneally through the groin. Cullen [38] has discussed this question with great clearness in a recent article.

E. Group 3.—*Four hundred and sixty-two cases of pelvic abscess or similar purulent collections treated only by vaginal incision and drainage without fatality.*

Of 625 patients with pelvic abscess or similar purulent collections found in connection with pelvic inflammatory disease, 462 were treated only by vaginal incision and drainage. This group constitutes the real subject matter of the paper. When considered with the twenty-five patients of this type that died, they give us a picture of the successes and failures that have followed our attempts to treat these conditions.

These cases will be presented from these points of view:

1. Diagnosis and preoperative complications.
2. Operative accidents:
   (*a*) Injury to the rectum.
   (*b*) Bleeding.
   (*c*) Injury to the bladder, ureter, small bowel, etc.

(*d*) Fistulas in connection with pelvic abscess: rectovaginal, rectoperitoneovaginal, vesicovaginal.

(1) Factors predisposing toward the occurrence of operative fistulas.

(2) Fistulas developing during convalescence.

(3) Fistulas as a factor in convalescence.

(4) Umbilical sinuses in pelvic abscess.

(5) Lumbar and psoas abscess complicating pelvic abscess.

3. Convalescence following vaginal incision and drainage of pelvic abscess.

(*a*) Types of convalescence.

(1) Normal convalescence.

(2) Convalescence with marked high rise of temperature immediately after operation.

(3) Continuously febrile convalescence.

(4) Convalescence with late high rise in temperature.

(*b*) Convalescence in the different types of cases.

(1) Puerperal pelvic abscesses.

(2) Tuberculous pelvic abscesses.

(3) Pelvic abscess of gonorrheal type.

(*c*) Convalescence following different methods of treatment.

(1) With irrigation.

(2) Without irrigation.

(*d*) Relation of the length of drainage to the convalescence.

4. Immediate results, following vaginal incision and drainage.

(*a*) Temperature and pulse at times of discharge from hospital.

(*b*) Condition of pelvis when discharged from the hospital.

(*c*) Symptoms present on discharge.

5. Ultimate results.

(*a*) Patients readmitted following the drainage of pelvic abscess.

(*b*) Patients followed by correspondence or visit.

(1) Relation of the method of treatment to ultimate result.

(2) Relation of the convalescence to the ultimate result.

(3) Relation of the length of drainage to the ultimate result.

(4) Relation of the immediate result to the ultimate result.

(5) Pregnancies following the drainage of pelvic abscess.

(6) Menstruation following the treatment of pelvic abscess by vaginal incision and drainage.

1. *Diagnoses and Preoperative Complications.*—The diagnoses of these 462 cases are given in Table 9.

There were numerous complications in these cases. Since I have already listed the complications of all of our cases in another place, I shall not enumerate them again. These cases, however, presented all the serious inflammatory pelvic complications which are ordinarily

found with such purulent collections, and which could be treated by vaginal incision and drainage.

TABLE 9.—DIAGNOSIS IN FOUR HUNDRED AND SIXTY-TWO CASES OF PELVIC ABSCESS OR SIMILAR PURULENT COLLECTIONS

Diagnosis	No. of Cases
Pelvic abscess, nonpuerperal, nontuberculous	320
Pelvic abscess, tuberculous	2
Pelvic abscess, puerperal	21
Pelvic cellulitis with abscess, puerperal	7
Pyosalpinx	32
Hydrosalpinx	6
Encysted peritonitis, pelvic	34
Tubo-ovarian abscess	30
Ovarian abscess	3
Acute pelvic inflammatory disease with abscess	3
Pelvic peritonitis	4

2. *Operative Accidents.*—In the treatment of these 462 patients, the only operation employed was vaginal incision and drainage. This procedure was used 538 times. These operative accidents occurred.

(*a*) Rectal Injury: In ten instances the rectum was apparently torn or punctured at the time of operation. In one of these ten cases, pressure on the abscess during a rectal examination made under anesthesia immediately before the operation, caused the abscess to rupture into the rectum. It has been pointed out that under some conditions the sudden evacuation of a large amount of fluid under high tension in the pelvis might so change the pressure relations that a very delicate abscess wall might immediately rupture into the rectum or the peritoneum without direct injury having been inflicted, due to intrarectal pressure.

(*b*) Bleeding: Significant bleeding from the vaginal veins occurred twelve times. In all these cases, it was stopped immediately either by packs or sutures. In one of these twelve cases, the bleeding was rather profuse. Bleeding from injury to the uterine arteries occurred only once. In that case, the left uterine artery was torn. The hemorrhage was readily controlled by a clamp.

(*c*) Injury to Bladder, Ureter, Small Bowel, etc.: There were no instances of injury to the ureter in any of our cases, nor were there any instances of injury to the small bowel. In three or four cases, parts of the small bowel protruded into the vagina during the operation. These patients had a high elevation of temperature for twenty-four hours after the operation; otherwise their convalescence was normal. In no case was the bladder injured although in three the pelvic abscess was anteuterine, between the bladder and the uterus, and in these cases the vaginal incision was made anteriorly to the cervix. These injuries

formerly seemed quite common and were a source of much discussion in the literature of 1885 to 1895.

(*d*) Fistulas with Pelvic Abscess: Rectal involvement in cases of pelvic abscess is not uncommon, either due to a preoperative complication, an operative accident, or as a development during convalescence. In pelvic inflammatory disease, pain on defecation is a symptom always to be looked for and very frequently found. Actual rupture of an abscess into the rectum, although not a rarity, is not so frequent. The same conditions which would lead an abscess to point and rupture into the rectum make it easy to injure that organ during the operative treatment.

The result of such an injury in every case we have had, whether the injury was operative or of spontaneous development, has invaribly been a fistula. This type of fistula has usually been called a rectovaginal fistula. In some cases this is what actually exists. In others, however, such a fistula is more than a rectovaginal fistula, the condition really being a rectoperitoneovaginal fistula. In these cases, the rectal opening is usually in the culdesac of Douglas, connecting the rectal lumen with the pelvic cavity or the abscess sac, which in turn opens into the vagina. This relationship has been clearly seen in several of our cases at necropsy and really is rectoperitoneovaginal fistula.

(1) *Factors Predisposing to the Formation of Fistula.*—The close relationship of a pelvic abscess to the rectum may lead not only to rectal injury at the time of operation, but also might cause other rectal complications of more or less serious moment. Among these are rectal stricture, due to a proctitis. This was seen in five of our cases. Or again, the abscess might burrow behind the rectum, pushing the rectum forward. In this type of case, a blunt clamp pushed in the usual manner into the mass with the idea of puncturing the abscess might perforate both walls of the rectum and traverse the rectal lumen before it reached the abscess sac. This unusual anatomic relationship was found in one case; the impending operative accident, however, was avoided by a careful rectal examination. In two cases of this series, the pressure of the abscess on the rectum and sigmoid was sufficient to cause chronic intestinal obstruction without genuine rectal stricture being present. This was relieved as soon as the abscess was evacuated. The evacuation of a large collection of fluid under pressure in the pelvis makes necessary rather definite mechanical readjustments in the relationship of the pelvic and lower abdominal viscera to the abscess sac. Where there was once a strong positive pressure in the abscess sac there is now a negative pressure. It is, therefore, possible that in these readjustments, a new factor such as postoperative distention, a quick muscular movement, urinary retention or the administration

of an enema, might cause the rupture of a weak point in the membrane lining the abscess sac either into the peritoneal cavity, the rectum, or rarely into the bladder.

All these complications tend to make it easy to injure the rectum. Nothing so clearly impresses the operator with the possibility of rectal injury during the vaginal drainage of an abscess as the view of the pelvis he obtains in cases seen at laparatomy or necropsy. This is particularly true in those cases in which the abdomen is opened immediately after an unsuccessful attempt has been made to drain an abscess by the vaginal route. Not infrequently does the operator then see that the clamp with which he had attempted to puncture the abscess had passed within a few millimeters of edematous, inflamed, friable and almost necrotic rectal wall which in such a condition would have ill withstood surgical insult.

It is of paramount importance, therefore, to make careful rectal examination before attempting to drain an abscess per vaginam. In many instances, moreover, we have found it advisable to have an assistant guide the operator during the operation by keeping his index finger in the rectum. In spite of all these precautions, we have found it impossible to avoid a certain number of rectal injuries.

We have had thirty-two rectovaginal or rectoperitoneovaginal fistulas. In ten of these cases, the abscess had ruptured into the rectum before admission to the hospital, and in these cases rectopelvic sinuses existed which were changed by the operation into rectoperitoneovaginal fistulas. In ten of these cases, the injury was probably operative, accidental in nine, in one intentional for the purpose of obtaining additional drainage. In the remaining twelve, the fistulas developed during the convalescence, the first symptom being the discharge of feces through the vaginal drainage tract.

(2) *Fistulas Developing During Convalescence.*—The cause of the development of fistulas during convalescence does not seem to have attracted much investigation in the literature. Although it is rather hard to ascribe a definite cause for every case, it is probable that in most instances the general etiologic conditions can be determined. In attempting to determine the cause of such postoperative fistulas, three factors are to be considered: (1) the period of time between the day of operation and the development of the fistula; (2) the material used for drainage, and, (3) the condition of the rectal wall.

The time relation between the operation and the development of the fistula is important in determining the cause of the fistula. Seven of our twelve postoperative fistulas developed within three days after the operation. Of the remaining five patients, four developed signs of fistula on the sixth, seventh, eighth and eleventh days, respectively, counting the day of operation as the first day. In one case, the fistula

was not observed until the twentieth day, at necropsy. Of the seven patients that developed fistulas early in convalescence, five show a fairly clear cause. In one instance, the patient died on the fourth day, and at necropsy a drain was found passing into the rectal lumen and out again at a higher level, showing clearly that the rectum had been perforated at operation. In four cases, the operator was convinced that he had torn the rectum, but was unable to find the injury, even with the proctoscope. The immediate development of fistula, however, proved that the operator's fears had been correct. It seems clear, therefore, that in some patients that develop signs of fistula early in convalescence, the complication is due to rectal injury inflicted during the operation. The difficulty of detecting such injury in the presence of pelvic abscess is well illustrated by the case just mentioned. In some cases in which there was no evidence of mechanical injury to the rectal wall, the development of fistula during the first few days of the convalescence seems to have been due to conditions beyond control, the friable condition of the rectal wall and the changes in pressure relations in the pelvis.

The material used for drainage in cases of pelvic abscess treated by vaginal incision and drainage is a matter of some importance in its relationship to fistula. We have long since discarded the use of rubber tubes for drainage in these cases, more from unfortunate experience with individual cases than as a result of systematic study of a whole group. In five of the cases that developed fistula during convalescence, rubber tubes were used for drainage; in seven, iodoform gauze, either plain or rolled into cigaret drains. Since the total number of cases in which rubber tubes have been used for drainage is much smaller than those in which gauze has been, we believe that the action of our predecessors in this clinic in abandoning rubber tubing for pelvic drainage was well indicated.

It is probable, however, that any material used for drainage might have a tendency to cause fistula in patients with extreme proctitis. In one third of our cases of postoperative fistula, the rectal opening was detected first on the day on which the drains were started or removed. In one of these cases, there was a rectal slough on the eleventh day, no sign of fistula having been present before that time. In two thirds of the patients that developed fistula after the fourth day, there seemed to be some definite connection between the moving of the drains and the development of fistula. We cannot avoid this complication by removing the drains early, as prolonged drainage is the essential requisite in the treatment of these patients. The only paths of escape lie in the choice of soft material for drainage, iodoform gauze or loose cigaret drains, and care in placing the drains so as not to cause pressure on the rectum.

(3) *Fistulas as a Factor in Convalescence.*—The convalescence of patients with fistulas, whether rectovaginal or vesicovaginal, is usually not smooth. Of four patients with vesicovaginal fistula, one died and one had a febrile convalescence. Of thirty-two patients with rectovaginal fistula, whether due to spontaneous rupture or operative accident, five died, twelve had a prolonged and febrile convalescence, and in fifteen the recovery was uneventful, though longer than normal. There are probably two factors which are influential in producing the unsatisfactory convalesccence found in patients with these complications:

(1) Fistulas usually occur in patients with severe forms of pelvic abscess.

(2) The fecal discharges in the fistula constantly reinfect the abscess and pelvic cavity.

(*a*) End-Result of Rectal Fistulas Complicating Pelvis Abscess: Rectal fistulas complicating pelvic abscess usually have a fair prognosis. Of eighteen cases, twelve, or 66⅔ per cent., healed spontaneously within three weeks. The ultimate history of six patients is unknown, except that the rectovaginal fistulas were present when they left the hospital, and that they have not returned for closure of the fistulas. In treating rectovaginal fistula, Howard A. Kelly [35] recommends the use of rectal irrigations, allowing the fluid to pass into the rectum and come out by means of the fistula through the vagina. He states that by this means the wound is kept clean, and healing is hastened. This would be recommended, however, only in case the fistula were low and had no intrapelvic connection. Should pelvic abscesses occur in patients with healed rectovaginal fistulas, there is a tendency for such recurrent pelvic abscesses to rupture into the rectum. This has been seen in two cases. This is analogous to the much more commonly observed phenomenon—the spontaneous rupture of recurrent pelvic abscesses through old healed drainage tracts in the vagina.

(*b*) Vesicovaginal Fistulas and Pelvic Abscess: Vesicovaginal fistulas are naturally not found as often with pelvic abscess as are rectovaginal. This is probably due to the shallowness of the anterior half of the pelvis as compared with the depth of the culdesac of Douglas and the tendency of inflammatory masses to gravitate toward and become adherent to the rectum. Just as proctitis and pain on defecation are frequently found in pelvic abscess, so cystitis and extremely severe bladder symptoms may be present. But the rupture of a pelvic abscess into the bladder is infrequent and occurs only in the presence of an extremely severe infection which travels around into the anteuterine spaces of Retzius and causes both ulceration of the bladder and pressure symptoms. Although we have seen three anteuterine pelvic abscesses which were opened by incisions anterior to the cervix.

in none of these cases was the bladder injured or did vesicovaginal fistula result.

We have had five cases of vesical fistula complicating pelvic abscess. In four of these the abscess opened spontaneously into the bladder, causing fistulas which opened either directly into the vagina or into the vagina through the pelvis. In these cases the diagnosis was made by the sudden appearance of quantities of pus in the catheterized bladder urine. In one of these cases there were three small openings in the bladder leading into the pelvis. In another instance, the vagina formed a common cloaca for the discharge of feces, urine and pus, the patient having both a rectovaginal and vesicovaginal fistula, both of which occurred spontaneously and closed without operation. In the fifth case a urethrovesicovaginal fistula appeared on the day on which the pelvic drains were removed.

(*c*) End-Results of Vesicovaginal Fistulas in Pelvic Abscess: Vesicovaginal fistulas complicating pelvic abscess do not show the tendency to heal that rectovaginal fistulas do. Of our five cases, only one healed without operation. As we have observed, in this instance the patient had both vesicovaginal and rectovaginal fistulas, both of which closed spontaneously after the pelvic abscess was drained.

(4) *Umbilical Sinuses in Pelvic Abscess.*—Cullen[46] has discussed this subject in detail recently. He presents numerous instances of purulent drainage from the umbilicus, usually associated with peritonitis, at times with fecal fistula, patent urachus, broad ligament abscess or appendix abscess. From the literature, he quotes seven cases of abscess originating in the broad ligament and one in the appendix which ruptured at the umbilicus. His bibliography on the subject is very extensive. Personally, I have seen only one such case; in this instance the pelvic abscess was of tuberculous origin.

(*a*) End-Results of Umbilical Fistulas in Pelvic Abscess: Umbilical fistulas seem extremely persistent, judging not only from the cases quoted by Cullen but also from the experience with the case I have had. Our patient (Gyn. No. 24848) had a pelvic abscess which was of tuberculous origin, coming on two weeks after childbirth. The abscess ruptured spontaneously at the umbilicus. At the time the patient was admitted to the hospital she had a large pelvic abscess which was discharging green pus copiously through an umbilical sinus. The abscess was opened and drained per vaginam. The patient made a good recovery and at the time she was discharged from the hospital the umbilical sinus had healed. It reopened again, however, in a very few days. Since the first admission, the patient has returned five times, and has had a total of six operations performed, the first five

46. Cullen, T. S.: The Umbilicus and Its Diseases, Philadelphia, W. B. Saunders Company, 1916.

of which were extremely conservative and without permanent result in causing the umbilical sinus to close. Vaginal incision and drainage was performed four times and abdominal drainage once in a period of seven months, and the umbilicopelvic fistula persisted in recurring. Finally, in February, 1920, a radical operation was decided upon, and laparotomy was performed. The left tube and ovary were found to be involved in a caseous tuberculous abscess; there was also a tuberculous salpingitis on the right side. There were an old drainage tract and sinus lined by tuberculous granulation tissue which extended from the old abscess in the pelvis up to the umbilicus, and from the umbilicus along the ligamentum teres to the region of the gallbladder and duodenum. The appendix was normal. Both fallopian tubes, the left ovary, the appendix and the sinus tracts were removed. Since that time, the patient has been quite well.

(5) *Lumbar and Psoas Abscess in Pelvic Abscess.*—The extraperitoneal situation of broad ligament abscesses causes them to extend widely. Such abscesses are usually of puerperal origin. If not incised and drained, they may point in the groin, in the lumbar or kidney regions and may extend over Poupart's ligament down the thighs. We have seen cases of each of these types. With the extension of the abscess into the retroperitoneal spaces or down the fascia planes of the abdominal wall or thigh, the focus of infection in the broad ligament may clear up almost entirely. In these cases, it may be extremely difficult to establish the etiology of the infection—those we have seen are almost always of puerperal origin.

In patients with abscesses of this type it is necessary to have accurate histories and searching clinical examinations supplemented by roentgenographic studies of the spine, the hips and the bony pelvis in order to eliminate distant foci which might give rise to burrowing abscesses. Unusual tumors, moreover, must also be considered. I have personally seen a definite instance in which an unusual swelling pointing in the region of Scarpa's triangle was diagnosed and incised for an abscess of pelvic origin but which at operation proved to be a large and inoperable periosteal angiosarcoma with extensive softening and destruction.[47]

Convalescence.—During the last fifteen years, the tendency in this clinic has been to shorten the convalescence and to simplify the postoperative treatment of patients with pelvic abscess. Between 1890 and 1895 it was common practice to irrigate the abscess cavity either on the operating table or on the ward. Such irrigations were carried out through rubber drainage tubes which were either left in the drainage tract after the method of Rodriguez[28] or were inserted for each

47. This patient was seen at St. Agnes' Hospital, Baltimore, in conjunction with Dr. Alexis McGlannan, 1914.

treatment. If the tubes were taken out, the cavity was packed with iodoform gauze after each irrigation. Such treatments were at times carried out daily, over periods of two or three weeks or longer.

About twenty-five years ago, we broke away from this complicated postoperative treatment, rational as it may seem. Now we do not irrigate the abscess sac nor do we repack it as a routine. We, however, do insist on the necessity of prolonged drainage and attempt to accomplish this by allowing the drains to remain in place for ten days. After they are removed, we keep the drainage tract open by digital dilation performed every day or two.

With the simplification of the methods of postoperative treatment, there has also been a marked shortening of the length of convalescence. This is shown clearly by a statement of the average number of days patients have spent in this hospital following the vaginal incision and drainage of pelvic abscess (Table 10). Whether this tendency has not been too marked in recent years will be discussed in connection with the paragraphs on the immediate and ultimate results.

TABLE 10.—TIME SPENT IN HOSPITAL FOLLOWING VAGINAL INCISION AND DRAINAGE OF PELVIC ABSCESS

Year	Average No. of Days of Convalescence in Hospital
1895	27
1896	27
1897	23
1898	22
1902	23
1914	14

(*a*) Types of Convalescence: The convalescence of patients following vaginal incision and drainage of pelvic abscess may be of several fairly distinct types. These types may be named: (1) normal convalescence; (2) convalescence with early high rise of temperature; (3) febrile convalescence, and (4) convalescence with late high rise of temperature.

(1) *Normal Convalescence.*—Under this group I have included those patients that show no high postoperative rise in the temperature and that have an afebrile course. In such cases the course which the temperature follows after operation usually varies with the temperature on admission. When the admission temperature is low, 99 to 101 F., during the first twenty-four or thirty-six hours after operation it usually rises to 101 to 102 F., remains at that point for twelve hours, falls promptly and within a week or ten days approaches normal and remains there. The pulse in these cases is correspondingly rapid, almost always running above the temperature curve. On the other

hand, if there is a marked elevation of temperature on admission, 103 to 106 F., it usually falls promptly after the operation, the pulse rising to 130 or 160. Both gradually fall after the manner just described.

This type of convalescence, called the "normal convalescence" in this paper, has been observed in 65 per cent. of all of our cases of pelvic abscess treated by vaginal incision and drainage. In patients who have this type of convalescence the immediate result obtained is usually good.

(2) *Convalescence with an Early High Rise of Temperature.*—This phrase, early high rise, is used to characterize a group of cases in which the temperature takes a sudden rise, at times of 4 or 5 degrees, within twenty-four or thirty-six hours after operation, remaining elevated for twelve or eighteen hours, then falling rapidly to 101 F., or less, and within a week or ten days reaching normal. At the time of greatest elevation, the temperature may reach 105 F., at times even higher. I have not called a postoperative elevation a high rise unless it reached 102.5 F. As in the normal convalescence, the pulse accompanies the temperature, the pulse curve usually running above the temperature. Twenty-two per cent. of our patients showed this high rise. The significance of this early and temporary high rise is not great unless it is accompanied by untoward symptoms.

(3) *Febrile Convalescence.*—I have included in this group those cases in which the temperature was continuously elevated, 100 F. or more, for over a week or ten days. Such a febrile course might have its beginning at any time during the convalescence—it might follow what started out to be a temporary high rise following the operation or it might develop late in the convalescence after the temperature had reached almost normal. In these cases, the pulse is also elevated, usually reaching from 112 to 120. We have observed this type of convalescence in 13 per cent. of our patients.

This picture is of definite clinical significance. Its importance is shown by the fact that the operation had to be repeated in one third of these patients and by the list of complications which they presented. These complications are given in Table 11.

General peritonitis, endocarditis, pericarditis, septicemia, carcinoma of the cervix, myomata uteri, perirectal abscess, acute tonsillitis, anteuterine pelvic abscess, vesical fistula caused by rupture of abscess into the bladder, bronchopneumonia—each of these complications occurred once.

In those instances in which the febrile course was due to reaccumulations or secondary abscesses, relief was obtained by repeating the vaginal operation. At times, a febrile course may be due to some surgical complications which cannot be treated by this procedure. Of

170 patients that were treated by both vaginal drainage and ·otomy, twenty-seven were subjected to abdominal operations for reason. When the febrile course starts late in convalescence after irly normal beginning, we have usually found it to be due to a :umulation in the pelvis due to the premature removal of the ıs or the failure to keep the drainage tract open. Prolonged ctant treatment of a patient with pelvic abscess who is having a inued elevation of the temperature after vaginal incision and drain- may be a dangerous procedure.

TABLE 11.—COMPLICATIONS IN CASES OF FEBRILE CONVALESCENCE

Complication	No. of Cases
Reaccumulation of pelvic abscess	18
Rectovaginal fistula, operative	6
Rectal connection with abscess, preoperative	4
Rectal connection with abscess, postoperative	1
Large size of pelvic abscess (reaching to umbilicus)	4
Pelvic peritonitis	3
Postoperative femoral phlebitis	3
Broad ligament abscess	2
Tuberculous pelvic abscess	2

(4) *Convalescence with Late High Rise of Short Duration.*—This of convalescence is seen not infrequently. It is characterized by ıgle short elevation of the temperature coming late in convalescence, r the first week without serious symptoms or with symptoms of short duration. The type is really a modification of the "early rise" type, and is usually just as easily controlled. In several ›ur cases, we have found it to be due to a local peritonitis of a l grade. In two cases this was induced as a direct result of the cture of the peritoneum or rectum by an irrigating nozzle during ;ations given on the ward. In other cases this short rise was not rly explained, being unaccompanied by any alarming symptoms.

(*b*) Convalescence of Various Types of Cases: There is a dis- t relationship between the type of infection present in the pelvic :ess and the convalescence. This is brought out most clearly in le 12.

ABLE 12.—RELATION BETWEEN TYPE OF INFECTION AND CONVALESCENCE

Type of Case	Number of Cases	Normal Convalescence, per Cent.	Febrile Convalescence, per Cent.	Early High Rise, per Cent.	Days of Convalescence
rrheal	465	65	13	22	19
peral	28	39	36	25	22
rculous	7	14	86	—	21

This table speaks for itself. The greater seriousness of puerperal tuberculous pelvic abscesses is clearly evident.

(*c*) The Relation of the Convalescence to the Method of Treatment: *The manual technic involved in performing the operation of* vaginal incision and drainage has been fairly well standardized; as a result, with a few exceptions, a uniform operative procedure has been utilized in the treatment of all of these patients. The most important variations have been with regard to irrigation of the abscess sac and the length of time during which drainage has been continued.

As has been stated, irrigation of the abscess sac as a routine procedure was discontinued in this clinic about twenty-five years ago. In very few instances has it been performed since. Rodriguez [28] and La Bonnardiere [29] were perhaps the most ardent of those who practiced irrigation, and in their hands the results obtained seemed to justify their enthusiasm. Our experience has been that the convalescence is not so distinctly affected by irrigation as its supporters claimed. Out of a total of 495 patients, eighty-eight were treated by irrigation of the abscess cavity and 407 were not. Following irrigation, in 68 per cent. of the cases, the patients had a normal convalescence; without irrigation the percentage of normal convalescence was 62 per cent. In 22 per cent., irrigation was followed by a febrile convalescence; without irrigation, this was found in only 14 per cent. During the first twenty-four hours after operation, a temporary high rise in temperature was found in 10 per cent. of the patients that had been treated by irrigation; without irrigation, in 24 per cent. This sharp but temporary postoperative elevation, unaccompanied by serious symptoms, is of slight clinical importance and seems to have had no influence on the later convalescence. The average duration of the convalescence of patients who were treated by irrigation was twenty-three days; of those not treated in that manner, eighteen. In view of these findings, it seems that irrigation, as formerly practiced in this clinic, did not yield the results expected, so far as immediate convalescence was concerned, and that any benefits or advantages which might have been gained by its routine practice were not of sufficient moment to overbalance the danger of serious accidents which at times have resulted from its use.

(*d*) The Relation of the Length of Drainage to the Convalescence: One of the most important questions in relation to the convalescence and the immediate result obtained is that of drainage. The maintenance of prolonged drainage has long been acknowledged to be the essential element in the successful treatment of pelvic abscess by the vaginal method. Laroyenne [15] emphasized this point clearly as early as 1886. It has been repeated so frequently since that time that it has become practically axiomatic.

The advantages of prolonged drainage and the poor results following insufficient drainage are clearly brought out by a study of this

series of cases. In order to present this, we have collected a series of twenty-seven consecutive cases in which there was febrile and prolonged convalescence following the vaginal incision and drainage of uncomplicated pelvic abscesses. There were no unrelated conditions in these cases which might have produced this unfavorable immediate result. In this group, the drains were removed on an average at the end of 5.8 days. In a series of eighty-eight patients with similar types of pelvic abscess, who were treated by the same operative procedure but who had normal convalescence, the drains were removed at the end of 8.2 days. Furthermore, in nineteen of the twenty-seven patients with febrile convalescence, it was necessary to repeat the operation in order to evacuate reaccumulations of pus. In only two instances out of the nineteen in which second operations were necessary, were the drains allowed to remain in place longer than eight days. It is therefore evident that the maintenance of prolonged and efficient drainage is of prime importance in the postoperative treatment of pelvic abscess.

4. *Immediate Results Obtained in Cases of Pelvic Abscess After Vaginal Incision and Drainage.*—The determination of the immediate results which were obtained in the treatment of these patients is based on their condition at the time of their departure from the hospital. The data on this subject may conveniently be brought together under three heads: (1) the temperature and pulse; (2) the findings on pelvic examination, and (3) the symptoms manifested by the patient.

The temperature charts of these patients show that almost one half of them had a slight elevation at the time they left the hospital. In 47 per cent. the temperature was above 98.6 F., in 37 per cent. the pulse rate was above 100 to the minute. This applies with equal force to patients who were treated with or without irrigation of the abscess sac.

The explanation of this persistent elevation of the temperature and pulse is found very readily in the condition of these patients as shown by pelvic examination. The data on this subject are presented clearly in Table 13.

TABLE 13.—CAUSE OF PERSISTENT ELEVATION OF TEMPERATURE

Type of Case	Number of Cases	Pelvis Clear, per Cent.	Pelvis Abnormal, per Cent.	Slight Induration, per Cent.	Much Induration, per Cent.	Masses, per Cent.	Fundus Adherent, per Cent.	Pain Present, per Cent.
All cases examined....	383	8	92	13	57	28	33	12
Without irrigation...	314	7	93	3	58	29	33	13
With irrigation.....	69	13	87	—	52	22	27	7

Examination of this table reveals that fully 90 per cent. of these patients had distinct abnormalities in the pelvis at the time they left the hospital. This is not to be wondered at. The remarkable fact is that any patient with a large pelvic abscess can leave the hospital after a

period of only three weeks without marked abnormalities. The summary given in the table shows that in 8 per cent. of our cases of pelvic abscess treated by vaginal incision and drainage, the immediate anatomic result obtained was almost ideal. As far as could be determined, in these instances there were no pelvic masses, no tenderness, no significant induration and the pelvic organs were in excellent position and freely movable. Even in these patients, however, it was not an unusual thing to notice that there was a slight elevation of the temperature at the time they were discharged from the hospital, indicating that there still remained a focus of infection which had been neither eradicated nor completely controlled.

As a rule, however, in 90 per cent. of our patients with pelvic abscess who were treated by vaginal incision and drainage, there remained definite and at times marked pelvic abnormalities at the time they left the hospital. These abnormalities usually consisted of inflammatory masses, dense induration, adherent malpositions of the uterus, inflammatory cysts of the ovaries, pelvic tenderness and a certain amount of pain. In fully half of these patients, there was also a definite elevation of the temperature at this time. It is possible that if the active postoperative treatment had been continued for five or six weeks instead of two or three, the immediate results might have been somewhat better.

When one considers the nature of the lesion and the type of the treatment received, it becomes evident that this result is all that should be expected. To him who expects more, this operation loses its chief significance. By opening up of the various abscess pockets in the pelvis, and allowing them to drain freely for a long period of time the surgeon accomplishes a two-fold immediate result: he avoids dangerous complications which are seen in untreated cases of pelvic abscess and so controls the pelvic infection that it becomes amenable to medical therapy and gives the opportunity for conservatism in surgery. When viewed in this light, we must conclude that in all these cases the immediate results were highly satisfactory, remembering at the same time that most patients who are thus treated leave the hospital with their real convalescence only begun.

5. *Ultimate Results Obtained in Cases of Pelvic Abscess Following Treatment by Vaginal Incision and Drainage.*—It is always difficult to determine the ultimate results obtained following any form of treatment in a large series of patients. Natural obstacles present themselves which in many instances are unsurmountable and prevent the assembling of complete records. These difficulties increase in proportion to the number of patients one attempts to study and the length of time which elapses after they pass from under the direct observation of the surgeon. This is particularly true in a large free clinic

which is no respecter of persons and admits all without regard to mentality, race, color or previous condition of servitude.

As a consequence, it is impossible for us to present this phase of our work with the well rounded out completeness that we had desired. We have, nevertheless, been able to follow up 143 of our patients who left the hospital either well or improved following the vaginal incision and drainage of pelvic abscesses or similar purulent pelvic collections. Although this represents only about 31 per cent. of our entire group of patients, it is a larger series than we have yet been able to find reported in the literature.

In spite of the shortcomings which always attend attempts of this nature, conclusions based on the study of a large series of patients who were suffering from the same disease, were subjected to a uniform and standardized method of surgical procedure and who have been observed for long periods of time, deserve a certain amount of consideration. Realizing that the gravest errors which creep into deductions based on incomplete data are apt to be mathematical or statistical, we have attempted to present such conclusions with due reservations. The clinical facts, however, which stand out constitute the real value of such a study and it is to this phase that we shall direct most of our efforts and attention.

The ultimate results obtained in the treatment of these 143 patients have been ascertained by two means, by the readmission of the patient to this hospital, or by correspondence and visit. Fifty-six patients with pelvic abscess who were treated by vaginal incision and drainage have been readmitted to the hospital with a recrudescence of some form of chronic pelvic inflammatory disease. Eighty-seven have answered letters with regard to their health, and at our request, some of these have returned to the hospital for examination. No patients have been considered ultimately well or improved who have not been followed for a period of at least three years. In some instances, we have been able to interview and examine patients who were operated upon twenty or twenty-five years ago. We shall consider first the group of patients who were readmitted to this hospital.

(*a*) Patients with Pelvic Abscess Who Were Readmitted to This Hospital Because of the Ultimate Failure of the Former Treatment, Fifty-Six Cases: In these fifty-six patients, as far as permanent results are concerned, the treatment resulted in failure. The phrase ultimate failure, however, as applied to the treatment of pelvic abscess by vaginal incision and drainage has a qualified meaning. When one considers that this is the most conservative of all the surgical procedures used in the treatment of this condition, that the focus of the infection is not removed at all, and that in many cases this operation is intended only as a preparation for more radical treatment at a later date, then one

can realize that failure in the sense of subsequent recurrence of the disease is not at all an unexpected outcome. The fact that only 12 per cent. of our patients thus treated have returned might with very little effort be construed to be a favorable comment on the success of this form of treatment.

In the study of pelvic abscess, it is important to know in what forms it recurs following vaginal incision and drainage. A comparative table, showing the diagnosis of the fifty-six cases at the time of the first admission and the form of recurrence at the subsequent admissions is given in Table 14.

TABLE 14.—FORM OF RECURRENCE AFTER VAGINAL INCISION AND DRAINAGE

Diagnosis at Time of First Admission	No. of Cases	Diagnosis at Time of Subsequent Admissions	No. of Cases
Pelvic abscess	43	Recurrent pelvic abscess	23
		One patient having become pregnant since the first operation and readmitted with a puerperal pelvic abscess.	
		Adhesions, intestinal, omental or pelvic, with chronic salpingitis	10
		Pyosalpinx	5
		Encysted pelvic peritonitis	4
		General peritonitis	3
		Hydrosalpinx	1
		Tubo-ovarian abscess	2
Tubo-ovarian abscess	4	Pelvic adhesions with chronic salpingitis	3
		Pelvic abscess, puerperal, following miscarriage since first admission	1
Pelvic abscess, puerperal	2	Pelvic abscess, puerperal	1
		Tubo-ovarian abscess	1
Pelvic peritonitis	2	Pelvic abscess	1
		Pyosalpinx	2
Pyosalpinx	2	Pelvic abscess	1
Encysted pelvic peritonitis	1	Pelvic abscess	1
Ovarian abscess	1	Cornual abscess with pelvic peritonitis	1
Puerperal cellulitis	1	Hydrosalpinx	
Total	56	Readmissions	61

At the time of their first admissions, these fifty-six patients presented the usual picture of cases of this sort. There were no unusual findings as regards the temperature, pulse, blood picture or general condition. The complications presented in this group were about the same as have been found in all other patients with pelvic abscess. In two instances, the abscesses had ruptured into the rectum before operation, in one into the bladder. In one patient; the rectum passed directly through the abscess, in two the abscesses were situated anteriorly to the uterus. Bilateral tubo-ovarian abscesses complicated the pelvic abscess in one instance and in another a dermoid cyst of the ovary. With regard not only to the preoperative condition, but also preopera-

tive complications and operative findings, this group of cases present nothing unusual and must be considered to be a fairly typical series of average cases.

All of these patients were treated by vaginal incision and drainage. The abscess sac was irrigated in fourteen instances. On the average, these patients stayed in the hospital nineteen days after operation, which is a normal period of convalescence.

The convalescence of these patients during their first admissions presented only one unusual characteristic, and that not very strikingly. Twenty-three per cent. had the febrile type of convalescence, which is 10 per cent. higher than was found in the average of all of our cases. Of the three patients with puerperal collections, two had normal types of convalescence, one febrile. The complications developing during the convalescence were not unusual—one case of thrombosis of the left popliteal vein, one of local pelvic peritonitis, one of intestinal obstruction—all of which were relieved.

When these patients were discharged from the hospital after their first operation, 46 per cent. had a temperature above 98.6 F.; and 34 per cent. a pulse rate above 100 per minute. This represents with remarkable accuracy the usual picture seen in most of our cases. Pelvic examination of these patients made at the time they were discharged revealed that in only 6 per cent. were the pelves normal, in 94 per cent. abnormal. Sixty per cent. had marked induration, 28 per cent. masses, 15 per cent. pain, and in 37 per cent. the fundus of the uterus was adherent. These figures, while not remarkably different from average findings, show a slightly smaller number of normal pelves and a correspondingly larger number of abnormalities than usual. Whether such a slight difference as this could have any significance is more or less problematical.

We have thus made a summary of these fifty-six cases in the effort to determine whether they were in any respect different from the cases in which the treatment resulted more fortunately. As a result, we can state that there was a tendency toward a febrile convalescence in this group, this being true of almost one fourth of these patients. The only other characteristic of this group was that at the end of their convalescence, the anatomic results of the operative treatment were not so satisfactory, for the incidence of pelvic abnormalities was slightly higher than usual.

In all these cases, the treatment received resulted in ultimate failure, though it gave immediate relief. All of these patients returned to the hospital and were again operated on for some form of chronic pelvic inflammatory disease which was causing symptoms. A glance at the list of diagnoses at the time of the first admission and the form of recurrence will show that the largest single cause of readmission was

recurrent pelvic abscess, which occurred in 51 per cent. of these patients. Of the twenty-seven patients who suffered from a recurrence of pelvic abscess, 60 per cent. were readmitted within less than a year from the time of their first operation. As a rule, these patients who were readmitted within twelve months with recurrent pelvic abscess were never completely free of symptoms for any appreciable length of time, recurring or constant abdominal pain, dysuria, dysmenorrhea and menstrual irregularity being constant features of their histories during the interim.

The eight patients who were well for more than a year present a different picture. Their average period of good health was four years, two patients being free of all symptoms for ten years, and two for six. Three of these eight patients became pregnant, the earliest pregnancy occurring two years after vaginal incision and drainage of the original pelvic abscess. In one instance, the patient became pregnant six years after her first admission to the hospital, the pregnancy ending at two months in a spontaneous miscarriage followed by a puerperal infection and pelvic abscess which caused the patient to return to the hospital for operation. In the second instance, the patient gave birth to a normal child about four years after the drainage of a pelvic abscess, the puerperium being normal. Six years later this same patient became pregnant again, the pregnancy ending after three months in a miscarriage followed by a puerperal infection and pelvic abscess. In this case, it is difficult to determine whether the puerperal infection was in any way concerned with the original infection which had occurred ten years before. The third patient became pregnant two years after a pelvic abscess had been drained, gave birth to a full-term, stillborn child and developed a serious puerperal infection. The acute symptoms of this infection were controlled without operation. Two years later, however, after a long period of invalidism, she was admitted to the hospital with an acute exacerbation and died of general peritonitis. Thus, of the four pregnancies which occurred in this series of patients between their first and second admissions, only one was carried to term without complications, one resulted in a stillborn child at the end of nine months, and two in miscarriages under three months. Three of the four pregnancies were followed by severe puerperal infections, one eventually resulting in the death of the mother.

Next to recurrent pelvic abscess, the most frequent cause for readmission of the patient was pain due to adhesions. In 25 per cent. of these fifty-six patients, this was the lesion found at the time of the second admission. Only 25 per cent. of these patients returned within one year, the average interval being between two and three years. In one half of these patients, there had been more or less constant pain since the first operation: in the remainder the symptoms due to the

adhesions did not appear until later, after intervals varying from two or three months to ten years. As a rule, however, the symptoms became so increasingly severe that at the end of two years the patient was not only willing, but anxious, to undergo laparotomy for the sake of relief.

Three patients were readmitted with general peritonitis. The convalescence of these patients following their first operation for the drainage of pelvic abscess had been very good. The temperatures of two were normal at the time they were discharged from the hospital, and in only one was the pulse rate as high as 100 per minute. Pelvic examinations made at the time they left the hospital showed that there were no masses in any case, slight tenderness in one, and no unusual induration. One of them had a rectovaginal fistula due to the rupture of the abscess into the rectum. The convalescence of these patients averaged twelve days. They were readmitted with general peritonitis at the end of two months, three months and two years, respectively, and died. The history during the intervals between the admissions was that of slight abdominal pain at times, dysmenorrhea and menstrual irregularity, but of generally improved health. In all three patients the acute symptoms were of sudden onset with short course and fatal termination.

The histories of two patients of this series of fifty-six are worth giving in detail, in view of their bearing on the question of the proper treatment of pelvic abscess and chronic pelvic inflammatory disease. In an age when conservatism is the rule of universal practice, it is well to pause to observe these two instances in which repeated and varied conservative attempts, usually at the patient's own request, were futile and finally were forced to give way to radical treatment. Very rarely does one see conservatism carried to such a degree as in these two instances.

Case 1.—A woman (Gyn. No. 635) went through a course of conservative operative therapy which extended over a period of twenty years. She was admitted to the hospital for the first time in 1891, complaining of pain in the lower abdomen. As pelvic examination under ether did not reveal enough to justify performing an operation, the patient was discharged from the hospital to be treated in the dispensary. In 1896, she was again admitted to the hospital. At this time she had a right tubo-ovarian abscess, the left fallopian tube was occluded but not acutely inflamed. The right tube and ovary were removed, the left tube was opened. A salpingotomy was performed as the patient was extremely anxious to bear children. Following this operation she was greatly improved for a few months; at the end of a year, however, she returned for the third time with a pelvic abscess which was drained per vaginam. Again in 1899 and 1901, she was operated on for pelvic abscess, each time by vaginal incision and drainage. Following the operation performed in 1901, the patient was perfectly well for ten years; at the end of that time, however, she had an acute exacerbation with abdominal pain, nausea, vomiting, chills and fever. At

this time it was found that the left tube was the seat of a pyosalpinx, and in the left ovary was an inflammatory cyst. On this occasion, a hysterectomy and left salpingo-oophorectomy were performed. Since 1911, the patient has been perfectly well.

CASE 2.—A woman (Gyn. No. 1924) was admitted to this hospital for the first time in 1892 with bilateral pyosalpinx, for which both fallopian tubes were removed. Within a year she was readmitted with a right ovarian abscess which was treated by vaginal incision and drainage. The immediate results of both of these operations were good. Six months later, however, she had an acute recurrence in the form of pelvic peritonitis which was again drained per vaginam. She was admitted to the hospital again for the fourth time one year later in 1894 with abscesses in both ovaries and both cornua of the uterus, at which time hysterectomy and bilateral oophorectomy were performed. Since 1894, this patient has been free of all symptoms. These two cases illustrate the limitations not only of vaginal incision and drainage, but also of all conservative procedures in the sugical treatment of pelvic infections.

Taken as a whole, 12 per cent. of our patients with pelvic abscess that we have treated by vaginal incision and drainage have returned to us either unimproved or with acute exacerbations of their old infections. Of these, 80 per cent. came back within two years, 58 per cent. within one year, 40 per cent. within three months, and only 20 per cent. after periods longer than two years. Most of the patients who returned within one year did so because of the recurrence of their disease in the form of pelvic abscess or peritonitis, either pelvic or general, without ever having been completely free of symptoms for any appreciable length of time. Inflammatory adhesions were usually responsible for the symptoms that caused patients to return after periods of more than one year's duration, although acute exacerbations, at times without any known cause, occasionally following miscarriages and puerperal infections, have been seen in patients who have been free of symptoms for as long as ten years.

These cases demonstrate the impossibility of rendering an accurate prognosis as to the ultimate result in any individual patient who has been treated for pelvic abscess by vaginal incision and drainage. Pregnancies in such patients are particularly liable to be followed by acute exacerbations which are usually of a serious type. It has been our practice to inform these patients of the general nature of their ailment and the treatment they have received, and to warn them of the possibility of future developments.

(*b*) Patients Heard from by Report: This group includes eighty-seven patients. The determination of the ultimate result in this series is based on observations which extend over periods of from three to twenty-five years, the information being obtained either by personal interview, physical examination or replies to letters.

The diagnosis of these cases are given in Table 15.

There were no cases of tuberculous pelvic abscess in this series.

In the treatment of these patients, vaginal incision and drainage was the only operation performed, this procedure having been used 111 times. It is evident that in not a few instances the operation was repeated while the patient was in the hospital. None of these patients were readmitted, as far as we know. In eighteen patients, the abscess sac was irrigated.

TABLE 15.—DIAGNOSIS IN EIGHTY-SEVEN CASES OF PELVIC ABSCESSES

Diagnosis	No. of Cases
Pelvic abscess, not puerperal	49
Pelvic abscess, puerperal	9
Tubo-ovarian abscess	10
Encysted peritonitis, pelvic	8
Pyosalpinx	7
Subacute pelvic inflammatory disease	2
Ovarian abscess	1
Hydrosalpinx	1

Following operations, the convalescence of these patients represents the average fairly well. Of those who were not irrigated, 70 per cent. had a normal and a febrile course, 12 per cent. febrile, and in 18 per cent. there was a high postoperative rise in the temperature during the first two days without serious significance. Of those that were irrigated, in 67 per cent. the convalescence was normal, in 22 per cent. febrile, and in 11 per cent. marked by an early high rise of the temperature. The average length of convalescence of the patients that were treated by irrigation was twenty-six days, without irrigation nineteen, of the puerperal cases thirty-five days.

At the time that these patients were discharged from the hospital, 43 per cent. of them had a temperature above 98.6 F. and in only three patients did pelvic examination fail to reveal some definitely palpable abnormality. In 23 per cent., the only lesion found at the time of discharge from the hospital was slight or moderate induration surrounding the pelvic structures, in 23 per cent. there were also definite pelvic masses. Thus, as regards diagnosis, operative treatment, convalescence and the immediate result obtained the eighty-seven patients of this group show nothing unusual, but manifest the general characteristics noted in most of our cases.

From the point of view of ultimate results, these patients have been divided into three classes, depending on whether the treatment resulted in cure, improvement or failure. In order to have some fixed standard, arbitrary interpretations have been given to these terms. By cured, we mean that the patient has been permanently relieved of symptoms and is in good health; by improved, that she still occasionally has a slight amount of abdominal pain, but is at least in fairly good health and on the whole has been much relieved. In the case of

patients who have continued to have abdominal pain, at times severe, and who are in either fair or poor health, we have judged the treatment to have been a failure. As far as the function of the pelvic organs is concerned, the criterion of a cure is the ability of the patient to bear children. But a patient who is thus functionally cured may be symptomatically miserable because of abdominal pain due to adhesions or gastro-intestinal disturbances connected with a diseased appendix which had been involved in the pelvic abscess. This actual state of affairs has been observed by us in no less than seven out of eighty-seven patients. Since our first consideration in these cases is the immediate welfare of the patient herself, we have not reported any patients as cured who have not been free of all symptoms. Although we are dealing with the question of ultimate results, it must be kept in mind that in all of these cases the immediate danger to health and life was removed, and that in that sense the operative procedure achieved the desired end. As we shall see, in a certain number of instances even greater success was realized.

Of these eighty-seven patients, thirty-five have been permanently cured, thirty-two improved and twenty not improved. To these twenty cases of failure must be added the fifty-six cases of patients that were readmitted, making a total of seventy-six failures. Thus, of 143 patients with pelvic abscess or similar purulent collections who were treated by vaginal incision and drainage, 25 per cent. have been permanently cured, 22 per cent. improved and 53 per cent. not improved. Whether this ratio would maintain itself if applied to all of our cases thus treated, can probably never be determined.

The subject matter in the subsequent pages of this section will be considered in the following manner:

(1) The relation of irrigation of the abscess sac to the ultimate results.

(2) The relation of the convalescence to the ultimate result.

(3) The length of drainage as a factor in the ultimate result.

(4) The relation of the immediate result to the ultimate result.

(5) Pregnancy following vaginal incision and drainage of pelvic abscess.

(6) Menstruation following vaginal incision and drainage of pelvic abscess.

(1) *The Relation of Irrigation of the Abscess Sac to the Ultimate Result.*—Of these 143 patients, the ultimate results of whose treatment we know, thirty-two were treated by irrigation, 111 were not. A comparison of the end-results following each of these methods of treatment is given in Table 16.

Although this is not a complete record, it apparently furnishes sufficient basis for the conclusion that in spite of the labor and time

spent in the elaborate routine of this form of treatment, irrigation did not yield any better permanent results than has the simpler technic of incision and prolonged drainage.

TABLE 16.—A COMPARISON OF END-RESULTS

Treatment	Cured, Per Cent.	Improved, Per Cent.	Failure, Per Cent.
With irrigation	19	22	59
Without irrigation	26	23	51

(2) *The Relation of the Convalescence to the Ultimate Result.*—Of those patients that had a normal convalescsence, 27 per cent. were cured permanently, 22 per cent. improved and 51 per cent. not improved. Of those that had a febrile convalescence, 20 per cent. resulted in ultimate cure and 67 per cent. in failure, 13 per cent being permanently improved. This would seem to indicate that, other things being equal, patients who experience a normal convalescence have a slightly better chance for permanent improvement than those who have febrile courses.

(3) *The Length of Drainage as a Factor in the Ultimate Result.*—In patients that were cured, the pelvic drains were allowed to remain in place on the average for 7.4 days; in patients in whom the treatment resulted in ultimate failure, 6.7 days. There does not seem to be as close a relation between the length of drainage and the ultimate result as there is between the length of drainage and the immediate result. This is probably due to the fact that the operation is permanently curative in not more than 25 per cent. of all cases. This fact, however, does not in the least detract from the value of prolonged and efficient drainage in this method of treating pelvic abscess, for in order to obtain a good immediate result, it is one of the essential requisites.

(4) *The Relation of the Immediate Result to the Ultimate Result.*—Of the patients whose treatment resulted in ultimate cure, 43 per cent. had a temperature above 98.6 F. at the time they left the hospital; of those that resulted in ultimate failure, 46 per cent. Twenty-four per cent. of the cured patients and 26 per cent. of the unimproved, respectively, had masses in the pelvis when discharged from the hospital. We have examined several of these patients from ten to twenty years after their departure from the hospital, and in some of them these masses still persist. In others they have disappeared. *It is probable that a large number of these persistent and* symptomless masses are ovarian cysts of inflammatory origin, hydrosalpinges, or similar remains of the old infection. It is a well known fact that a patient may harbor definite pathologic lesions of this sort

for years without experiencing the least discomfort or any serious impairment of health.

(5) *Pregnancy Following Vaginal Incision and Drainage of Pelvic Abscess.*—In this group of 143 patients, there are nineteen who have become pregnant since their treatment for pelvic abscess. In six of these nineteen, the pelvic infection which had given rise to the abscess was definitely puerperal in origin, in thirteen it was not. We have seen no instances of pregnancy occurring in patients following the drainage of pelvic abscess of a tuberculous nature. Of the nineteen patients who became pregnant, fifteen were successful in carrying at least one pregnancy to full term, although there were in addition not a few miscarriages in this same group.

The total number of pregnancies in these nineteen patients was fifty-two, of which thirty-four were carried to term and eighteen ended in miscarriages. The incidence of puerperal infections in patients who had been treated for pelvic abscess and who later became pregnant is not fully known. Three of the eighteen patients of this group have been readmitted to this hospital with serious puerperal infections, one dying of general peritonitis.

We have seen only one instance of subsequent pregnancy in which the treatment for pelvic abscess had resulted in failure. In that case, the pregnancy terminated in a miscarriage. In eleven of the eighteen patients, the treatment had resulted in symptomatic cure, in the case of six, in improvement. Three patients in whom the treatment had apparently resulted in complete cure remained free of all symptoms and in perfect health until they became pregnant, had miscarriages and developed puerperal infections.

From these statistics, therefore, it is evident that pregnancy is not only possible, but also not uncommon following the treatment of pelvic abscess by vaginal incision and drainage. About 13 per cent. of the patients whose subsequent course we have been able to follow have become pregnant. It seems that in cases of pelvic abscess of puerperal origin, the functional integrity of the genital organs is less often damaged irreparably than in any other type, as the incidence of pregnancy in patients after the drainage of pelvic abscesses of this origin has been about 60 per cent. On the other hand, the incidence of pregnancy in cases of gonorrheal pelvic abscess which were not of puerperal origin has been less than 10 per cent., to be exact, 9.9 per cent. That the occurrence of pregnancy in a patient who has been treated for pelvic abscess is not an altogether innocuous procedure is shown by the three cases of serious puerperal infection and one death in eighteen patients. From the point of view of vital economy, it is noteworthy that the number of normal children born to patients after they have been treated for pelvic abscess by vaginal incision and drainage is

greater than the number of deaths due to the disease when treated by this procedure. This statement is true although we have been able to obtain the subsequent histories of only one third of our patients; it is probable that the force of this comparison would be considerably enhanced if our data on this subject were complete.

(6) *Menstruation Following Vaginal Incision and Drainage of Pelvic Abscess.*—The menstrual history of eighty-eight patients following treatment for pelvic abscess by vaginal incision and drainage has been followed with sufficient accuracy to warrant reporting. In 73 per cent., the menstrual periods have been regular, in 10 per cent. irregular, in 8 per cent. menstruation ceased entirely with the development of the pelvic abscess and has never returned. Menstruation has been less painful in 56 per cent., painless in 23 per cent., and in 21 per cent. the patients have had pain of equal or greater severity than that experienced before the operation.

Particular interest attaches to the histories of the seven patients who ceased menstruation entirely after the development of pelvic abscess. The ages of these patients were 37, 34, 32, 31, 29, 20 and 19. In two instances, the abscesses were unusually large, filling the pelvis and extending up to the umbilicus. At the time these patients were discharged from the hospital, pelvic examination revealed that in five cases the fundus of the uterus was of normal size and consistency, in three the condition of the uterus was not clearly made out. Since the only operative procedure employed in these patients was vaginal incision and drainage, and since none of them have been operated on since their departure from this hospital the total cessation of menstruation probably indicates the entire destruction of the menstrual function by disease.

IV. DEATHS IN CASES OF PELVIC ABSCESS AND THE PATHOLOGY OF THE DISEASE

Deaths in Cases of Pelvic Abscess Treated by Vaginal Incision and Drainage.—There have been forty-four deaths in this series of 716 patients, a mortality of 6.1 per cent. Among these forty-four cases are found pelvic abscesses of all types—those secondary to acute and chronic salpingitis, tuberculous peritonitis, inoperable carcinoma of the uterus, infected and ruptured extra-uterine pregnancy, ruptured appendixes, infected and degenerating tumors of the pelvic organs such as gangrenous ovarian cysts and parasitic myomas of the uterus. Many of these cases shed no light whatever on the subject we are considering, but merely illustrate the possible complications that one may meet in treating cases of pelvic abscess.

The only cases which concern us are those of pelvic abscess or of similar purulent collections which develop secondarily to infections in

the fallopian tubes or as a result of puerperal infections and which have been treated by vaginal incision and drainage. In another section of this paper, I have reported 462 such cases without a fatality. I shall now present twenty-five cases of pelvic abscess in which this form of treatment was carried out but which terminated fatally, a mortality of 5.1 per cent. In discussing these deaths, I shall attempt to correlate the clinical and pathologic findings in representative cases of the various types of pelvic abscess, and on the basis of this correlation to determine, if possible, the cause of the failure.

The diagnoses of these twenty-five cases were: pelvic abscess, twenty-one, of which six were puerperal and two tuberculous; pelvic peritonitis, three, of which one was tuberculous, and hydrosalpinx, one case.

Three cases of pelvic abscess were complicated by early general peritonitis, one of pelvic peritonitis, one by intestinal obstruction and one by myomata uteri. The patient with puerperal pelvic peritonitis had also a streptococcus septicemia. The patient with hydrosalpinx presented an extreme grade of toxemia and weakness, due to the chronic infection and her own lack of physical resistance.

The fact that most of these cases represent the last stages of chronic pelvic inflammatory disease will be seen at a glance. In most instances their histories tell the story of serious infections which had been allowed to progress untreated. As a consequence, these patients were in more serious clinical condition than are the usual cases of pelvic abscess. The large percentage of tuberculous and puerperal infections in this group is striking. In six patients, the temperature was below 100 F., in fourteen between 100 and 103, in five above 103. The white blood counts usually demonstrated definite leukocytosis, ranging from 9,000 to 32,000, in only two instances being below 16,000.

All of these patients were treated by vaginal incision and drainage; in one instance this operation was repeated. Twelve of these patients were also subjected to laparotomy because of unsatisfactory convalescence following vaginal incision and drainage.

The causes of death are given in Table 17.

TABLE 17.—CAUSES OF DEATH IN CASES OF PELVIC ABSCESS TREATED BY VAGINAL INCISION AND DRAINAGE

Cause of Death	No. of Cases
General peritonitis	16
Tuberculous peritonitis	1
Generalized tuberculosis	1
Broad ligament and retroperitoneal abscess	1
Intestinal obstruction	1
Septicemia	1
Toxemia	1
Pneumonia, postoperative	2
Pulmonary embolism	1

It will be seen that some of these patients died of complications which were not amenable to surgical treatment and as such have no bearing on this discussion. Septicemia, toxemia, pneumonia and pulmonary embolism, however, are complications which seem at times unavoidable, and as a consequence, always have a place in the death list in any series of surgical cases. The patient that died of toxemia was operated on for bilateral hydrosalpinx by vaginal incision and drainage. She was not in good physical condition at the time of her operation; she had an old rectovaginal fistula, was very weak and exhausted—a woman apparently with very little resistance. She lived for thirty-nine days after the operation and died without the advent of any new complications. Blood cultures were negative. Necropsy revealed nothing but the old and practically quiescent chronic pelvic inflammatory disease with a rectovaginal fistula. The history of this patient is an illustration of the weakness and exhaustion that sometimes accompany chronic infections.

The relative seriousness of the various types of pelvic infection is made clearly evident by these statistics. Of our patients with pelvic abscess of the type usually called gonorrheal, 4.5 per cent. died; in cases of acute puerperal pelvic abscess, the mortality was 13 per cent.; in those of tuberculous origin, about 25 per cent. The figure for the death rate in cases of tuberculous pelvic abscess is probably much too high and correspondingly misleading, as in most cases of tuberculous salpingitis with pelvic abscess the nature of the infection is not realized until complications render a laparotomy necessary. It, therefore, is probable that only in the most serious cases of tuberculous pelvic abscess was the etiology of the infection recognized and that consequently the percentage of deaths is higher than it would be had we the complete data on the diagnosis. Nevertheless, because of the association of concomitant tuberculous lesions elsewhere in the body, it is evident that the mortality in cases of tuberculous pelvic abscess is much higher than it is in the more common types of this disease.

General peritonitis is the most common cause of death in pelvic abscess. Sixteen of our twenty-five deaths were due to this complication. In seven of these sixteen patients, the existence of either pelvic or general peritonitis was definitely evident at the time they were admitted to the hospital, and in these instances the infection spread rapidly after the vaginal incision and drainage of the pelvic abscess. In nine patients, peritonitis developed during the convalescence after the drainage of the pelvic abscess.

The immediate problem in the treatment of pelvic abscess is the arresting of the infection; the acute problem in diagnosis is whether the infection is so localized that by the vaginal route one can reach all its active extensions and afford them proper drainage. As applied

directly to peritonitis, the question is not only whether there is a peritonitis, but also whether the peritoneal infection is localized, is spreading, and whether it is of such a degree of virulence that it demands immediate treatment.

The diagnostic and operative problem in cases of pelvic abscess of the gonorrheal type can be most clearly presented by quoting the clinical history and the necropsy protocol of one of these cases:

CASE 3 (Gynec. No. 22164).—A large colored woman, aged 28, who showed clearly the evidence of considerable loss of weight, was admitted because of illness of two years' duration, with the history of abdominal pain, dysuria, occasional pain on defecation, usually persistent constipation with rare attacks of diarrhea, occasional attacks of nausea and vomiting which had been most marked during the last two months. There had been no disturbances of menstruation. The patient had been married for twelve years, but had never been pregnant. Until one year before admission, she had a slight leukorrhea; since then there had been none. During the last year she had several severe attacks of diarrhea, at times with traces of fresh blood in the stools. She had lost 30 pounds in weight during the last twelve months.

Physical Examination.—There was considerable abdominal pain. The temperature was 101.5 F., pulse 130, respirations 40 per minute. The leukocyte count was 9,600. The examination of the head, heart and lungs was essentially negative. The abdomen was unevenly distended by a mass, reaching from the pelvis to the level of the umbilicus, causing a greater prominence on the left than on the right side. This tumor was regular, elastic, movable and moderately tender. There was no free fluid and no muscle spasm.

Pelvic Examination: The cervix was large and high in the vaginal vault. The fundus was replaced by a hard, nodular mass, continuous with the mass just mentioned. Behind the cervix, filling the culdesac, was a cystic mass with marked induration. Before the patient was operated on, the diagnosis was pelvic abscess with myomata uteri.

On June 3, the operation was performed and by vaginal incision and drainage a pelvic abscess was evacuated, 900 c. c. of pus being obtained. On the following day her condition was good. On June 5, the patient became disoriented, her temperature still remained at 101.F., and she developed a severe but symptomless pyuria. A diagnosis of intravesical rupture of the pelvic abscess was made. A phenolsulphonephthalein test of her renal function was performed the next day, the excretion for two hours being 21 per cent. The blood pressure was 120/100 (Tycos, auscultation), the white blood count 26,000. Within twenty-four hours the patient developed the picture of general peritonitis without evidence of free abdominal fluid, the leukocyte count rose to 30,000, and on the seventh day after she had been operated on, she died.

Necropsy Findings (Necropsy No. 4718).—Anatomic Diagnosis: Chronic salpingitis, right, acute purulent salpingitis, left, ruptured into peritoneal cavity. Localized acute fibrinopurulent and organizing peritonitis; dilation of upper parts of both ureters; thrombosis left uterine vein; acute splenic tumor; cloudy swelling of viscera.

Body: The abdomen is distended and tense; a hard mass is felt in the lower part. The upper part of the peritoneal cavity is partly smooth, the lower

part is filled by a large, very tense mass in which all the lower intestines, cecum, appendix and sigmoid are included.

Pelvic Organs: The upper halves of both ureters are acutely dilated. The lower halves pass into the large mass which fills the lower abdomen and pelvis. This mass is made up of loops of ileum, cecum, appendix, sigmoid, uterus, bladder, ovaries, tubes and large cavities filled with thick fibrinopurulent pus and others filled with a clear straw colored fluid and fibrin. The loops of the intestine and other organs are bound together by fresh organizing fibrinous adhesions. The cavities are found between the loops. The bladder appears normal. The mucous membrane is slightly roughened. There are, however, three small holes which open into the pouch of Douglas. These are just to the right of the median line. Their edges are deeply injected and smooth, but not very much thickened. The bladder wall in the vicinity of these holes is thin and very fragile. These holes measure 2 mm. in diameter. They open into a small cavity which is empty. The uterus appears normal. The cervix is slightly swollen and shows a few small ulcerated areas on its surface. The right fallopian tube is thickened and is retracted downward and firmly attached to the lumen of false pelvis. The cavity of the tube is dilated and contains a small amount of dirty greenish purulent material. The walls are thick and edematous. It ends in a large mass of granulation tissue in which is a large cavity filled with clear fluid. A cystic ovary is found in this mass. The left tube is dilated. Its walls are thin and its large cavity is filled with a thick stringy green purulent material. This tube opens directly into a large cavity filled with the same material. This cavity extends downward to the left of the uterus and up high among the loops of intestines in the left and to some extent in the right side. A thin layer of peritoneum separates it from the operative drainage canal into the vagina. On the left and right sides there are several large and small cavities between the loops of the intestines which contain a clear straw colored fluid and fibrin. Both ureters open into the bladder. The left ovary is not recognized. The right ovarian vein contains a fresh thrombus. The retroperitoneal lymph glands are large, soft and deeply injected.

Rectum: Mucous membrane shows postmortem changes. The walls are thick and edematous.

In this type of pelvic abscess, the diagnostic and operative problems are clearly presented by this picture. Before operation the abdominal mass was believed to be a large myoma of the uterus, the pelvic mass an abscess. At the operation, 900 c.c. of pus was obtained by vaginal incision and drainage, the abdominal mass was not reduced completely and the impression still remained that there was probably a large uterine tumor in the midst of the inflammatory mass. At that time it was thought unwise to perform an abdominal operation because of the severe shock that would have attended it and also because the vaginal operation had been definitely successful in draining what seemed to be the main abscess. Not until the necropsy had been performed did it become clear that the entire mass was inflammatory and that only a delicate membrane separated the abscess in the abdomen from the abscess in the pelvis (Fig. 2). But with only the sense of touch to guide and knowing by experience the extreme danger attend-

ing indiscriminate exploration and having already obtained 900 c.c. of pus, the operator felt that further operative interference, either pelvic or abdominal, was contraindicated, and decided to adopt a policy of expectancy. As matters turned out, the decline was rapid, a bladder fistula developed, and the patient died.

The outlook in some cases of pelvic abscess is hopeless from the outset. In such a case as the one just described, it would be difficult to state that any form of operative interference could have altered the course. The necropsy findings in this patient give us an extreme picture of the end-result of neglected disease and consequent therapeutic failure. The salient point is that every patient with pelvic abscess who has a long and febrile convalescence after vaginal incision and drainage presents the same picture in its incipiency. Failure in the treatment of pelvic abscess of this type is usually due to just one factor—the failure to open, evacuate and give efficient drainage to every pocket of infection, whether it be a subsidiary abscess in the pelvis, a broad ligament infection, a pyosalpinx, or a spreading peritonitis. If at the first operation a well localized and encapsulated pocket in the pelvis is missed, the worst result may be only a prolonged febrile convalescence which can readily be corrected by a secondary drainage later. Failure to recognize and drain a spreading peritonitis which complicates a case of pelvic abscess, however, usually terminates far more seriously.

The existence of a pelvic abscess presupposes in most instances that there is or has been a peritonitis. In most cases, fortunately, this is localized to a part of the pelvic peritoneum and never becomes generalized. Whether the extension of the infection from the fallopian tubes to the pelvic peritoneum takes place as a result of the ooze of purulent material from the patent fimbriated extremity into the culde-sac of Douglas or whether the fallopian tube becomes occluded and the infection makes its way through the wall of the tube and by direct invasion involves the contiguous peritoneum, the result is the same—a local peritonitis and in some cases a pelvic abscess. By means of adhesions which form between the omentum, the redundant sigmoid, the pelvic viscera and the parietal peritoneum, the abscess usually becomes walled off and remains limited to the pelvis. The virulence of the infection often dies out and then there remains an encapsulated collection of old pus forming a hard mass which may persist for months and assume many of the clinical characteristics of a hard, solid pelvic tumor.

On the contrary, the abscess may not be completely walled off, small intestine may become involved, the virulence of the infection may not become attenuated and the abscess may grow. It may force its way up between coils of small bowel, between the folds of the mesentery and develop many ramifications. The adhesions which

enclose these subsidiary pockets may rupture, and general peritonitis may ensue. An abscess of this type is represented by the necropsy protocol just recorded. Fortunately, most patients come to the surgeon before this stage is reached.

The clinical symptoms which accompany the development of the disease are usually definite, although at times they may be deceiving. During the earliest stages, before the abscess has developed and while the infection is still acute, the symptoms of pelvic peritonitis are usually clear. There is marked tenderness over the lower abdomen, a certain amount of increased resistance, at times rigidity and localized muscle spasm. Examination of the upper abdomen and flanks is usually negative, except that pressure in these regions may at times elicit referred tenderness in the hypogastrium. On bimanual examination, the pelvis is found to be extremely tender, hot, feels soft and edematous, is not indurated and contains no masses. Because of the tenderness, accurate palpation can be done only under a general anesthetic, and under such conditions one finds that the pelvis is essentially negative as far as palpable abnormalities are concerned. For this reason, pelvic examinations made under ether on patients who present this stage of the disease are often less instructive than when they are made without an anesthetic.

Symptomatically, such patients usually have sharp abdominal pain which is localized in one or both lower quadrants, extreme dysuria, pain on defecation, dysmenorrhea, leukorrhea, occasionally menorrhagia, at times nausea and infrequently vomiting. The treatment of the disease at this stage is purely medical, consisting of hot vaginal douches, Fowler's position, rest in bed, regulation of the diet and of the systems of elimination.

After a week or two, the acute signs and symptoms disappear, the temperature drops, the sense of health returns and the patient usually wants to go home. The pelvic organs, however, do not return to normal so quickly, and there is usually a definite residuum of the disease left. This may consist of only a moderate degree of induration, a few adhesions or a small pyosalpinx. Such a patient may remain in almost perfect health for a year or two, with very little or no discomfort. At some time, however, there is apt to be a return of her former symptoms. Their development is usually gradual, almost never with any severe or acute gastro-intestinal disturbances, but usually with progressively increasing severity. At the end of two or three months, the patient may return to the hospital with a pelvic mass, the diagnosis of which is usually clear. In other instances, at the end of this time the symptoms may spontaneously lessen in severity, the general health may improve and except for a dull, aching pain in the lower abdomen, the patient may feel quite well. Such a patient may

harbor a well encapsulated pelvic abscess for as long as a year or more, with no acute symptoms whatever. The diagnosis of such a mass rests as much on an accurate history and a thorough understanding of the pathology of acute and chronic pelvic inflammatory disease as it does on skilful bimanual examination of the pelvic organs. This is the type of pelvic abscess which is excusably confused with solid tumors of the ovary, papillocysto-adenomas, degenerating myomas, old extra-uterine pregnancy, corpus luteum cysts and malignant pelvic tumors. And it is in such instances as this that by means of a vaginal incision one may either drain the abscess or establish the correct diagnosis and thus determine the proper operative indications.

From this pathologic résumé, it is evident that there is or has been a certain amount of peritoneal involvement at some time in practically all cases of pelvic abscess, whether during the stage of the acute gonorrheal salpingitis or later during the chronic stages, as a localized peritonitis well walled off to form a pelvic abscess, a recurrent pelvic peritonitis due to an acute exacerbation of the chronic infection, or to a rupture of the abscess wall. It is also equally true that in any of the various stages of the development of a pelvic abscess, the peritoneal cavity may become acutely and seriously involved. The clinical significance of each of these various forms of peritoneal involvement, moreover, is different, and carries its own therapeutic indications. It might be just as unwise to operate on a patient with an acute pelvic peritonitis in the presence of an acute gonorrheal salpingitis as it would be to postpone operating on a patient with a spreading peritonitis due to a pelvic abscess, and it is here that the diagnostic problem lies.

Returning to our own sixteen patients who died of peritonitis, we find that seven of them had either outspoken or very suggestive signs of peritoneal involvement when they were admitted to the hospital and that in nine patients peritonitis developed after the pelvic abscess had been drained. Considering first the group of patients who had symptoms of peritonitis on admission, we find that in all these instances, the pelvic abscess was treated by vaginal incision and drainage and the peritonitis was treated expectantly. In some cases the trauma of the manipulations and operative procedures seemed to give new life to the peritoneal infection. In such instances the course was usually short in spite of laparotomies which were performed later. Other patients lingered for ten days or more with continuous fever, the symptoms not alleviated, the general condition not improving. Here also, further surgical intervention proved to be of no avail.

Nine patients did not have peritonitis when they were admitted to the hospital but developed it after the drainage of the pelvic abscess. In two instances the onset of peritonitis seemed to be due to the irrigation of the abscess sac. Fortunately this practice was discontinued in

1902. In other patients, peritonitis developed within two or three days after the vaginal drainage of the abscess, suggesting that the manipulations incidental to the ether examination and the operation had disseminated the infection. In a few instances, it was not until after the end of the first week of convalescence that the signs of peritonitis became evident.

There is a marked difference between the significance of peritonitis in a patient with a pelvic abscess and in a patient with an acute salpingitis. In the one case it means that the infection, once localized, has broken through the defensive barriers and is beginning to spread; in the other, it occurs because the infection is in its earliest stage and has not yet been walled off. In a spreading peritonitis in connection with a pelvic abscess, the organism is usually a secondary invader of a fairly virulent nature; in early salpingitis, the gonococcus can often be demonstrated. Patients with pelvic abscess are not usually in as good condition as they were in the earliest stages of the disease, for continued illness and a chronic infection has weakened their resistance and lessened their ability to withstand peritonitis. Experience, moreover, has shown that in a patient already suffering with a pelvic abscess, early laparotomy is the indicated procedure as soon as the diagnosis of spreading peritonitis is made; and it has demonstrated with equal clearance that in most instances the acute pelvic peritonitis found in connection with acute salpingitis will resolve or become localized under medical treatment.

For this reason, the diagnosis of peritonitis in cases of pelvic abscess is highly important, although often extremely difficult. There is almost always a certain amount of abdominal tenderness around a pelvic abscess and not infrequently resistance and some muscle spasm over the mass itself. But the symptoms which are usually absent in uncomplicated cases of pelvic abscess and very rarely found in any localized forms of chronic pelvic inflammatory disease are nausea and vomiting.

The proper significance of nausea and vomiting can be most clearly observed in the group of patients that were treated by both vaginal incision and drainage and laparotomy at the same time. We have had thirty-one such patients who had nausea and vomiting before operation. In seventeen of these thirty-one, there was either general peritonitis, spreading pelvic peritonitis, intestinal obstruction or some condition complicating the pelvic abscess which distinctly indicated laparotomy. The significance of nausea and vomiting is made more striking yet when we consider that these symptoms were present in only 9 per cent. of our cases of pelvic abscess and in 7 per cent. of our cases of pyosalpinx when uncomplicated by peritonitis; when these conditions were complicated by peritonitis, however, the frequency of

nausea and vomiting rose to 78 per cent. In a patient with chronic pelvic inflammatory disease which has become localized in the form of a purulent pelvic collection, the onset of nausea and vomiting should put one on his guard to use every clinical means to determine the cause of these symptoms and their proper significance.

Peritonitis, however, is not the only serious complication which must be borne in mind in the case of patients who do not react well after vaginal incision and drainage of pelvic abscess. In addition to the usual causes of unsatisfactory and febrile convalescence which have already been enumerated, there is one complication which arises not infrequently and, if not recognized, usually leads to serious results. Lateral extension of the pelvic infection into the broad ligaments and up under the lateral pelvic peritoneum may occur in any type of pelvic abscess that is associated with parametritis or cellulitis and is particularly common in pelvic infections of puerperal origin. Such collections may form also in the infundibulopelvic ligaments and in some instances be situated so high up in the pelvis that their diagnosis may be extremely difficult.

The clinical history and postmortem findings in infections of this type are well represented by the following case:

Case 4 (Gynec. No. 20187).—The patient was admitted to the ward with a puerperal pelvic abscess, the abortion having taken place one month before, during the third month of pregnancy. There was no peritonitis at the time she was admitted to the hospital, the temperature was 104 F., the pulse 144. A large fluctuant abscess filled the pelvis. This was evacuated successfully and without accident by vaginal incision and drainage. The convalescence, however, was unsatisfactory, the temperature remaining at 104 F., accompanied with a pulse rate around 140. On the fifth day, nausea and vomiting developed. Pelvic examination revealed that there was a tender mass in the left fornix. An exploratory laparotomy performed under procain revealed a perfectly normal peritoneum. The abdomen was drained, nevertheless. During the first week after this operation, phlebitis appeared in the left leg. Two weeks later, after an extremely febrile course, the patient died.

Necropsy Findings (Necropsy No. 4218).—These were so characteristic of this type of infection in this patient that they will be quoted in detail, with a few omissions.

Anatomic Diagnosis: Pelvic abscess of the posterior culdesac, with perforation into the rectum; abscess of the left broad ligament with extension to the extraperitoneal tissues; early adhesive pelvic peritonitis. Thrombosis of the left femoral vein and its branches. Edema of the lungs with pulmonary thrombi.

Body: On entering the abdominal cavity, we find that it contains a small amount of clear, straw colored fluid. The omentum, appendix, lower portion of cecum and the lower coils of the ileum, sigmoid, rectum, uterus, right tube, ovary and bladder are involved in delicate connective tissue adhesions. The peritoneum of the left broad ligament is raised to form two or three cysts filled with clear serum. The posterior culdesac is filled with thick creamy pus. The abscess cavity communicated with the rectum and also with the vagina. A

second abscess has taken its origin in the left broad ligament; involving the ovary and tube, it extends outward and upward along the psoas sheath as far as the kidney, and down below Poupart's ligament into Scarpa's triangle and anteriorly between the abdominal muscles and the skin. Posteriorly it has extended along the inner surface of the innominate bone, around the posterior edge of the same and out into the buttocks below the gluteal muscles. The left femoral vein and its branches are plugged with dry, granular, laminated, friable, white and antemortem thrombi.

The bladder is large and distended with clear urine; the mucous membrane is pink. The vagina, uterus, right tube and ovary present nothing.

This case of pelvic abscess represents a type the characteristics of which are different from those of nonpuerperal origin. In the one the infection has its chief focus usually in the fallopian tubes and its usual extension is into the pelvic or abdominal cavity. In the puerperal pelvic abscess, however, the extraperitoneal extension of the abscess is often a prominent feature, forming abscesses in the broad ligaments which may travel along fascia planes into the thigh, along the anterior, lateral or posterior abdominal wall, pointing eventually in the groin, Scarpa's triangle, Petit's triangle, the superior lumbar triangle or rarely at the umbilicus. I have described such cases in another section of the paper, and here would only point to the necessity of recognizing the characteristics of this type of infection.

The last four cases of this list of fatalities introduce a new problem: the ultimate result in patients with pelvic abscess that have apparently been treated with success by vaginal incision and drainage. These four patients (Gynec. Nos. 18630, 18199, 16644, 14858) had been operated on in this hospital for pelvic abscess, the treatment having been vaginal incision and drainage. Their convalescence had been normal, and when they were discharged from the hospital, pelvic examination had revealed nothing unusual.

One of these patients was readmitted to this hospital at the end of four years. During this time she had become pregnant and had given birth to a full-term, stillborn child. Following this, she developed a puerperal infection, was readmitted to the hospital and died of puerperal peritonitis. The only symptom which she manifested between the time of her first operation and the birth of her child had been occasional dysuria. Another patient was readmitted at the end of two years with general peritonitis; during this time she had been quite free of all symptoms until the acute exacerbation of the infection. The third and fourth patients remained in fair health for three and five months, respectively; at the end of these periods, they were readmitted with general peritonitis and died. During these months they had complained of dysmenorrhea, irregular and profuse menstruation and occasional attacks of abdominal pain.

These four cases illustrate the urgent necessity of keeping under continued observation patients with pelvic abscess who have been treated by vaginal incision and drainage and demonstrate clearly the limitations of the operation in the treatment of these conditions. Just as a patient with chronic appendicitis is always subject to the danger of an acute exacerbation, so a patient who has been treated for pelvic abscess by vaginal incision and drainage is always liable to have a recurrence of the manifestations of the infection, at times in fulminating form, and for this reason should always be kept under observation.

This concludes the study of the cases of pelvic abscess in patients who died after having been treated by vaginal incision and drainage. The nature of the disease and the gravity of the complications that attend it mark it as one of the most serious of gynecologic disorders. In spite of every form of treatment, complications such as septicemia, generalized tuberculosis, pulmonary embolism and pneumonia make the outlook hopeless in a certain number of cases. General peritonitis, however, is the most frequent cause of death in this disease; in fact, in importance, it outweighs all the others combined. Guided by an intimate knowledge of the pathology of the disease and knowing the clinical significance of its various manifestations, the experienced surgeon can conduct the treatment of his patient with the minimum of operative mutilation and the maximum of surgical safety. Without the knowledge of these principles, however, or without the patience to carry them into effect, he is liable to subject his patient to needless risk and unnecessarily radical surgical procedures. There is probably no form of gynecologic disorder the treatment of which makes a greater demand on the exercise of clinical judgment and continued observation than does pelvic inflammatory disease and its manifold manifestations.

V. GENERAL SUMMARY AND CONCLUSIONS

Historical.—The history of the treatment of pelvic abscess reproduces almost every phase of the development of gynecology. Although there are records extant of operations which were performed for the cure of this condition as early as 1840, it was not until about 1880 that there are records extant of operations which were performed for the known. The various steps which mark the progress in the development of the operative treatment of pelvic abscess are indissolubly linked with the names of men who, in their day, were the commanding figures in the surgical and gynecologic world: Récamier [4] (1820-1840); Marion Sims [5] (1845); Nélaton [10] (1860); Eugène Koeberlé [20] (1862); Lawson Tait [22] (1868); Thomas Addis Emmett [11] (1879); Hegar [36]

(1880); Laroyenne[14] (1880); Goullioud[16] (1891); Péan[23] (1890); Segond[24] (1890); Sänger[26] (1890), and others.

Diagnosis.—The diagnosis of a typical case of pelvic abscess presents but few difficulties. The clinical history and physical findings are usually characteristic. Atypical cases, however, are common and are frequently mistaken for solid and cystic tumors of the pelvic organs.

Classification.—There are many possible ways in which a pelvic abscess may originate. In the presence of infection it may be due to the degeneration of pelvic tumors, either benign or malignant, ruptured extra-uterine pregnancy, ruptured appendixes, and the rupture of cystic ovarian tumors. Those which are primarily due to infection in the female genital organs constitute by far the largest group and are our chief concern in this work. These may be brought together under three clinical types: gonorrheal, puerperal and tuberculous. The classification of cases of pelvic abscess on the basis of the bacteriologic findings is usually unsatisfactory because in many instances the organism which originally caused the infection has disappeared and sterile pus is obtained, while in others secondary invaders have completely masked the picture. In these cases, it is therefore often impossible by means of bacteriologic examinations to establish the true etiology of the infection. Finding, however, that on the basis of clinical characteristics these cases usually fall into three groups, for practical purposes we have adopted this means as the basis of our differentiation. Although this method of classification presents the usual clinical inaccuracies, yet in many instances it corresponds to the bacteriologic findings when they are positive. When viewed from the standpoint of clinical characteristics, these types are fairly distinct—in the history of the development of the disease, its localization, its complications, the postoperative convalescence, the relative mortality, the immediate and ultimate results obtained, and the frequency of the occurrence of subsequent pregnancies. With regard to diagnosis, tuberculous pelvic abscess forms an exception to the rule. Its nature is not usually recognized before operation.

Complications.—The complications, which often accompany pelvic abscess and which may develop unexpectedly during the convalescence in any case, markedly increase the inherent gravity of the disease. Not infrequently the symptoms of these complications may be almost completely masked by the greater prominence of those due to the pelvic abscess.

Operative Treatment.—In 67 per cent. of all of our patients with pelvic abscess, vaginal incision and drainage has been the only operative treatment employed.

Operative Accidents.—The nature of this operative procedure and the propinquity of the pelvic abscess to the pelvic viscera make the

occurrence of operative accidents an easy possibility. Because of these anatomic relationships, pelvic abscesses may also rupture spontaneously into the bladder, the rectum, the vagina, the peritoneal cavity, or may burrow out into the retroperitoneal spaces and travel extensively. Operative or spontaneous rupture into the bladder or rectum leads to the formation of fistulas which greatly prolong the convalescence. In this article the histories of such fistulas have been studied in detail.

Convalescence.—The convalescence of patients with pelvic abscess who have been treated by vaginal incision and drainage requires the greatest surveillance, as complications of a serious nature are common and require prompt treatment. The essential factors in the routine postoperative care are Fowler's position and prolonged drainage. The pelvic drains should not be removed for at least ten days. After they have been removed, the drainage tract should be dilated digitally every day or two to preserve its patency. Irrigation of the abscess sac we condemn. The convalescence of patients with abscesses of puerperal or tuberculous origin is usually much more stormy, prolonged and febrile than that of any other type. In all cases of pelvic abscess general hygienic measures should be employed to build up the strength of the patient.

Mortality.—In all of our cases of pelvic abscess without differentiation of the various types, the mortality following treatment by vaginal incision and drainage has been 5.1 per cent. In the gonorrheal type, the mortality has been 4.5 per cent; in the puerperal type, 13 per cent; in those which were tuberculous, about 25 per cent. It is rather difficult to obtain accurate statistics with regard to the mortality in cases of tuberculous pelvic abscess, because it is probable that in many cases in which laparotomy was not performed, the real nature of the infection was not recognized. The most frequent cause of death has been general peritonitis.

Immediate Results.—The average length of convalescence of patients with pelvic abscess treated by vaginal incision and drainage has been from two to three weeks. Although at the end of this time, 88 per cent. of our patients left the hospital free of symptoms, it would be impossible to state that they were therefore free of the disease; for in 92 per cent. of them pelvic abnormalities were palpable, in 47 per cent. the temperature was above 98.6 F., and in 37 per cent. the pulse rate was more than 100 per minute. Practical conditions which are quite beyond the control of the clinician often make it impossible to keep these patients in the hospital as long as is advisable. It is probable that the immediate results would have been distinctly better had the convalescence of these patients been somewhat longer than it was. In practically all these cases, however, the most important result

which was desired was obtained in that the progress of a serious infection was arrested, the development of grave complications was avoided, good health was at least temporarily restored, and in practically all instances the acute symptoms were entirely relieved.

Late After-Treatment.—It should be a routine procedure in patients with pelvic abscess who have been treated by vaginal incision and drainage to follow up the hospital treatment by active therapy in the office or dispensary. Such patients leave the hospital with their real convalescence only begun. Although the pelvic collections which were present may have been drained and the acute symptoms relieved, the infection which they have harbored for months and at times years and of which the abscess was only an acute manifestation, is still present and may at any time flare up in fulminating form. In some instances, two or three months of active office treatment with visits once a week are necessary before the infection seems to be perfectly controlled, the symptoms entirely relieved, and good health restored. In three fourths of our cases, this end has never been achieved permanently without the extirpation of the focus of the infection by an abdominal operation. In deciding the question as to when one should advise a second operation of a more radical nature, the personal equation often is a large factor. The persistence of definite symptoms, the continuation of poor health, and the presence of pelvic abnormalties which will not yield to medical treatment should be the clinical indications to guide one in giving advice on this question.

Ultimate Results.—Twenty-five per cent. of our patients with pelvic abscess have apparently been permanently cured by vaginal incision and drainage. These patients have been relieved of all symptoms and have been in perfect health for periods of from three to twenty-five years. Twenty-two per cent. have been improved permanently, and in 56 per cent. this treatment has resulted in ultimate failure in that these patients have not been permanently relieved of their symptoms.

Prognosis.—It is not possible to give an accurate prognosis in individual cases of pelvic abscess after this method of treatment. Although the prospect of obtaining a permanently good result is better in a patient in whom the immediate result has been good, the frequency of unexpected and acute exacerbations, puerperal infections, and persistent pain due to adhesions, make it impossible to make an accurate forecast in individual cases.

Subsequent Pregnancies.—The functional integrity of the pelvic organs as shown by the ability of the patient to become pregnant and give birth to normal children is not always destroyed by a pelvic abscess, although in 87 per cent. of our cases permanent sterility has resulted. It is difficult to see how the vaginal incision and drainage of a pelvic abscess could be any factor in inducing this sterility. About

13 per cent. of our patients have developed subsequent pregnancies after having been treated for pelvic abscess by vaginal incision and drainage. The ability of a patient to become pregnant, however, is not always an indication that she has been symptomatically cured; for in no small number of instances women who have become pregnant after their recovery from pelvic abscess have been symptomatically miserable because of the discomfort and the gastro-intestinal disturbances associated with inflammatory adhesions, chronic appendicitis, or other sequelae of chronic pelvic inflammatory disease. Although a woman in such a condition may occasionally become pregnant, we have never seen a pregnancy carried successfully to term by a patient in whom the treatment for pelvic abscess had failed symptomatically. I know of no cases of subsequent pregnancy in patients with tuberculous pelvic abscess. Forty per cent. of all the subsequent pregnancies which occurred in women who had been treated for pelvic abscess by vaginal incision and drainage ended in miscarriage, and the incidence of puerperal infections under these circumstances is high. The number of normal children born to patients who have been treated for pelvic abscess by vaginal incision and drainage is considerably greater than the number of deaths due to the disease when treated by this procedure.

Menstruation.—After having been treated for pelvic abscess by vaginal incision and drainage, 23 per cent. of our patients have had no dysmenorrhea whatever, in 56 per cent. it has been less severe, and in 21 per cent. it has been of equal or greater severity than that experienced before the operation. Eight per cent. of our patients ceased menstruating entirely after the development of pelvic abscess. Because of the fact that these patients were young women who had not been subjected to any radical surgical procedure, this cessation of menstruation seems to indicate the total destruction of the menstrual function by disease.

The Rôle of Vaginal Incision and Drainage in the Operative Treatment of Pelvic Abscess.—This operation was first presented as a uniformly curative procedure. In the hope of accomplishing this end, gynecologists of the old school devised complicated procedures and instituted elaborate courses of treatment which involved no small amount of labor, months of hospital treatment, and in some instances a very definite element of risk. This view was based on a misconception of the pathology of the disease which in turn was due to the fact that men had evolved their theories before they had seen the actual lesions of the disease. It was the boldness of Lawson Tait [22] which enabled men to see for the first time with the naked eye the varied manifestations of salpingitis, and from that day the pathology and treatment of pelvic infections began to be placed on a scientific basis.

With the development of pathology, the ultraradical surgical procedures which formerly had been employed in the treatment of pelvic inflammatory disease began to be displaced by more conservative measures. In the treatment of pelvic abscess, the marsupializations and panhysterectomies of Lawson Tait and Péan began to give way to the more conservative methods of Laroyenne and Goullioud. This tendency toward conservatism has taken such a firm hold that today it is almost the guiding principle in the surgical treatment of pelvic infections.

Of all the surgical procedures which are employed in the treatment of pelvic inflammatory disease, the vaginal incision and drainage of pelvic abscess is the most conservative. On the basis of the data which I have collected in this paper, I have attempted to define its sphere of application and to determine the part it should play in the treatment of pelvic infections.

From 1890 until 1895, the technic which was employed in performing this operation in this clinic was in general like that of Laroyenne. Since 1895, this procedure has been simplified and the operation as it is performed now is described in another section of this paper. With regard to comparative results that have been obtained following these two different methods of treatment—the older method of Laroyenne with the drainage tube and daily irrigations or the use of simple gauze drainage without irrigations—it is sufficient to state that both the immediate and ultimate results have been as satisfactory in patients who have been treated by the simpler and safer method as they were by the procedures formerly in vogue, but that in neither case have they fulfilled the hopes of those who developed these operative procedures.

On the basis of this study of 462 cases of pelvic abscess that were treated by vaginal incision and drainage, it seems that this operative procedure has two distinct functions: (1) as a method of pelvic diagnosis; (2) as a method of treatment. In the presence of pelvic tumors of uncertain origin, a vaginal incision will often establish the diagnosis and place the operative indications on a rational basis. As a therapeutic procedure in pelvic abscess, it has been most uniformly successful in giving drainage to pelvic collections, checking the spread of the infection, and relieving the patient of her immediate symptoms and the danger of complications. This much can almost always be accomplished by this procedure. In 25 per cent. of all of our patients, this relief has proved to be lasting, as in these instances they have been permanently relieved of all symptoms, have enjoyed perfect health, and in some instances have even given birth to normal children afterward. In 75 per cent. of our patients, however, this relief has been only temporary, and of these a large number have returned to

this hospital for operative treatment of a more radical nature which would offer greater assurances of permanent relief. In these cases, the previous drainage of the pelvic abscess has rendered it both safer and easier to perform operations of a conservative nature.

From this summary it is not difficult to determine the proper rôle of this operative procedure in the treatment of pelvic abscess and the purulent forms of pelvic inflammatory disease. As a measure of expediency, it undoubtedly saves life and makes it possible to avoid many a hazardous abdominal operation under extremely unfavorable circumstances. As a conservative surgical procedure in itself, its use has resulted in permanent relief in 25 per cent. of all cases, and for this reason, if for no other, should always be tried in every case of pelvic abscess that is amenable to this form of treatment. In the majority of instances, however, it has proved to be but the first step in the safest and most conservative method of obtaining permanently good results in the treatment of patients with pelvic abscess. In view of our findings in this series of observations, we are compelled to admit that as a curative procedure vaginal incision and drainage is in the majority of instances a failure, but when considered and used as a measure of expediency to be followed when necessary by the employment of more radical procedures, it has a definitely indicated use and fulfills an important function in the conservative operative treatment of pelvic abscess and the purulent forms of chronic pelvic inflammatory disease.

THE GYNECOLOGIC SIGNIFICANCE OF APPENDICITIS IN EARLY LIFE

WILLIAM P. GRAVES, M.D.
BOSTON

An article dealing with the relationship between appendicitis and pelvic disease may seem like a profitless reversion to ancient gynecologic history; nevertheless, in the consideration of even so well-worn a subject as this, fresh experience adds new points of view, and the recording of such experience cannot be without some value.

Fifteen and twenty years ago, the output of literature relating to the appendix and the female pelvis was colossal. It was, however, devoted mainly to the discussion, at that time absorbingly important, of the routine removal of the appendix during gynecologic operations, Overwhelming evidence was produced showing not only that the appendix is frequently involved secondarily in pelvic inflammatory disease, but that unsuspected inflammations of the appendix, often unrecognizable by gross inspection, may occur entirely independently of pelvic lesions. Many writers, such as Fraenkel, Pollak and Bandler, recognized also the possibility of an inflammatory process traveling from the appendix as a primary focus to the pelvic organs. This aspect of the discussion, however, played only a minor rôle. Some even denied the existence of pelvic inflammation as the result of appendicitis; others regarded it as being so infrequent as to be of little practical significance. Thus, Hunter Robb as late as 1905 in an article read before the American Gynecological Society failed to "find in 1,000 laparotomies that the appendix had been the primary seat of the disease (pelvic inflammation)." Child, in the most important contribution on the subject in recent years (1919), makes the following statement: "Where the primary infection is in the appendix, it is unusual to observe any very extensive pathologic changes in the pelvic organs; a few restricting adhesions that aside from the subjective symptoms they may cause by restricting the mobility of these organs are of little moment, seldom if ever causing permanent tissue changes to be observed."

The campaign carried on for the routine removal of the appendix during pelvic operations was rapidly won, through the influence chiefly of American surgeons under the leadership of such intrepid operators as Deaver, Kelly, Peterson and others, so that by the year 1905 the routine removal of the appendix, whether diseased or not, became. excepting for special contraindications, a well-nigh universal custom.

With this question settled, the topic of the interrelationship between the appendix and the pelvic organs lost its interest, so that within the last fifteen years, the literature has been much less voluminous.

It is the object of this article to review the subject with especial reference to that neglected aspect of it which is represented by the descending infections from the appendix as a primary focus. My attention has many times been drawn to this condition by encountering extensive adhesions in the pelves of women who had suffered from early appendicitis and in whom the chance of a gonorrheal or a puerperal infection could by all possible moral certainty be excluded. The idea of writing an article on the subject has been stimulated by several recent conversations with experienced surgeons, some of whom, to my surprise, have either expressed an entire ignorance of the condition or characterized it as of small importance.

MEANS OF COMMUNICATION OF INFECTION

In order to clarify the special points which I wish to make, it is necessary to review the commonly accepted theories regarding the means of communication by which infection may pass between the appendix and the uterine adnexa. In the earlier literature, the so-called appendiculo-ovarian ligament, or ligament of Clado, was regarded as the chief medium of infectious communication. This structure was described by Clado as a peritoneal fold of the posterior abdominal wall, more or less definitely marked, springing from the infundibulopelvic ligament, and passing upward to the cecal fossa to a termination at the base of the appendix. It was said to contain the spermatic vein and artery, the spermatic nerves, and numerous lymph vessels from the right ovary and the uterine body. Great clinical importance was assigned to this ligament by such early writers as Broschke, Weldeyer, Nagel, A. Martin and Doederlein; but in the light of later observations less significance was attached to it. Barnsby (1898) was unable to find it in 127 necropsies; Füth in the same year could identify it only exceptionally. Other investigators, both surgeons and anatomists, found it inconstant. Moreover, experimentation by injecting the blood and lymph vessels failed to substantiate the claim of Clado of a specific vascular and lymphatic connection between the appendix and ovary. In 1902, I published a short article demonstrating the appendiculo-ovarian ligament in a fetus of 5 months, but in the course of a long surgical practice it has been encountered as a well-defined ligament comparatively rarely. I am inclined to regard the structure as a fetal rest, possibly a relic of the upper portion of the mesorchium,[1]

1. This is denied by Professor Fawcett (Bristol).

or it may even be merely an accidental prolongation of the infundibulo-pelvic ligament (Paterson). We are justified in concluding, therefore, that Clado's ligament exerts at the most only an incidental influence in conducting infection to or from the pelvis.

The various methods of infectious communication have been thus described: intraperitoneally, (1) by the blood and lymph vessels of Clado's ligament; (2) through the new vessels formed in adhesions to the appendix or adnexa, or (3) along the adherent intestine, or (4) by direct contact of the appendix and adnexa: extraperitoneally (1) through the subserous cellular tissue of Clado's ligament, or (2) through that portion of the general pelvic cellular tissue which extends from the parametrium and broad ligament to the paracecum. An additional method, rarely mentioned by the earlier writers, is the descent by gravity of products of inflammation from the appendix into the pelvis. In considering these various methods, those relating to Clado's ligament may safely be disregarded. Those relating to extension through preformed adhesions may also be discarded for this immediately begs the question of how the adhesions were originally formed. We have left for consideration then the methods of communication represented by contact, gravity and extension through the subperitoneal cellular tissue. A phlegmonous infection involving the cellular tissue from the paracecum to the parametrium is quite possible. Authentic cases have been reported of parametritis following acute appendicitis during pregnancy. It is conceivable that the pelvic abscesses that occasionally appear after an operation for acute appendicitis, may have originated by extension through the cellular tissue, though it is probable, as Hermes has pointed out, that in the great majority of cases the infection extends intraperitoneally, that is to say, by gravity or contact. Higgins (in 1913) described in a male child of 3½ years an extensive cellulitis starting from an acute appendicitis and terminating in a perforating pararectal abscess. I have not been able to find authentic evidence of a distal secondary infection of the appendix from an initial parametritis. In other words, when an associated inflammatory process between appendix and adnexa does occur through the cellular tissue, its progress appears to have been *descending* rather than *ascending*. It is, of course, possible that when a severe sactosalpingitis has invaded the pelvic cellular tissue, the deep cellulitis may extend as far as the appendix and cecum, especially if they have a low attachment. In my experience, the high involvement of the cellular tissue is far more common on the left side, often with serious implication, and even obstruction of the sigmoid.

Thus we are forced to conclude that, whereas a primarily affected appendix may transmit its infectious process to the pelvis in three

different ways, that is, by contact, gravity and through the agency of the subperitoneal cellular tissue, inflammations of the pelvic organs involve the appendix secondarily only by contact. And this statement applies whether we are dealing with gonorrheal salpingitis, puerperal peritonitis or with neoplastic tumors of the uterus and its adnexa. It is pertinent probably for the most part to genital tuberculosis.

Such a conclusion reached more or less by reasoning is substantiated by personal experience, for excepting in cases in which the appendix is actually implicated in the adherent mass of a pelvic inflammation or is attached to a pelvic tumor in the manner of any mobile organ of the peritoneal cavity, I have never observed that the appendix exhibits a much greater tendency to disease than is apparent in association with noninflammatory pelvic conditions.

It is to be noted that appendicitis secondary to inflammation of the adnexa, unless the implicating process is very destructive, is of the nature of a periappendicitis. It is also probable that an appendix involved in adhesions is more susceptible to infection and ulceration of its mucous membrane, so that, theoretically at least, an essential idiopathic appendicitis may result indirectly from pelvic disease. Such an appendix may return the compliment and reinfect the originally offending organ with disastrous results. An example of this kind of interchange may be seen in cases of purulent ovarian cystomas, the contents of which have been inoculated by an adherent perforating appendix. Intestinal reinfections are, however, not confined to the appendix for they may, of course, proceed from any loop of adherent bowel, and indeed are very common in secondary sigmoiditis.

On the other hand, infectious processes transmitted to the pelvis from a primary appendicitis by gravity or contiguity are essentially peritonitic in character, so that a secondary salpingitis, for example, would ordinarily be of the nature of a perisalpingitis. On account of the open ostium of the tube, however, it seems evident that when the adnexa are swimming in the pus of an appendicular pelvic abscess, the lumen of the tube may be invaded, and a typical sactosalpinx may result (Bandler). McNaughton-Jones reports two such cases in unmatured girls, aged 10 and 11 years, respectively.

Although we have shown that a descending infection from the appendix to the pelvis is more readily effected than an ascending infection from the tube, it must not be inferred that when both organs are involved the appendicitis is more commonly primary. In fact, quite the reverse is true. Acute pelvic inflammation from all causes is more frequent than acute exudative appendicitis. When one takes into account the fact that in 25 per cent. of all women the appendix lies in the pelvis (Kelly), the chances of a secondary involvement of the

appendix are very great even though we eliminate all the theoretical methods of infectious access excepting that of contiguity. It is obvious that in many cases of appendiculosalpingitis, it is impossible to make a definite diagnosis as to the primary seat of infection, even by the microscope, and for that reason it would be difficult to secure trustworthy comparative figures. Although such a comparison, if it could accurately be made, would show a great preponderance of ascending infections, it would also reveal the fact that pelvic adhesive peritonitis as a result of primary appendicitis is much more frequent than is commonly supposed. It is necessary to protest against the teaching that nontuberculous inflammatory processes encountered in the pelvic organs are practically all due to gonorrhea or puerperal sepsis.

There is no doubt that the secondary pelvic inflammations are more common and more serious when they follow appendicitis in the young. In the immature, the appendix, even in its normal position, lies in fairly close proximity to the right tube, while a low hanging appendix may even rest in the posterior culdesac. Moreover, the bony pelvis of the young is straighter, that is to say, less canting, than one that is fully developed, so that the influence of gravity acts more directly on a free exudate from above. Hence in the young the anatomic conditions are less favorable for a local walling off of an appendix abscess than in adult women in whom there is greater distance and a less direct course between the appendix and the adnexa.

The appended case reports illustrate well the immediate and late changes in the pelvic organs, which may result as a consequence of youthful acute appendicitis.

EFFECT OF CHRONIC APPENDICITIS ON THE PELVIC ORGANS

It remains now to inquire whether secondary changes may be effected in the pelvic organs by a *chronic appendicitis.* The solution of this problem offers greater difficulties inasmuch as the histologic data of a given case are less well-defined, and it is necessary to resort in part to speculation.

It seems to be well established that the appendix may undergo considerable grades of inflammation and yet eventually be restored to a condition of approximate normality. It is entirely probable that during the inflammatory periods of a chronic appendicitis, a serous, or serofibrinous exudate is produced which finds its way by gravity into the true pelvis. One often encounters such an exudate in apparently uncomplicated pelves and wonders whence it came. It is quite within reason to suppose that, although this exudate is usually absorbed by the peritoneum, under certain conditions it may be sufficient either through bacterial or chemical influence to destroy the superficial epi-

thelium of the pelvic peritoneum and to stimulate the subserous connective tissue into the formation of organized plastic adhesions; or it may itself become organized and form the basis of adhesions.

In this way may be explained theoretically the cases not infrequently encountered, in which without sign or history of gonorrhea or puerperal sepsis, adhesions are found in the posterior culdesac, or implicating the surfaces of the adnexa while the appendix shows only mild evidence of disease, or perhaps none at all, to gross appearance. If besides the pelvic adhesions there is added a well-defined chronic appendicitis, or the scar of an appendix operation performed in youth, our explanation becomes still more plausible; certainly more so than the attempt to ascribe the condition to an entirely improbable gonorrheal infection.

The pathologic tissue changes that take place later in a secondary pelvic inflammation depend on the severity of the initial appendicular infection. In cases in which there has been an overwhelming flood of pus in the pelvis, the resulting adhesive peritonitis may be so extreme as to involve completely the uterus and both adnexa. The immature uterus becomes fixed, usually in the position of retrocessed anteflexion, and is prevented from attaining its full development. The ovaries buried and immobilized are likely to retain their infantile character of form, usually cystic, with a white, thickened, unscarred, albuginea; or they may develop retention cysts of moderate size. The tubes, though encased in adhesions, may show remarkably little destructive change. It is sometimes found that after being dissected free, the ostia though inverted are only delicately adherent and that by careful manipulation the fimbriae may be made to roll out into their normal efflorescent form, an important practical point to remember when operating for sterility.

The severe cases of this kind that I have encountered in my practice (in which gonorrhea could with certainly be ruled out) have been observed during an operation, usually for sterility, perhaps years after the attack of appendicitis in early life. In some of the most adherent cases there has been in the patient's history a remarkable absence or mildness of pelvic symptoms. In several instances, when bimanual examination even under an anesthetic has revealed nothing more than an infantile uterus, the pelvic organs have proved to be so buried in adhesions as to be almost indistinguishable. It is as if there had been a complete organization of adhesions and adjustment of internal genitalia during the period of development and growth. On more than one occasion, I have felt after releasing the adhesions that it would have been better to leave the pelvis entirely alone.

The adherent organs in a severe case are extremely difficult to separate, but there is not that stiffness and hardness seen in adhesive tuberculosis, nor the tissue destruction of an old gonorrheal process.

From the cases of universal adherence, there are all grades of secondary plastic pelvic peritonitis to cases in which there is only a mild posterior perimetritis or a few insignificant adhesions of the right adnexa.

One of the most serious consequences of appendicitis in early life with pelvic involvement is sterility, and it has been in the attempt to remedy this complaint that I have most often encountered the condition. Theoretically, conservative operations for the relief of sterility in cases of secondary pelvic inflammation should be more successful than in cases following gonorrheal salpingitis, for there is not the same degree of tissue destruction of the tubes and ovaries. Practically, however, the outlook for a cure of sterility is not very good, at least it has been so in my experience, even when the tubes and ovaries can be left in a comparatively normal condition. On the other hand, I have observed that the symptomatic results of a conservative operation for pelvic adhesions secondary to appendicitis are much better than after a similar operation for primary gonorrheal adhesions. This is to be expected, for there is not the same tendency in the former to a reorganization of adhesions, nor is there the possibility of leaving behind in the conserved tissues, latent sources of the original infection.

Much has been written regarding early appendicitis, as a causative factor in a later ectopic pregnancy. Numerous cases have been reported, in which the anatomic relationship of an ectopic pregnancy and an acute or chronic appendicitis, make it extremely probable that in this or that particular instance there was a causal connection between the two lesions. Theoretically, it is conceivable that the serous exudate which, as I have heretofore stated may sink into the pelvis during the exacerbations of a chronic appendicitis, may create minor tissue changes in the tubes sufficient to result in an ectopic pregnancy. It is probable that only a minute abnormality in the tube may retard the normal progress of the impregnated ovum long enough to cause it to nidate in the tubal mucous membrane. The plastic influence of a descending pelvic exudate may be exerted on either or both tubes, but it may be expected that a chronic appendicitis would more frequently affect the right tube. In a series of forty-seven cases of ectopic pregnancy, I found the condition only slightly more frequent on the right than on the left. On the other hand, in the right-sided cases the appendix was found diseased in 80 per cent. whereas in the left-sided cases it was diseased in only 57 per cent. These figures, though comprising

too small a number of cases, are at least suggestive that appendicitis must be reckoned with as an important factor in extra-uterine pregnancy.

The relationship of early appendicitis to dysmenorrhea is a subject to which gynecologists have given considerable attention. It is a matter of constant observation that the appendicular colic of a chronic appendicitis is usually more marked at the menstrual period, and frequently is experienced only at that time. The same may be said of the pains of a plastic adnexitis, whether it be from a tubal or appendical origin. Such symptoms are due to the effect of the general catamenial congestion on adherent organs, and must be grouped under the heading of secondary dysmenorrheas.

The relationship of appendicitis to essential dysmenorrhea is a more difficult and as yet an unsolved problem. No gynecologist can have failed to note the frequency with which young patients with essential dysmenorrhea complain also of appendicular pain during or between the periods. Most of these patients have an abnormality of uterine position, most commonly in the form of retrocessed hyperanteflexion. Genital hypoplasia is frequent. There is in the majority of cases no secondary inflammatory reaction in the pelvis. In a series of 100 cases, taken from hospital records, in which operation was performed for essential dysmenorrhea, I find that the appendix was diseased in 63 per cent. This series is to be contrasted with one of 100 noninflammatory pelvic conditions, cases of essential dysmenorrhea being excluded, in which the appendix was diseased in only 33 per cent.; and also with a series of cases of pelvic inflammation in which the appendix was abnormal in 47 per cent.

We are confronted then with the indubitable fact that the genital abnormalities that produce symptoms of essential dysmenorrhea are associated with an unusually high percentage of diseased appendices. Is there any causal relationship between the two conditions, and if so, in what way is it effected? This question has not as yet been satisfactorily answered. Lapeyre, in 1913, rather vaguely explained it on the ground of correlated sclerosis of the appendix and ovaries, but did not answer the main question. It has been a matter of personal observation that essential dysmenorrhea is conditioned rather on the position and tissue-consistency of the uterus than on functional or anatomic changes in the ovaries. In addition to the hypoplasia and retrocessed hyperanteflexion of the uterus heretofore mentioned, one frequently encounters short, thickened, uterosacral ligaments often tender to the touch, and suggesting a chronic posterior (sometimes called superior) parametritis. In the more obstinate cases there is also often found a cicatricial band at the internal os, giving the impression

of a partial stricture. Is it not possible that these metrial and parametrial cicatrices are the rests of some early changes secondary to an inflammatory process in the intestinal track? If we accept the theory that Jackson's membranes, Lane's kinks, folds of Treves, attic adhesions, and the numerous other organized intestinal bands are the result of early, even fetal, peritonitic processes, it is not difficult to imagine that such inflammations may be imparted to the pelvic organs through the channel of the subserous cellular tissue, and there leave traces which may later limit the full development of such organs. Perhaps in this way may be explained the amazing frequency of genital hypoplasia in women. Perhaps too the colic and "growing" pains of young children are in reality peritonitic in character and are often the ultimate cause of restricted genital development.

The foregoing speculation as to the effect of fetal adhesions is not without some scientific support. I have observed a case of uterus didelphys caused by an intervening adhesive band between the bladder and rectum, which prevented the complete union of Müller's ducts. Other similar cases have been reported.

A thorough realization of the pathology of early appendicitis in the female emphasizes several very practical lessons, which may be summarized thus:

Appendicitis in childhood and young girlhood is an affection which must be regarded not simply with reference to the diseased appendix itself but to the serious harm which it may exert on the pelvic organs, if left to work out its own destiny in a state of chronic inflammation. Early operation is therefore indicated in children when there is any suspicious evidence of appendicular infection. In the acute stage, the appendix should be removed immediately to forestall if possible a secondary involvement of the adnexa. If pus is present, every effort should be made to drain the pelvis, it being feasible in certain cases to drain the pouch of Douglas through the vagina. Excepting in cases of localized abscess it is advisable to make a median line incision in order that the pelvic organs may be inspected, and that any abnormalities of position or plastic adherence may be remedied by a proper surgical procedure.

REPORT OF ILLUSTRATIVE CASES

The three cases herewith reported are illustrative of the serious results that may follow early appendicitis.

CASE 1.—*History.*—M. M., aged 14, had an abdominal attack in 1915, which was diagnosed by a physician as acute salpingitis with sactosalpinx. Expectant treatment was advised. The condition grew worse and on the third day after the attack demanded immediate intervention.

Examination.—The patient was well developed, puberty was established and the hymen was unruptured. The condition was diagnosed as acute appendicitis with pelvic abscess.

Operation and Result.—An operation, at which I assisted, was performed under disadvantageous conditions in a country town. A right rectus incision was made, and the pelvis and abdomen were found filled with pus. The right tube which appeared first in the wound was very large and red. The appendix, which was located with some difficulty, was gangrenous and perforated. It was removed, and the pelvis was drained. There was a slow, stormy convalescence resulting in recovery.

Five years after the operation, the patient was seen, but no examination was made. She had suffered considerable pelvic pain since the operation. The menses, which were well established at the time of operation, have been somewhat irregular and scanty since, and there has been severe dysmenorrhea. Though unusually well developed at 14, she has grown little since, presenting the general appearance of incomplete development.

CASE 2.—*History.*—Mrs. R. P. K., aged 27, who had been married for five years and who had no children, complained chiefly of sterility. Menstruation was very irregular, the flow was profuse and clotted. Otherwise the patient was perfectly well. She had severe appendicitis at about the age of puberty for which an operation was performed.

Examination.—The patient was well developed and tended to be fat. There was retroversioflexion of the uterus. Both ovaries were prolapsed and the uterus was undeveloped. There was no possibility of gonorrhea or puerperal sepsis.

Operation and Result.—Operation was performed, Jan. 21, 1911. The pelvis was filled with adhesions extending from an old appendicitis scar. These were released. The tubes when released appeared normal; both ovaries showed a white dense albuginea. The left ovary contained a small fibroma. No corpus luteum was found in either ovary and no scarring. Both ovaries were very large. They were resected to normal size, and the uterus was restored to normal position by a modified Gilliam's operation. Convalescence was uneventful. Although the patient was perfectly well after the operation, fertility was not restored. A similar operation was performed later by another surgeon with similar results.

CASE 3.—*History.*—Mrs. H. B., aged 30, who had been married five years, complained chiefly of sterility. She felt perfectly well. Menstruation had been regular, but there had been some dysmenorrhea. There was no possibility of gonorrhea or puerperal sepsis. She had acute appendicitis during her girlhood for which operation was performed.

Examination.—The patient was well developed. The uterus was anteflexed and retrocessed. The left ovary was prolapsed and somewhat tender.

Operation and Result.—Operation was performed, May 22, 1916. The pelvic organs were found completely buried in adhesions which extended from an old appendicitis scar. The pelvic organs were released from the adhesions with the greatest difficulty. The left ovary contained a blood cyst. The left tube and ovary were so damaged that they required resection. The release of the adhesions left a bleeding area in the pelvis requiring ligature of a branch of the left uterine vein and packing to control venous oozing. The patient had a stormy convalescence, but recovered eventually. She has been perfectly well since, although fertility has not been restored. There has been no disturbance of the menses.

244 Marlboro Street.

THE TREATMENT OF PES CAVUS (HOLLOW CLAW FOOT)

ARTHUR STEINDLER, M.D.
IOWA CITY

The deformity herewith described is known as pes cavus or arcuatus, hollow or hollow claw foot. Clinically it is characterized by these cardinal points:

1 An increase in the height of the longitudinal arch.

2. A dropping of the anterior arch with plantar flexion of the front of the foot.

3. A variable amount of dorsal retraction of the toes, the claw foot deformity proper, with hyperextension of the metatarsophalangeal, and flexion of the phalangeal joints.

The retraction of the toes is as inherent a part of the deformity as is the abnormal height of the arch; both features are, in fact, genetically interdependent.

Of the nonparalytic cases, a small number are present at, or develop soon after, birth; but the majority of these cases develop during adolescence, first as talipes arcuatus or hollow foot, and progress under certain conditions, to the claw foot stage. Some of these cases present evidences of developmental arrest in the form of anomalies of the spinal column, wedge formation of vertebrae, rachischisis or defective occlusion of the neural arches (Duncker).

A considerable number of cases of hollow claw foot deformity are due to infantile paralysis; another group develops in the wake of spastic paralysis.

Of the poliomyelitic group, the cases with severe paralysis, especially those with paralyzed calf muscles and calcaneus deformity, will not be considered. In these cases, the correction of the claw foot deformity does not mean cure. An arthrodesis of the affected joints must be performed. The only type of poliomyelitic claw foot that will be considered here is that with a limited paralysis, in which correction, with or without tendon transplantation, is followed by a permanent result.

ANALYSIS OF THE MUSCLE IN IMBALANCE PRODUCING HOLLOW CLAW FOOT

The increase in height of the longitudinal arch is due mainly to the unopposed or insufficiently opposed pull of the short muscles of the foot, which draw the ball of the foot toward the heel. This muscle

group, consisting of the common short flexor of the toes, the abductor of the first and the abductor of the fifth toe, is aided in producing this deformity by the flexor of the big toe, and the posterior tibial muscle. Opposing this group are the flatteners or extensors of the longitudinal arch, namely, the Achilles tendon behind, and the tibialis

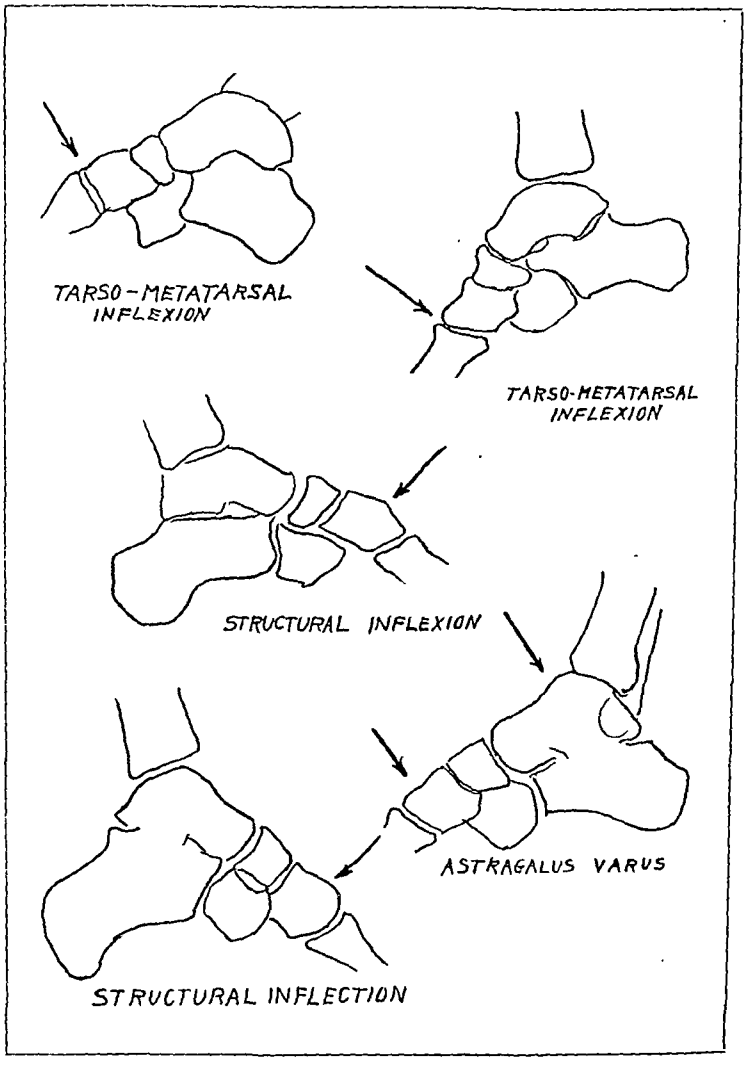

Fig. 1.—Structure of tarsus in pes cavus deformity.

anticus in front, the former acting on the posterior pillar, the latter on the anterior pillar of the longitudinal arch. The forces concerned act thus:

The flattening of the arch is caused by the body weight, centered on the body of the astragalus, by the muscles inserted into the Achilles

tendon and the tibialis anticus; the arch is maintained and elevated by the short muscles of the foot, the tibialis posticus and the flexor of the big toe.

Deficiency of power of any of the muscles involved will destroy the balance and be capable of producing the deformity. In infantile

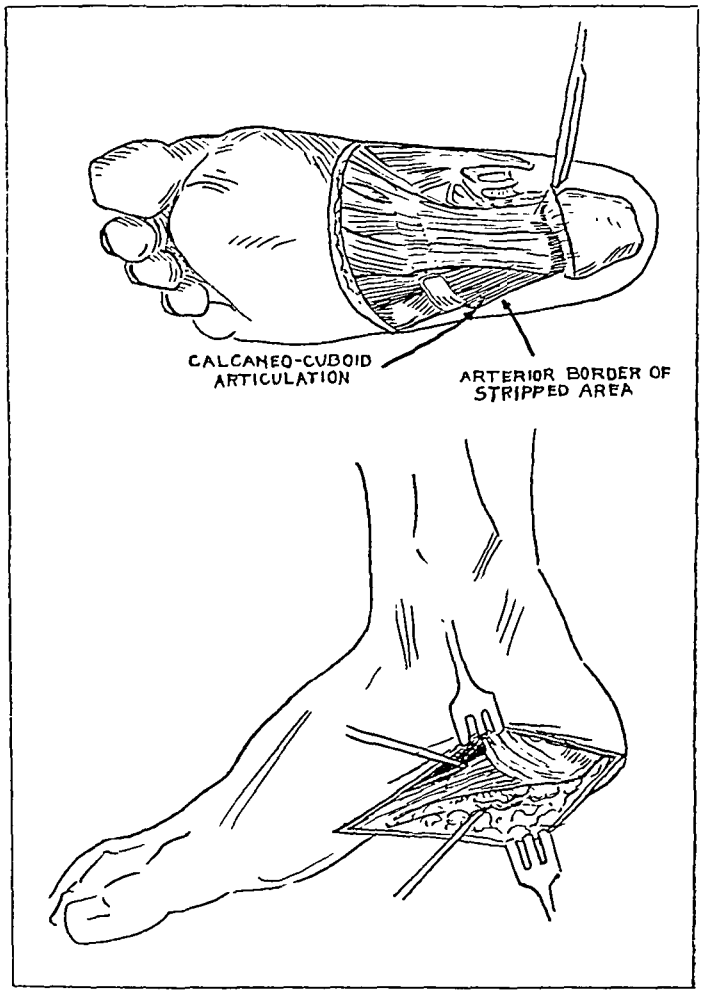

Fig. 2.—Stripping of the os calcis for the correction of the contracted structures in the sole of the foot.

paralysis, loss of gastrocnemius-soleus action is followed by an upward tilt of the front of the os calcis and the approachment of the heel to the ball of the foot as a result of the unopposed action of the short muscles of the sole. Although these cases of paralytic calcaneo-

cavus deformity cannot be cured by correction alone, as has already been mentioned, and arthrodesis must be resorted to, they are cited to explain one mechanism of the claw foot deformity.

Our attention has for some years been called to another type of paralytic hollow claw foot, in which the paralysis is distinctly limited, only the tibialis anticus being involved, and in addition, but usually to much lesser extent, the extensors of the toes and the quadriceps extensor. These patients not only develop the hollow foot with contraction of the plantar structures, but skeletal deformity, and retraction of the toes as well.

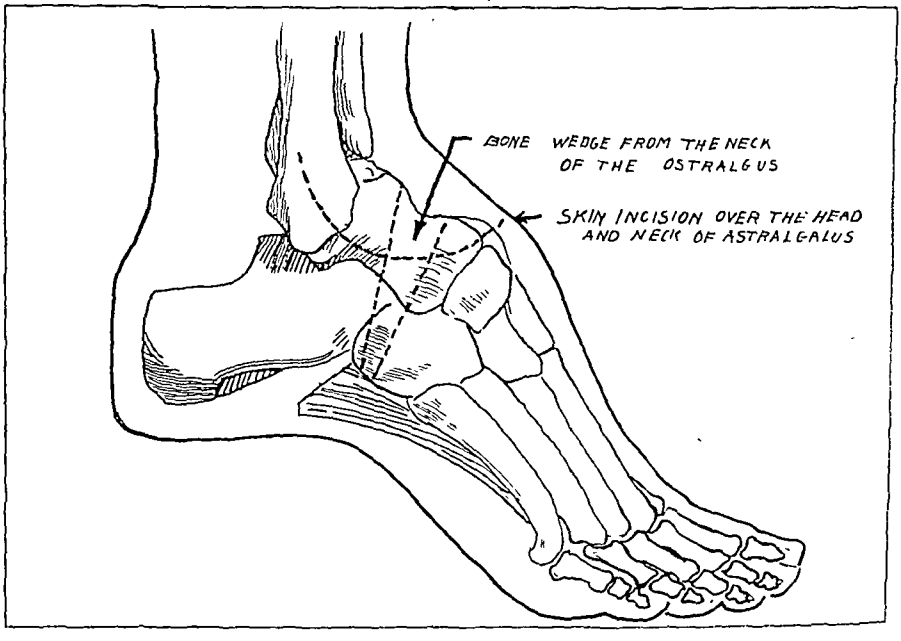

Fig. 3.—Cuneiform osteotomy for the correction of the skeletal deformity.

The cases in which correction of the deformity promises a cure are those with well functioning triceps surae muscles with no relaxation of the Achilles tendon. Many of these are associated with equinus deformity. This is either a true equinus deformity due to contraction of the Achilles tendon, or an apparent equinus deformity, the Achilles tendon being neither contracted nor relaxed, and the position being due to a plantar flexion of the front of the foot. This plantar flexion is seen especially in the severe cases, showing not only marked contraction of the plantar structures, but also skeletal deformity, and protrusion of the ball of the foot into the planta and retraction of the toes.

In most of the cases of this kind there is much less contraction of the Achilles tendon, if there is any at all, than might be suspected

a *b*

Fig. 4 (L. C.).—Equinocavus paralyticus corrected by stripping of the os calcis: *a*, foot before operation; *b*, same foot, three and one-half years after operation.

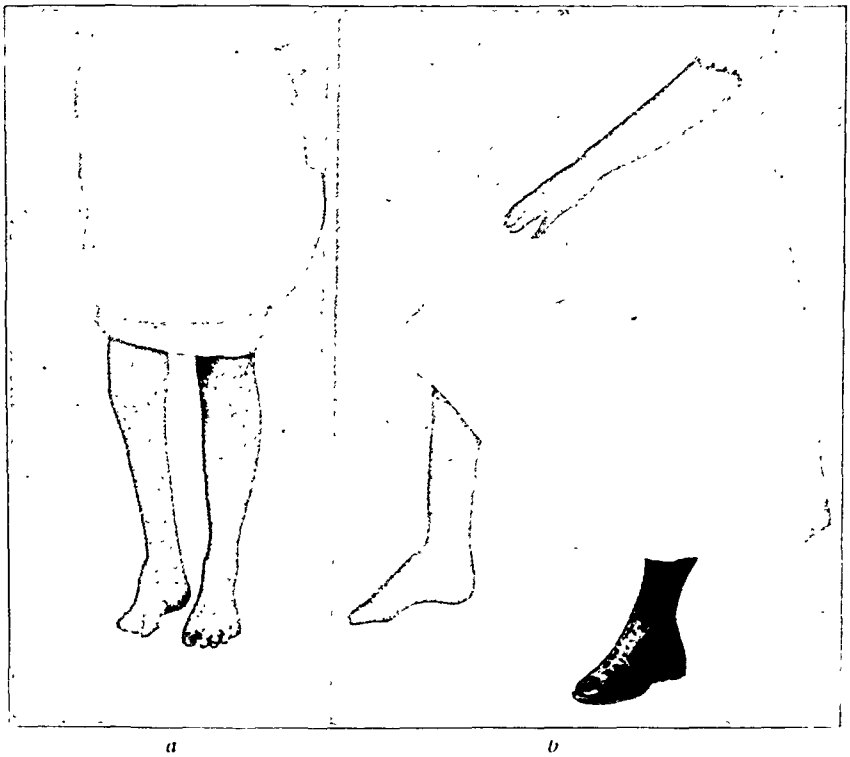

a *b*

Fig. 5 (H. E.).—Paralytic cavus corrected by stripping of os calcis: *a*, before operation; *b*, one and one-half years after operation.

from a first glance at the deformity. The so-called equinus is almost entirely due to the plantar deflection of the front of the foot and the tarsus.[1] The intrinsic structures of the skeleton of the foot demonstrate this deflection clearly at different points, as I have pointed out on previous occasions. The break occurs sometimes in the astragalus, the head and neck bending downward with a decrease of the angle normally found between the axes of the body and the neck of the astragalus (astragalus varus), sometimes the bending may be noted

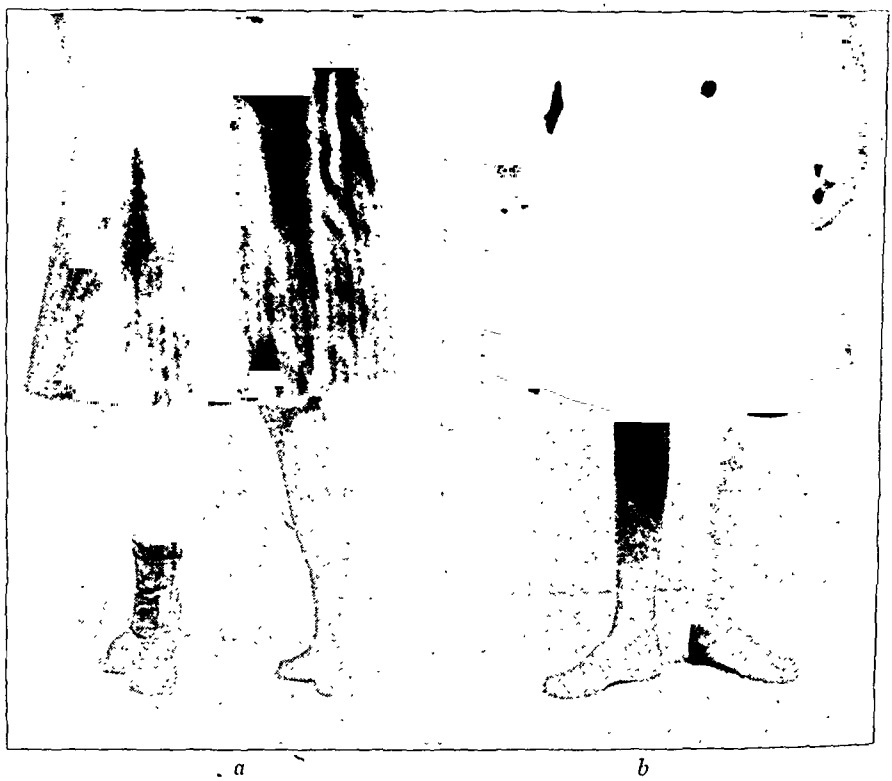

a *b*

Fig. 6 (E. B.).—Paralytic cavus corrected by stripping of os calcis. *a*, before operation; *b*, six months after operation.

in the astragalo-scaphoid joint or in the internal cuneiform bone. The first metatarsal bone is usually deflected downward more than the others, its head projecting into the sole of the foot (Fig. 1).

I think it is necessary to dwell at some length on the several phases of the development of the deformity because the treatment must be based on a knowledge of the factors concerned in its development. It must take into account all deforming factors and the correction must be complete.

1. Steindler, A.: Architecture of the Tarsus, Am. J. Orthop. Surg., 1916.

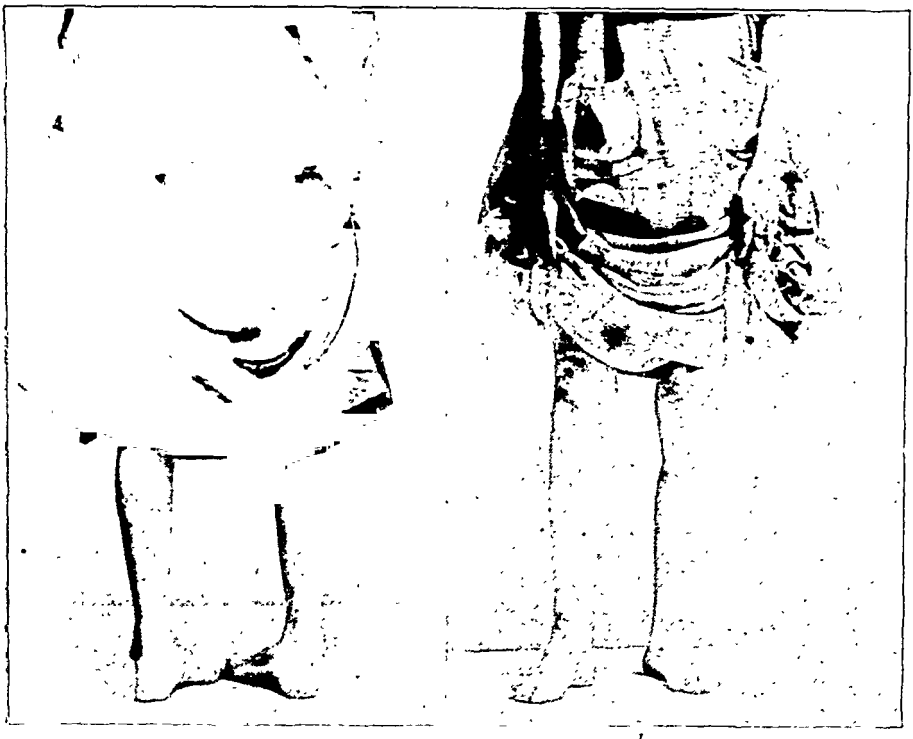

a *b*

Fig. 7 (A. W.).—Congenital pes cavus corrected by stripping and osteotomy; *a*, before operation; *b*, right foot, two months after operation, left foot, two years after operation.

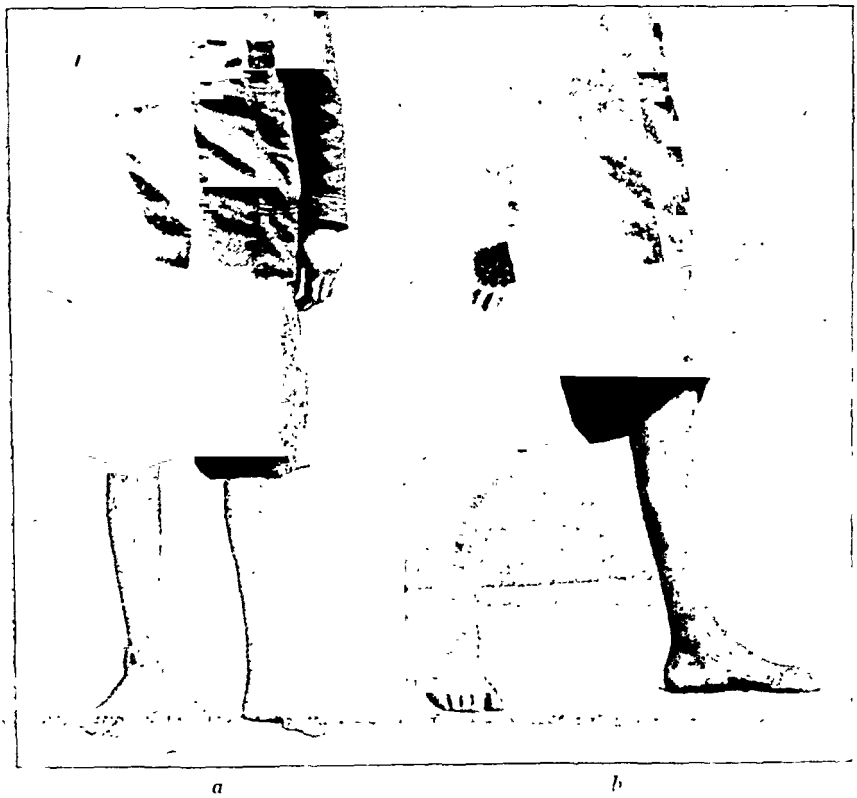

a *b*

Fig. 8 (R. E.).—Paralytic calcaneocavus corrected by stripping and osteotomy: *a*, before operation; *b*, immediately after operation.

TECHNIC OF CORRECTION OF THE DEFORMITY

For the correction of the contracted structures in the sole of the foot I have, on a previous occasion, advised the following method:[2]

A curved incision is made which extends on the inner side of the foot from the back of the heel to a point well in front of the anterior process of the os calcis. As the subcutaneous fat is incised, the median border of the contracted structures of the sole is seen, and the shiny fibers of the thickened plantar fascia appear. The entire

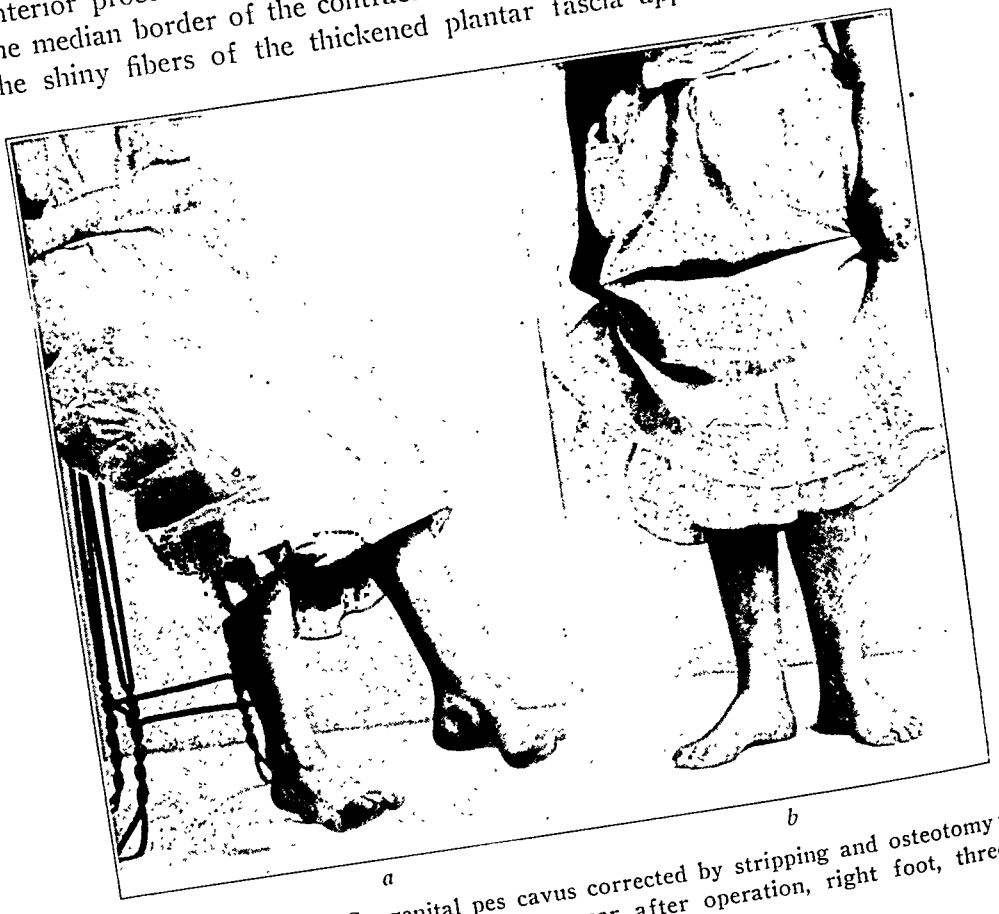

a *b*

Fig. 9 (M. T.).—Congenital pes cavus corrected by stripping and osteotomy: *a*, before operation; *b*, left foot, one year after operation, right foot, three months after operation.

width of plantar fascia for a distance corresponding to the length of the incision is then exposed. As the fascia is separated from the fat, many fibrous strands running from the fascia into the subcutaneous tissue must be severed. A blunt dissection is then made until the space between these short muscles of the foot and the flexor of the big toe is reached. A grooved director is then passed between the two. The

2. Steindler, A.: Operative Treatment of Pes Cavus, Surg., Gynec. & Obstet. **24**:612 (May) 1917.

plantar fascia is now incised transversely at the line of insertion into the os calcis. From this line the fascia and attached short muscles are stripped off subperiosteally, from the under surface of the os calcis. This stripping[3] should extend far enough forward to include the inferior calcaneo cuboid ligament or ligamentum plantare longum, since this is largely responsible for the cavus deformity on the outer border of the foot. By keeping close to the inner tuberosity of the os calcis and proceeding from here outward, one can keep at a safe

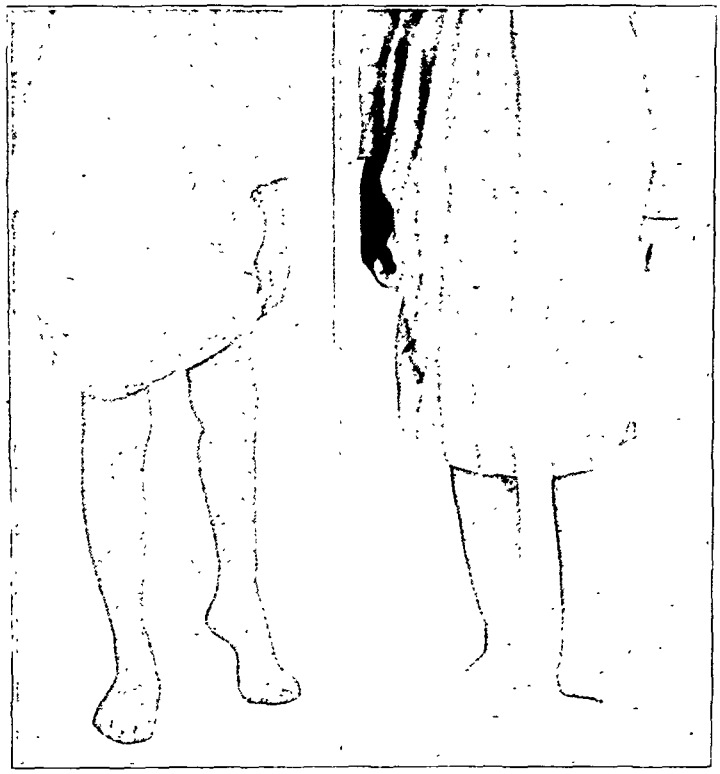

a *b*

Fig. 10 (T. A.).—Paralytic equinocavus corrected by stripping and osteotomy: *a*, before operation; *b*, eighteen months after operation.

distance from the plantar nerves and vessels. There is sometimes considerable oozing, but it can be controlled readily by temporary packing. The wound is closed in two layers of sutures, one passing through subcutaneous tissue, the other through the skin (Fig. 2).

The contraction in the sole being corrected by the procedure just described, the skeletal deformity is then corrected by a cuneiform osteotomy:

3. Steindler, A.: Stripping of the Os Calcis, J. Orthop. Surg. 2:8 (Jan.) 1920.

a *b*

Fig. 11 (G. C.).—Paralytic pes cavus corrected by stripping and osteotomy: *a*, before correction; *b*, eight months after operation.

Fig. 12.—Pes cavus before operation.

A curved incision is made from the anterior edge of the external malleolus downward and inward to a point directly over the head of the astragalus. After severing the fascia, a blunt dissection is made between the extensor of the big toe and the common extensor, retracting the median muscles inward and the lateral outward. The head and neck of the astragalus are easily exposed and a suitable

Fig. 13.—Pes cavus after correction.

wedge, with a dorsal or dorsolateral base, is removed. The osteotomy is then extended laterally through the cuboid or the anterior process of the os calcis, these bones being readily exposed by further lateral retraction of the tendons. This will be necessary in all cases in which there is varus tendency or in which the skeletal deformity is more marked. Whether the osteotomy is to be performed through the neck or through the head of the astragalus or farther in front

Fig. 14.—Pes cavus before operation.



Fig. 15.—Pes cavus after correction.

depends on the site of the plantar deflection in the individual case (Fig. 3).

These procedures should completely correct the claw foot deformity. They should allow the arch to flatten out completely, and the anterior arch to be properly raised thus permitting the retracted toes to be placed in a straight position. In order to accomplish the last, a tenotomy of the extensor and of the long flexor of the big toe, as well as of the common extensors of the toes in more pronounced cases of claw foot may be necessary. With the operative measures just mentioned all degrees of hollow claw foot should be entirely corrected with the exception of those of extreme degree which require extensive operations on the heads of the metatarsal bones.

In addition, it may be stated that in the cavus deformity due to paralysis of the tibialis anticus a physiologic tendon transplantation [4] should be included after the deformity has been properly and completely corrected. I use the extensor of the big toe to supplant the paralyzed tibialis anticus muscle.

In the last four years, ninety patients with hollow claw foot have been operated on by these methods: stripping of the os calcis in fifty-nine cases, and stripping and osteotomy in thirty-one cases.

The results were quite satisfactory as far as correction of the deformity was concerned. In the earlier operations, the results were frequently not entirely satisfactory because of the incompleteness of the surgical procedure. Later, however, when osteotomy became included more regularly in the operative plan, and arthrodesis was employed in the severe paralytic cases of cavus and calcaneocavus, the operative results of the treatment just outlined became sufficiently complete and permanent to warrant the advocacy of this method for the correction of the hollow claw foot deformity.

Figures 1 to 10 illustrate the operative result in ten cases.

University Hospital.

4. Steindler, A.: Nutrition and Vitality of the Tendon in Tendon Transplantation, J. Orthop. Surg. **16**:63 (Feb.) 1918.

MIDLINE CONGENITAL CERVICAL FISTULA OF TRACHEAL ORIGIN

M. G. SEELIG, M.D.
Professor of Clinical Surgery, Washington University Medical School
ST. LOUIS

Up to about 1880 it was generally believed that midline congenital fistula of the neck might be due to tracheal maldevelopment, but according to the well established doctrine of today, they are supposed never to be of tracheal origin. If one studies the subject in any of the larger bibliographic reference works, he is impressed by the comparatively large number of reported cases of so-called congenital tracheal fistula. On consulting the articles referred to, however, one becomes aware that the error of referring these fistulas to tracheal maldevelopment persists only by virtue of the titles of the various articles. As a matter of fact, within three years after Dzondi (1829) first created the term tracheal fistula, Ascherson recognized the error; but in correcting it, fell into a somewhat similar one by assuming that all midline cervical fistulas communicated with the pharynx. In 1864, Heusinger coined the phrase branchial fistulas to explain these defects. Heusinger states: "Some authors classify congenital fistulas of the neck into *(a)* pharyngeal fistulas and *(b)* tracheal fistulas." He then adds that he will preserve this classification, although "a congenital tracheal fistula has never been demonstrated." He might have stated his point even more emphatically; for an analysis of all the case reports up to the time of Heusinger's publication discloses neither clinical nor pathologic evidence that would warrant more than a faint suspicion of tracheal participation in midline fistula formation. In 1848, Luschka published an article that evidently carried much weight as authority, for his views were accepted by Koenig as late as 1875 in that year's edition of his "Specielle Chirurgie," and by Fisher in the 1880 volume of "Deutsche Chirurgie," devoted to diseases of the neck. Luschka assumed that in midline cervical fistulas there exists, originally, a communication between the fistulous tract and the trachea.

An article published by Kostanecki and Mielecki in 1890 marked the establishment of the fundamental pathologic principles underlying cervical fistulas. These authors showed that the so-called tracheal midline fistulas had, in reality, nothing to do with the trachea. In their opinion, no significance was to be attached to the site of cervical fistulas; all cervical fistulas were branchiogenetic, and whether the openings were centrally or laterally placed depended merely on which

branchial cleft was responsible for the fistula. In their opinion, when the second branchial cleft was involved, a midline fistula resulted, as a rule; but when the third or fourth cleft was involved, a lateral fistula resulted. This, of course, was an error. It persisted, however, for only a short time.

The year after the publication of Kostanecki and Mielecki's article in 1891, His published his study of the thyroglossal duct, demonstrating its descent from the foramen cecum of the tongue to the permanent site of the thyroid isthmus, causing abnormalities in this descent that are responsible for all midline cervical fistulas. The views expounded by His have met with universal agreement. Koenig, himself, in a

Fig. 1.—Anterior view of the defect. Inset shows enlargement of the teat, rosette, cicatrix and fistulous opening.

later edition of "Specielle Chirurgie" (1895) says that "midline tracheal fistulas of congenital origin are merely figments of the imagination" (phantasiegebilde). And thus the question has stood since 1891: Midline congenital fistulas of the neck are related in some way to the maldevelopment of the thyroglossal duct (barring, of course, the cases in which branchiogenetic retentions have burrowed over toward the midline), and are never due to maldevelopment of the trachea.

A case encountered recently in private practice seems to establish quite clearly the fact that midline congenital fistulas of the neck may be due to tracheal anomalies, and that we cannot unreservedly group all these fistulas under the head of thyroglossal duct anomalies.

REPORT OF CASE

History.—A man, aged 26½ years, with a totally negative family and past history, reported that since the day of his birth he had had a defect in the middle of his neck. There had never been any associated pain or discomfort, and professional advice had never been sought regarding a cure. There had always been a small amount (a drop a day) of purulent discharge from the lower part of the defect, and a minimal amount of glairy secretion from the upper part ("not enough to bother about wiping off"). There had never been any retention with consequent signs of inflammation. The patient sought relief merely because the defect had become unsightly to him.

Physical Examination.—This was negative except as regards the defect itself There were no other visible congenital defects.

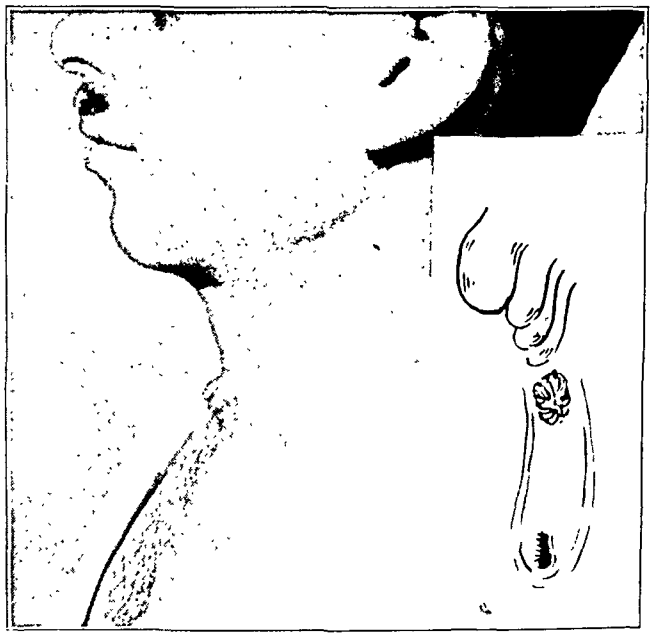

Fig. 2.—Lateral view of the defect. Inset shows the details from this view.

From 1 inch below the chin, in the midline of the neck, running down to 1 inch above the jugulum, there was a prominent fold of skin, which felt like a subcutaneous cicatrix and which became tense when the chin was elevated. About 1½ inches above the jugulum in the midline, there was a firm fleshy teatlike process, three-fourths inch long and one-fourth inch in diameter. This process hung, tip downward, and was attached to the skin of the midline by a fold of skin, running from base to apex of the teatlike process. This fold which was creased on itself at rest, could be spread out fanwise by picking up the teat and pulling it away from the neck.

Directly beneath the low point of the fold of skin, there was a small circular rosette-shaped bud of granulation-like tissue, about one-fourth inch in diameter, presenting radiating sulci and rugae, and a surface that had a glazed appearance, as if painted with mucus. This glairy surface could be wiped dry and dull, but shortly afterward it became moist and glazed again. With

the finest silkworm gut probe, it was not possible to discover a fistulous opening in this rosette.

From this rosette, running downward toward the jugulum was an elliptical cicatrix, 1 inch long and one-half inch wide. The surface of this cicatrix was thoroughly epithelialized, dry and glazed. This cicatrix at its lower pole, ended in a fistulous opening one-fourth inch in diameter, which in turn led into a sinus that ran down to a point slightly below the upper margin of the sternum. This sinus was immediately under the skin, throughout its course, and could be partly everted through its mouth, showing a moist, rugose and bright red mucous membrane lining (Figs. 1 and 2).

Operation and Result.—The opening of the fistula was circumscribed and the tract was dissected out with a minimal amount of the surrounding tissue in which it lay. During this dissection, it was noted that in the wall of the

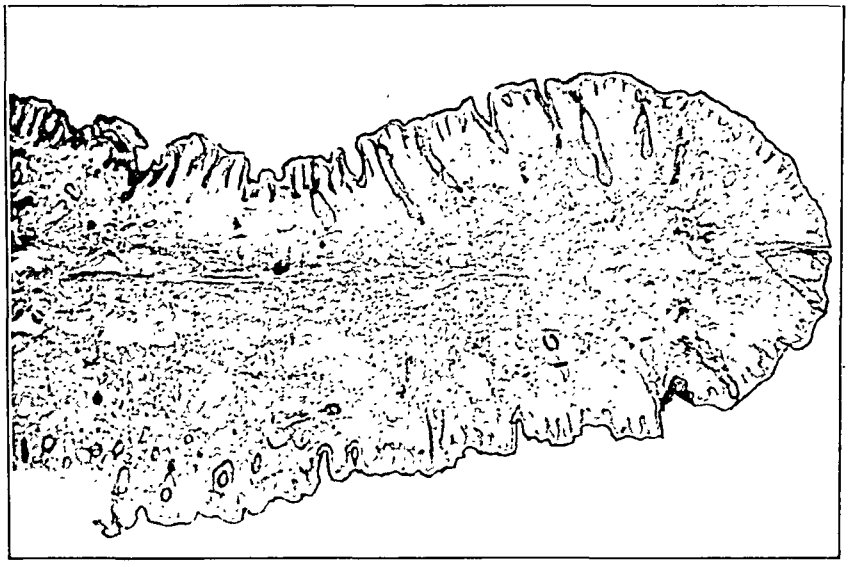

Fig. 3.—Photomicrograph of the teat.

tract, at about its center, there was a small pea sized cartilaginous-like mass. After the tract had been dissected out, two elliptical incisions were made, circumscribing the entire defect, running from just above the teat, along the lateral margins of the cicatrix already described and ending in the incision utilized for dissecting out the lower tract. Through these incisions, the defect was removed *en masse* and all removed tissue was dropped into 10 per cent. liquor formaldehydi. At no point could there be made out anything resembling a patent thyroglossal duct, or any other type of fistulous deep running tract.

The wound was closed around a small rubber tissue drain, and was perfectly healed in two weeks. It has remained healed now for more than ten months.

Histologic Examination.—The tissue removed was examined by Dr. M. T. Burrows, whose report is given herewith:

The specimen examined lay in the midline of the neck and consisted essentially of three parts. The upper end was located at a point just below the

level of the lower edge of the thyroid cartilage and the lower end was well down beneath the skin over the upper end of the sternum. The upper part consists of a teatlike protuberance which is covered with skin and looks like the lobule of the ear. This projects out and hangs over a small sessile tumor mass which has a glairy and fissured surface. The surface of this tumor mass is covered with a glairy secretion. The third part is a tube closed below and opening above, just below the middle part into a floor of what appears to be very thin skin. This tube admits a 3 mm. probe and extends down into the subcutaneous tissue over the sternum for about 3 cm. There

Fig. 4.—Low power magnification of section through rosette, showing cartilage, muscle layer, submucosa and papillary mucosa.

is a small mass of cartilage attached to the wall of this tube in its lower half. There is no definite connection between these structures and the deeper tissue of the neck. The specimen is fixed in liquor formaldehydi and sections are taken from three parts.

Section 1 is of the upper teatlike process. It is composed of a central mass of connective tissue. This is divided into two parts. An outer part which is covered by the epithelium of the skin. This part looks like true skin. It contains hair follicles and sebaceous glands, and transmits the sweat ducts from the glands below to the surface. The sweat glands appear normal. The internal layer consists of connective tissue in the center of which are a few

striated muscle fibers, a part apparently of the superficial muscle layer of the neck (Fig. 3).

Section 2 is from the sessile tumor which lies just below the teatlike process (Section 1). The outer edge of this mass is irregular. It has many papillomatous projections. Its surface is covered by low cuboidal and high columnar and ciliated epithelium (Figs. 4, 5 and 6). In the tissue between the papillae there is a mass of hyaline cartilage. The connective tissue between this cartilage and the surface is poorly divided into mucosa and submucosa. It is areolar in character. There are a few smooth muscle cells about the cartilage, and it contains well formed mucous glands and ducts. The ducts are lined with high columnar epithelium without, and low cuboidal cells within. The glands are like those of the normal trachea and bronchus. In a few glands, on the surface, the epithelium is pseudostratified, like that of the trachea. The whole picture is like that of sections of the trachea or bronchus.

Fig. 5.—High power magnification of portion of section shown in Figure 4. demonstrating the structure in greater detail, particularly the mucous glands.

Section 3 is a section through the lower part of the wall of the tube. It is covered with squamous epithelium like that of the larynx. It differs from this only that in a few places it has a more definite horny layer. The other layers peculiar to the skin are not present however. Ducts extend down from this into the deeper tissue. They are lined with a stratified epithelium of which the inner row of cells are high, columnar and ciliated. Their cytoplasm is clear. They are apparently filled with mucus. No glands are seen in this section. At one end of the section, there are a few sebaceous glands near what appear to be hair follicles. The connective tissue is areolar in type. The part lying just beneath the outer epithelial covering is densely infiltrated with lymphoid and polyblastic cells (Fig. 7).

Section 4 is taken from the wall of the lower end of the tube. It is covered with squamous epithelium like that of the larynx. There are a few lymphoid

cells in the connective tissue beneath, and deep in, there is an irregular mass of hyaline cartilage surrounded by a well formed perichondrial layer and skirted on one side by a mass of mucous glands like those in the larynx or trachea.

Section 5 is taken from just without the mouth of the tube. It is covered by squamous epithelium like that of the mouth. Deep in, there is a gland duct lined by pseudostratified and stratified epithelium of which the inner

Fig. 6.—High power magnification of mucosa (Fig. 5) showing ciliated epithelium.

layer is composed of clear high columnar cells. The connective tissue is dense and fibrous, and near the surface, it is infiltrated in many places by lymphoid and polyblastic cells.

COMMENT

In view of the arrangement, in almost typical fashion, of all the histologic elements that form the trachea, there seems to be no escape from the conclusion that the malformation was of tracheal origin.

Congenital fistulas of the neck are lined by all possible varieties of epithelium, and smooth muscle, and mucous glands are found in the walls of these fistulas. In no recorded instance, however, have I been able to find any notation regarding the presence of cartilage, such as has been described in the case under discussion, and no one has described an arrangement of epithelium, connective tissue, muscle tissue, mucous glands and cartilage, laid down exactly as they are in these sections.

After a most patient search of the literature had failed to disclose an analogous instance, the opinion of Prof. Ludwig Pick was sought.

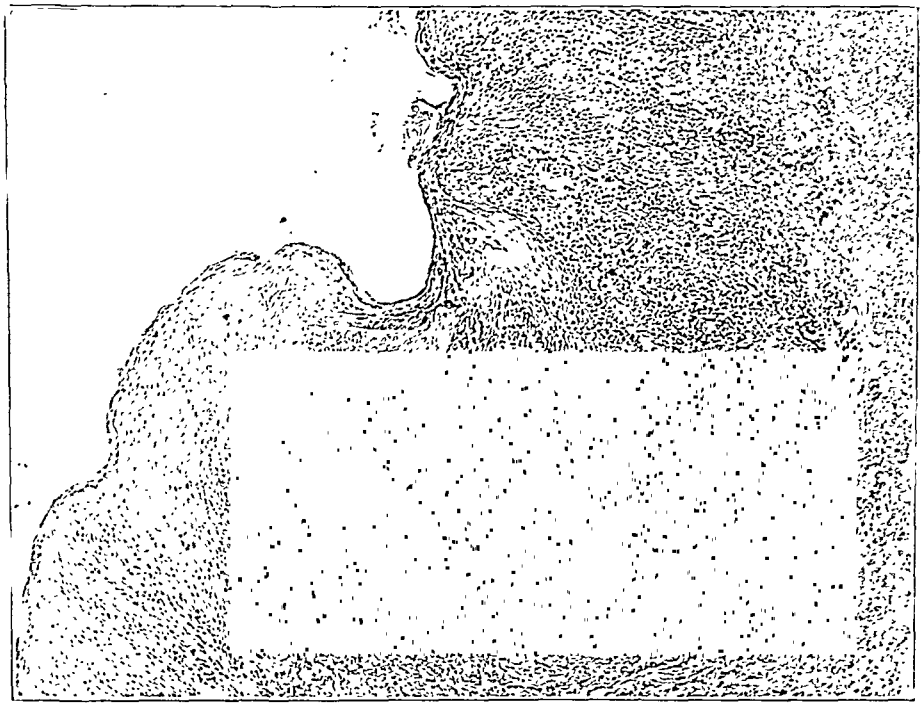

Fig. 7.—Low power magnification of wall of fistulous tract.

He kindly went through the literature, also without finding an analogous instance, and reported that basing his opinion on the microscopic sections he would state unqualifiedly that the malformation was tracheal in origin.

The explanation of the formation of such a fistula as has been described must of necessity be more or less hypothetical, but it is herewith appended as a matter of record: An anomalous budding process takes place at some point on the ventral or lateral aspect of the primitive trachea. As the primitive trachea develops into its definitive form, the anomalous sprout grows downward in a plane anterior

to the sternum. Pick suggests that this is not a budding process, but rather should be interpreted as a double tracheal anlage, with the accessory trachea taking a course anterior to the sternum. At the point of budding or division, the anterior branch loses its connection with the foregut (from which the tracheal and lung anlage developed), becomes closed off, and gradually dilates to cystic proportions. The cyst stretches the overlying skin in the midline. Finally, rupture occurs, establishing a fistula, and resulting in skin retraction in the shape of the folds, or possibly teats, as in the present instance.

DIVERTICULA OF THE JEJUNUM

WALLACE I. TERRY, M.D., AND FREDERICK R. MUGLER, M.D.
SAN FRANCISCO

This case is reported because of the rarity of diverticula of the jejunum.

REPORT OF CASE

A woman, aged 59 years, complained of symptoms typical of duodenal ulcer, which had been present for only a few months and were gradually increasing in intensity. She had been constipated for years. She was of medium stature, well nourished, but not obese. Her weight had remained constant for several years. She had had the ordinary diseases of childhood and had borne three children. Fifteen years before the present complaint, while living in one of the Southern states, she had had amebic dysentery and had been treated in a hospital for six weeks with apparent cure. The clinical diagnosis of duodenal ulcer was confirmed by roentgenogram and later at operation. These roentgenograms have since been carefully studied, but they show no evidence of jejunal diverticula.

At the operation, Jan. 24, 1917, in picking up the jejunum, preparatory to performing a posterior gastrojejunostomy, five diverticula of the jejunum were discovered. Two of these were about 2 cm. long by 1.5 cm. wide, and the other three were smaller. All were ovoid in shape. They were from 8 to 16 cm. apart, beginning about 15 cm. below the duodenojejunal flexure, and all were on the concave side of the jejunum, but not between the layers of mesentery. There seemed to be a definite relation between the blood vessels and the diverticula in that the larger diverticula had rather large blood vessels running over them and the smaller ones looked as if the blood vessels pierced their apexes. There was a fine weblike film of adhesions between the convex surface of the jejunum at its upper part and the gastrocolic omentum, but these adhesions were not connected with the diverticula. The two larger diverticula were inverted into the lumen of the intestine, using fine iodized catgut, and the smaller ones were left undisturbed. A posterior gastrojejunostomy was then performed, employing a portion of the jejunum above the diverticula.

Recovery from the operation was prompt, and the patient returned to her home in Oregon. She remained perfectly well until August, 1918, more than a year and a half after the operation, when she developed an acute intestinal obstruction, which necessitated an operation. Dr. Warren Hunt of Klamath Falls, Ore., has kindly written us that he found this condition:

"The bowel obstruction was caused by an irregular enterolith filling the lumen of the upper portion of the jejunum. This was broken up without opening the bowel, and subsequently passed, resembling yellow shale. The mass formed in one of the diverticula discovered in the first operation." The patient has since remained well.

REPORTS OF THE CONDITION IN THE LITERATURE

A rather careful search of the literature has revealed but nineteen cases of jejunal diverticula. It is, however, possible that in some of

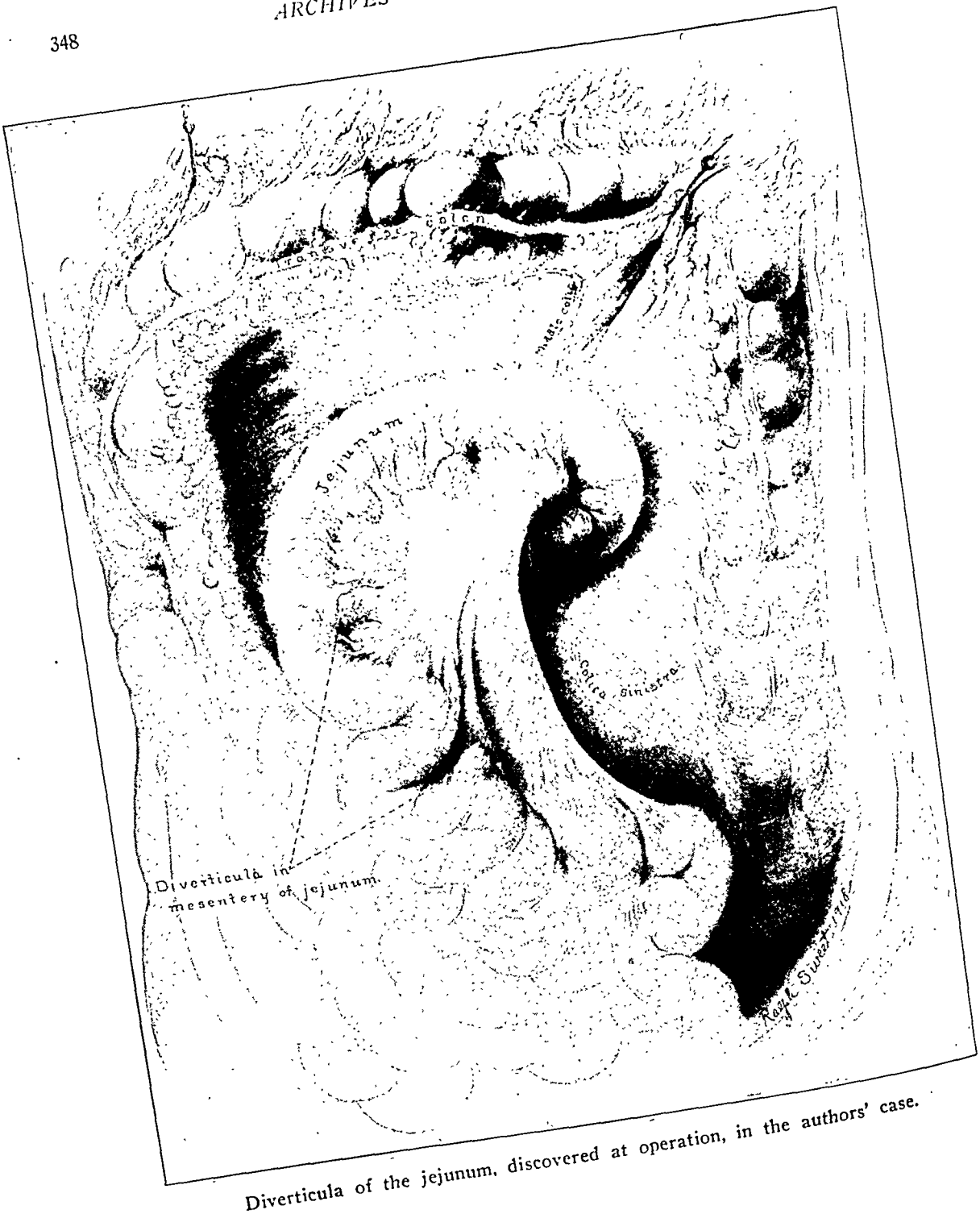

Diverticula of the jejunum, discovered at operation, in the authors' case.

the cases reported as diverticula of the small intestine, the jejunum was involved, but when nothing definite has been stated they have not been included in our list.

That diverticula may occur in any part of the intestinal tract is a well established fact. Their frequency is greatest in the colon; they are less frequent in the ileum and duodenum, and least frequent in the jejunum and rectum. The etiology is not well understood. Cachexia, constipation, senility, obesity, a primary state of adiposity and subsequent wasting, pressure from within, traction from without, weak places at the mesenteric border, due to penetration by the large vessels, muscular deficiency of the intestinal wall and many others have been mentioned as etiologic factors contributing to the formation of these diverticula.

CLASSIFICATION OF DIVERTICULA

Diverticula are classified as congenital and acquired, true and false. In true diverticula, all of the intestinal coats are present, whereas the false type are hernial protrusions of the mucosa through the muscularis, carrying the serosa as a covering. The congenital diverticula are usually true and the acquired are usually false diverticula, but exceptions to this rule have been found. It seems probable that a congenital true diverticulum, if subjected to long continued distention, would increase in size, the muscularis would atrophy and rupture, and thus it would be converted into a false diverticulum. Meckel's is the most common congenital diverticulum. It is usually on the convex surface of the lower ileum, whereas the majority of other diverticula appear near the mesenteric border or between the layers of mesentery. The most probable explanation for the occurrence of acquired diverticula on the concave surface of the intestine is the weakening of the walls by the penetration of the blood vessels at the mesenteric border.

That the jejunum is less subject to diverticula than the ileum is probably due to three factors: the fluid content of the jejunum, its thicker wall and its larger lumen.

CASES OF JEJUNAL DIVERTICULA REPORTED IN THE LITERATURE

The appended cases of jejunal diverticula are those that we have been able to find in the literature:

Sir Astley Cooper,[1] in 1844, reported a case of multiple diverticula of the jejunum, situated between the layers of mesentery and varying in size from a pea to a walnut. They were found postmortem in a man, aged about 50, who died of general dropsy.

---

1. Cooper, Astley: The Anatomy and Surgical Treatment of Abdominal Hernia, Philadelphia. 1844, p. 364.

Cornillon,[2] in 1869, reported a case of a single diverticulum, the size of a hen's egg, found near the middle of the jejunum. It was discovered, at necropsy, in a woman, aged 30, who died following placenta praevia. No further details are given.

Osler,[3] in 1881, reported the case of a man, aged 65, who died of an acute enteric attack with melena. He had suffered for years with rumbling noises in the abdomen, particularly after eating. Necropsy disclosed fifty-three diverticula in the jejunum on the mesenteric border. "They ranged in size from a cherry to a large apple." They were not connected with the enteric trouble which caused death.

Moore,[4] in 1883, described a specimen, obtained at necropsy, of jejunum in which there were three diverticula and also a congenital stricture at the commencement of the jejunum. The diverticula were 1 inch in diameter and were situated on the mesenteric side. The walls consisted of all the intestinal coats and were not mere hernial protrusions. There had been no symptoms produced by these diverticula. The specimen was obtained from a man, aged 40, who died of bronchitis.

Buzzi,[5] in 1885, reported a single diverticulum 1 meter from the upper end of the jejunum on the mesenteric side. It measured 23 by 32 mm. and had all the intestinal coats. It was found, at necropsy, in a man, aged 77, who died following perforative peritonitis from pyloric carcinoma. Buzzi considered this a misplaced Meckel's diverticulum.

Buchwald and Janicke,[6] in 1887, reported a case found at operation in a boy, aged 6, with obstruction of the bowels due to a cystic tumor of the jejunum. After resection of the bowel, it was found that the lining of the cyst was continuous with the mucous membrane of the jejunum by a narrow slit which was sealed. The opening was on the mesenteric side.

Virchow,[7] in 1890, reported a necropsy specimen of multiple diverticula of the jejunum and also some in the ileum. The jejunal diverticula were the size of an egg and all were on the mesenteric side

2. Cornillon: Diverticulum de l'intestin grêle, Bull. Soc. anat. de Par. **44**: 525, 1869.

3. Osler, William: Notes on Intestinal Diverticula, Ann. Anat. and Surg. **4**:202-207, 1881.

4. Moore, N.: Diverticula of the Small Intestine, Brit. M. J. **2**:920, 1883. Tr. Brit. Path. Soc. **25**:202, 1884.

5. Buzzi: Ueber einen Fall von angebornem Divertikel des Jejunums, Arch. f. path. Anat. **100**:357, 1885.

6. Buchwald, A., and Janicke, O.: Ueber Darmcysten (Enterokystome) als Ursache eines completen Darmverschlusses, Deutsch. med. Wchnschr. **23**: 868, 1887.

7. Virchow, Rudolf: Verhandl. d. Berl. med. Gesellsch., 1890, p. 116.

with rather large opening into the bowel. All were hernias through the muscularis. The body was that of a lean, old man.

Edel,[8] in 1894, reported a necropsy specimen of seven diverticula of the jejunum varying in size from a walnut to an apple. All were located on the mesenteric side and followed the course of the blood vessels. Other diverticula were present in the colon. The woman was 73 years of age.

Seippel,[9] in 1895, reported a case of multiple jejunal sacculations.

Hansemann,[10] in 1896, reported a necropsy specimen from a boy, aged 14. There was a single diverticulum in the jejunum on the convex surface of the bowel and to its apex was attached an accessory pancreas. He also reported the case of a man, aged 85, who died of pneumonia. There were 400 small diverticula in the small intestine, most of them in the jejunum. All were located near the mesenteric attachment and at those places where blood vessels penetrated the muscularis.

Grassberger,[11] in 1897, reported a necropsy specimen from a man, aged 73. There was a diverticulum in the stomach, two in the duodenum, many in the colon, and many pea sized and thirteen walnut sized diverticula in the upper jejunum. All were on the mesenteric side of the bowel and were without muscularis. The cause of death was a perforating ulcer of the duodenum.

Nicholls,[12] in 1899, reported a necropsy specimen from a woman, aged 64. There were fifty diverticula in the jejunum varying in size from a dried pea to a walnut. All were at the mesenteric attachment and were hernias through the muscularis. The woman had had double inguinal hernia for thirty years and chronic bronchitis for twenty-five years. She was of spare build.

Fischer[13] reported, in 1900, a museum specimen of a piece of jejunum containing a diverticulum, the size of a bean and within the layers of the mesentery. It communicated by a small opening with the bowel. The muscularis was absent.

---

8. Edel, M.: Ueber erworbene Darmdivertikel, Arch. f. path. Anat. **138**: 347, 1894.

9. Seippel: Ueber erworbene Darmdivertikel, Diss., Zurich, 1895.

10. Hansemann, D.: Ueber die Entstehung falscher Darmdivertikel. Arch f. path. Anat. **164**:400, 1896.

11. Grassberger, R.: Ein Fall von multipler Divertikelbildung des Darmtractes, complicirt mit peptischem Geschwür am Pylorus, Wien. klin. Wchnschr **10**:149-151, 1897.

12. Nicholls, A. G.: Path. Spec. Multiple Diverticula of the Small Intestine, Philadelphia M. J. **3**:700-701, 1899.

13. Fischer, M. H.: False Diverticula of the Intestine. J. Exper. M. **5**:333. 1900.

Taylor and Lakin,[14] in 1910, reported a necropsy specimen from a woman, aged 68, who died of pneumonia. There were large numbers of diverticula in the upper jejunum varing in size from a pea to an unshelled walnut. They projected between the layers of mesentery and all had well defined mouths into the bowel. There were also numerous pouches in the colon.

Latarjet and Murard,[15] in 1914, reported a necropsy specimen from a woman, aged 50. There was a single diverticulum in the jejunum, 23 cm. below the opening of the common duct. It was 2.5 by 5 cm. in size and communicated with the bowel by a large opening. It was on the mesenteric border and in the course of the blood vessels.

Braithwaite [16] reported, in 1918, a necropsy specimen from a man, aged 45. There were two diverticula in the second part of the duodenum, two or three in the first part of the jejunum and about sixty in the next yard of jejunum. All were situated along the mesenteric attachment. The largest had a capacity of 25 c.c.

Case [17] reported, in 1920, multiple jejunal diverticula in a man, aged 61, who complained of "indigestion." Roentgen-ray examination showed a diverticulum located apparently a few centimeters below the duodenojejunal junction. At operation, about a dozen diverticula were found in the upper jejunum—one was 5 cm. in diameter. They were between the folds of mesentery. The patient recovered after a resection of the involved area. Case [17] also reports the case of a man, aged 73, in whom twenty-five or thirty sacculations in the jejunum and upper ileum were diagnosed by roentgen-ray examination. The diagnosis was later confirmed by operation. There were also multiple diverticula in the pelvic colon.

Terry and Mugler in the case here reported of a woman, aged 59, found five diverticula of the upper jejunum at an operation for duodenal ulcer. All were located on the mesenteric side; two of them were treated by inversion. A later operation was performed for obstruction due to enterolith forming in a diverticulum.

COMMENT

Analysis of these twenty cases demonstrates these facts: There were twelve males and six females (sex was not given in two cases). The ages varied from 6 to 85 years—only three patients were less than

14. Taylor and Lakin: Perforative Peritonitis Originating in Pouches of the Large Intestine, Lancet **1**:495, 1910.

15. Latarjet, A., and Murard, J.: Les diverticules de l'intestin grêle, Lyon chir. **40**:425, 1914.

16. Braithwaite, V.: A Case of Diverticulitis of the Small Intestine, Guy's Hosp. Gaz. **32**:77, 1918.

17. Case, J. T.: Diverticula of Small Intestine, Other Than Meckel's Diverticulum, J. A. M. A. **75**:1463 (Nov. 27) 1920.

40 and fifteen were more than 40 (age not stated in two cases). The diverticula were single in six cases, multiple in fourteen. In one case, a single diverticulum was present on the side of the jejunum opposite the mesentery, and this was thought to be due to traction from an accessory pancreas. In sixteen cases, the diverticula were on the mesenteric side (location was not stated in three cases).

It is interesting to note that only three patients presented symptoms due to the diverticula. The two cases reported by Case are of great interest, inasmuch as a correct preoperative diagnosis was made in both. In fifteen cases the diagnosis was made at necropsy.

240 Stockton Street.

FRACTURE REDUCTION AND FIXATION WITH A SPECIALLY DESIGNED BAND

ASA W. COLLINS, M.D.
SAN FRANCISCO

The treatment and repair of fractures form one of the most important and fascinating fields of surgery. It is probable that the earliest surgery had to do with fractures, for the weapons employed (clubs, slings, etc.) frequently caused them. The early Egyptians treated fractures successfully, and some of the splints employed by them would do credit to a surgeon of the present day. Apparently, the open operation was even employed by the ancients. The Incas of Peru developed a technic which gave some remarkable results.

Asepsis made possible an extensive employment of the open operation, and its use was stimulated by the introduction of the roentgen ray, which enabled the patient to see the position of the fragments, thus causing him to be dissatisfied with an imperfect anatomic result, although the function might be good. The desire of the patient for a perfect anatomic result has caused an extensive use of the open method of reduction.

I do not agree with those who, discarding the older and more conservative methods, believe that all fractures should be operated on, but I do believe that in certain types of fractures the open method will give better results in a shorter time than the simple, or closed method.

In certain fractures of long bones, associated with great comminution, a wide separation of the fragments by muscular pull, or the interposition of soft parts (muscle, nerve or periosteum), the open operation finds its fullest justification, for it may be impossible to secure close apposition of fragments, without which anatomic repair does not occur, unless an operation is resorted to.

Many technics and procedures have been introduced as the open operation has become more extensively employed. Nails, screws, silver wire, bands, plates and bone grafts were used—and each had its ardent advocate and supporter. Bad results, due to errors in technic, were certain to follow the extensive use of the open method. Failures were not infrequent, and more or less well deserved criticisms have been directed against the indiscriminate use of this method of treating fractures.

The report of the British committee which was appointed to determine the results of the two methods of treatment would seem to demonstrate that in children at least the two methods give approxi-

mately the same results, for the functional results were good in 90.5 per cent. of 1,017 fractures treated by the closed method, and were good in 93.5 per cent. of the sixty-four fractures reduced by operation.

Although the functional result may be good in a case in which the anatomic result is relatively poor, a good anatomic result is the best guarantee of a good functional result.

The mortality of the operative method of reduction is so small that this cannot be raised as an objection to the method. A greater percentage of good results is obtained at all ages by operative reduction. If there are no objections to the method itself, the question naturally arises by what method (plate, wire, band or bone graft) are the best results obtained. Before discussing this question it will be of advantage to consider the physiology of bone.

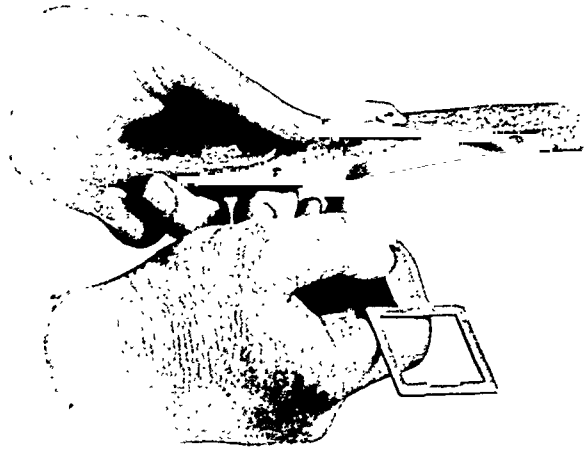

Fig. 1.—As a first step, the small end of the band is bent and passed around the bone, beginning underneath.

REPAIR OF FRACTURED BONE

Physiologically, bone should be regarded as a definite organ adapted to the bodily needs and serving its function by conformity to definite functional laws. Consequently, when an injury is sustained, function is impaired to a greater or less degree, and the bone, like any other organ, seeks to regain the normal by the processes of repair.

Just what factors are involved in bone repair after fracture are still not definitely established; but the fact that the periosteum is intimately connected with the process is so thoroughly established that added injury to this structure has been regarded as one of the chief objections to mechanical devices for fixation.

The periosteum lies close to the bone, and in the vast majority of cases sustains some injury when the underlying bone is injured. The

blood vessels of the bone proper, the periosteum and the medullary cavity are all most intimately related. True vessels, not capillaries (Stohr), enter the bone and pass from the periosteum through the haversian and Volkmann canals to the inner surface of the bone where they communicate with the blood vessels of the marrow. The marrow is supplied by relatively large nutrient arteries, which not only nourish the firm cortical substance, but also ramify in the marrow and form a large, vascular network.

It is obvious, therefore, that any device which would impair the function of the periosteum would seriously inhibit the nutrition of the

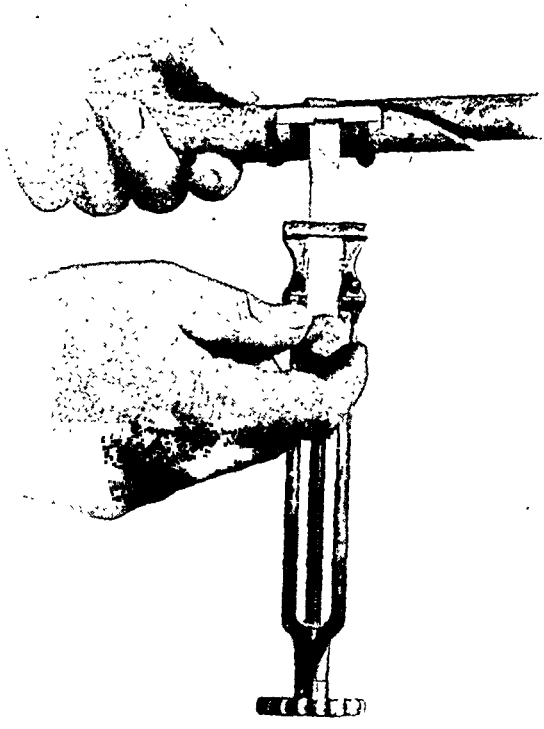

Fig. 2.—The small end of the band is passed through the window in the band and into the instrument. Before applying the instrument be sure that the screw shown between the thumb and forefinger is unscrewed so that the end of the band will slide in where it can be fastened by tightening the screw, also be sure that this part is down close to the hinge.

bone. It is not so much a question of whether the periosteum is osteogenetic or not, but whether a band which would constrict the periosteum would really interfere with bone repair and callus formation.

The brilliant work of Ollier, Albee, MacEwen,[1] Brooks and Phemister has contributed to our knowledge of this subject; the final work,

1. MacEwen, William: Growth of Bone, Glasgow, Maclehose, 1912.

however, was done by MacEwen, who has definitely established that the periosteum is not essential to bony repair and that, moreover, of itself it has no true rôle in osteogenesis.

MacEwen's work has shown that the osteoblast has its own intrinsic power of proliferation and that, furthermore, diaphyseal growth and repair can take place without the presence of the periosteum. To the latter, he ascribes the function of a limiting membrane with some nutrient rôle, analogous entirely to the capsule of the liver, spleen, etc.

He has further shown that bone, when injured, throws out osteoblasts from the medullary cavity; and that these may, without ever going

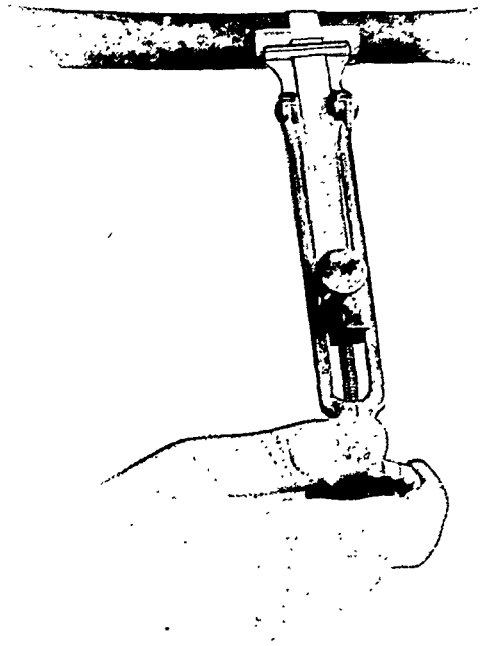

Fig. 3.—Tightening the band forces the fragment into position. Extension and manipulation of the limb may be accomplished at this time if necessary.

through the cartilage stage, repair and make good the damage. Agreeing fully with these views, I conducted my own series of experiments with the view of ascertaining whether a band which would encircle the bone would interfere with bone repair, and of determining whether or not it was of any import if the band was applied above or beneath the periosteum.

Believing that the Lane plate was fundamentally wrong, I devised a band which would not encircle the bone at any one point in the circumference, and which at the same time would give a perfect apposition of

fragments without any foreign body being introduced into the bone substance proper.

A priori, it is clear that a band would give better mechanical support than a plate alone, which is laid on one side of the bone. A plate covers a large surface of the periosteum, is bulky and depends for its strength on the screws driven into the cortex.

These screws at once act as a violent irritant and instead of hastening repair, simply prolong that process by adding an extra task, namely, the extrusion or removal of the irritating foreign body. The screws become loosened and as a result the plate's grasp is weakened, and it then merely causes a *locus minoris resistantiae,* infection ultimately developing. That this is a most serious disadvantage is borne out by the figures of Thomas, who collected 450 cases in which the Lane plate had been applied. In 48 per cent. of these, the plate had to

Fig. 4.—When drawn as tight as possible, the band is locked by pushing on the instrument, which bends the band on itself.

be removed owing to suppuration or other causes. Another disadvantage is that if the bone is angulated or roughened, the plate does not lie evenly, and the callus envelops or includes it with difficulty. The same objection applies in part to bands, where the bone is encircled in one circumference.

If the periosteum has a nutrient function, it is apparent that close constriction at any one point should, if possible, be completely avoided. The Parham [2] band is subject to this objection, as are the bands devised

2. Parham, F. W., and Martin, E. D.: New Device for Treatment of Fractures, New Orleans M. & S. J. **66**:451 (Dec.) 1913. Parham, F. W.: Circular Constriction in the Treatment of Fractures of the Long Bones, Surg., Gynec. & Obst. **23**:541 (Nov.) 1916. Parham, F. W., and Martin, E. D.: Device for Treatment of Fractures, Modern Hospital **6**:75 (Jan.) 1916.

Lund, F. B.: Parham and Martin Band in Oblique Fractures, Surg., Gynec. & Obst. **23**:545 (Nov.) 1916.

by Milne [3] of London, Lambotte [4] of Brussels, and to a lesser degree those devised by Rexwald Brown [5] of Santa Barbara.

In wiring, the bone is encircled in one circumference. Wire injures by constricting, and mechanically it immobilizes the least of all, and any movement of the fragments causes the wire to cut into the solid cortex, producing a sawing effect.

Animal ligatures are less objectionable for fixing fractures than the devices just mentioned but they are applied with difficulty, they frequently carry infection and are open to the same mechanical objections as the wire and continuous circular band devices. Also their tensile strength is insufficient.

Theoretically, an autogenous bone transplant or a sliding graft should be ideal; but in a great many cases, excessive comminution of

Fig. 5.—The screw that tightens the band should be unscrewed. A little lateral motion back and forth will force the instrument away from the band, so that the band may be cut with a pair of heavy scissors.

the parts and the location of the fracture will prevent the use of this method without extensive dissection and often damage to the soft parts.

It is axiomatic that the simplest procedure involving the least destruction of tissue and approximating closely the normal anatomic architecture should be the method of choice, and it is this point which in many cases contraindicates extensive dissection and bone grafting.

3. Milne, Robert: Device for Fixation of Fractures of Long Bones, Murphy Clinics **2**:229 (April) 1913.

4. Lambotte, quoted by Putti, V.: Un nuovo metodo di osteosintesi, Clin. Chir., Milan **22**:1021 (June 30) 1914.

5. Brown, Rexwald: Fracture Clamp for Open Treatment of Fractures. Surg., Gynec. & Obst. **13**:453 (Oct.) 1911.

With these views in mind, therefore, I devised a band which not only avoids the difficulties herein mentioned, but which also has certain distinct advantages which, I believe, will recommend its use and promote its application.

DESCRIPTION OF BAND AND APPLICATOR

The band and instrument for its application have been described in previous articles.[6] It is made of silver, nickel and copper, and is heavily plated with silver. The design is best shown in the illustrations, and, as can be seen, is quite thin, being of 26 standard gage with the two cross-bars of twice the thickness. The application is very simple, as is demonstrated by the description that accompanies each illustration.

Fig. 6.—The end should be bent over with any suitable instrument.

EXPERIMENTAL STUDIES

Extensive experiments were carried out to obtain a metal or alloy which would be well tolerated by the tissues and yet possess the proper physical properties, namely, tensile strength and ductility.

The maximum amount of strength with the least amount of material is what has been obtained.

This band, then, theoretically possessed the desired requisites for a satisfactory method of reducing and holding a fractured bone. Experi-

6. Collins, Asa W.: Fenestrated Band in Fractures of Bone, Surg., Gynec. & Obst. **29**:513 (Nov.) 1919; New Fracture Band, J. A. M. A. **74**:950 (April 3) 1920.

ments were conducted to test the soundness of my views regarding the device as well as to determine: (1) the metal best suited to the purpose; (2) the effect on callus formation; (3) the effect on bone with periosteum; (4) the effect on bone without periosteum; (5) the effect on adult bones; (6) the effect on adolescent bones, and (7) the mechanical efficiency of the bands as an immobilizing device.

Experiments were made on seventy-five rabbits weighing between 1½ and 2½ pounds and about one-third grown. The left femur was used in nearly every case. The rabbits were all carefully shaved and prepared antiseptically, and there was no infection in any case. All rabbits were etherized and a longitudinal incision was made on the outer side of the thigh. The wounds were closed with two plain catgut sutures. No external splints were applied, the wound being dressed with compound tincture of benzoin and cotton. When bands were used in these experiments, they were of the *fenestrated* type, unless otherwise specified, and were made of metal described in this article, also the bands used were much larger in proportion than those used in human beings. Roentgenograms were taken of all the rabbits soon after the operation, and again several months later when the rabbits had reached their full size. These roentgenograms were large enough to include both femurs.

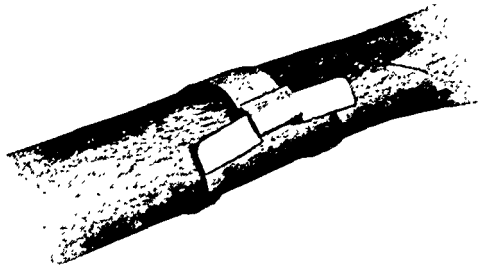

Fig. 7.—The application of the band completed.

EXPERIMENT 1.—Five rabbits were etherized. About a 1 inch strip of the periosteum, 1 inch wide, was completely removed from the center of the shaft of the femur, the bone being traumatized with a sharp instrument, after which a band was applied.

Result.—Six months later roentgenograms demonstrated the band completely covered with callus. The bone with the band appeared longer and larger in every diameter. These rabbits were killed and the bones were removed. The bands were not seen, being covered with bone, and there appeared to be periosteum over the callus.

EXPERIMENT 2.—Six rabbits were operated on. The left femur was fractured longitudinally, splitting the shaft from one epiphysis to the other. This

was easily accomplished by using a chisel and hammer, and the bands were applied in the center of the diaphysis over the periosteum.

Result.—Five months later roentgenograms demonstrated the bands covered with a large callus; and the bones when removed were found to be larger than the control bone on the right side. The bands were completely enveloped in the callus.

EXPERIMENT 3.—Three rabbits were operated on. Two bands made of pure copper were applied to incomplete fractures of the diaphysis.



Fig. 8.—A typical case of fracture of the femur in which the Collins band is indicated.

Result.—Four months later when roentgenographed, the bands were found to be covered with callus, but the callus showed a greenish tinge. The bones in these rabbits were found to be larger in every diameter than the control bone.

EXPERIMENT 4.—Eight rabbits were etherized. The femur was fractured longitudinally at the lower end of the diaphysis close to the epiphyseal line, and bands were applied very tightly.

Result.—When the rabbits were killed, five months later, the bone was found to be longer and wider in every diameter than the control bone and the bands were almost completely covered with a callus.

EXPERIMENT 5.—In four rabbits the diaphysis was fractured obliquely, on two a 22 carat gold band was applied, and on two a silver band was applied.

Result.—Eight months later, when the rabbits were killed (one rabbit died of snuffles three months after the band was applied), there was complete union, the band was covered with callus and the bone was larger and longer than the control bone.

EXPERIMENT 6.—Twelve young albino rabbits that weighed from 1 to one-quarter pound were operated on. Bands were applied to incomplete fractures of the diaphysis.



a *b*

Fig. 9.—Fracture of the femur in a boy, aged 12 years, who was shot with a 32 caliber automatic pistol: *a*, appearance of femur sixteen days after injury; *b*, appearance of the femur three months after the application of the band. The child now has perfect function of the leg. It is for use in fractures of this kind that the Collins band is best suited.

Result.—Four months later the rabbits were killed. They weighed from 5 to 6 pounds. The bones had grown to twice the length that they were when the rabbits were operated on, and were found to be 3 per cent. longer than the control bones on the opposite side. The band was completely covered with callus. The bones were also wider in every diameter.



Fig. 10.—Right and left femurs of rabbits operated on four months before being killed, showing the comparison between the bone with the Collins band and the control bone of the opposite side. The left femur was fractured when these rabbits were half grown and weighed about 2 pounds.

EXPERIMENT 7.—Two rabbits were used. Two Parham bands were placed on the right femur of each of these rabbits about the middle of the diaphysis, and about one-half inch apart on a complete fracture.

Result.—One month later, there was preternatural mobility of the left femur. These rabbits were killed, and it was found that there was necrosis of bone between the bands.

EXPERIMENT 8.—Fenestrated bands were applied to the shaft of the left femur in four rabbits.

Results.—Four months later, it was found that both bands in each case were completely covered with the callus and that there was no necrosis.

EXPERIMENT 9.—Fenestrated bands were applied to the shaft of the left femur in four rabbits.

Result.—Four months later it was found that both bands in each case were completely covered with callus and that there was no necrosis. The bone was about 3 per cent. longer than the control bone.

EXPERIMENT 10.—Four rabbits with incomplete fracture of both right and left femurs were used.

Result.—These rabbits were killed several months later, and it was found that both bones were the same size and the bands were covered with callus.

COMMENT

This series of experiments, while not entirely conclusive or final, warranted using the band on the human subject with these results:

Case reports gathered to date include more than 100 fractures in which the band has been used, and the humerus and femur have been operated on in all but seven cases. The band has been removed in eight cases. In four of these the band was removed because the operator objected to allowing any foreign material to remain in the tissues. Some difficulty was experienced in their removal, as the band was found firmly embedded in a callus. The other four cases were compound fractures. The oldest patient operated on was a man, aged 74, with an oblique fracture of the lower end of the humerus. The youngest was a boy, aged 16 months, with a very long oblique fracture of the femur, the fragments being widely separated.

Infection occurred in five cases, but it is a satisfaction to state that in all five cases, the fractures were compound. However, in all of these cases there was a final good result with good apposition. The particular thing that characterizes all the cases is the large callus formation surrounding the band. It seems to stimulate callus formation as no other internal splint does.

CONCLUSIONS

From these cases, therefore, I draw these conclusions, favorable to the use of the fenestrated band:

1. It is more quickly applied than screw plates, bone grafts, kangaroo tendons, medullary dowels, etc.

2. It furnishes sufficient force under easy control to bring the parts into apposition and is of sufficiently strong mechanical construction to immobilize them.

3. It provides a simple means for fastening without disarranging the tension or position of the band or the fragments.

4. Through its use, a circle of unyielding pressure at any one point is avoided; and the band adapts itself to an uneven flaring surface.

5. The band is compatible with a good callus formation.

6. It has no deleterious effect on growing bone, but on the contrary, it stimulates growing bone. (Further experiments to establish just why this should occur are now in progress.)

7. And lastly, it affords greater satisfaction to the operator even in those cases in which normal function might be assured with a lesser degree of coaptation, especially in cases related to accident insurance, the Workman's Compensation Act, damage suits, etc.

Therefore, in view of these facts, the band is presented to the profession as a device which not only has none of the disadvantages of the older methods, but has distinct advantages of its own.

126 Post Street.

PROGRESS IN ORTHOPEDIC SURGERY

FOURTEENTH REPORT OF PROGRESS IN ORTHOPEDIC SURGERY *

ROBERT B. OSGOOD, M.D.; ROBERT SOUTTER, M.D.; MURRAY S. DANFORTH, M.D.; HARRY C. LOW, M.D.; HERMANN BUCHOLZ, M.D.; LLOYD T. BROWN, M.D., AND PHILIP D. WILSON, M.D.

BOSTON

TUBERCULOSIS

Treatment of Paraplegia in Pott's Disease by Puncture of Spinal Abscess.—Calvé [1] believes that paraplegias are less likely to recover under nonoperative treatment in adults than in children. He reminds us that they occur almost exclusively in those cases in which the lesion is located in the dorsal vertebrae, and he thinks the common cause is a pressure on the spinal cord by an abscess situated between the cord and the posterior surface of the vertebral bodies. He considers that laminectomy is too serious an operation to be ordinarily advised, and yet he believes that relief of pressure from the abscess is the important factor in recovery.

After careful dissections, he discovered that a properly curved sound could be introduced through the upper part of the intervertebral foramen just above the intercostal nerve, and placed in contact with the posterior surface of the vertebral body. He determines by neurologic examination the level of the point of pressure, and under local anesthesia makes an incision to the left of the spinous process of the next vertebra above the one selected as the point of puncture of the abscess. Through this

* This report is based on a review of about eighty articles selected from approximately 1,500 titles of papers having to do with orthopedic surgery appearing in medical literature between July, 1917, and July, 1919. References are given to only those articles which have been chosen for report and comment. During the period of the American participation in the recent war there was a necessary interruption in these reports owing to absence in service of several of the editors. On this account the Fourteenth Report covers a longer period of time and is therefore not so contemporaneous as the previous reports have been It is planned to publish future reports more frequently.

1. Calvé: Paris, J. B. Ballière et Fils, 1918.

incision is inserted a sound cannula, 10 cm. long and curved at the end at an angle of 115 degrees. The end of the sound cannula is pushed down until it touches the lamina of the selected vertebra and then moved upward till it comes in contact with the transverse process. By manipulation, as with a urethral sound, the instrument can be gently forced through the dense tissue of the foramen. A trocar is then substituted for the sound, and the abscess is punctured, and if the contents do not flow out they are withdrawn by attaching a syringe. The author states that he has performed the operation three times with no unfavorable results.

[Ed. Note.—Our report of Calvé's article, based on an abstract by Dr. W. A. Clark of Chicago, is too brief to warrant any important favorable or unfavorable criticism. The author's well earned reputation for sound and careful work makes the article at once significant. We are not at all certain that it has been proved that the pressure of abscesses on the cord is by any means always the cause of the paralysis in Pott's disease. The danger also of the puncture of an abscess within the vertebral canal without the possibility of observation cannot be inconsiderable. In the majority of cases which the Editors have observed, the shadow of the abscesses in Pott's disease, as seen in the roentgenogram, extend well beyond the spinal canal, and would seem, therefore, commonly to be approachable outside the vertebral canal. We are not clear as to whether Calvé presupposes a separate abscess within the canal and only approachable through the foramen or by laminectomy. Frazier's exploratory laminectomies in cases of paraplegia dissociated from tuberculous disease of the spine have revealed tuberculous granulation tissue pressing on the dura. In a recent case in the orthopedic ward at the Massachusetts General Hospital, in which an exploratory laminectomy was performed by Dr. Jason Mixter, the existing abscess was in front of the vertebral bodies. Although it was found to communicate with the canal, it was under no tension and did not seem to be causing any pressure on the cord. There was, however, a circumscribed mass of firm tuberculous material posterior to the cord at the apex of the kyphos, adherent to, but outside, the dura, and causing sufficient pressure to stop pulsation. It must be obvious that Calvé's procedure would have in no means solved this particular problem.]

Froelich [2] again calls attention to the recurrence of symptoms under strenuous use in cases of hip joint disease occurring in childhood, but which had recovered with practically normal function. The cases he observed were soldiers who had been accepted as A men. He found some abnormality of the joint with partial destruction by periostoses or

2. Froelich: Rev. de chir., April, 1917.

deforming arthritis, which he states had occu
epiphyseal osteitis, coxa valga or vara, osteomye
had attained a perfect functional recovery. Un
paign these joints became incapacitating. The
the necessity of careful and trained orthopedic

Maragliano[3] reports favorable results from
repair processes in tuberculous disease of the l
periosteal graft removed from the tibia through
head, just to the acetabulum.

[Ed. Note.—The Editors believe that more
be done before the method should be generally
necessary, and careful comparative roentgen-ra
logic and repair processes of the bone before ar
of the graft would seem to be a sine qua non in
of the method.]

Jeanneret[4] believes that he has demonst
prophylactic value of the sun's rays for so-cal
dren and those generally below par. He org
twenty to thirty children of this sort in Basel,
with them to the shore of a nearby lake. Here
in games and gymnastic exercise, clothed only in
methods were carried out, and Jeanneret cons
from the water of the lake greatly enhanced the
The results have been unexpectedly good. In t
average gain in weight was 825 gm., and in c
Only four children of the 200 failed to improve.
colder, less clothing was removed. Jeannere
exercises in schools be given with the trunk b
whenever weather conditions permit.

Chenut[5] adds his testimony to the value
which he formerly considered "surgical tubercu

Berntsen,[6] in twenty-seven patients under tr
by the carbon arc light, has made a careful st
examinations conducted at regular intervals re
were not within the range of normal physiologi

SYPHILIS OF BONES AND JO

Caronia and Marinucci[7] have observed bon
persons suffering from inherited syphilis. Th

3. Maragliano: Riforma med., May 17, 1919.
4. Jeanneret: Rev. méd. de la Suisse Rom., April
5. Chenut: J. de méd. de Bordeaux, May 25, 19
6. Berntsen: Hospitalstid. April 24, 1918.
7. Caronia and Marinucci: Pediatra, December.

tion very common and often unrecognized. In 72 per cent. of seventy children between the ages of 2 and 13 years with tuberculous caries of the spine or other tuberculous lesions of the bones or joints, they found inherited syphilis. They state that the combined treatment was very satisfactory.

Deromps [8] quotes Ménard's warning that many cases of supposed tuberculous lesions of the long bones are in reality manifestations of inherited syphilis and thus exceptionally amenable to treatment. The roentgen rays reveal the syphilitic nature of the trouble and demonstrate its subsidence under treatment. Milian has published an instructive case of the kind with pronounced retrogression of the periosteitis under neo-arsphenamin treatment, notwithstanding the old chronic nature of the bone trouble and its enormous extent. A similar case is described in this article, with roentgenograms showing the enlargement of the femur, its diameter throughout its entire length being approximately the same as in the condylar region. In the other leg, only the lower end of the femur showed enlargement. The patient was a young woman of 20, of an infantile aspect, who had had pains in the thigh for nearly six months. At the age of 5 years, there had been opacity in the cornea, which later had retrogressed. At 15, there had been pains in the thigh for nearly a year, but they then subsided for four years, after which they returned more violently than ever. The Wassermann reaction was positive, and under neo-arsphenamin great improvement followed. The patient was unable to tolerate mercuric iodid. Such cases call for an early diagnosis and early and protracted treatment, regardless of the extent or duration of the lesions. The main thing is not to be misled into assuming the nature of the trouble to be tuberculous.

Wallace [9] also pleads for a more careful differential diagnosis of bone syphilis. He discusses at length the symptoms and signs of the condition, and has been impressed with the fact that these cases are often mistaken for the pyogenic forms of osteomyelitis, and are submitted to unnecessary operation.

Surgical procedures are to be the more regretted in these cases because, as Hotz [10] has pointed out, the bone lesions of inherited syphilis usually repair very quickly under specific treatment, especially in infants. In some of his cases, perfectly normal roentgenograms were obtained after ten weeks. The lime salt deposit beneath or in the periosteum seems to disappear more slowly than does the osteochondritis. The Wassermann reaction may become negative before the roentgen ray demonstrates recovery, or may remain positive after all other signs have disappeared.

---

8. Deromps: Ann. de méd., Sept.-Oct., 1917.
9. Wallace: J. Orthop. Surg., May, 1919.
10. Hotz: Cor.-Bl. f. schweiz. Aerzte, May, 1918

The persistence of the new periosteal formation is pointed out also by Fraenkel,[11] who looks on it as an attempt at repair. He has observed it to appear first during the healing of the osteochondritis under antispecific treatment, and when it was present to a slight degree he has seen it increase during the early stages of the treatment.

Castex [12] considers the bifurcation of the spinous processes of the twelfth dorsal or first lumbar vertebra as pathologic, and says he has observed it only in cases of inherited syphilis.

[ED. NOTE.—The Editors feel fairly certain that inherited syphilis especially is too often unrecognized in America, and its association with bone tuberculosis which Caronia and Marinucci believe common in children is, if true, an important matter as regards treatment. Castex' sign needs confirmation. Our impression is that we have observed this bifurcation of the spinous processes of the twelfth dorsal or first lumbar in cases in which there was no question of inherited syphilis, and we doubt its positive diagnostic significance.]

ARTHRITIS

Poynton [13] reports again his repeated success in causing not only multiple arthritis, but also pericarditis and endocarditis in various species of animals by injection of streptodiplococci isolated from cases of acute rheumatism. He believes that cold and dampness may predispose and may prolong the course, but that food has little influence. He shows how important it is to recognize the fact that our treatment of heart lesions ought to begin by preventing the occurrence of infectious diseases in children and in gaining control over them early before the cicatricial heart changes have taken place.

Lillie and Lyons [14] make a report on 200 cases of myositis and arthritis, a year after tonsillectomy had been performed. They think the operation is justified in all very early cases, and state that there was marked improvement in 79 per cent. of the cases. Dental infection they believe to represent another important etiologic factor. Some improvement and occasionally complete recovery followed the operation in chronic, long-standing cases. They believe that the size of the tonsil is no index as to the possibility of its being a focus of disease, and advise the complete operation in all cases.

Nalf [15] believes in the efficacy of intravenous injections of 8 to 10 c.c. of a 10 per cent. solution of peptone, with or without 0.5 mg. of epineph-

11. Fraenkel: Fortschr. a. d. Geb. d. Roentgenstrahlen., **23**: 1915.
12. Castex: Prensa méd. Argentina, Jan. 20, 1919.
13. Poynton: Arch. méd. belges., November, 1918.
14. Lillie and Lyons: J. A. M. A. **72**:1214 (April 26) 1919.
15. Nalf: Presse méd., Sept. 23, 1918.

rin in rebellious cases of acute articular rheumatism or septicemia caused by the staphylococcus or the hemolytic streptococcus. He combines this with the usual sodium salicylate treatment. If there is reason to anticipate a severe reaction, he dilutes peptone in 150 to 200 c.c. of isotonic saline solution. The intravenous injection is made very slowly, with careful watch of the pulse. If the rate runs up above 140, he suspends the injection until the pulse has come down.

Loeper and Verpy [16] report finding cholesterol crystals in the connective tissue, the synovia and synovial fluid of a case of deforming arthritis in a man of 47. They also found these crystals in a soft tumor removed from a woman, aged 39, with deforming arthritis and in a hygroma from a case of chronic rheumatism in a man. In the latter case, the cholesterol crystals were combined with uric acid crystals and the man had gouty tophi. They urge the wisdom of chemical study of joint deposits in deforming arthritis.

Péhu and Daguet [17] have encountered within a year ten cases of chronic spondylosis with ankylosis occurring in soldiers of about 40 years of age. There were no clinical signs of tuberculosis or Neisser infection. The first symptom was usually pain in the lumbosacral region, gradually extending, with remissions, the whole length of the spine, and ceasing when ankylosis took place. Roentgen-ray examination demonstrated the lateral ligament infiltrated with lime salts, beginning in the upper lumbar or lumbodorsal region, the vertebral bodies themselves showing no essential changes. They are convinced that many cases of this rather obscure condition are called lumbago or sciatica.

[Ed. Note.—The Editors see these cases frequently, chiefly in their public clinics, and have repeatedly failed to find evidence of tuberculosis or Neisser infection. They have been described by Strümpell-Marie and have been called spondylose rhizomelique because of their frequent tendency to involve eventually the root joints of shoulders and hips. No method of controlling the progress of the disease, other than the usually unavailing eradication of all foci of infection, is known to us. We believe there is one means of prevention which is of great importance, namely, the conservation of the thoracic cavity in order to give the largest possible amount of lung and heart space. The tendency is for the spine to bend sharply forward, and for the chest to become narrow and be depressed, and when the costal articulations become ankylosed, as they nearly always do, the insufficient areation is only too evident, and lung diseases and circulatory changes follow. By means of comparatively light retentive spring braces, hyperextended positions of

16. Loeper and Verpy: Bull. et mém. Soc. méd. d. hôp. de Paris, May 24, 1918.
17 Péhu and Daguet: Lyon méd., May, 1918.

recumbency, or even by corrective plaster jackets, this deformity may be prevented and even safely partially corrected if ankylosis of a too firm bony character has not occurred. The forcible correction of firmly ankylosed spines of this kind has had its mortality as well as its successes.]

PARALYSIS

Poliomyelitis.—Netter [18] reports sixty-two cases of acute poliomyelitis in which serum from convalescent cases of poliomyelitis has been administered. He evidently believes the method of value, and that it should be employed. In a most favorable case in a man, recorded by Etienne, the injection of the serum was not made until the seventh day. Twenty-five c.c. of spinal fluid under high pressure was first removed and then 5 c.c. of the serum injected. This serum had been obtained from a girl who had been convalescing for thirteen months. The patient's temperature before injection of the serum had dropped to normal, and his total paralysis had shown slight indication of improving. Rapid recovery followed the injection.

Netter reports that Neustadt and Banzhof have succeeded in obtaining an effectual serum from horses injected with the products of autolyses of nerve centers from human beings and monkeys who had succumbed to poliomyelitis.

Kraus and Kantor [19] have failed to reproduce poliomyelitis in Paraguayan monkeys injected with the Rockefeller virus, but have succeeded with the same virus when imported Macacus monkeys were used, thus confirming Flexner's experience that the monkeys of the New World do not seem to be susceptible to experimental poliomyelitis.

Spastic Paralysis.—Gill,[20] in a valuable article on the surgery of spastic paralysis, speaks of the simple operation of tenotomy as having two purposes: first, to relieve the stretching of the weakened opposing muscles, and second, to break up the vicious circle of impulses. There is no real shortening of the tendon. The tenotomy relatively only lengthens the muscle. He describes in some detail Stoffel's operation. This consists in removing part of the motor nerve supply to certain affected groups of muscles. Thus, in equinus, part of the internal popliteal nerve is resected; in contracted knee, part of the sciatic nerve; in adducted hip, part of the obturator, and in the arm, part of the median and the ulnar nerves. He has performed these operations on thirty-five patients, and now he believes that it is almost the operation of choice, and reports five typical cases. He mentions the fact that he

18. Netter: Bull. et mém. Soc. méd. d. hôp. de Paris, May 3, 1918.
19. Kraus and Kantor: Rev. d. Inst. bacteriol., November, 1917.
20. Gill, A. B.: Ann. Surg., May, 1918.

has better success in the lower extremities, and speaks of the after treatment as being most important and that the results depend to a certain extent on the mental condition and the ability of the child to be trained. It is better to resect too little than too much of the nerve, because a second operation can be very satisfactorily performed.

[Ed. Note.—This operation has been performed in a considerable number of cases at the Massachusetts General Hospital by Dr. Bucholz with results which encourage its continuance.]

Paralysis of the Peripheral Nerves.—Léri [21] has encountered recently eight cases of amyotrophic paralysis of the upper extremity due to cervical lesions of a chronic rheumatic nature. These consist in osteophytic protuberances and beak-like projections pressing on the nerves at their exits, as they emerge from the foramina. The distribution of the paralyses and their extent naturally varied with the location and severity of the lesion, but Léri persuaded himself that they were all due to this cause.

Molhaut,[22] as a result of his experience at a special hospital for the treatment of nervous affections of the war, is persuaded that most of the so-called reflex paralyses, supposed to be manifestations of hysteria and functional disorders, are in reality due to definite and usually irremediable organic injury. He believes the lesion to be a terminal neuritis of the sensory nerves, resulting in hypertonia, i. e., reflex irritability or hypotonia and reflex paralysis. The terminals of the deep sensory fibers are in the soft parts surrounding the joints and in the periosteum. Lesions of these structures may irritate these terminals to excessive activity or prevent their functioning. He urges the early recognition of the organic nature of the trouble and the fitting of braces or prostheses, and that the patients be discharged or given light duty. The author discusses in some detail the differential diagnosis of these organic lesions.

RICKETS, COXA VARA, OSTEITIS DEFORMANS

Gismondi [23] considers rickets to be a disease of the entire organism. The blood and the soft parts as well as the bones lack the normal calcium content. He advises for treatment a 50 per cent. emulsion of cod liver oil, 0.01 gm. of phosphorus being added to each 100 gm. of emulsion. A teaspoonful of this, representing 0.5 mg. of phosphorus, is given once or twice a day, immediately before eating. Calcium acetate in doses of 0.5 gm. is given with the cod liver oil and phosphorus. He

21. Léri: Bull. et mém. Soc. méd. d. hôp. de Paris, Nov. 15, 1918.
22. Molhaut: Arch. méd. belges, October, 1917.
23. Gismondi: Riv. di clin. pediat., March, 1918.

is convinced that this medication hastens the consolidation of the bones and shortens the period during which the danger of bony deformation exists.

Vargas [24] believes that rachitis is a national problem in nearly every country. It is a world scourge preventing the normal development of the young, leaving them damaged not only in their bones, but also in their mental and moral faculties. He expatiates on the prodromic symptoms, which, when heeded, permit the removal of the causes. This prodromic stage includes the period marked by the first sign that the child is not thriving normally to the manifest deformity in the skeleton evident in the skull during the first six months of life, and in the fifth and sixth ribs in infants from 6 to 20 months old. The child whimpers when it is moved, the scalp sweats freely, the head is swung from side to side as soon as it touches a pillow and the digestion is imperfect. A waxlike pallor is one of the earliest symptoms, and the hemoglobin percentage is low. The very first sign of rachitis is a special type of constipation. The feces are hard, the rectum is unable to expel the lump, which sticks in the anus until aided by mechanical means. There may be a fissure of the anus and prolapse of the rectum. Other signs of rachitis soon follow. The constipation may alternate with diarrhea, but in both types of stool the content in calcium salts is above normal. In the second stage, the disease which began in the blood, attacks the blood-producing organs, the bone marrow in particular. The resulting abnormal conditions in the marrow and cartilage make their effects felt in the faulty development of the bone. Other organs are affected likewise, the nervous system, the muscles, skin and mucous membranes. Vargas describes these changes in detail, defining rachitis as a "toxic infantile dystrophy characterized by hemolysis, irritability of the blood producing system and by 'osteism.'" The tendency in time is to spontaneous recovery, but the damage from it can be warded off only by removing the cause.

Quite significantly, Léri and Beck [25] report that they have recently encountered thirty soldiers who were suffering from the effects of early rickets. They call them "petits rachitiques." These men often have no gross evidences of rickets in childhood, but complain of persisting bone pain, dull and aching in character, which renders impossible any long march or specially arduous work. They are asthenic physically and sluggish mentally. They desire only rest. The authors consider these men unfit for full military service and advise that they be transferred to the auxiliary service.

---

24. Vargas: Paris méd., April 19, 1919.
25. Léri and Beck: Bull. et mém. Soc. méd. d. hôp. de Paris, March 1, 1918.

Coxa Vara.—Froelich,[26] writing under the title of Coxa Vara Essentielle and Arthritis Deformans Juvenilis describes the common symptoms of coxa vara and osteochondritis as described first by Legg, a little later independently by Calvé, and later still by Perthes, and usually called erroneously Perthes' disease. He points out the fact that it is often mistaken for tuberculosis, but contends that the evidence brought forward by the serodiagnostic studies of Port and the operative cultural evidence of Kidner make it fairly certain that the essential cause is a low grade osteomyelitis due to the staphylococcus.

Kirmisson[27] has been impressed by the frequent development of coxa vara in adolescents, along with the general tendency to obesity. This occurs too often for it to be merely a coincidence, especially as a familial tendency is also evident. In one family described, three children had had coxa vara since the period of puberty, and the mother also had coxa vara as a girl, and all four showed pronounced obesity. In another family, one girl, aged 11 years, showed double coxa vara and the tendency to obesity was marked. The parents and the five other children were healthy, but two were inclined to obesity. Several members of a third family showed obesity and in one girl, aged 12, the upper epiphysis of the femur became separated, which he regards as practically the equivalent of the coxa vara in the other cases. Abortive coxalgia is another tendency in the same direction. The obesity seems to be the connecting link between them all, and certain features of it, particularly the puffiness of the face, suggest myxedema and a possible thyroid origin. Roentgenoscopy in two of his cases failed to reveal anything abnormal in the pituitary region.

[Ed. Note.—While obesity and poorly developed genitalia are most frequently associated with these cases of coxa vara and slipped epiphyses and the so-caclled adolescent rickets, they are by no means essential. We have had under hospital and private observation several patients of both sexes in whom coxa vara and epiphyseal separation as a result of trivial trauma had occurred, who were thin rather than fat, tall rather than short for their age, and in whom the genitalia were fully developed. The fact that obesity and poorly developed genitalia are usually associated with the typical lesions must not dull our diagnostic acumen and lead us to fail to recognize these lesions in atypical cases.]

DeCourcy[28] reports a case of bone cyst of the upper half of the humerus or possibly a so-called giant celled sarcoma (because a few giant cells were found microscopically in the specimen) occurring in a boy of 12. There had been no known trauma, but the symptoms had

26. Froelich: Rev. d'orthop., April, 1918.
27. Kirmisson: Bull. de l'Acad. d. méd., March 5, 1918.
28. De Courcy: Osteitis Fibrosa, J. A. M. A. **72**:1612 (May 31) 1919.

first appeared ten months previously following a vaccination, the reaction to which had been severe. The roentgenogram disclosed several fracture lines in the lesion. At operation a cystlike cavity, 2½ inches in length, filled with bloody matter and lined with granulation tissue, was found. This was curetted out and a small amount of apparently healthy bone removed from each end. A one-fourth inch bone graft removed from the patient's tibia was then transplanted subperiosteally. One month later, callus was evident, and in three months firm union had occurred.

[Ed. Note.—The article is referred to because as far as we know bone grafts have not commonly been immediately implanted in such cases. The author writes under the title of Osteitis Fibrosa, but we believe that such lesions are more generally recognized under the name of bone cyst or giant cell sarcoma, or hemorrhagic osteomyelitis, as Barrie has called them. In a single bone, it is obviously important to be able to insert successfully a graft at the time of the exploratory operation. Bone cysts frequently heal spontaneously after fracture, and union occurs, but in the so-called giant cell sarcoma, involving the whole or nearly the whole circumference of the bone, it may be impossible thoroughly to remove them without resecting a considerable portion of the shaft. In these benign growths, there would seem to be reason to expect an inserted homogeneous graft to live, and convalescence to be thereby shortened.]

Osteitis Deformans—Paget's Disease.—Abbe [29] reports excellent repair after surgical operations on the bones in cases of Paget's disease.

[Ed. Note.—The Editors have several times observed fractures which have occurred as the result of trauma unite firmly in normal time in these cases. The knowledge that these bones may be operated upon without any special danger of nonunion is of great value, since considerable deformities of a conspicuous and even more or less disabling character frequently occur, especially in the lower limbs quite early in the disease, and seem often to remain almost stationary. If these patients can be operated upon successfully for the correction of these deformities, the benefit to them may be very great and may be expected to continue for many years, and perhaps permanently if the disease is quiescent. Of course, no effect on the underlying disease is to be expected.]

STATIC STRAINS AND DEFORMED FEET

High heels receive well merited and appropriately local censure in two French articles by Galippe [30] and Quénu and Ménard.[31] Galippe

29. Abbe: Paget's Disease of the Bone, J. A. M. A. 70:371 (Feb. 9) 1918.
30. Galippe: Bull. de l'Acad. de méd., Dec. 18, 1917.
31. Quénu and Ménard: Bull. de l'Acad. de méd., Dec. 4, 1917.

exclaimed, "Ce serait mal connaitre la psychologie féminine que de croire, un seul instant, que la coquetterie cédera jamais le pas á l'hygiene." It is an old cry. Camper of the Hague, in 1871, called attention to the "crime against physiology of the Louis XV heels," but it has little apparent effect against the dictates of fashion, for Galippe moans that his words have not been heeded in his own immediate circle.

Quénu and Ménard call attention to the artificially induced talipes equinus from wearing high heels. The hyperextension of the foot compels the trunk to be thrown back while the knees are slightly flexed. This pulls on the quadriceps, and this in turn draws the patella up. Moving pictures of the gait with high heels (from 7 to 9 cm.), that is, from 2¾ to 3½ inches, compared with the gait of the subjects (three young women) with bare feet, demonstrate the comparative inaction of the muscles of the leg and foot. This entails lesser activity in the nutritional phenomena of the contractile tissue and hence less perfect circulation through the leg. The "induced equinism," as they call it, upsets the architectural balance of the feet and legs, and the effect of the vicious attitude is felt in the spine and pelvis to such an extent that high heels are directly contraindicated for the growing organism. In the discussion that followed, Kirmisson called attention to the tendency to valgus when high heels are worn from weakening of the crural triceps. Linossier also reported that young girls with orthostatic albuminuria may be cured by having heels removed from their shoes. The high heels induce and aggravate lordosis and thus may be responsible for the orthostatic albuminuria.

[Ed. Note.—If high heels may induce a lumbar lordosis, they conversely may tend to correct a flattened lumbar curve and change a faulty attitude and center of gravity line. There are other methods of accomplishing the same purpose, by exercises, corsets, braces, etc. If we prescribe high heels to correct static defects, it is surely incumbent upon the profession to explain the temporary nature of this prescription and to make it quite clear to our patients that the troubles which may be expected to follow their continued use are more serious and annoying than the conditions for the correction of which they may occasionally have been prescribed.]

Robinson[32] maintains that hallux valgus and its accompanying bunion are caused by enlargement of the sesamoid bones. This enlargement against the resistance of the plantar fascia pushes the head of the metatarsal upward and inward (mesially), while the proximal phalanx and the whole great toe is displaced outwardly (laterally). He states that cures may be obtained from removal of the offending sesamoids and advises the operation in early cases as a preventive measure.

32. Robinson: Surg., Gynec. and Obst., September, 1918.

[Ed. Note.—It may well be that marked enlargement of these sesamoid bones is one of the causes of hallux valgus. That there are potent other causes, especially shoes, can hardly be gainsaid. It is also very clear that removal of even very much enlarged sesamoid could not reasonably be expected to bring about any quick or complete cure of a laterally displaced great toe or get rid of the frequently associated enlargement of the head of the first metatarsal and the chronic bursitis that ensues. New joint surfaces in the position of deformity have already formed and the extensor tendon has contracted and found a new bed. To cure quickly any marked deformity we must still rely upon the old Hueter-Mayo removal of the metatarsal head or the probably better Keller operation which removes the mesial and a part of the superior portion of the head and takes a narrow button of bone off the base of the proximal phalanx. By these procedures of Keller, the important weight-bearing pillar of the foot is preserved, while it is lost in the Hueter operation and the loss is felt. The author's theory of production of the deformity may be correct in certain cases. We have seen hallux valgus begin in young adults who have worn nondeforming shoes, and progress somewhat in spite of conservative treatment.]

Riosalido [33] has been impressed with the number of actual lesions other than syphilis and tuberculosis he has discovered in cases of persistent foot pain in children. Localized inflammatory processes, arthritis and supernumerary bones he mentions as frequently found, and he strongly urges that more roentgenograms be taken.

Roussy, Boisseau and d'Oelsnitz [34] discuss the type of talipes varus which has been seen so often during the war following thigh and leg injuries and immobilization, as well as injuries to the feet themselves. The etiology of this rather common and typical deformity has not been clear and many operations have been suggested and performed for its relief, with only partial success. These writers after their study conclude that whatever true contractures and nutritional disorders from prolonged immobilization may be present, the mind of the man is the main element in the perpetuation of the deformity and that the vicious circle can be best broken by treatment of the psychoneurosis.

[Ed. Note.—We had seen these adducted and painful feet in the French, British and American soldiers, and had begun to be rather discouraged by the results of manipulations, tenotomies, tendon transplantations, and even bone operations. We have observed many of these patients, treated as psychoneuroses, recover completely and remarkably quickly, and although it is not yet clear why this peculiar

33. Riosalido: Arch. españ. d. pediat., February, 1918.
34. Roussy, Boisseau, and d'Oelsnitz: Ann. de méd., Nov.-Dec., 1917.

deformity should occur so frequently, and some other original organic lesion is suggested, operation would seem to be contraindicated, and functional use encouraged in every way with assurance of complete recovery.]

SCOLIOSIS

We have discovered no truly significant article which offers much help in the successful treatment of scoliosis. Sir Arthur Keith,[35] in his fascinating historical book "Menders of the Maimed," believes Abbott has been proceeding on a wrong basic principle. He says, "Dr. Abbott's methods will appeal to many because of their apparent simplicity and effectiveness. When we come, however, to look more closely into the principles involved, we shall find that the method does not rest on a true physiologic basis, and that any improvement obtained by Dr. Abbott's method is only apparent and is confined merely to the surface of the body. . . . It is true that at an early stage of the deformity the dorsal ends of the ribs might be used as levers to undo the rotation of the vertebrae; it is clear that Dr. Abbott regards them in this way when he applies pressure to the convexity of their dorsal ends to undo abnormal curvatures; but in late stages such pressure could only remove a surface deformity—the deep essential deformity of the spine would still remain, for that cannot be undone by means of pressure applied to the ribs."

[Ed. Note.—It may well be that the correction of this surface deformity is of great cosmetic value in certain cases, especially if this correction be maintained by thorough after-treatment.]

Joland[36] makes a strong plea for the exercise treatment, associated with frequently changed braces if the patients are temporarily unable to retain the correction gained, but he brings forward no conclusive evidence of great success.

Jansen[37] has written a valuable article on physiologic scoliosis, considering it from the historical, statistical, anatomic, and clinical points of view, and not agreeing with the conception of either Lovett or Abbott.

[Ed. Note.—Jansen's studies and conclusions are very impressive, and we believe will throw light upon the still rather obscure mechanics of the condition. The reasons why certain deviations of the vertebrae are usually to the left, while others are to the right find here a very suggestive explanation. We hope that Jansen's trials may be followed by others and be broadened by anatomic and radiologic studies.]

35. Keith: Menders of the Maimed, Henry Frowde, London, Oxford University Press, 1919.

36. Joland: Paris méd., Jan. 4, 1919.

37. Jansen: Ztschr. f. orth. Chir. **33**:, p. 1.

LOW BACK PAIN

Colvin[38] in a general article on the causes of low back pain judicially considers the etiologic factors, and after weighing the evidence outlines the rationale of treatment of the orthopedic conditions.

Henninger[39] discusses the cord and nerve affections, which may be the explanation of low back pain, and after enumerating the numerous neurologic causes, spinal tumor, and other cord lesions, concludes that pain in itself is of little diagnostic value as regards nerve lesions, but that the presence or absence of the reflexes and the trophic and sensory changes must suggest an essential neurologic lesion.

Baker[40] takes up low back pain from the point of view of an urologist and quotes Head's theory as an explanation of the well recognized low back pain and sciatica which are present frequently in prostatitis and spermatocystitis. In the writer's series this occurred in about 28 per cent. of the cases. Head's explanation of referred pain from visceral lesions is so generally accepted and is so clearly and concisely written that it is here quoted:

> A painful stimulus to an internal organ is conducted to that segment of the cord from which its sensory fibers are given off. There it comes in close connection with the fibers for painful sensation from the surface of the body which also arise from the same segment. But the sensory and localizing power of the surface of the body is enormously in excess of that of the viscera, and thus by what might be called a psychical error of judgment, the diffusion area is accepted by consciousness, and the pain is referred to the surface of the body instead of to the viscera actually affected.

Baker mentions lesions of the kidney and ureter as occasional causes of low back pain. He believes that pain in the pelvic joints and limitation of motion are rare in genito-urinary lesions and are important aids in differential diagnosis.

Graves[41] believes that the commonest gynecologic cause for low back pain is a markedly retroflexed uterus, admitting that pelvic tumor and pelvic cellulitis may be responsible also. Graves' statistics and end-result studies would seem to leave no doubt that uterine malpositions, especially retroflexion, may be the sole cause of low back pain, which is usually central.

Davis,[42] taking up the question from an anatomic point of view, considers the movable lumbar spine, and especially the lumbosacral and sacro-iliac articulations as the chief seats of lesions giving rise to

38. Colvin: J. Orthop. Surg., June. 1918.
39. Henninger: J. Orthop. Surg., December, 1917.
40. Baker: J. Orthop. Surg., December, 1917.
41. Graves: J. Orthop. Surg., December, 1917.
42. Davis: J. Orthop. Surg., December. 1917.

symptoms of low back pain. Lesions of the bones themselves he dismisses as a frequent cause. He believes that we have little evidence of any common derangement of the muscle structure. The nerve trunks he admits may be irritated by bony changes or by continued hypertension from faulty posture. He considers that sprains of the ligaments are frequently the cause.

Wilson,[43] making a radiologic study of the impingement of the lateral processes of the fifth lumbar vertebra with the ilium or sacrum as a cause of backache, gives the following precentage statistics in fifty-one cases. Fifty-two per cent. were free from contact; 12 per cent. were bent; 17 per cent. were in contact; 10 per cent. were overlapping; 4 per cent. were fused; 2 per cent. showed periosteal thickening, and 1 per cent. showed erosion. He concludes that the lateral processes may be etiologic factors in backache when (*a*) they are the seat of a pathologic process; (*b*) when they are associated with bursae, and (*c*) when they are in contact with the sacrum or ilium. Certain occupations predispose to symptoms from these causes.

Cofield,[44] studying the lesions of the sacro-iliac joint, conceives the ordinary nontuberculous and nonarthritic lesions to be sprains of the joint rather than true displacements. He explains the symptoms as follows: Localized pain and tenderness, due to original sprain, plus chronic strain due to protective spasm of the hamstring and erector spinae groups of muscles. These two muscle groups tend to move the joint. Sciatica, due to irritation of the nerve as it lies in the groove between the outer and inner hamstring muscles, these latter being in a condition of chronic retraction and spasm. Atrophy of thigh muscles, due to long overaction which interferes with normal blood supply.

The relief obtained by manipulation he explains as due to the stretching of the retracted lumbar and hamstring muscles. The click that is sometimes heard may be due to an actual rupture of muscle fibers or tendinous attachment in the hamstrings. He always applies a plaster jacket following manipulation.

Fassett[45] discusses displacements of the bones as causes of low back pain. He groups them into three types: (A) gross displacement, the results of crushing trauma or destructive disease; (B) momentary displacements, which leave behind them sprains, and (*C*) slight displacements, which persist unless reduced by chance or manipulation.

[Ed. Note.—The author's early experience with osteopathy has been large and his later orthopedic training and practice larger still. It is, therefore, interesting to have him estimate that in a thousand cases which would be diagnosed as displacements by an average group

43. Wilson: West Virginia M. Monthly, February, 1918.
44. Cofield: J. Orthop. Surg., November, 1918.
45. Fassett: J. Orthop. Surg., November, 1918.

of osteopaths, only one or two would really belong to Group C. Two hundred or 300 would be actual anatomic variations or irregularities in palpable portions of the bones, and the rest would represent self deception or conscious fraud. Much work needs to be done upon these joints and their lesions, especially the arthritic and traumatic lesions. Stereoscopic roentgenograms are helping us much, both in discovering anatomic variations, the presence of an unsuspected arthritis, and in proving the occasional persisting displacement and disproving the frequently suspected one. We can ill afford to neglect this helpful diagnostic measure.]

SCIATIC PAIN

[ED. NOTE.—It is interesting if somewhat discouraging in reviewing numerous articles on sciatica to find that comparatively little attention is being paid to the causes of pain from irritation of the sciatic nerve and that the symptom is still being considered as a disease entity and treated as such. Thus Barré,[46] Rembaud,[47] Roussy, Cornil and Leroux,[48] and Chiroy and Roger [49] all devote special attention in their articles to certain signs by which real sciatic pain may be differentiated from simulated pain, a differentiation which up to the present time the Editors had not considered difficult. Thus a patient with real sciatica can squat without increasing his pain, a simulator usually pretends it is very difficult. They speak of the deviation of the spine and of pain in forward bending with the knees straight, the slight outward rotation of the foot and slightly bent knee on the affected side, the lowered surface temperature, especially on the outer aspect of the lower half of the leg, a flattening out of the groove on either side of the Achilles tendon, etc. Chiroy and Roger admit that the "syndrome musculaire de la sciatique" is extremely variable, while there is great uniformity in the sensory disturbance, and they argue quite properly that the seat of the disturbance must be at the point where the motor and sensory fibers run separately, i.e., at the roots. Rest is the treatment which all depend on for cure, and Fraikin,[50] while insisting on fixation of the limb, strongly advocates various physiotherapeutic measures.]

Saliba [51] proposes without any very evident reason a new name for sciatic scoliosis, calling it antalgic spinal distortion. He concurs in the commonly accepted theory that the phenomenon is due to the position instinctively assumed to relieve pain, but believes the psychic

46. Barré: Presse méd., Feb. 6, 1919.
47. Rembaud: Bull. et mém. Soc. méd. d. hôp. de Paris, Oct. 11, 1918.
48. Roussy, Cornil and Leroux: Presse méd., Sept. 6, 1917.
49. Chiroy and Roger: Bull. et mém. Soc. méd. d. hôp. de Paris, Jan. 31, 1919.
50. Fraikin: J. de méd. de Bordeaux, Feb. 28, 1919.
51. Saliba: Antalgic Spinal Distortion, J. A. M. A. 72:549 (Feb. 22) 1919.

factor in many of these cases is a large one and must be reckoned with in treatment.

None of these authors seem to be fully conscious of the fact that bony, ligamentous, and bursal lesions in the neighborhood of the exits of the nerves making up the lumbosacral cord and the sacral plexus are probably by far the commonest causes of sciatic pain and that the mechanical irritation of parts of the plexus or of the main nerve trunk in the neighborhood of the hip joint may occur from these lesions. Some of the Italian authors are appreciating these facts. Thus Blanc and Fortacin [52] report a case of sciatica in a child in which a hip joint lesion requiring resection was the cause, and Rossi [53] has collected a number of cases in which roentgenograms revealed definite abnormalities of the fifth lumbar vertebra.

We have by no means solved the problem of sciatic pain, but we may fairly be said to have convinced ourselves that no such entity as sciatica exists and that the most important etiologic factors are lesions in which the spinal and pelvic bones play a part. We must not forget the misleading referred pains of visceral lesions, prostate and seminal vesicles, but we must do more work on low spinal arthritis, bursitis, associated with anatomic variations and ligamentous strains, from posture, occupation or sudden trauma, and the rarer displacements. We need sorely to classify these common lesions and refine our therapy, but we must have less symptomatic and more rational treatment if we are to lessen our patients' suffering and increase our own knowledge.

DISLOCATIONS

Recurrent Dislocation of Jaw.—Blake [54] reports a method of operative relief of recurring dislocation of the jaw which has proved successful in one case. He considers the method has the advantage of being comparatively simple, and of avoiding work on the joint itself, which is difficult to expose. His incision is along the lower border of the zycoma. The fibers of the masseter muscle are separated and the coracoid process exposed. A wire is passed over the zygoma and through the border of the coronoid and tightened sufficiently to prevent the separation of the teeth more than an inch. In Blake's case there had been no recurrence of the dislocation after one year.

Dislocation of Shoulder.—Turner [55] describes a simple method of reducing dislocations of the shoulder joint, reporting uniform success in fourteen cases, in one of which the patient was 24 days old. His procedures are as follows: The patient is anesthetized in a recumbent

52. Blanc and Fortacin: Rev. d. méd. y cirug. práct., July 14, 1918.
53. Rossi: Chir. degli Organi di Movimento, December, 1918.
54. Blake: Ann. Surg., August, 1918.
55. Turner: Practitioner, August, 1918.

position. One assistant exerts traction on the arm in the axis of the limb and in the adducted position. Counter traction is made by the anesthetist by a hand in each axilla. A towel is placed around the upper arm and the surgeon obtains the necessary outward traction by a pull on this towel. The principle of the method is that downward traction in the adducted position brings the head to the level of the rent in the capsule and outward traction pulls it through the rent into the glenoid.

Dislocation of the Elbow.—Verney [56] has encountered three cases of obstinate backward luxation of the elbow which he was unable to reduce until he employed the method he describes. The patient was directed to hook his arm over the highest rung of a ladder which he could reach and then to suspend his weight from it, standing "side on" to the ladder. The triceps was relaxed by the high position and the reductions were accomplished without manipulation of the surgeon.

Atlo-Axoid Luxation.—Swanberg [57] compares in the accompanying tabulation the normal roentgen-ray findings with the abnormal in a case of anterior dislocation of the atlas following a tonsillectomy.

NORMAL AND ABNORMAL ROENTGEN-RAY FINDINGS IN CASE OF ANTERIOR DISLOCATION OF THE ATLAS.

Normal Atlas	Dislocated Atlas
1. Posterior pharyngeal wall practically vertical.	1. Posterior pharyngeal wall markedly curved forward, anterior to atlas.
2. Anterior margin or anterior tubercle of atlas in line with anterior margin of body of axis.	2. Anterior tubercle on a more anterior level.
3. Lateral masses of atlas rest on superior articular processes of axis.	3. Lateral masses of atlas on a more anterior level.
4. Odontoid process in contact with anterior arch of atlas.	4. Odontoid process free.
5. Anterior margin of posterior tubercle of atlas on a plane posterior to anterior margin of spinous process of axis.	5. Anterior margin of posterior tubercle on a plane anterior to anterior margin of spinous process of axis.

Jacobs' [58] article on luxation of the atlas and axis may be outlined thus:

Dislocation of the atlas may be forward or backward. Unilateral dislocation is most common; bilateral dislocation is complete or incomplete. Trauma dislocation, forward or backward, has been considered

56. Verney: Arch. d. méd. et d. phar. mil., April, 1918.

57. Swanberg: Anterior Dislocation of Atlas Following Tonsillectomy, J. A. M. A. 72:107 (Jan. 11) 1919.

58. Jacobs: J. Orthop. Surg., October, 1918.

possible only after (1) fracture of odontoid process; (2) rupture of the transverse ligament; (3) slipping of the process beneath the ligament. Distention luxation occurs during or after some febrile condition. The author reports two cases of his own and two from the literature. Diagnosis is made by the clinical picture, position of head, and the stereoscopic lateral roentgenogram. The treatment is by manipulation under ether followed by a Calot jacket for about two months. His conclusions are: Dislocation of atlas and axis must be no longer considered of rare occurrence. Distention luxation is a definite possibility. Treatment consists in extension by weight and pulley which will usually overcome the luxation. Manipulation under anesthesia is dangerous, but without ether is valueless. Operative procedures are called for when other methods of reposition have failed.

[Ed. Note.—Swanberg's case is by no means the first reported case of dislocation of the cervical vertebrae, usually the atlas or axis, which has followed a tonsillectomy, and the Editors have encountered several other unreported cases. They are usually unrecognized by the surgeon, and the parent or patient is assured that the "stiff neck" which he finds on recovery from ether will soon disappear. Stiff neck following tonsillectomy should always excite suspicion and demand immediate explanation. Luxations are invariably demonstrable by roentgenograms taken stereoscopically or even laterally and through the open mouth in an anteroposterior position, which will reveal the odontoid and the flat spheroidal, atlo-axoid articular facets. There would seem to be no excuse for failing to make this diagnosis at once. Jacobs [58] speaks of operative procedures when manipulative attempts have failed, but does not specify what these shall be. Direct approach to the atlo-axoid facets is extremely difficult, even hazardous, and if manipulative procedures, including pressure on the posterior pharyngeal wall have failed, we are inclined to believe that some procedure which fixes the position of the atlas and axis and prevents further luxation is the safer procedure. The foramen formed by the posterior arch of the atlas is so large that considerable forward displacement of the atlas on the axis may occur without cord compression. One very feasible fixative procedure has been described by Mixter and Osgood [59] and successfully carried out by Ely as well. Through a linear incision in the midline of the neck, the posterior arch of the atlas and the bifid spinous process of the axis are exposed and after all possible correction of position has been gained a retentive suture of wire or silk is placed around the arch of the atlas and anchored to the spinous process of the axis.]

59. Mixter and Osgood: Ann. Surg., February, 1910.

Dislocation of Lumbar Vertebra.—An interesting and somewhat unusual case of traumatic lateral dislocation of the second lumbar vertebra, with successful manipulative reduction, is reported by Guyot and Mauclaire.[60] There was paralysis of the right leg. Anesthesia was given and vertical traction and countertraction were exerted on the legs and shoulders, while the lateral traction was exerted on the chest and countertraction on the pelvis. The roentgenogram revealed reduction, and the cord symptoms disappeared.

Luxation of the Sacro-Iliac Joint.—Wentworth [61] describes a method of demonstrating luxations of the sacro-iliac joints in two cases of painful hypermobility. The patients stood with their backs to the observer, whose fingers were placed on the crests of the ilia, while the thumbs palpated the region of the upper portion of the sacro-iliac joints just mesially to the posterior superior spines. The patient raised first the right and then the left foot, approaching the knee to the chest. As the thigh on the side of the lesion passed the horizontal, a sharp click was heard, accompanied by pain felt by the patient, and a definite sensation of movement appreciated by the thumb of the observer on the side of the pain. Roentgenograms were then taken with all precautions of symmetrical position of tube and patient, and a definite asymmetry and tilting of the sacrum on the ilium was revealed.

Congenital Dislocation of the Hip.—Scheuermann [62] has performed a necropsy on a 4 year old child whose congenitally dislocated hip had been successfully reduced nine months before she died of pneumonia. He found the condition of the joint almost normal. The upper pocket of the stretched out capsule had disappeared. The upper margin of the acetabulum was found to be very weak. Scheuermann thinks that this suggests that retention is maintained by shrinking of the capsule and by a development of the cotyloid ligament, indicating the necessity of a firm, long continued fixation after reduction.

FRACTURES

Fractures of the Spine.—In a review of postmortem findings and a presentation of specimens of gunshot wounds of the vertebrae and spinal cord by Thorburn and Richardson,[63] it is interesting to note the frequency of minor fractures at a distance from the main lesion, probably due to the tearing off of the ligamentous attachments.

---

60. Guyot and Mauclaire: Rev. d'orthop., April, 1919.
61. Wentworth: J. Orthop. Surg., November, 1918.
62. Scheuermann: Hospitalstid., May 31, 1919.
63. Thorburn and Richardson: Brit. J. Surg., April, 1919.

In attempting to answer the question as to whether early operation is indicated in fractures of the spine with cord symptoms, A. S. Taylor [64] admits the lack of unity of opinion, but believes that operation is indicated in these classes of cases: (1) when the lesion is caused by a missile or direct violence and a dissolution of both osseous and soft structures is believed to have occurred; (2) when there is effusion and hemorrhage with pressure on the cord; (3) when the pressure is caused by the displaced vertebra or displaced fragments of the vertebrae.

Elsberg [65] in an article on fractures of the spine with cord and root symptoms concludes that (1) extreme conservatism is indicated in the patients with signs of a transverse lesion of the cord; (2) operation should be performed as quickly as possible after the injury upon all patients showing evidence of only partial injury of the cord. The interference with function may be so slight or the general condition of the patient may be so poor that operation is not justifiable, but in general he considers that prognosis in the latter group is extremely good with immediate operation.

Fracture of the Clavicle.—Hidden,[66] evidently dissatisfied with the results obtained in fractures of the clavicle by the ordinary methods of retention, Velpeau, Sayre strapping, etc., expatiates upon the advantages of an apparatus which draws the shoulders outward, backward and upward. He maintains this position by means of rings of hollow metal, padded wire, or plaster covered wire wound with cotton, fitted around both shoulders, and tied together back and front, the corrective force being applied in tying the rings together at the back. He keeps the patient in bed a day or two, but throughout the treatment allows free use of the arms.

[Ed. Note.—We also have become convinced that only by recumbency with a pillow between the shoulders and the affected shoulder held back and up, or by some device which pulls back and up both shoulders if the patient is allowed to be ambulatory, can good alinement of most clavicular fractures be maintained. Whether this is accomplished by the specially fitted Taylor clavicular brace, the rings of Hidden, plaster of Paris, or the old fashioned clavicular cross of wood, matters little, the principle is the same in all, but the principle seems to us important if the patient is allowed to be out of bed.]

Fracture of Forearm.—Destot [67] considers four things essential in fractures of both bones of the forearm: (1) that the relative length of

64. Taylor, A. S.: New York M. J., March 30, 1918.
65. Elsberg: Ann. Surg., January, 1918.
66. Hidden: Progrès méd., Sept. 21, 1918.
67. Destot: Paris méd., Aug. 17, 1918.

the two bones be maintained; (2) that the natural curve of the radius be conserved and its excentric position appreciated; (3) that the hand must be kept in supination; (4) that immediate immobilization, even in compound war injuries, must be provided. He makes a plea for the employment of these methods of treatment and emphasizes the difficulties of correcting malalinements and synostoses.

Masmonteil [68] calls attention to the rotation of the distal fragment which always takes place in fractures of the ulna. This was first pointed out by Destot, who stated that the rotation was inward, resulting in diminished power of supination, unless the hand was immobilized in this position. Masmonteil, on the other hand, thinks that the lower fragment rotates outward, owing chiefly to the pull of the pronator quadratus, and believes that in fractures of the ulna alone, the hand should be immobilized in a position of easy pronation. In radial fractures and in fractures of both bones, he agrees that the position of supination is most likely to maintain correct alinement of the radius and conserve rotatory motion of the forearm.

Jouon [69] reports fifteen cases he has observed of union between the radius and the ulna following fractures of the forearm. The disability is very great. He points out the greater difficulty of operative interference in the upper part of the forearm than in the lower, owing to the important anatomic structures, especially the posterior interosseous nerve winding spirally round the upper end of the radius beneath the supinator brevis which it penetrates, 2 to 3 cm. above the lower margin of muscle. His incision in the upper part of the forearm begins in the depression between the olecranon and the head of the radius, extending downward parallel to the bones. The callus is exposed and a guard placed to protect the interosseous artery. The callus is then excised, enough being removed to allow almost full supination. His after-care is early mobilization. He reports nine good results from twelve operations.

Fractures of the Femur.—Ghillini [70] calls attention to the tendency of the proximal end of the shaft fragment to displace posteriorly in relation to the distal end of the head fragment, due to the weight of the thigh in the recumbent position. He applies traction to the extremity and thrusts the trochanter anteriorly, applying a plaster cast embracing the pelvis and thigh. He reports perfect anatomic union in four cases in which the tendency to backward displacement of the shaft fragment was recognized and overcome.

68. Masmonteil: Presse méd., April 4. 1918.
69. Jouon: Rev. d'orthop., April, 1918.
70. Ghillini: Policlinico, Aug. 4, 1918.

Bradford[71] reports perfect results in three cases of fracture of the femoral neck treated by his abduction splint. This splint is a modification of the Thomas ischial ring knee splint. The modification consists of the addition of a padded wire arm which ascends from the mesial side of the Thomas ring, passes up over the pubes, and descends to form a crutch grasping the ischial tuberosity on the side opposite the lesion and maintaining the affected limb in abduction. Traction is applied to the end of the splint by a key and windlass. His first patient treated in this way was 64 years of age. She was kept in bed with the splint applied for two weeks, was allowed to be up in a chair the third week, and with the aid of a walking frame got about during the fourth week. Traction was abandoned in six weeks, and the ambulatory splint worn for three months.

Taylor[72] believes that fractures of the base of the neck of the femur in children under 13 years of age are common and that the lesion is typical. He proposes the name of "hinge fracture," because the periosteum under the neck is usually not broken and acts as a hinge, allowing the common adduction deformity, but preventing displacement en masse. The symptoms are often slight, but the lesion unrecognized results in a coxa vara. The treatment is by means of a plaster spica applied in abduction. Ambulation is allowed with crutches. The lesion is produced by a strong adducting force and the fracture may occur during delivery.

Desmarest[73] and others have called attention to the frequent deplorable results in subtrochanteric fractures of the femur and the difficulties of their reduction. In this connection a method of immediate treatment devised by Constantine and Vigot[74] is worthy of note. The position of flexion and abduction is required, but, as has been pointed out above, the shaft fragment tends to displace posteriorly. These surgeons place the patient in the ventral position on a frame or special table, which is arranged to allow the removal of the supporting surface directly beneath the affected thigh. An ankle strap is fastened to the lower end of the table or frame, and the fractured thigh allowed to sag through the opening in the table. The knee bends slightly, and a certain amount of traction is exerted, by the weight of the limb through the ankle strap. They have observed, in a compound fracture, the fragments come into perfect alinement by this method, with almost no manipulation. A plaster spica is applied while the patient is in this position.

---

71. Bradford: Boston M. & S. J., July 3, 1919.
72. Taylor, H. L.: New York State J. M., November, 1917.
73. Desmarest: Presse méd., April 27, 1919.
74. Constantine and Vigot: Paris méd., Dec. 14, 1918.

Glaspel,[75] D. W. Crile,[76] Eastman, and Bettman,[77] Fresson and Toupel,[78] and many other surgeons, notably Besley,[79] and Pearson, are firm in their conviction that direct skeletal traction on the condyles, usually by means of caliper or ice tongs, is the best method of obtaining good results in fractures of the femur, especially of the lower third. Pearson's [80] method and technic are probably the best. In Glaspel's forty cases of war fractures, reported in 1918, there was about one-half inch in actual lengthening in more than one fourth of the cases, no shortening in another fourth, and an average of three-eighths inch shortening in about one half the cases. Crile describes the essentials of good calipers and has devised a method whereby full extension as well as flexion of the knee can be obtained during treatment.

Col. H. M. W. Gray,[81] whose experience in front line war work was prolonged and very extensive, believes that the five following conditions justify amputation in compound fractures of the femur: (1) when the main vessels, both artery and nerve, are divided; (2) when gas gangrene has become established in more than one group of muscles; (3) when either artery or vein requires ligature and there is gas gangrene beyond the point of injury; (4) when the sciatic nerve is hopelessly destroyed, and (5) when virulent sepsis is already established in extensive wounds.

Fractures of the Lower Leg.—Hawley [82] believes that a Steinmann pin passed either over or through the os calcis is superior to the Finochietto stirrup for lower leg skeletal traction, because of ease of passage. He obtains traction from a stirrup which fits over the ends of the pin.

Dowd [83] calls attention to the fact that many Pott's fractures and the longitudinal fractures of the posterior portion of the lower end of the tibia into the joint, described by Cotton, may be often much more perfectly reduced if the Achilles tendon is divided.

General Methods of Treatment of Fractures.—Ashhurst [84] reports thirty-seven cases of joint fracture in which he has used with great

75. Glaspel: End-Results from Treatment of Compound Fractures of the Femur by the Caliper Method, J. A. M. A. **71**:649 (Aug. 24) 1918.

76. Crile, D. W.: Employment of Calipers in Fractures of the Femur, J. A. M. A., **72**:789 (March 15) 1919.

77. Eastman and Bettman: Surg., Gynec. and Obst., October, 1917.

78. Fresson and Toupel: Rev. de chir., Sept.-Dec., 1918.

79. Besley: Value of the Caliper in Obtaining Extension in Compound Fractures of the Femur, J. A. M. A., **70**:87 (Jan. 12) 1918.

80. Pearson: Brit. M. J., Aug. 24, 1918.

81. Gray: New York M. J., June 22, 1918.

82. Hawley: A Combination Finochietto and Steinman Pin Traction Stirrup, J. A. M. A., **70**:22 (Jan. 5) 1918.

83. Dowd: Ann. Surg. **70**:22 (Sept.) 1918.

84. Ashhurst: Jour. Med. and Surg., Oct., 1918.

satisfaction the Lambotte screw, which is long, light, and with a thread between that of a wood screw and a machine screw. It can be driven directly without drilling and does not splinter.

Blake [85] has made notable contributions to the treatment of fractures. He is strongly in favor of traction and suspension methods, many of which he has himself devised.

A paper by Groves [86] deals with a series of sixty consecutive cases treated by him during the last two years, and refers almost entirely to gunshot injuries. Loss of substance was the most important factor in the production of nonunion. This cause accounted for thirty-four cases (56.6 per cent.). Necrosis, which is a common cause of delayed union, but a very rare cause of nonunion, was operative in three cases. In twenty-one cases, nonunion was due to displacement of the main fragments. In two cases, eburnation was the cause of nonunion. The series contains thirty-four cases of autogenous bone grafting. Of these, ten (29.4 per cent.) have been failures, five (14.7 per cent.) have been eventual successes in producing bone union after extrusion of the graft, and nineteen (55.8 per cent.) have been complete successes. In every one of the fifteen cases in which success was not complete, the cause of failure was traced. The reasons for failure were:

The operation was performed too early.

There was scanty contact between the graft and its bed.

A sliding graft was used.

The patient fell on his arm and broke the graft, bursting open the wound.

The graft was laid in unhealthy bone which should have been removed.

Too complicated a procedure was adopted and the patient died of shock.

The humerus was not immobilized adequately, and the arm, hanging on the graft, broke the fixation. Scars in front of the tibia were not sufficiently replaced by healthy tissue before grafting. Periosteal flaps with thin bone scales adhering to them were turned down over the gap and produced only a thread of bone.

The conclusions of the Committee on Fractures appointed by the American Surgical Association and presented by Estes and others [87] may be important from a medicolegal standpoint .

1. Results are best in the age period under 15 years. Conservative treatment is generally effectual during this period.

---

85. Blake: *Gunshot Injuries of the Extremities*, Paris, Masson et Cie., 1918. Blake and Bulkeley: Surg., Gynec. and Obst., March, 1918.

86. Groves: Brit. J. Surg., October, 1918.

87. Estes and Others: Ann. Surg., August, 1918.

2. Good anatomic restitution of a fractured long bone always results in best functional result and has the shortest period of disability.

3. While few open operations are recorded under the 15 year period, it seems to make little difference in the result what the age period is in which the operation is done, save in senile cases.

4. The end-results of nonoperative and operative treatment of compound fractures show very little difference in the anatomic result, but the functional results are better after operative treatment except in compound fracture of both bones of the legs. Here the reverse is the rule.

5. The average period of disability is: fracture of shaft of humerus, 14 weeks; fracture of head and neck of humerus. 11.5 weeks; fracture of condyles of humerus, 9 weeks; fracture of shaft of both bones of forearm, 10.8 weeks; fracture of femur (all sites), 6.2 months, and fracture of leg (all sites), 4.9 months: compound fractures of femur, 13 months; leg, 6 months, and upper extremity, 4 months.

6. The humerus should show not more than 1 cm. shortening and no appreciable angulation. Forearm bones should show no appreciable shortening, and rotation should be unhindered. Function should always be good and without lasting pain. Fracture of the femoral shaft should not show shortening of more than 2 cm. nor a fixed position of angulation or rotation. No permanent disability should result. Fracture of the shaft of the bones of the leg should result in no appreciable shortening and no angulation or rotation.

7. No method or splint is universally applicable nor has any one proved its superiority. All depends upon the discrimination of the surgeon and the manner in which the apparatus is applied and maintained. Traction methods are most frequently unskilfully employed. Plaster casts and molded splints are especially indicated and useful after a fracture has been satisfactorily reduced.

Gazzotti's [88] researches seem to show that in the healing of fractures the presence of a hematoma stimulates the periosteum to greater regenerating activity.

BONE GRAFT SURGERY

Dauriac,[89] after a wide experience, expresses great satisfaction with the results he has obtained in repairing losses of bone substances by using the methods of bone grafting devised by Albee. He believes firm contact of the ends retained only by absorbable sutures is the most essential. He uses only autogenous grafts.

---

88. Gazzotti: Policlinico, May, 1918.
89. Dauriac: Bull. de l'Acad. de méd., Nov. 12, 1918.

Imbert,[90] after experimental animal study, has become convinced that tibial grafts are more successful than rib or fibula grafts and that close fitting pointed ends, well embedded, are important. His subcutaneous grafts in animals always disappeared. He believes that even in the inert bone of old pseudarthosis, bone grafts stimulate new growth and union better than any other method. He is convinced that the fate of a bone graft is often uncertain for several years.

Gaenslen,[91] after an experience which justifies opinion, has become dissatisfied with intramedullary grafts. In all cases of nonunion he feels it of great importance to remove completely the eburnated bone ends.

Billington [92] is convinced that in bone grafts of the jaws no metal plates or wires should be used. Disfiguring sinuses almost always occur. The graft, with care, may be well fixed with slowly absorbable sutures and careful approximation of the surrounding soft parts.

Brooks [93] reports three cases of fracture of the tibia following the removal of bone grafts by the motor saw in patients who were allowed to walk on the limb at the beginning of the fifth week. He urges a longer period of protection.

Cowan and Ely [94] have been studying the fate of autogenous bone buried in living bone, either the patella or fragments of the femoral condyle or tibial head inserted into the bone of resected knee joints in dogs. Fourteen observations were made 432 days after operation. In none of the cases was there complete disappearance of the graft; although this tendency was shown in all, the borders were absorbed or replaced. There was either a rarefying osteitis or absorption of bone in the interior. Cartilage or bone covered with periosteum was found to be no more resistant than marrow. The bone slowly disappears and fibrous tissue takes its place. They say that the changes resemble roughly those seen in chronic arthritis of the atrophic and ankylosing types.

Gallie [95] has made important studies in relation to the fate of boiled bone implants. He believes that the most important thing is good external bony contact for the graft, rather than the character of the graft itself. Any kind of graft of transplanted bone loses its character and is invaded by new blood vessels and connective tissue which is replaced by the activity of the osteoblasts from the surrounding bone

90. Imbert: Presse méd., May 9, 1918.
91. Gaenslen: J. Orthop. Surg., October, 1918.
92. Billington: Brit. M. J., Dec. 21, 1918.
93. Brooks: J. Orthop. Surg., June, 1918.
94. Cowan and Ely: J. Orthop. Surg., February, 1919.
95. Gallie: J. Orthop. Surg.. June, 1918; Brit. J. Surg., October, 1919.

tissue. Especially, as has been more recently shown, these osteoblasts on the surface of the living bone graft have to build or help to build up the bone. Except for these few osteoblasts, the autogenous bone graft has no advantage over the boiled bone. In using boiled bones, it must be remembered that the graft is dead and must depend for its replacement on the osteoblasts in the tissue about it. Perfect contact with the living bone must be obtained. Careful preparation beforehand of the bone splint to make sure of the correct curve or angle and length is very important. There exists a doubt as to whether the boiled bone graft would be able to stimulate the building of a bridge over a gap between bony points. He concludes that it is not safe to expect new bone to replace the boiled bone if the gap between the living bone contacts is more than three-fourths inch.

OSTEOMYELITIS

Harde and Houser[96] are convinced that as regards successful primary or early secondary closure of bone sinuses, cases of osteomyelitis may be divided into two classes: (1) those that show streptococci, and (2) those that do not. The former must be thoroughly disinfected by wide surgical removal of bone followed by Carrel-Dakin sterilization before closure, and the latter may often be closed at once or very early.

Bonneau,[97] in charge of a hospital in which cases of bone sinuses were segregated, has become convinced that really thorough surgical cleansing of the fistula may be counted on for a cure. He emphasizes the necessity of thorough removal of the sclerosed soft tissue and the sacrifice of often formidable amounts of sound bone, converting all ramifying cavities into flat surfaces and covering them with the mobilized soft tissue.

Luzoir,[98] writing on osteomyelitis of the spine, summarizes some recent cases and calls attention, as Kirmisson did in 1909, to the characteristic oblong shape of the swelling over the inflamed vertebrae, almost spindle shaped. Another common early sign is the manifest collateral circulation in the region. The acute cases are usually secondary to some infection elsewhere and puncture of the swelling will usually show staphylococcus pus. Some of the cases run a subacute almost chronic course, and are differentiated from tuberculosis chiefly by the oval outline of the swelling. Staphylococci are frequently found in the spinal fluid. The treatment is drainage and removal of the necrosed laminae and spinous processes.

---

96. Harde and Houser: Presse méd., March 28, 1918.
97. Bonneau: Paris méd., Aug. 10, 1918.
98. Luzoir: Presse méd., July 23, 1918.

Tassone[99] describes the characteristic posttyphoidal bone lesions occurring during convalescence or even months later. They are usually associated with fever and he has noted them most frequently in the tibia, metatarsals and scapula.

[Ed. Note.—One of the Editors has seen a case in which the bone lesion preceded a typical attack of typhoid fever. We have seen the lesions in other cases, in the forearm, the femur, and in several cases in the spine.]

JOINT SURGERY

Metcalfe[100] analyzes eighty-eight cases of war wounds involving the knee joint, giving his conclusions as to the treatment of the different types. In discussing immobilization versus mobilization, he advises immobilization for all cases in which the synovia is closed or has been closed at operation, for joint resections and all other primary closures, for fractures of the patella and all extensive destruction of joint surfaces. He advises mobilization (voluntary) for septic joints with open wounds and cases treated by delayed primary or secondary suture. Conservatism in the treatment of all wounds of the knee joint except those frankly septic is advised by Monprofit and Courty,[101] Schwartz,[102] Judd,[103] and Delmas.[104] They all agree that occasionally a resection or a complete laying open of the joint by a U-shaped incision through the patellar tendon is necessary as a life saving measure, but that sepsis can be controlled usually by small incisions without drains, running into the joint, but with the voluntary motion of Willems instituted at once. In early cases the joint can be washed out and at least the synovia closed tight. Of course, these remarks refer to cases without bone lesions or with very slight bone lesions.

McWilliams and Hetzell,[105] in a report to the American Surgical Association, believe that much better results have been obtained in septic joints by the Willems treatment of immedate frequent voluntary movements than by any form of immobilization.

Laubie[106] makes a plea for simple aspiration in cases of hydarthrosis and mild infections. The aspiration is followed by lavage with a 1 per cent. phenol solution, and motion is allowed. If the joint is very

---

99. Tassone: Gazz. d. osp., May 1, 1919.
100. Metcalfe: Ann. Surg., March, 1919.
101. Monprofit and Courty: Paris méd., July 20, 1918.
102. Schwartz: Paris méd., Sept. 29, 1917.
103. Judd: Surg., Gynec. and Obst., February, 1918.
104. Delmas: Rev. de chir., Jan.-Feb., 1918.
105. McWilliams and Hetzell: The Willems Treatment in Knee Joint War Injuries, J. A. M. A. **73**:221 (July 19) 1919.
106. Laubie: J. de méd. de Bordeaux, June, 1918.

sensitive, he injects 4 or 5 c.c. of a 1 per cent. solution of cocain before the lavage is given.

[ED. NOTE.—The Editors have seen several cases of purulent effusion in the knee joint, secondary to septic processes elsewhere in the body, in which radical operation was for one reason or another contraindicated. Repeated aspirations were performed as a palliative measure with little hope of controlling the process, but to our surprise these joints have quieted down and regained large ranges of motion.]

Sir Berkeley Moynihan's [107] conclusions as to the treatment of wounds of the knee joint, especially front line treatment, are valuable:

1. All knee joint wounds should be absolutely immobilized at the earliest possible moment.

2. At the first opportunity, they should be roentgenographed and prepared for operation.

3. Essentials of operation: (*a*) débridement following trail of projectile; (*b*) free exposure of joint; (*c*) removal of all foreign bodies; (*d*) wounds closed in layers, drainage by gaps in sutures and drains down to, but never into, the synovial cavity.

4. In cases of severe infection, especially by streptococci, wounds must be reopened, the synovia sutured to the skin, and Carrel-Dakin treatment instituted.

5. In severe comminutions of articular ends, resection is advised.

6. In severe and extensive wounds without serious infection, the ends of the resected bones should be separated.

7. In extensive damage to the bones with severe infection, amputation is advised.

Leriche [108] has constantly advocated primary resection of joint wounds involving the articular ends, but insists that the resection must be performed subperiosteally. He strives to regain a periosteal sheath or capsule which assures the continuity of the sustaining soft tissues and leaves the supporting ligaments intact. He states that as the bone tissue reforms, the sheath of periosteum limits as well as aids its growth, and that the play of the undisturbed muscles molds it into shape. He credits the method to Ollier.

Leclerc [109] reports fifteen "good results" from eighteen secondary resections of the elbow joint for septic arthritis. Eleven patients have stiff elbows, two patients have flail joints, one has nearly normal motion. In some of the cases, arthrotomy had failed to control the sepsis.

---

107. Moynihan: Boston M. & S. J., Nov. 22, 1917.
108. Leriche: Lyon méd., December, 1917.
109. Leclerc: Lyon méd., October, 1917.

Chutro[110] and Alquier and Tanton[111] report good results from resection of the hip joint for septic war wounds. Chutro reports nine cases with "functionally capable" joints and an average shortening of 9 cm. Alquier and Tanton have had twelve cases, with solid ankylosis in eleven.

That resections of joints to control sepsis are not always successful and frequently leave very useless limbs is maintained by Osgood,[112] who reports numerous failures he has observed in a base hospital receiving cases from the front. The statistics of Nové-Josserand and Tuffier,[113] who reviewed, in 1916, the functional results of 1,132 resections of joints of the upper extremity and 678 of the lower extremity performed for war wounds, 80 per cent. of the primary resections of the shoulder and 70 per cent. of the elbows were unsatisfactory, 32 per cent. of the secondary resections of the elbow were bad; the primary resections of the knee were better than the primary resections of the elbow, but the secondary resections of the knee were less successful than the secondary resections of the elbow.

Daw,[114] after a study of the methods for regaining mobility in joints stiffened as a result of gunshot wounds, reaches the following conclusions:

1. Improvement in mobility is more likely to be gained by slight movements followed by periods of rest or by slow stretching of contracted parts rather than by forcible movements carried through a large range.
2. Open operations to obtain mobility are rarely advantageous except in the elbow joint.
3. Passive movements have limited value and are often harmful.
4. Active movements, especially those of normal use and occupation, are as a rule more valuable than surgical measures.

MOBILIZATION OF JOINTS

Willems[115] may be said to have revolutionized the treatment of septic joints, and his methods have been generally adopted by those who have observed his results, despite the fact that most surgeons because of their former teaching and what they believed had been their experience approached the subject with strong prejudice. Willems evacuates the effusion or pus in a joint at once by small incisions and

110. Chutro: Presse méd., October, 1917.
111. Alquier and Tanton: Jour. de chir. **14**, 1917.
112. Osgood: J. Orthop. Surg., October, 1918.
113. Nové-Josserand and Tuffier: Bull. de l'Acad. de méd., May 16, 1916.
114. Daw: British J. Surg., October, 1918.
115. Willems: Arch. méd. belges, March, 1918.

insists upon the patient's moving the joint by the voluntary action of his muscles as soon as he has recovered from the anesthetic. Passive motion is absolutely contraindicated. The patient declares he cannot do it, but must be persuaded. Willems insists that this immediate exercising of the joint is not painful in the true sense of the word unless the incision has glued together and a secondary effusion has occurred. In this case, this is at once evacuated surgically and the pain on motion disappears. With serious damage to the bone ends, Willems admits that immediate motion is painful and unwise because it causes displacements of the fragments, but with fractures of the patella he ties silkworm gut around it and starts the patient moving his knee in five or six days. Unless the intra-articular fractures preclude the possibility, the patients are encouraged to walk with their knee wounds still open. Willems maintains that in purulent arthritis this movement and function of the joints affords the most perfect drainage and gives the most surprising results.

Caestecker [116] describes the application in forty-two cases of Willems' method of puncture, followed by immediate walking, using the knee. The puncture is made under stovain local anesthesia, the knee having been prepared as for a major operation. The operator stands on the patient's right side, whichever knee is to be operated on. With his left hand, he pushes the fluid forward until it lifts the patella, and the lateral culdesacs protrude. With the right hand, the bistoury is introduced close to the edge of the patella about half way up. As the bistoury enters the cavity, it is moved for a quarter of a circle to make the incision gape. Then the operator manipulates the joint to force all the fluid out through the puncture hole, held open by the bistoury. Then the bistoury is straightened and withdrawn. A small loose dressing is applied, and the patient begins to walk as soon as he gets off the table. At first, he is afraid to use his knee, but as soon as he can be persuaded to take a few steps he finds that it does not hurt him and he is "turned loose" with the advice to keep on walking, even to the point of fatigue. With simple hemarthrosis, the blood does not clot for several days. Whenever clots are found, this indicates some lesion in bone or cartilage. Twenty-five hemarthrosis cases are described in detail. The cure is very rapid; all objective findings returning to normal in three or four days, and the last trace of the subjective disturbances vanishing by the end of the first or second week. No tendency to atrophy of any muscle was observed in any instance. The effusion returned in 23.5 per cent. of the seventeen hydrarthrosis cases and in 4 per cent. of the others, but they yielded to a second puncture. He insists that there is no exception to the rule

116. Caestecker: Arch. méd. belges, March, 1918.

that every case of effusion in the knee should be punctured and the knee used at once.

In a later article, Willems and Caestecker[117] advise immediate voluntary motion and weight bearing after removal of joint mice and deranged cartilages from the knee, and report seventeen cases in soldiers, several of whom returned to the front in two weeks. If effusion occurs, it is aspirated and motion continued.

[Ed. Note.—The Editors doubt the necessity, if not the wisdom, of these immediate voluntary motions after clean operations for internal derangements of joints. Willems admits that in these tightly closed cases, these motions are often painful and effusions occur. On the other hand, following the meticulous technic of the properly performed cartilage or joint mouse operation, the knee being kept at rest or even completely immobilized for a week, there is frequently no subsequent effusion, little or no pain, and nearly normal motion and painless functional use in two weeks. It is quite possible to ride a hobby too hard.]

Kouindjy,[118] in a strong article, deplores the fact that joints in the neighborhood of wounds are allowed to become stiff from disuse and fixation. Judging from the frequent occurrence of these secondary ankyloses, which are often more crippling and prolonged than the original lesion, surgeons cannot be too often reminded of this fact, which in the light of our present knowledge amounts today to nothing short of malpractice.

Hamilton's [119] article on arthroplasty of the thumb and finger joints is worthy of comment since these operations have in many surgeons' hands been unsatisfactory. He believes his successes have been due to (1) large enough incisions (lateral) to give free access; (2) careful modeling of the bone ends to conform to the original contours; (3) interposition of free fat fascia autogenous transplants; (4) accurate suturing of the soft parts; (5) application of traction for three weeks until circulation in the flap has been established; (6) motion after three weeks; (7) absolute asepsis.

Baer [120] has reopened four joints in which arthroplasty with animal membrane had been performed. In each case, he found that the joint space persisted and the lining was perfectly smooth. The microscopic examination demonstrated that the membrane is transformed into a fibrous tissue which covers the bone and that a joint-like space is formed with fibrous walls like a cavity encysting a foreign body.

The advantages of the membrane are: (1) The joint will retain as near its normal size and shape as possible; (2) the simplicity of the

117. Willems and Caestecker: Arch. méd. belges, December, 1918.
118. Kouindjy: Paris méd., October, 1918.
119. Hamilton: Texas State J. M., March, 1919.
120. Baer: J. Orthop. Surg., January, 1918.

operation; (3) the stability of the joint; (4) less chance of infection because of the lessened handling; (5) less painful after-treatment, because movements are not begun before three weeks; (6) a normal joint is the ultimate result, no foreign substance is left, as the membrane is absorbed within from sixty to one hundred days.

The membrane must be (1) thin and flexible; (2) tenacious to withstand disintegration for from sixty to one hundred days; (3) durable; (4) absolutely sterile. The membrane is made thus: The pigs' bladders, carefully selected, are thoroughly cleansed and disinfected and the submucosa obtained. They are then soaked for twenty-four hours in a medium hard potassium chromate solution, after which they are cut into the proper size, stretched on boards and exposed to the sunlight for three days, until the color corresponds to the reduction of the chromic salt. After being freed from all their soluble chromic salts they are thoroughly dried and are then inserted into sterile glass tubes containing chloroform. At the time of operation, these tubes are boiled for five minutes. The tube is then broken and the membrane placed in normal salt solution for ten minutes before using.

Baer reports 100 cases with sixty-eight good results, painless and useful joints with more than 25 degrees of motion, as far as the hip and knee are concerned. For the knee, he uses now the horseshoe incision through the patellar tendon, because the time of absolute rest, which is four weeks for the knee joint, allows a perfect union of the divided tendon. In several cases of old tuberculosis, the disease has lighted up again.

[Ed. Note.—The Editors have yet to see any considerable number of cases in which arthroplastic operations have been performed in bony ankylosis of the knee in which the results have seemed in their opinion to justify the operation.]

Phemister and Miller [121] have studied the changes which follow the resection of joint surfaces in arthroplastic attempts when no flaps, free flaps, and pedunculated flaps were employed. Dogs were operated on by all these methods and the results showed that it matters little which method is used. The important factors are the construction of well fitting joint surfaces, the excision of obstructing tissues, and the after-treatment to maintain mobility.

TENDON TRANSPLANTATION

Serafini,[122] describing various methods of tendon transplantation for radial nerve paralysis, emphasizes a point which the Editors believe is of great importance if success in tendon transplantation is to be

121. Phemister and Miller: Surg., Gynec. & Obst., April, 1918.
122. Serafini: Chir. d. org. di movimento, April, 1918.

secured. This point is that any malposition or deformity must be thoroughly corrected before any transplantation is attempted. The transplanted tendon always works at a disadvantage at first and ought not to be expected to overcome deformity in addition to its new functional adaptation.

Nageotte and Sencert [123] report success in bridging gaps of from 3 to 4 cm. in the flexor tendons of the wrist by introducing segments of dogs' tendons which had been kept in alcohol for a month. The aponeurosis of the brachialis was drawn over the sutured tendon and the skin sutured tight. Great functional improvement was gained. The report of their experimental research in the use of these dead, preserved tissues is interesting and seems to prove the safety and value of their methods.

Delorme [124] examined their case after their article was published and found that practically complete use of the hand had been regained. He urges the further application of this technic.

Slomann,[125] in a case of paralysis of the deltoid, supraspinatus, infraspinatus, and a part of the pectoralis major, has transplanted the long head of the triceps into the acromion process by detaching it from the scapula and bringing it backwards around the head of the humerus. In six weeks, an elevation of 45 degrees was possible and the patient could raise his hand to his mouth.

Biesalski and Mayer [126] have published a book on physiologic tendon transplantation. They believe that the frequent poor results from old methods of transplantation which have brought the procedure into disrepute are due to the fact that so often the gliding mechanism has been destroyed. They have employed two new types of operation: (1) transplanting the tendon through the sheath of a paralyzed muscle; (2) transplanting the mesotenon in conjunction with the tendon. Fourteen operative procedures have been worked out and are clearly illustrated. The book includes a good deal of anatomic and physiologic research, the nutrition of the tendons, and the comparative strength of the muscles of the leg.

Duvergey [127] has employed the cicatricial tissue, binding together old stumps of tendons to form the bridge. He models this into the shape of a tendon, and cutting it in the middle, pulls over one end a long piece of the excised internal saphenous vein below its junction with

123. Nageotte and Sencert: Bull. de l'Acad. de méd., Nov. 12, 1918; Presse méd., Dec. 9, 1918.

124. Delorme: Presse méd., Dec. 19, 1918.

125. Slomann: Wchnschr. f. Aerzt., 1915.

126. Biesalski and Mayer: Berlin, Julius Springer, 1916.

127. Duvergey: Presse méd., Jan. 7, 1918.

the femoral vein. The cut ends are then reunited and the vein pulled down as a sleeve to prevent readhesion.

CORRECTION OF DEFORMITY

Putti [128] advocates a Z-shaped osteotomy of the femur in cases of marked shortening in old fractures of the femur. The bone is sawed at a distance from the old fracture. The traction necessary to secure the desired lengthening is obtained by means of inserting two long screws into the femur above and below the osteotomy and fastening them into a stout bar running parallel to the femur, which bar can be lengthened at will. He reports gains of as much as 7 cm.

Fassett [129] states that 2 cm. can be added to the length of an osteotomized femur, but at a cost of time and hardship which he considers too great for the gain. He believes that shortening of the longer limb is the better procedure. Six or 7 cm. may be sacrificed without serious loss of muscle tone. He considers that the simplest procedure is to remove a simple cylinder of bone and to fix the approximated fragments by a bone splint or a Lane plate. Calvé and Galland,[130] while agreeing that shortening of the longer limb is the operation of choice, advise a slanting cut of one bone end. The other bone end is left with a small button of bone on its end, but so shaped below this button as to fit the slanting cut of the other fragment. Above this slanting surface, a notch is cut, into which the button of bone left on the lower fragment is made to fit. This obviates any other method of retaining the fragments in place.

ROENTGENOLOGY

Sgobbo [131] states that several Italian surgeons have noticed that callus did not form as usual in certain fractures which had been repeatedly subjected to roentgen-ray examination. A series of experiments on dogs has seemed to confirm his suspicions that roentgen rays exert an inhibitory influence on callous formation.

Lawrence [132] has devised the following method of obtaining satisfactory lateral views of the shoulder joint: The patient is placed on his well side, the roentgen-ray tube is placed below, the plate is placed on top of the affected shoulder. The patient takes a long breath, which raises the sternum, and while he holds this deep inspiration, the picture is taken.

---

128. Putti: Chir. d. org. di movimento, December, 1918.
129. Fassett: J. Orthop. Surg., September, 1918.
130. Calvé and Galland: Arch. de méd. et pharm. mil., May, 1918.
131. Sgobbo: Riforma med., April 13, 1918.
132. Lawrence: Am. J. Roentgenology, April, 1918.

Snell[133] has made a careful study of the shape and ramifications of the capsule of the knee joint by injecting the joint postmortem with bismuth paste and taking roentgenograms.

RESEARCH

Leriche and Policard[134] attempt to clarify our conception of the rôle of the periosteum. The point which they very properly make is that the discussion as to whether the periosteum is or is not osteogenetic is futile as long as we consider it as an anatomic rather than as a physiologic entity. Their researches show that if it is meticulously dissected as a fibrous membrane only, it has little or no osteogenetic power, but if it is taken with bone cell scrapings or with thin slivers of bony tissue immediately beneath it, new bony tissue may be produced almost at will. If, in other words, the fibrous membrane is contacted with living bony tissue it plays its important part in bone regeneration and acts as a limiting membrane as well.

Nyström[135] has made a study of the sensibility of bone to pain, using himself as a confirmatory subject, by having one of his surgical friends drill a hole through his own tibia. The periosteum is rich in sensory nerves and the marrow possesses a few, but the bone itself has no sensibility to pain. If the marrow is irritated over a considerable area there is an aching sensation, but a small prick is hardly felt. He discovered also that the cartilage of joints and the cartilage of the epiphyses were devoid of sensibility.

[Ed. Note.—In operating on bone under local anesthesia we have been frequently surprised to find that once the periosteum is passed, much can be done to bone without any considerable discomfort to the patient.]

Kirsh,[136] employing rabbits in his studies, has found that pieces of free muscle transplanted into living tissue heal in, but after two hours the electrical and mechanical irritability has disappeared and after four and eight-tenths hours complete degeneration of the nuclei has taken place. The process of regeneration begins early in the transplanted piece and in the muscle from which it has been removed.

APPARATUS

Alquier and Tanton[137] have published a book on the various forms of apparatus which the French have employed to immobilize the com-

133. Snell: Brit. M. J., June 29, 1918.
134. Leriche and Policard: Presse méd., March 18, 1918.
135. Nyström: Upsala Läkaref. Forhandl. **22**: 1917.
136. Kirsh: Festschr. der Cölner Akad., 1915.
137. Alquier and Tanton: Paris, Masson & Cie., 1917

pound fractures suffered in the war. In their introduction they deal with the surgical treatment of these wounds, and then with copious illustration discuss the apparatus which in their opinion has proved of greatest value in the French military service.

The Medical Department of the U. S. Army [138] published in December, 1917, a Manual of Splints and Appliances, including standardized surgical dressings. The standard splints were used throughout the war, both as transport splints and to a large extent in the base and general hospitals overseas and in America, and have proved their value.

Osgood [139] has described these transport splints and their use and outlined the purposes of this standardization. He finds they served their purpose admirably, embodying as they did, inexpensive construction, simplicity of design, ease of transport, efficient mechanical principle, universal adaptability. The important details of their use were quickly taught by instructors from the orthopedic section and were readily grasped by the stretcher bearers and regimental surgeons. No one can estimate the amount of suffering which they saved nor the number of deformities they prevented.

The lessons which the British Medical Department, through Major-Gen. Sir Robert Jones, taught were largely responsible for their adoption by our Army. One order from General Pershing made their employment universal to an extent never attained even by the British themselves, although several of the standard splints of the British and American armies were identical.

MISCELLANEOUS ORTHOPEDIC ARTICLES

Graessner [140] has examined 492 roentgenograms of the lumbosacral region and found among them 78 cases of spina bifida occulta, or as he prefers to call them, myelodysplasia. In ten of these, the operation performed by Cramer showed that soft tissue pressing upon the nerves was the cause of sensory and motor disturbances. Graessner believes that in industrial accidents these tissues which connect the skin with the spinal canal in cases of spina bifida occulta may be stretched or so injured by the accident as to cause injury to the nerve elements with which they are connected. Thus, the accident may be the exciting cause of motor and sensory disturbances remote from the site of injury.

---

138. Manual of Splints and Appliances. Medical Dept., U. S. Army. Ed. 1. New York, Oxford Press, 1917: Ed. 2. Paris American Red Cross.

139. Osgood: The Transport Splints of the American Army. J. A. M. A., **71**: 734 (Aug. 31) 1918.

140. Graessner: Festschr. der cölner Akad., 1915.

Hey-Groves [141] has devised an ingenious and, in his hands, a successful operation for the repair of torn crucial ligaments of the knee joint. The principle of his operation consists of utilizing the iliotibial band for the anterior crucial and the tendon of the semitendinosus for the posterior crucial. In both cases, he retains its upper attachments in the thigh and threads them through new canals bored through the femoral condyles and the tibial head in line with the old torn crucials. Sufficient length may be secured to turn them upward again after their emergence from the tuberosities of the tibia and thereby form new internal or external lateral ligaments of the knee if these have been injured or weakened. The knee joint must be fully opened for these procedures and Groves was employing, when observed by one of the Editors, a U-shaped incision through the infrapatellar tendon and lateral expansions.

McMurray [142] has repaired a rupture of an internal lateral ligament of the knee joint by changing the insertion of the sartorious muscle tendon from the inner aspect of the upper end of the tibia to the inner aspect of the lower end of the femur, laying it into a groove cut in the femoral condyle after the tendon has been carefully exposed and isolated from its insertion into the internal lateral ligament. The tendon is drawn tight and the ligament sutured, while the knee is in the semiflexed position. The knee is retained in a semiflexed position in plaster for three months.

Askgaard [143] estimates that about 25 per cent. of the patients with syringomyelia develop joint lesions. Although the joint lesions closely resembling those of tabes have remissions and may remain stationary, many of the cases demand surgical interference. The rarity of successful union following resection makes amputation in his opinion often the operation of choice in completely incapacitated joints.

Steindler's [144] work on reconstruction in the hand and forearm in congenital defects and paralytic conditions deserves special mention. It is the result of wide experience, careful study, and the methods which he has employed are original and ingenious. His plastic operations on the forearm muscles for poliomyelitis, in which he dissects the ulnar group from the inner condyle and inserts it higher up into the intermuscular septum, give real though weak power of flexion to elbows otherwise lacking it. This power is of greatest importance in allowing the patient to bring his hand to his face. Steindler's work is worthy of close attention and is based on sound principles.

---

141. Hey-Groves: Lancet, Nov. 3, 1917.
142. McMurray: Brit. J. Surg., January, 1919.
143. Askgaard: Hospitalstidende, Aug. 29, 1917.
144. Steindler: New York M. J., Dec. 21, 1918.

Soutter [145] has written a most useful book on the Technic of Operations on the Bones, Joints, Muscles, and Tendons. The illustrations are clear line drawings and the important operative procedures in both adult and children's lesions are described. We have long felt the need for grouping these operations in one work, and for clear description of the lines of skin incision, anatomic approaches and actual operative technic of the corrective measures.

Lovett [146] makes a plea for more fundamental methods in teaching in orthopedic surgery and in medical teaching in general. It is desirable, for example, not to describe bow legs and coxa vara as clinical entities, but to outline the processes of bone growth, ossification, and the common disturbances. Thus rickets would be taken up as the most prevailing of these disturbances, the changes in shape of the bones resulting from mechanical influences. The treatment for the underlying condition is appreciated, therefore, as the most important element in the cure and the local treatment for the local lesion has been given its proper background. The necessity for this stressing of the fundamentals was emphasized by the teaching of military surgeons. First must come the idea of the principles involved and then the illustration of these principles in clinical cases. This is the reverse of the case teaching method. In the orthopedic military instruction given by the author in the Boston School, the subjects taken up were these: affections of joints; diseases and affections of bones; affections of the neuromuscular mechanism; static affections; congenital deformities; apparatus reconstruction.

Sir Robert Jones [147] has surely done more than any living man toward dignifying and advancing orthopedic surgery. His book on Military Orthopedics and his numerous articles give only a meager idea of the extent of his untiring work for the reclamation and prevention of cripples among the British wounded. His estimate that 50 per cent. of the battle casualties result in impairments of the locomotor function and usefulness of the limbs is probably too low, and from 60 to 70 per cent. would be more nearly correct. The British Government has finally recognized that orthopedic principles and methods are needed for the greatest possible restoration of function in these cases. In the prevention of these deformities, the general surgeon must share very largely, but for their correction the trained orthopedic

145. Soutter: New York, The Macmillan Company, 1917.

146. Lovett: J. Orthop. Surg., August, 1918; A Plea for a More Fundamental Method in Medical Teaching, J. A. M. A. **70**:1070 (April 13) 1918; Boston M & S. J., April 10, 1919.

147. Jones: Brit. M. J., Jan. 12, 1918; J. Orthop. Surg., May, 1918; Boston M. & S. J., Sept. 26, 1918; London, Cassell, Military Orthopaedics.

surgeon is eminently fitted. The orthopedic centers, or as they came to be called, the special surgical military hospitals, scattered all over the British Isles, represented the ideals which orthopedic surgeons in other countries strove to attain. To Sir Robert's foresight and energy these were due. His work has not ceased with the closing of the army hospitals. A wise government has continued to draw from his store of knowledge and his services to the Pensions Ministry have been of hardly less value to the Royal Army Medical Corps. We believe that to no man does the world owe such a debt of gratitude for lightening the enormous burden of the cripple as to Sir Robert Jones.

ARCHIVES OF SURGERY

VOL. 2 MAY, 1921 No. 3

REACTIONS TO THE PARENTERAL INTRODUCTION OF HORSE SERUM IN MAN

FRASER B. GURD, B.A., M.D.
MONTREAL, CANADA

The parenteral introduction of foreign protein in the form of antiserums is accompanied in a large proportion of cases by local and constitutional manifestations of irritation or intoxication. Such manifestations consist, in the majority of cases, in the development of urticarial and erythematous eruptions, joint or muscle pains, pyrexia and occasionally vomiting.

Such manifestations of the disease, though they may be annoying to the affected individual, and although, occasionally, the onset of an unexplained pyrexia in the course of the treatment of the wounded may cause anxiety to the surgeon in charge, are of comparatively little importance.

Unfortunately there occasionally occur, within a short time after the injection of the serum, more serious reactions. The symptoms in these cases comprise collapse, tachycardia, drop in blood pressure, unconsciousness, and occasionally difficulty or arrest of respiration with consequent cyanosis and air hunger. Such cases are often fatal.

In consequence of the very large number of serum injections performed during the war both in normal and previously injected persons, there has been a unique opportunity of studying the reaction of the human tissues to the parenteral introduction of horse serum protein. It is upon the results of observations upon soldiers, both in France and Canada, that this contribution is based.

Before proceeding to an analysis of the cases reported in this paper, it is proper to review the symptoms and signs of anaphylaxis as noted in experimental animals.

In the dog, the predominant reaction is one in which drop in blood pressure and acceleration of the heart rate are the most striking clinical features. Vomiting and diarrhea, the latter frequently bloody, are common. At necropsy, extreme dilatation of the vessels draining the upper abdominal viscera is noted. The liver, spleen, and kidney are congested, and the veins of the upper intestinal tract are distended. The bowel wall, in rapidly fatal reactions, is deep purple in color.

If the injections are made subcutaneously the reaction is not usually fatal, but is similar in nature. In the event of either a subcutaneous or intravenous injection having produced severe shock, which does not immediately prove fatal, there often supervenes a period during which the animal appears to have returned to normal. In some cases following such a period, there is a second onset of symptoms after the lapse of from two to twelve hours. This delayed reaction is similar in nature to the first, is more protracted, and is often fatal.

As compared with the splanchnic dilatation and consequent drop in blood pressure in the dog, the guinea-pig presents a very different picture, although this animal, too, is readily "shocked" by the parenteral introduction of the protein to which it has been sensitized. If the sensitized guinea-pig is injected intravenously with a small dose of protein, there is an almost immediate onset of symptoms. These symptoms consist of itchiness of the skin, as evidenced by the animal's scratching itself, excitability, convulsive seizures and paralysis, usually noted in the loss of power in the hind legs. The animal suffers from difficulty in breathing. Cyanosis develops and the animal dies from an arrest of respiration.

If immediate necropsy is performed, the heart will be found still beating. The lungs are voluminous, with rounded borders, and exhibit small hemorrhagic foci over the surface.

Occasionally, in guinea-pigs, more particularly in those that die at the end of from six to ten minutes following intravenous injection, there is evidence at necropsy of marked splanchnic dilatation.

If the guinea-pig receives its dose of serum subcutaneously or intraperitoneally, the onset of the reaction is delayed, is less severe, the amount of protein injected being the same and is frequently accompanied by a rigor as evidenced by the animal's shivering. A definitely delayed reaction following upon a period of apparent return to normal takes place less frequently in the guinea-pig than in the dog, but does sometimes occur.

In the rabbit, urticaria and localized cellulitis, accompanied occasionally by necrosis, about the site of subcutaneous injections, takes place in sensitized animals; and it is in these animals that such manifestations have been more generally studied (Arthus' phenomenon). The rabbit may also be so sensitized and shocked that dyspnea, convulsions, diarrhea and sometimes death may result.

In addition to the clinical manifestations noted herewith, examination of the blood of shocked animals may reveal diminution in complement content, leukopenia or leukocytosis and lengthening of coagulation time, as well as blood concentration.

It is evident from this brief résumé that different species of animals react in a manner typical for that species. Such a typical reaction occurs irrespective of the source of the protein. It is also evident that no one symptom is characteristic of the anaphylactic reaction in all animals, although in all animals the involuntary muscle tissue is apparently chiefly affected by the irritant.[1] The manifestations of intoxication are, moreover, influenced in the same animal by the size of the dose of protein, and the route of administration, as well as by the degree of hypersensitiveness on the part of the animal.

In man, it is evident from a study of cases that reactions of all three types occur, namely, urticaria and cellulitis, splanchnic dilatation and respiratory anaphylaxis, as in the guinea-pig. It would appear that both as a primary cause of death and also as subjecting the patient to the danger of a delayed reaction the splanchnic type is of most importance.

The cases which are analyzed in the following pages have been grouped under three headings:

1. Severe immediate general reactions: (*a*) death; (*b*) recovery.
2. Immediate focal reactions and moderately severe early reactions.
3. Focal and general delayed reactions.

I. SEVERE IMMEDIATE GENERAL REACTIONS—ANAPHYLACTIC SHOCK

Two cases that terminated fatally I have observed personally, and the notes of one case, hitherto unpublished, have been placed at my disposal. In addition to an analysis of these cases, three cases which have been recently reported in the English and American literature are employed.

In three of these six cases, death supervened following intravenous injection of the serum protein. In the remaining three, the route of administration was subcutaneous (possibly intramuscular).

Four cases are reviewed in which severe immediate reactions occurred, which, however, were not followed by a fatal termination. Reports of two of these cases are published for the first time, two have recently been reported in the literature (Tables 1 and 2).

In those cases in which the splanchnic type of reaction predominated, there occurred collapse, pallor, tachycardia, thready pulse, pain in the epigastrium and over the heart, increased intestinal peristalsis, rectal tenesmus, vomiting and blood concentration. The recurrent type of reaction occurred in half of the fatal cases.

1. Simonds, J. P.: The Fundamental Physiologic Reaction in Anaphylactic and Peptone Shock, J. A. M. A. **73**:1437 (Nov. 8) 1919.

The respiratory type of reaction was characterized by choking sensations, cyanosis, asthmatic dyspnea and arrest of respiration.

The cutaneous phenomena consisted of erythema urticaria and "angioneurotic" edema.

It is evident from Tables 1 and 2 and from the subjoined case reports that in many cases both splanchnic and respiratory reactions took place, and in three of the four nonfatal cases, cutaneous phenomena were noted.

An abstract of a case report[2] of a healthy man who collapsed following the hypodermic administration of a relatively small dose, 5 c.c. of horse serum, and who died with symptoms during life identical with those which occur in anaphylactic shock in the dog, is given herewith. Necropsy findings were identical with those which are found in the guinea-pig.

REPORT OF CASES

CASE 1.—Sgt. E., aged 30, was given 5 c.c. of serum subcutaneously over the right pectoralis major at 11:15 a. m., Sept. 1, 1916. He was in good general condition, the wounds from which he was suffering being trivial.

At 1:30 p. m., he commenced to vomit and a bloody diarrhea developed. This gastro-intestinal disturbance was accompanied by a moderate degree of collapse. At 5 p. m., his pulse was 104 and his temperature 102.8 F. He complained of moderate headache and thirst; there was slight generalized abdominal tenderness, but no rigidity. He made no complaint of respiratory distress, despite the fact that he was cyanosed and restless. The skin was "goose-fleshed" and covered with a mild erythema.

Until 11 p. m. his condition remained somewhat relieved. No treatment was instituted as his condition was not considered alarming.

At 11 p. m., after a slight vomiting attack, the collapse became very severe. He became pulseless at the radials; the heart beat rose to from 160 to 170 per minute. He became extremely cyanosed, and restlessness increased. During the night, stimulation was pressed to the utmost. Pituitary extract, 1 c.c. to the dose, was given every three hours. One-thirtieth grain of strychnin was given at 11 p. m., and its administration was continued in doses of one-fortieth grain every three hours. He received three pints of saline subcutaneously during the night, and oxygen was given almost continuously up to the time of death. Except for the fact that he became quieter and more comfortable while receiving oxygen, there was no response to stimulation.

At 6 a. m., September 2, these notes were made: "Pulse is absent at the wrist, heart rate 180 and feeble. There is a very marked purplish discoloration (cyanotic erythema) of the whole body. This discoloration disapppears on pressure and returns very slowly. The extremities are cold. There has been no return of vomiting or diarrhea."

Death ensued at 10:30 a. m., apparently due to cardiac failure secondary to drop in blood pressure. Respirations during the last three hours of life were at the rate of from 48 to 54 per minute.

---

2. Gurd, F. B., and Emrys-Roberts, E.: Fatal Anaphylaxis, Lancet **1**:763 (April 3) 1920.

TABLE 1.—Reactions Following the Administration of Serum Protein in Six Fatal Cases

Case	Author	Route of Administration	Amount Injected in C.c.	Dilution	Length of Time Supervening Before Onset of Symptoms	Length of Time Between Injection and Death	Type of Action	Treatment Employed	Most Striking Features
1	Gurd	Subcutaneous	5	Undiluted	135 Min.	19 Hrs.	Splanchnic recurrent (respiratory)	Pituitary extract, strychnin, subcutaneous saline	Collapse, cyanosis, erythema, recurrent collapse
2	Gurd	Subcutaneous	5	Undiluted	150 Min.	11 Hrs.	Splanchnic recurrent	Intravenous glucose saline, epinephrin	Collapse, response to epinephrin
3	Gurd	Intravenous	2	Undiluted	Immediate	10-15 Min.	Respiratory	Artificial respiration.....	Strong slow pulse; absence of splanchnic reaction
4	Boughton	Intravenous	1/16	Undiluted	2 Min.	45 Min.	Respiratory (splanchnic)	Epinephrin.....	Asthmatic attack; response to epinephrin
5	McCallum	Subcutaneous	5	Undiluted	2 Min.	5 Min.	Splanchnic primary	None.....	Epigastric discomfort; rectal tenesmus
7	Patrick	Intravenous	5	1/50	3 Min.	36 Hrs.	Splanchnic recurrent	None.....	Loss of consciousness; rapid appearance of urticaria

TABLE 2.—Severe Immediate Reactions Followed by Recovery

Case	Author	Route of Administration	Amount Injected in C.c.	Dilution	Length of Time Supervening Before Onset of Symptoms	Duration of Symptoms	Type of Action	Treatment Employed	Most Striking Features
9	Gurd	Intradermic	0.25	Undiluted	15 Min.	4-6 Hrs.	Respiratory urticaria	None.....	Extreme edema of face and at site of injection
10	Gurd	Subcutaneous	5	Undiluted	2-4 Hrs.	12 Hrs.	Splanchnic urticaria	Calcium lactate.....	Vomiting; blood concentration
11	Munro	Intravenous	30	Diluted	1 Min.	5 Min.	Respiratory (splanchnic)	Posture, artificial respiration, epinephrin, atropin chloroform	Recovery of most desperate case; use of chloroform
6	Patrick	Intravenous	20	1/50	1½ Min.	Few minutes	Splanchnic urticaria 24 hrs.	None.....	Pain over heart

Necropsy was performed four hours after death. Owing to the presence of pleural adhesions, the lungs were squeezed considerably in the process of removal, nevertheless, they were voluminous and downy, except over the posterior parts which were boggy and dark in color. The lungs were reddish gray and were covered over the whole surface with innumerable subpleural collections of deep purple blood. These patches[3] varied in size from 1.5 to 5 mm.

Beneath the parietal pleura there was a smaller number of similar hemorrhagic spots.

The cut surface of the posterior parts exuded a considerable amount of bloody frothy fluid; the anterior portions showed a dilatation of the alveoli and numerous small purplish red spots.

The upper intestinal tract showed slight capillary dilatation.

So far as we are able to discover, the patient had not been previously wounded nor had he received at any other time injections of horse serum. That he was an individual presenting a natural hypersensitiveness to horse serum is therefore a fair assumption. The fact that the same person is not infrequently sensitive to more than one foreign protein in all probability offers an explanation of the patient's history of repeated attacks of vomiting and bloody diarrhea.

Inasmuch as the patient in Case 2 was not under observation by any one medical officer during the period intervening between the time of serum injection and his death, there is perhaps some slight doubt regarding the nature of the collapse that resulted. Correspondence was, however, carried on with those officers who had seen the patient prior to admission to the casualty clearing station, and the note made by the officer in charge of the patient at the main station of the field ambulance stated that "while in the field ambulance, he appeared to be suffering slightly from shock, but in other respects was in good condition when he left the main dressing station."

Case 2.—S. M. was admitted to the casualty clearing station six hours after being wounded and three hours after receiving serum injection at the field ambulance.

His injury consisted of a perforating wound of the upper third of the left thigh behind the bone. No large vessel was injured; there was no evidence of hemorrhage; the sciatic nerve was intact and there was no important laceration of muscle. Briefly, the wound was of such a nature as was considered trivial, infection excluded.

He was admitted at 8:30 a. m. On admission his condition was seen to be extremely grave; he was pale, slaty in color and mentally stuporous. The mucous membranes were not blanched. The pulse was barely perceptible at the radials; the rate was over 140 per minute. There was no respiratory difficulty, no urticaria and the extremities were cold.

The patient was placed under an incandescent heater with the foot of the bed raised; but no improvement occurred. On the contrary he appeared to

3. These hemorrhagic patches are typical of those found in anaphylaxis in the guinea-pig.

become worse. An operation was therefore performed at 2 p. m., as it was feared that despite negative findings he might be suffering from a deep seated gas gangrene.

Examination of the wound was made under gas and oxygen anesthesia. An intravenous saline solution containing 7.5 per cent. glucose, to which was added 8 mm. of epinephrin, was given. Fifteen hundred c.c. was thus injected. During the induction of anesthesia (nitrous oxid and oxygen) collapse of the patient became almost complete. Respiration ceased and the heart sounds became almost inaudible. The rate of flow of the intravenous solution was increased, and artificial respiration was employed. This resulted in return of signs of life. After 500 c.c. of the solution had been injected, there was marked improvement in the patient's condition, and at the time of the completion of the injection of the total quantity of 1,500 c.c. the patient's pulse rate was 86, of good pressure, and his color was good. Evidently he had lost no important amount of blood. He became mentally alert and remarked that he had felt "all in," but that he was now fit. The operation itself consisted simply in an incision of the affected part for purposes of examination. Carrel tubes were inserted. The whole procedure occupied but three or four minutes. Examination revealed no evidence whatever of gas gangrene.

He returned to the ward in good condition, "practically normal in appearance," and remained fit for approximately thirty minutes, when he rapidly collapsed, and died at 4:30 p. m. Unfortunately, owing to pressure of work in the operating room, it was not possible to see him during this second period of collapse.

Necropsy was performed thirty minutes after death. There were no positive findings other than enlargement of all the great and smaller veins in the splanchnic area. After removal of the heart, the right thorax filled immediately with fluid blood up to two thirds of its capacity. Examination of the leg confirmed the absence of gas gangrene.

There is no doubt in my opinion that this was a case of fatal anaphylaxis following the subcutaneous administration of a small dose (presumably about 5 c.c.) of antitetanus serum. This belief is based upon the absence of any other cause of shock or infection, and upon the very prompt response to the glucose injection with its epinephrin content. At necropsy, as mentioned above, the only abnormality was the extreme content of blood in the veins and capillaries of the splanchnic area and the absence of clotting one-half hour after death. One cannot help feeling it was unfortunate that circumstances were such that we were unable to repeat the epinephrin injection at the time of his second collapse.

For notes regarding the following case I am indebted to Dr. Edward W. Archibald of Montreal.

CASE 3.—The patient received a gunshot wound of both legs in October, 1915. Severe infection of all wounds occurred; drainage was instituted, but his condition remained unsatisfactory, and two weeks after admission to the hospital a blood culture proved that he had a streptococcus septicemia. There is some doubt as to whether he had received tetanus serum at the field ambu-

lance. Although no note of such was made on his card, it is probable that such an injection had been made.

Upon discovery of the blood infection, he was given a dose of antistreptococcic serum. This was injected undiluted intravenously. The material was injected very slowly. After he had received 2 c.c., symptoms of anaphylaxis supervened. He complained of feeling queer and tight across the chest. Respirations increased somewhat in rate and became more labored. The pulse remained strong and comparatively slow until he died. Death occurred between ten and fifteen minutes after the onset of symptoms.

Dr. Archibald's notes state that the chief trouble seemed to be with his respiration. His face took on an anxious expression, and he became pale. He was quite conscious for several minutes and then became unconscious. Involuntary micturition and defecation occurred. Artificial respiration was employed but without avail.

At necropsy the lungs were found to be voluminous with subpleural ecchymoses.

Boughton [4] reports a case (Case 4) of anaphylactic death occurring in an asthmatic following an intravenous injection of 1 minim of normal horse serum undiluted.

CASE 4.—"Within two minutes a typical attack of asthma supervened. He was given 10 minims of epinephrin intravenously with definite relief for about ten minutes." Four other similar doses were given, each gave relief for several minutes, but the patient died forty-five minutes after the injection of serum.

Necropsy was performed within half an hour after death. The face was cyanotic and the lips swollen. "The abdominal cavity showed intense injection of the vessels everywhere, being especially marked in the veins of the stomach, mesentery, gallbladder and appendix. The entire small intestine was bright red and the dilated submucous vessels showed distinctly through the intestinal wall. The parietal peritoneum was markedly injected; no exudate was visible in the peritoneal cavity.

"Both lungs were enormously distended and emphysematous. The left lung showed small areas of hemorrhage at the lateral portion of the lower lobe, about 4 cm. in diameter, with a gelatinous organizing exudate at this point. On section the lungs were found to be dry. Microscopically the lungs showed passive hyperemia but no edema; there were a few small interstitial hemorrhages." Microscopic examination of the kidneys revealed the most marked changes: "The epithelium of the convoluted tubules was distinctly edematous and there was considerable degeneration and some necrosis; there was intense passive hyperemia. Interstitial hemorrhages were numerous but not extensive."

McCallum [5] reports a case (Case 5) of fatal anaphylaxis following the prophylactic injection of diphtheria antitoxin subcutaneously.

---

4. Boughton, T. H.: Anaphylactic Death in Asthmatics. J. A. M. A. **73**:1912 (Dec. 27) 1919.

5. McCallum, D.: Fatal Anaphylaxis Following Prophylactic Injection of Diphtheria Antitoxin Subcutaneously, Brit. M. J. **2**:596 (Nov. 8) 1919.

CASE 5.—The patient was a boy, aged 8, apparently healthy. Following the injection of 2,000 units (amount of serum not stated), death occurred in five minutes. Two minutes after the injection was made, the boy made the complaint that "it had gone to his stomach." He ran out of the house to the privy in the backyard. One minute later, he was heard calling, "Daddy, Daddy." His father immediately ran to his assistance and found him completely collapsed and apparently choking. His whole body was deeply cyanosed; he was pulseless. Artificial respiration was employed without avail.

Necropsy was performed. No note regarding the condition of the lungs nor splanchnic region is published.

Patrick[6] reports three cases of anaphylaxis occurring in patients who received intravenous injections of horse serum in the treatment of bacillary dysentery.

CASE 6.—His first patient was not known to have received serum injections previously. During seven days, he received 85 c.c. in five divided doses of about 20 c.c. each.

"About one and one-half minutes after the last injection, the patient experienced sudden pain over the heart, became pale and felt faint. He felt all right again within a few minutes. A serum rash covered the body by the following day. His convalescence was rapid."

CASE 7 (Patrick's Case 2).—Antidysenteric serum was administered subcutaneously twenty-six days before the intravenous dose, which was accompanied by anaphylactic shock.

Twenty-five c.c. of serum were diluted in saline up to 1,000 c.c. Three minutes after the commencement of the injection of serum, the patient complained of pain across the chest. He became restless, stretched out his arms. His eyes became wide and staring. He probably lost consciousness for a few seconds; the heart sounds remained steady and there was no sign of cardiac dilatation. Injection was stopped.

Five minutes later his condition appeared normal and the injection of saline containing serum was resumed. Seven minutes after the resumption of the injection an urticarial rash began to appear on the arm, apparently along the line of the vein into which the fluid was being injected. Within a few minutes urticarial patches had appeared on the forearm, hands, and upper part of the trunk. They were not observed elsewhere. The total quantity of serum and saline was injected in twenty minutes. Five minutes after the completion of the injection, all traces of urticaria had disappeared.

The injection was completed at midnight. During the night, the patient vomited a great deal, and died the following day, though immediately following the injection his condition appeared improved.

At necropsy, in addition to the dysenteric findings, the stomach was found to be much distended, and there was great dilatation of the duodenum which had a diameter equal to that of a normal stomach.

CASE 8.—The third patient (Case 6) had received antitetanus serum, after being wounded sometime before. In the treatment for dysentery, 50 c.c. of antidysenteric serum were diluted in 1,000 c.c. of saline, and intravenous injection was commenced. When not more than 50 c.c. of the mixed fluid had been run

6. Patrick, C. A.: Anaphylactic Shock After Injection of Serum Intravenously, Brit. M. J. **2**:114 (July 28) 1917.

into the vein, he suddenly became very ill, his eyes became staring, and his arms stretched out. His face was pale and he had become unconscious. Breathing stopped for about thirty seconds. Within a few minutes he looked quieter, but remained unconscious for about two hours with a rapid pulse. In the evening (injection had taken place at 2 p. m.) he improved and was able to answer questions. No rash was seen. He had a restless night but was slightly better in the morning. He died the following morning.

Necropsy notes refer simply to the dysenteric condition.

Patrick refers to the severe pain in the chest as being one of the most striking phenomena, but draws attention to the fact that overfilling of the heart could not have been held responsible, as the injection was being carried on very slowly and was small in amount.

Case 9.—Lieut. H. was admitted to the casualty clearing station on account of asthma, which the patient himself believed to follow proximity to horses. An effort was made to confirm his sensitiveness to horse protein, and to determine the degree of sensitiveness to horse serum. At 11:30 a. m., Nov. 12, 1915, 0.25 c.c. of horse serum was injected intradermically into the skin on the outer border of the left upper arm. Fifteen minutes later there was an onset of coryza and an asthmatic attack occurred which increased for about twenty minutes. At its maximum, it was slightly to moderately severe. A marked swelling of the face and ears, more particularly of the eyelids, occurred to such a degree that he was unable to see. The lobes of both ears filled with fluid and hung well down on his neck. At the site of injection there was an edematous enlargement, about the size and shape of a hen's egg, which hung down, having the appearance of a supernumerary breast. This reaction persisted, though gradually subsiding, for from four to six hours.

The effect of this reaction to the injection was more marked than was anticipated and suggests that the dose used (0.25 c.c.) was unnecessarily large for the purpose of confirmation or diagnosis.

The following day, November 13, at 11 a. m., he was injected with 0.15 c.c. of horse serum subcutaneously; no reaction occurred. At 12:30 the same day he received 0.25 c.c. intramuscularly; no reaction either local or general took place. At 2 p. m. of the same day, he received 0.5 c.c. subcutaneously, again without reaction.

The patient was unwilling to remain in the hospital longer, and seemed satisfied to have the cause of the asthma definitely established, hence it was impossible to attempt immunization. The experiment does prove a very great hypersensitiveness to horse protein in a patient who thought himself to be subject to asthma when in the presence of horses, and also the possibility of desensitizing by means of a dose of 0.25 c.c. of horse serum.

The patient was discharged from the hospital with a note given to him to the effect that prophylactic or therapeutic injections of horse serum should not be employed unless such was preceded by a desensitizing dose.

For the following notes I am indebted to Major John Fraser, M. C.

Case 10.—The patient was wounded June 29, 1917. His injury consisted of a small perforating wound of the right upper arm. Five hundred units of antitetanus serum were administered at the field ambulance. Upon admission

to the casualty clearing station, three or four hours later, the patient was pulseless, his body was covered by a hyperemic rash, there was a generalized edema of the whole body and he was vomiting frequently. Blood count demonstrated: hemoglobin, 110 per cent.; erythrocytes, 8,240,000, and leukocytes, 25,000.

Calcium lactate was given in doses of 15 grains, three times a day. Improvement in the patient's general condition followed after the third dose.

The following day the patient's condition was satisfactory. Blood count showed: hemoglobin, 82 per cent.; erythrocytes, 6,100,000, and leukocytes, 13,000.

An important case of severe anaphylaxis following the administration of horse serum with recovery, is reported by Munro.[7] This case is of interest on account of the description of symptoms, and also on account of the satisfactory result which followed the treatment as instituted by Munro.

CASE 11.—The patient, who had received prophylactic antitetanus serum subcutaneously when wounded, came under Munro's care suffering from erysipelas of the leg. In the treatment of the latter, he was given 30 c.c. of antistreptococcic serum intravenously. The serum was diluted. The extent of dilution is not stated in the article. No effort was made to desensitize the patient. Within one minute after the injection, the patient complained of choking, he grasped his larynx, breathed jerkily and spasmodically. Extreme cyanosis developed and the pulse became flickering. Breathing ceased in full inspiration. Treatment was instituted at once; the head of the bed was lowered and artificial respiration was commenced. Epinephrin, 30 minims, and atropin, 1/100 grain, were given subcutaneously, and chloroform was placed on a mask through which all air which entered the lungs during artificial respiration had to pass.

Within five minutes, the patient's condition improved; normal breathing commenced; the pulse returned at the wrist, and was counted at 150 per minute. The patient later made an excellent recovery.

In this case, the reaction was almost exclusively respiratory in nature, and in this respect should be compared with Case 5 in which the manifestations of splanchnic dilatation predominated.

II. IMMEDIATE FOCAL REACTIONS

If the hypersensitive individual receives an injection of serum into tissues in which the injected protein is exposed to the action of only a small portion of the body fluid or blood stream, the protein is but slowly acted upon by the anaphylactic bodies. In consequence, instead of a fulminant systemic reaction taking place, there may occur simply a focal reaction to the presence in the tissues of an irritant foreign substance. In other words, inflammation develops at the site of injection.

The following case is an example of the cellulitis type of local allergic reaction which occurs in cases of serum hypersensitiveness.

7. Munro, W. T.: A Case of Anaphylaxis. Brit. M. J. 2:668 (Nov. 22) 1919.

TABLE 3.—SUMMARY OF CASES ILLUSTRATING IMMEDIATE AND DELAYED FOCAL AND GENERAL REACTIONS TO SERUM PROTEIN

Case	Route of Administration	Amount Inoculated, C.c.	Time Since Last Injection	Time Between Injection and Reaction	Type of Reaction	Duration of Reaction	Most Striking Feature
12	Subcutaneous	4	21 days	4 hours	Local cellulitis (severe); pyrexia 103 F.	4 days	Typical cellulitis of thigh
13	Subcutaneous	3.5	25 days	2 hours	Local cellulitis (severe); headache; joint pains; pyrexia 102 F.	3 days	Typical cellulitis of arm
14	Subcutaneous	4	10 months	Immediate	Local cellulitis; generalized itchy urticaria	7 hours	Apparent response of urticaria to calcium chlorid
15	Intradermic	1	2 months	30 minutes	Local cellulitis	Short duration	Desensitization as evidenced by injection of 5 c.c. 3 hours after primary injection without reaction
16	Subcutaneous	10	.....	2 days	Local cellulitis; pyrexia 105 F.; headache	24 hours	High fever, 105 F.
17a	Intradermic	1	6 weeks	Immediate	Mild hyperemia	Short duration	Dose sufficed to desensitize
17b	Intramuscular, thigh	75	2 hours	3 days, 5 days	Marked edema, locally; moderate urticaria	5 days	Extensive edema in injected tissues
17c	Intradermic, forearm	0.25	20 days	Immediate	Local cellulitis; lymphangitis; lymphadenitis	12-24 hours	Focal reaction at site of injection of serum twenty days previously
18	Intradermic	0.5	15 days, 500 C.c.	4 hours	Focal reaction; thigh	3-24 hours	
				.....	No reaction	.....	Absence of reaction due to immunity or tolerance
19a	Subcutaneous	10	18 months (6 doses)	4 days	Pyrexia 104 F.; local urticaria and moderate cellulitis	2 days	Malaise
19b	Intradermic	0.25	24 days	2½ minutes	Local cellulitis; lymphangitis	80 minutes	Prompt local reaction of short duration
19c	Subcutaneous	2	2 hours	1 hour or less	Purulent reaction	1 week	Pus cell accumulation
					Deep cellulitis; pyrexia 100.4 F.	2 days	0.25 c.c. of serum failed to desensitize; reaction at site of injection 24 days previously
20	Subcutaneous	5	7 days	24 hours	Pyrexia 100.4 F.; malaise; cellulitis	9 days	Large abscess formation
				4 days	Local abscess formation		
21 Treadgold	Subcutaneous	10	No previous injection	6 days	Local urticaria; joint pains; malaise; pyrexia 100 F.	7 days from commencement of reaction to return to normal	Gradual increase in severity of symptoms of intoxication; edema of glottis
				7 days	Lymphadenitis (local)		
				8 days	Generalized giant urticaria; generalized lymphadenitis; pyrexia 103.4 F.		
				9 days	Weak rapid heart action; buccal urticaria; edema of glottis		
22 (Type)	Subcutaneous	10	.....	8 days	Local urticaria with tenderness; pyrexia 100-101 F.; generalized urticaria; anorexia and malaise	2-4 days	No symptoms causing anxiety or very annoying to patient; type of reaction usually occurring in previously uninjured individuals

In this case the reaction was well established at the end of four hours and persisted for four days, accompanied by fever.

CASE 12.—Pte. A. M. D., while working on the barbed wire in "No Man's Land," three weeks prior to admission, suffered a small tear below the right knee. At that time he received a routine dose of antitetanus serum. He was admitted to the casualty clearing station on account of a slight infection of the tissues about the abrasion. The temperature was 100 F. and the pulse 88.

On admission, a small incision was made into the infected area, and 750 units of antitetanus serum, contained in 4 c.c. of serum, were administered into the right thigh at 5 p. m. Four hours later, at 9 p. m., the patient complained of pain in the thigh. His temperature was 103 F., his pulse 116. The following morning the temperature was 103 and the pulse 116. The anterior surface of the thigh about the point of serum injection was swollen, hot, red, painful, tender and edematous. Immediately about the point of the needle puncture, there was some itchiness. The wound below the knee was dressed and found to be free from pus. During the next twenty-four hours, the cellulitis of the thigh became more marked. It then commenced to subside, without further treatment. On the fifth day after the injection, the thigh showed but slight induration, and the temperature was normal.

In view of the fact that the cellulitis subsided, although no treatment whatever was instituted, and in view of the prompt onset of the reaction at the site of serum injection, it would appear that the inflammation was a local allergic reaction consequent upon the injection of horse serum into the tissues of an individual who had been sensitized by a dose given three weeks previously.

A similar instance is Case 13.

CASE 13.—Pte. A. G. H. suffered a bullet wound of the hand Feb. 19, 1918, on which date he received 750 units of antitetanus serum. The following day he had a generalized urticaria. Between three and four weeks later, on March 23, he was given a dose of 500 units subcutaneously in the left arm. Two hours later, the arm became swollen, red, and very painful, and he complained of headache and joint pains all over the body. His temperature, which had previously been normal, rose to 102 F. The following day there developed a severe cellulitis of the left upper arm. This was judged to be a serum reaction; no treatment was employed. During the next three days, the hyperemia and swelling subsided entirely.

In Case 14, in addition to an immediate focal reaction at the site of reinjection (ten months after sensitizing doses), a generalized urticaria developed within six hours. The latter subsided promptly following the administration of calcium chlorid.

CASE 14.—Sgt. E. W. was wounded Oct. 1, 1916. Serum was given on the same day, and was repeated on the fifth day. It is presumed that on each of these occasions he received approximately 5 c.c.

He was again wounded Aug. 15, 1917. At 3 a. m. of the same day, he received 750 units of antitetanus serum. He states that an immediate painful

and tender local reaction occurred. When first seen at the casualty clearing station at 9 a. m., he was suffering from a generalized marked itchy urticaria. He received at once 1 dram of calcium chlorid in four divided doses, at fifteen minute intervals. The urticaria subsided promptly.

The following represents a typical case of immediate focal reaction to the intradermic injection of 1 c.c. of serum, two months after a previous dose. This case is also of interest since it demonstrates that 1 c.c. of serum desensitized the patient completely.

CASE 15.—Pte. G. M. was wounded Sept. 6, 1916, at which time he received a routine dose of antitetanus serum. He returned to duty and was again wounded Nov. 6, 1916. His wound consisted of an entrance and exit wound of the left thigh. In view of the fact that he had recently received an injection of horse serum, no antitetanus serum was administered at the field ambulance.

On November 7, at 11 a. m., an injection of 1 c.c. of serum was administered intradermically into the upper right arm. Thirty minutes later, there was a hyperemic swelling with a clean-cut edge measuring 6.5 cm. in diameter. The surrounding area was slightly itchy.

At 2 p. m. of the same day (Nov. 7), he received 5 c.c. of serum, representing 750 units, subcutaneously in the pectoral region. No reaction other than slight soreness at the site of injection supervened.

In Case 16, the reaction occurred on the second day following the serum injection. Focal cellulitis accompanied by a febrile reaction took place. The temperature rose to 105 F.

CASE 16.—Pte. H. K. P. sustained an unimportant wound of the left buttock, March 31, 1917. On the same day, he was given 1,500 units of antitetanus serum. April 2, the left side of the chest, at the site of serum injection, became swollen and reddened, slightly tender, but not itchy. His temperature rose to 105, the pulse to 116, and remained high for twenty-four hours. Except for headache, which accompanied the fever, and the swelling of the side of the chest, there were no other symptoms.

Case 17 is of interest since it appears to prove that serum, injected into the muscles of the body, remains in situ, more or less unaltered, for at least three weeks.

CASE 17.—P. J. was wounded Nov. 5, 1916, on which date he received a routine dose of 750 (U.S.A.) units of antitetanus serum at the field ambulance. His wound consisted of comminuted fractures involving the left knee joint. December 22, an attack of tetanus developed. He had received no subsequent doses of antitetanus serum during the interval.

Before commencing the treatment of the tetanus, the patient was given intradermically a desensitizing dose of 1 c.c. of serum. Slight hyperemia immediately developed about the injection area, otherwise no reaction occurred (Table 3, Case 17*a*). During the next three days he received 13,500 units of serum into the muscles on the anterior part of the thigh, in order, if possible, to bathe the filaments of the anterior crural nerve, which was thought to be the nerve involved in transmitting the toxin upward. This antitetanus content

required about 75 c.c. of serum. The course of the tetanus infection was benign, all symptoms having disappeared by Jan. 2, 1917.

During the night following the third day's injection into the thigh, the left thigh and foot commenced to swell; this swelling increased in size for forty-eight hours, until the thigh became almost twice the size of its fellow (Table 3, Case 17*b*). The leg and thigh were very edematous, slightly painful, and moderately tender. The swelling pitted upon pressure, impressions from 2 to 3 cm. in depth being easily produced.

On the fifth day, following the beginning of the injections, the whole body was covered by a mild to moderate grade of itchy urticaria. No joint or other pains, besides those in the left leg and thigh, occurred. The swelling of the leg, though gradually subsiding, persisted for several days, and returned to normal five or six days after its commencement.

This local delayed allergic reaction is of great interest, not only since it demonstrates in a very striking manner the development of a typical allergic reaction several days (five) after the introduction of the protein, but also since it indicates that although, as other experiments prove, the antitoxin content of the serum is easily available for use in the tissues following intramuscular injection, part at least of the protein serum remains in situ for at least five days.

Twenty days after the last dose of serum the patient was subjected to a test reaction to horse serum—allergic. A dose of 0.25 c.c. of horse serum was injected intradermically over the flexor surface of the left forearm at 10 a. m. The arm was under constant observation for the first ninety minutes following injection. There instantly (from 30 to 60 seconds) developed a small raised white swelling along the needle track and at the point of injection of serum, 1.5 cm. away (Table 3, Case 17 *c*). In four minutes, a well marked hyperemic zone, 4 cm. in diameter, roughly oval in shape, had developed with some swelling. In seven minutes, the swelling was well marked, red and commencing to pit upon pressure. In nine minutes, the swelling was 8 by 4 cm. in diameter, red, tender and painful (typical erysipeloid reaction).

In fifteen minutes, the area had enlarged still more and pitted readily on pressure. A mild grade of lymphangitis developed up the arm; the epitrochlear gland became enlarged and tender.

The swelling enlarged gradually during the succeeding hours, though the color faded somewhat. At 5 p. m. the whole of the flexor surface and part of the radial aspect of the extensor surface was involved.

The patient suffered no constitutional disturbances, no pyrexia, no itching, either general or at the point of injection. The reaction was of a true cellulitis type.

About 2 p. m. of the same day the left thigh commenced to swell and became somewhat tender. Swelling increased for about one hour then gradually subsided.

Thus we have a focal reaction occurring at the site of the injection of serum given three weeks prior to the test dose. It would appear obvious that a definite amount of more or less unaltered serum was present in the muscles of the thigh, and that the balance of tolerance and hypersensitiveness was upset by the test dose, with the result that a reaction occurred in those tissues in which serum from the previous injection still remained.

An experiment similar to that which was carried out in Case 17 was attempted in another case of local tetanus, Case 18.

CASE 18.—Pte. G. B. was wounded Aug. 7, 1917, on which date he received 1,500 units of antitetanus serum.

During the night of August 21 he was disturbed by jumping and slight pain in the left thigh. (He was suffering from a severe compound fracture of the left tibia and fibula.) On August 23, the condition was diagnosed as tetanus. During the ensuing week, he received 90,000 units of antitetanus serum, contained in about 500 c.c. of serum. For the most part, the serum was given locally in an effort to bathe the sciatic and anterior crural nerves. Twenty thousand units were also given intravenously.

After an early tendency of the disease to spread and become more severe, it was well controlled by August 30.

He received no serum after August 29 until September 13, when he was given 0.5 c.c. into the skin on the flexor surface of the left forearm. Absolutely no reaction either constitutional or focal occurred at the site of the previous injections. As the patient's condition at this time was favorable, the tetanus being cured, the pyogenic infection of the wound being well under control, and bony union commencing, he was evacuated to the base.

There are two explanations why, in this case, no reaction, either focal or otherwise, followed the test dose. In my opinion, the absence of reaction was not due to desensitization persisting, but was due to tolerance (immunity) having been established to a degree which was not overcome by the administration of 0.5 c.c. of serum.

The following case is made use of for three separate experiments. In the first place, as the result of the injection of 10 c.c. of serum eighteen months after the last dose in a patient who had previously received repeated doses of horse serum, there occurred a shortening of time and a more severe reaction than usually occurs in previously uninjected individuals. One month later he was found to be extremely sensitive and reacted immediately to a dose of 0.25 c.c. of horse serum given subepidermically. This small dose did not suffice to desensitize the patient, since a focal reaction occurred when he was injected one hour later with a dose of 2 c.c. of serum.

CASE 19.—J. E. H., aged 23, on Jan. 23, 1920, suffered amputation (railroad accident) of both legs. He was brought to the Montreal General Hospital, and immediately operated upon. At the completion of the operation, he was given 1,500 units of antitetanus serum contained in 10 c.c. of serum.

The patient had served throughout the war in France and had been wounded three times. Following these wounds he received five or six prophylactic doses of antitetanus serum. The last dose was administered in August, 1918.

Four days after the injection of serum (Jan. 27, 1920), his temperature suddenly rose to 104 F. (Table 3, Case 19*a*). (Prior to and following this day his temperature had remained about 100 F. at its maximum.) An area of cellulitis appeared on this day over the left deltoid muscle, at which site serum had been injected. This region was slightly itchy and became red, swollen and tender. No joint pains and no evidence of generalized urticaria or erythema was noted.

At 11 a. m., Feb. 21, 1920, he received subepidermically over the flexor surface of the left forearm, an injection of 0.25 c.c. of horse serum (antitetanus serum). Within two and one-half minutes, there was a well established zone of edema, appearing in radiating lines from the point of injection (Table 3, Case 19*b*). Within five minutes a hyperemic zone 5 cm. in width, and 7 cm. in length, had appeared about the injection point. During the ensuing half hour, this increased in size somewhat and became a deep inflammatory red. The whole area was somewhat swollen and tender and was definitely warm on palpation, as compared to the surrounding tissue. Spreading upward from the zone of inflammation, there appeared two parallel lines similar in appearance to those seen in lymphangitis. These reached to the junction of the middle and lower thirds of the upper arm.

The reaction reached its maximum about twenty-five minutes after the injection, and commenced to subside rapidly about eighty minutes after injection. At 1 p. m., 2 c.c. of serum were injected subcutaneously in the upper arm; this area was observed one hour later, at which time a moderate swelling of the part could be palpated (Table 3, Case 19*c*). Obviously, the previous injection of 0.25 c.c. of serum had not sufficed completely to desensitize the patient.

The following day, the patient's temperature, which had been normal during the last week, rose to 100.4 F. This elevation of temperature persisted during the day and the following day. Over the site of the second injection into the upper arm was a slight swelling on both February 22 and 23.

The site of the subepidermal reaction in the forearm, on February 23, consisted of a small elevated area, 1 cm. in diameter, deep red in color, and showing over the center a collection of pus cells (small yellowish gray focus).

The inflammatory nodule on the forearm persisted, though gradually subsiding, for one week. No discharge of pus occurred.

A very interesting feature was the fact that, over the deltoid at the site of the injection, one month previously, there appeared a slight amount of swelling which, however, was not accompanied by itchiness or discoloration of the skin.

Apparently this patient when he received the first dose of the present series was not immune, but had lost to a considerable extent his hypersensitive state. In consequence, however, of his tissues having been previously stimulated by injections of horse serum, anaphylactic bodies developed more quickly than in the normal individual. A reaction occurred, therefore, after a short period. One month after this dose of 10 c.c. of serum, our experiments proved that he was extremely

hypersensitive and also that 0.25 c.c. of serum did not suffice to desensitize.

Abscess Formation.—In several cases, I have observed small collections of pus cells following intradermic injections. The following case is one in which a massive collection of pus developed at the site of serum injection such as occurs more commonly in the rabbit.

CASE 20.—The patient, L., following frost-bite, received a dose of antitetanus serum. Seven days later a second dose (5 c.c.) was administered. The second dose was injected deeply into the right rhomboid area; within twenty-four hours pain developed in this area, and the temperature rose to 100.4 F. During the next few days he suffered from anorexia, but no joint pains and no diarrhea.

On the sixth day following the injection, a well marked fluctuating swelling had developed; this remained about the same size until the eleventh day, when it was incised and about 40 c.c. of thick purulent material was evacuated. The operation wound healed at once; there was no reaccumulation of fluid.

From the pus evacuated a few streptococcic colonies were cultivated. These I believe were a contamination from the skin.

Edema of Glottis.—I have not observed any patient showing definite signs of edema of the glottis. The phenomenon is well illustrated by a case reported by Treadgold [8] which is reported herewith:

CASE 21.—Pte. P. was admitted suffering from a slight shrapnel wound of the shoulder. This was practically healed on admission, and there was no pyrexia. Symptoms started on the sixth day after the injection of 10 c.c. into the left upper arm. These consisted of a local urticarial rash, which was accompanied by pains in both knees; faintness and giddiness were complained of on getting out of bed, while the temperature rose to 100 F. On the seventh day, the glands in the left axilla were swollen and painful; toward evening the patient vomited twice. Other symptoms remained as before. On the morning of the eighth day, local edema was marked, while the rash had become generalized. There was giant urticaria all over the body, and the itching was intense. Pain was complained of in nearly all the joints, while most of the superficial lymphatic glands were painful and enlarged. At night, the temperature rose to 103.4 F., but the pulse was so feeble and rapid that it could not be counted. There were urticarial spots on the oral mucosa, and the patient was so hoarse that he could hardly speak. Toward evening, the pulse fell to 90 per minute and was stronger. On the tenth day, the hoarseness had disappeared, the temperature was normal and the pulse was much improved, while the rash had practically disappeared. In all, the rash lasted five days, the joint pains six days, and the lymph adenitis seven days.

III. FOCAL AND GENERAL DELAYED REACTIONS

Persons who have not previously received doses of horse serum usually react sometime between the fourth and twelfth days, more especially between the sixth and eighth days, in a fairly typical manner.

---

8. Treadgold: Serum Disease and Anaphylaxis, J. Roy. Army Med. Corps, **27**:596, 1916.

Some form of rash is the most obvious and regular symptom. The rash is usually urticarial in nature; occasionally it is more erythematous in character, not infrequently simulating the eruption of scarlet fever. In probably all cases there is a febrile reaction during the period of the eruption; it may be high, 103 F. or more; it is more usually between 100 and 101 F. Joint and muscle pains occur, the site of injection is usually sensitive to pressure and the lymph nodes in the vicinity are often swollen and tender.

It is probable that all normal persons react in this way to an injection of 5 c.c. or more. Not infequently the manifestations of the reaction are slight. Serum reactions are diagnosed as such in approximately 80 per cent. of cases.

RÉSUMÉ OF REACTIONS

Following the injection of horse serum into the human tissues various results may be noted, depending on the state of the tissues in relationship to the serum protein.

1. If the individual is normal, no immediate result will be noted. His tissues will be stimulated to elaborate a substance which has the property of altering (splitting[9]) the protein molecule.

The protein splitting substance is gradually developed by the tissues, so that at the end of about six days there is a sufficient quantity available to act on a relatively large quantity of the serum protein. The effect of this cleavage of the protein molecule by the antibody developed by the tissue is that there is liberated a toxic or irritant product.

During that period immediately following the introduction of the horse serum, the amount of available antibody is not sufficient to liberate, at any one time, a sufficient amount of toxic substance to injure the tissues either locally or constitutionally. After the sixth day, the amount of antibody available has reached such concentration that a larger quantity of protein is split. In consequence, the focus in which the

9. Although in the author's opinion there is sufficient evidence for believing that the manifestations of tissue intoxication or irritation which constitute the phenomena known as anaphylaxis and allergy are due to the formation of a toxic product as the result of splitting or cleavage of the antigenic protein by the serum antibody, it is not his purpose in this article to discuss the nature of the alteration which manifestly takes place. Throughout this discussion of the reaction, as noted in the cases cited, the terms "split-product," "splitting," "cleavage" will be used, even though it is recognized that no proof that the alteration of the protein molecule is, in fact, a cleavage is presented. The author, moreover, desires to point out that the adoption of the hypothesis of the presence of two substances—anaphylactic body and tolerant body—in the tissues of the immune animal or individual is not dependent upon the nature of the reaction—cleavage or otherwise—between the tissue body and the injected antigenic protein.

serum has been injected becomes irritated. As a result of irritation hyperemia develops so that a larger amount of blood is brought in contact with the serum collection. As a result, then, of a greater concentration of protein splitting substance in the body fluids, and an increased circulation through the focus of body fluid containing the serum protein, there is a marked increase in the amount of irritant substances developed. Symptoms of constitutional intoxication then occur. These manifestations consist of fever, skin eruptions, swelling of the synovial membranes with consequent joint pains, and occasionally nausea or vomiting and diarrhea.

At the site of serum injection and in the neighboring (or distant) lymph nodes, evidences of inflammation such as hyperemia, interstitial edema, pain and tenderness, are noted.

2. If the individual is hypersensitive to horse serum, either because he has previously received parenteral injections of horse serum, or from any other cause, the injection of horse serum into his tissues is immediately followed by a reaction between the protein splitting substance already present and the injected protein.

The severity of the reaction which takes place will depend upon several factors:

(*a*) The degree of sensitiveness of the patient.

(*b*) The route of injection (intradermic, subcutaneous, intramuscular, intrathecal or intravenous). This is important, since depending on the nature of the tissue into which the serum is injected, there will be a variation in the available proportion of the total amount of protein splitting substance (anaphylactic antibody) present in the body.

(*c*) The amount of serum injected.

(*d*) The rate of injection. If the serum is very slowly injected into the blood stream, the total amount of protein splitting body available may be exhausted by a very small amount of serum. The amount of serum which is capable of absorbing all the available antibody may not be able to supply a sufficient quantity of toxic splitting protein materially to injure the individual.

(*a*) If the individual is very sensitive, if the route of injection is intravenous, and the dose injected sufficient to produce an active amount of toxic split protein, there occurs almost instantaneous liberation of the toxic product, with immediate manifestations of grave intoxication of the individual. Death may supervene within a comparatively few minutes, either as the result of drop in blood pressure and arrest of circulation, as is seen in anaphylactic shock in the dog, or the reaction which occurs is respiratory, as in the guinea-pig. In the human being,

it would appear that this respiratory type of reaction, though very terrifying, is less likely to lead to a fatal outcome than is the splanchnic reaction.

In a certain proportion of patients that are shocked by the parenteral introduction of serum, there occurs, as has been previously mentioned, a recurrent splanchnic reaction, after the lapse of several hours, which may prove fatal.

The explanation of this delayed reaction is by no means a simple one. It is my opinion that death in such a delayed reaction is due to the formation, more especially in the duodenal mucosa, of a toxic substance similar to that found by Whipple and his associates [10] in cases of duodenal obstruction and demonstrated by myself [11] to be formed when the portal venous circulation is obstructed. It is probable that, in consequence of the splanchnic congestion with its resulting venous stasis in the duodenum, nutrition of the mucosa of the duodenum is interfered with, to a degree which suffices to permit the formation of a toxic substance.

(*b*) If the serum is injected intradermically in small quantities, for example 0.25 c.c., the reaction which occurs is almost entirely focal. It commences within two or three minutes, or less, and is characterized by a well marked cellulitis of the tissues surrounding the injectetd area, accompanied not infrequently with lymphangitis, and lymphadenitis.

(*c*) If the serum is injected intramuscularly, it is brought in contact with less blood than if given intravenously. In consequence, the reaction which occurs is, other things being equal, less severe and more prolonged than following intravenous administration, though more severe than following intradermic injections.

3. If the individual has been desensitized by a recent injection of horse serum (a few hours to four days previously) the injection of a subsequent dose will find the tissues free from any available anaphylactic (protein-splitting) body. In this event, the injected serum will not be immediately split, as is the case in the hypersensitive individual, but will remain unaltered pending the accumulation, through the activity of the tissues, of a fresh supply of protein-splitting body. Since the tissues have already been stimulated to produce the antibody, the development of amounts sufficient to cause the liberation of an amount of split protein capable of injuring the tissues requires a shorter period than in the normal individual. In consequence, the outbreak of clinical manifestations of irritation will not be delayed for eight or nine days, but will appear at the expiration of a shorter interval.

---

10. Whipple, Stone and Bernheim: J. Exper. M. **17**:286, 307, 1913.

11. Gurd, F. B.: The Toxins of Intestinal Obstruction, J. Infect. Dis. **15**: 124, 1914.

4. If the person has received frequent large doses of serum within a few weeks or months, he will be to a certain extent immune (tolerant) to the toxic effects of the splitting of the serum protein. Such a patient may be injected by any route with a small dose of serum, without the development, either immediately or later, of manifestations of intoxication. In such a case the injected serum protein is split, but there is also present in the tissues a substance which is capable of neutralizing the toxic split-protein.

It is not deemed advisable in this article to enter into a consideration of the nature of the substance responsible for this neutralization of the toxic protein. A theory,[12] which in my opinion is supported by a certain amount of evidence and which suffices to explain the various phenomena noted, is that there is developed, as a result of previous stimulation of the tissues by sublethal doses of the split protein, a second type of body capable of further degrading the protein molecule to the stage of the polypeptids or amino-acids.

It is readily proved by means of experiments of transferred anaphylaxis [13] that there is, at all times, available in the tissues of protein-immune animals an amount of anaphylactic body greatly in excess of the amount of immune body. If, therefore, the amount of serum injected is potent to produce a greater amount of toxic split protein than can be neutralized by the available tolerant body, immediate manifestations of intoxication, as in the sensitized individuals, will occur.

The fact that it is possible to inject hypersensitive individuals with a small dose of the protein to which they are hypersensitive, without the development of toxic symptoms, must be borne in mind. Should the injection of a test dose in an individual suspected of being hypersensitive, either as a result of his being asthmatic or in consequence of his having previously received injections of horse serum, prove negative, the evidence thereby gained should not be accepted as final. The person should again be injected with a second test dose, larger in quantity, before it is assumed that he is not hypersensitive.

In my opinion, the fact that the hypersensitive individual may also be tolerant to the toxic split protein and consequently his hypersensitiveness may not be evident if too small an amount of the test serum is introduced is an important argument against the exclusive employment of the cutaneous method of testing for hypersensitiveness as used by Walker and others. By the employment of the subepidermal method

12. Gurd, F. B.: Anaphylaxis and Allergy and Their Relationship to Immunity, Am. J. Trop. Dis. and Prevent. Med. **1**:776, 1914.

13. Gurd, F. B.: Studies Upon Anaphylaxis and Its Relationship to Immunity, Am. J. Trop. Dis. and Prevent. Med. **1**:776, 1914.

of injection, more clean cut reactions are induced, and the quantitative element which is lacking in the cutaneous method is obtained. The method, moreover, is of real value in commencing desensitization of the individual.

DETERMINATION OF HYPERSENSITIVENESS AND DESENSITIZATION

At the present time, there are not sufficient data available to permit one to state with positiveness the optimum dosage of horse serum which should be employed in the determination of hypersensitiveness or in the induction of desensitization. I have employed a method which has apparently proved satisfactory although in one case (Case 9) the amount used was excessive. For the test dose, 0.25 c.c. of serum is introduced subepidermically. In performing the test, I have been accustomed to employ a very fine needle which is introduced through the skin and made to penetrate the skin again at a distance of a centimeter or more from the original puncture. As soon as the point of the needle is visible through the epidermis, serum is injected. In this way, a small white wheal is formed, which is the center of the subsequent reaction. *It is of the utmost importance that the fluid should not enter a vein.* Such an accident can be guarded against by attempting to withdraw the plunger of the syringe before injecting the fluid.

In sensitive individuals, the reaction commences almost immediately (from twenty to one hundred and eighty seconds), and consists in its first stage of an enlargement of the original wheal, usually in a radiating manner. Not infrequently at this stage, the point becomes itchy. Surrounding the definitely raised area, there appears within from three to five minutes a hyperemic zone, 1 to 5 cm. in diameter, which rapidly increases in size until it attains its maximum size, about one-half hour after injection.

Case 18 proves that in certain hypersensitive individuals, for such this patient must be considered to have been, 0.25 and even 0.5 c.c. is too small a dose to prove hypersensitiveness in individuals who have recently received large doses of serum and who are in consequence tolerant.

Should there be no reason for suspecting the patient to be highly sensitive or perhaps tolerant, a negative reaction to this amount (0.25 c.c.) may be accepted as proof that the individual is not hypersensitive in an important degree. On the other hand, should the fact that the patient had recently received one or more doses of serum lead one to suspect that he might be both hypersensitive and tolerant, the injection should be repeated about one hour after the first, a larger quantity, 1 to 1.5 c.c. of serum being employed.

Should a well marked reaction occur following the test dose, within one or two hours, a larger dose, 1.5 to 2 c.c., should be injected before assuming that the patient is desensitized. *That it is possible to inject a hypersensitive individual with serum in the hope of desensitizing him with a dose which is too small to exhaust all the available anaphylactic bodies must be remembered.* This is shown by the effect of a second injection two hours after the first injection in Case 19.

Even though repeated intradermic and subcutaneous injections have been made and desensitization believed to have been obtained, the greatest care should be taken in performing intravenous injections in patients who have reacted to the test dose. The serum injected should be diluted one in twenty of saline solution and allowed to run into the vein very slowly (Besredka).

TREATMENT

In the treatment of the mild forms of the reaction, little is necessary. In my experience, the discomfort arising from the urticaria is usually relieved by the administration, either before or after its development, of calcium lactate or chlorid, followed by a dose of magnesia. I have been accustomed to give the patient a mixture containing 1 dram of calcium chlorid, one fourth of the mixture to be taken every fifteen minutes; and at the end of the hour a dose of 4 drams of milk of magnesia is given.

In the treatment of the severe cases of splanchnic dilatation, posture, including compression of the abdomen, should be employed. Fluids, probably best in the form of hypertonic glucose (10 per cent.) solutions or gum acacia, are administered intravenously. Epinephrin, in doses of 5 or 10 minims (1:1000) intravenously, should be employed, if available, for its splanchnic effect. In the event of a recurrence of symptoms, further injections of epinephrin must be employed.

Although probably less effective than suprarenal extract, pituitary extract is, I believe, of value. It is probable that although its effect is less prompt than epinephrin, the best results are obtained by employing the latter preparation intravenously and injecting the pituitary extract in doses of 1 c.c., subcutaneously.

In cases of respiratory reaction, epinephrin should also be employed and, in addition, oxygen should be administered. As suggested by Auer and Lewis, the effect of atropin upon the smooth musculature is of real value in relieving the dyspnea. This drug should be administered in doses of 1/100 grain. In view of the fact that animals are apparently more resistant to fatal shock when under the influence of anesthesia and in view of the excellent results obtained by Munro in his case, chloroform or ether may well be administered. Artificial respiration should always be employed.

SUMMARY

The clinical phenomena which are grouped under the heading of serum sickness are manifestations of intoxication or irritation of the body tissues as the result of an alteration in the character of the injected serum protein molecule. This alteration of the molecule is due to the activity of specific substances presented in the tissues and body fluids. The stimulation necessary for the elaboration of such specific substances is a previous exposure of the tissues to the same protein.[14]

The alteration which takes place in the injected protein molecule (perhaps a cleavage of the molecule) results in a product which is extremely irritating to the tissues, more particularly to the involuntary muscles.

The animal or individual whose tissues are hypersensitive to a specific protein is said to be anaphylactic. When the reaction which occurs as the result of the interaction of injected protein and anaphylactic substances takes place in fulminant fashion, the phenomenon has been known by laboratory workers as anaphylactic shock. When, in consequence of either incomplete hypersensitiveness, small dosage, or gradual exposure of the injected serum to the anaphylactic bodies, the reaction is more gradual in onset and less severe, the condition is sometimes referred to as subacute anaphylaxis. In the human being, it is this less severe and more gradual type of reaction which is more usually encountered. The term allergy (von Pirquet) is ordinarily reserved to designate the focal visible reaction which occurs at the site of the introduction of the protein antigen in sensitive individuals. The manifestations as ordinarily seen in the human being are:

1. An inflammatory reaction (mild to moderately severe cellulitis) at the site of injection. This may be accompanied by lymphangitis and lymphadenitis.

2. Pyrexia, with accompanying headache and anorexia, and accelerated pulse rate.

3. Skin eruptions, commonly of an urticarial or erythematous type.

4. Joint pains, presumably due to swelling of the synovial membranes.

5. Occasionally, though rarely, accompanying the general urticaria and edema of the skin, edema of the larynx may occur.

6. Albumin is probably present in the urine for a short period in nearly all cases, though on this point sufficient data are not available.

---

14. From time to time, cases are seen in which it is impossible to determine the time at which such exposure occurred.

7. Leukocytosis, which may be marked, is present during the stage of pyrexia. (When the reaction occurs immediately after injection leukopenia is noted.) It is not improbable that a similar leukopenia occurs early in the reaction period in cases which later show a leukocytosis.

In hypersensitive individuals, an immediate reaction takes place. The manifestations of this immediate reaction are:

1. The focal inflammatory reaction at the site of injection is more severe, and occasionally results in suppuration or even necrosis of tissue.

2. There is often a feeling of fulness or pain in the epigastrium.

3. Vomiting and diarrhea, the latter often bloody, take place.

4. There may be marked splanchnic dilatation as evidenced by collapse, drop in blood pressure, and tachycardia. Examination of the blood reveals concentration. Such an effect may result in a complete arrest of circulation and death of the patient.

5. There may be marked dyspnea, accompanied by cyanosis and a choking sensation. Death may supervene from arrest of respiration.

In exceptional cases following an immediate splanchnic reaction with subsequent, more or less complete apparent recovery, there may occur after the lapse of some hours a recurrence of the collapsed state which may end in death.

Hypersensitive individuals may be desensitized so that large amounts of serum may be injected without danger. The method of desensitization that I employ has been heretofore described.

Avoidance of reactions is of greater value than is treatment. In all suspicious cases, prior to the injection of serum for prophylactic or therapeutic purposes, the absence of hypersensitiveness should be proved by means of an intradermic test. If found to be sensitive, the individual must be desensitized.

Treatment, in the event of severe reactions, must be promptly undertaken and pushed to the utmost. The various procedures which have apparently proved their value are discussed in the body of this paper.

THE RELATION OF MULTIPLE VASCULAR TUMORS OF BONE TO MYELOMA

H. GIDEON WELLS, M.D.
Department of Pathology, University of Chicago
CHICAGO

From time to time articles have appeared discussing vascular tumors arising in the bones, which have presented peculiarities resulting in their designation variously as pulsating sarcoma, bone aneurysms, hemangiosarcoma and hemangio-endothelioma, a variety of terms which indicate either that several different pathologic conditions may present similar characters, or that a single condition presents different features at different times and places.

The present consensus seems to be that true bone aneurysms rarely, if ever, occur, and that most, if not all, of the growths under discussion represent merely malignant neoplasms with hemorrhagic softening. Oehler early noted that in such cases the tumor tissue might be difficult to find, persisting merely as a thin superficial layer. He assumed that the so-called bone aneurysms arise from hemorrhagic sarcomas of bone, the blood stream gradually washing out the sarcoma cells. Gaylord [1] accepted this view, reporting a case in which only a small area presented tissue that could be interpreted as sarcoma. He stated that small, thin-walled blood vessels ran through the structure, and the illustrations and descriptions recall the appearance of organizing clots. He recognized that repeated hemorrhages might destroy the sarcoma, and so possibly lead to a spontaneous cure. Nakayama [2] agreed that the hemorrhagic-cystic sarcoma arises from a solid tumor altered by hemorrhage into the tumor tissue. He said that the sarcoma is usually of a mixed form with no predominance of any cell type, but he believed that there are also bone aneurysms that do not originate from sarcoma.

Howard and Crile [3] reviewed eighteen cases reported as endotheliomas of bone and added five more. Several of these had been mistaken for bone aneurysms. It is to be noted that in at least thirteen of these cases, the tumors were multiple, the bones of the skull, vertebrae, sternum, ribs and femur being most often involved, wherein they resemble the multiple myelomas, as well as in a lack of visceral metastases. Although albumosuria was not reported in these cases, it was probably not particularly sought.

1. Gaylord: Ann. Surg. **37**:835, 1903.
2. Nakayama: Beitr. z. klin. Chir. **64**:524, 1909.
3. Howard and Crile: Ann. Surg. **42**:358, 1905.

Ewing [4] accepts the occurrence of true endotheliomas of bone, stating that the structure presents thin strands of connective tissue supporting one or more layers of large clear cells enclosing spaces sometimes containing blood. He mentions, however, that "in one case, besides the clear cells, there were some areas resembling plasma cells." In discussing Marckwald's case of "geniune endothelioma" with multiple tumors in the flat bones, he says; "The general condition represented multiple myeloma, but the structure of the growth was entirely different;" and also, "Marckwald analyzed several cases from the

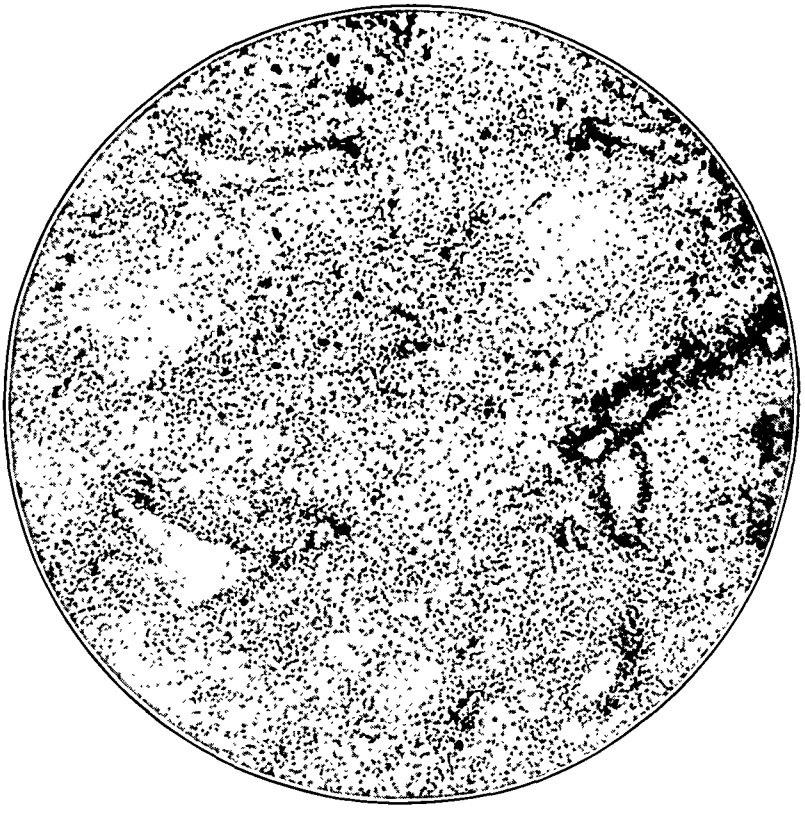

Fig. 1.—Vascular channels with some tumor cells persisting in proximity thereto; ×85.

literature. Some of these, however, were clearly multiple myelomas." He concludes that "while uncertainty still surrounds the origin of these tumors of the bone marrow, it is not clear that they can be separated from multiple myeloma."

Symmers and Vance [5] have reported an interesting case of this category under the explanatory title "Multiple Primary Intravascular

4. Ewing: Neoplastic Diseases, 1913, p. 313.
5. Symmers and Vance: Am. J. M. Sc. **152**:28 (July) 1916.

Hemangio-Endotheliomata of the Osseous System Associated with the Symptoms of Multiple Myelomata—A Lesion Hitherto Undescribed." In this case several of the flat bones and the upper end of the humerus were involved, but two examinations for Bence-Jones protein were negative. As no necropsy was performed, the only material available for study was that obtained by curetting a tumor attached to the ischium. The description of the histologic appearance was as follows:

The unit of the tumor is a thin-walled blood vessel, lined by a single layer of flattened endothelial cells, the lumen distended by red blood corpuscles,

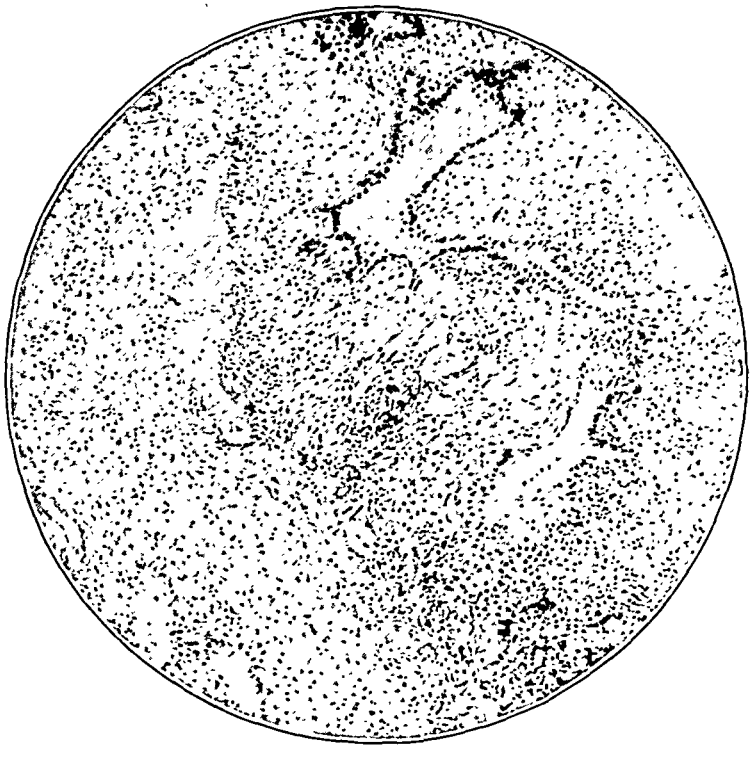

Fig. 2.—The predominating type of tissue, consisting of large blood channels with one or several layers of large endothelial cells and a cellular, edematous intervascular tissue; ×75.

the whole embedded in a stroma of poorly cellular fibrillar connective tissue arranged around spicules of bone. Here and there, however, the lining endothelium may be seen as a uniformly growing circumferential layer from five to twenty cells in depth, and from this point the process of proliferation may be followed through various stages leading to occlusion of the lumen by spindle-shaped tumor cells. In other cases, the overgrowth of endothelium commences at the periphery of the vessel as one or more armlike projections and the lumen is eventually occluded. An extraordinary histologic feature con-

sists in proliferation of the endothelium in such a way as to subdivide the vascular lumen into one or more compartments filled by red cells, obviously representing an attempt to form new vascular channels.

That true hemangiomas of bone may occur, if rarely, is indicated by Trommer's [6] compilation of eight cases, including one of his own, which seem for the most part to answer to this designation. Especially well established are those cases in which typical hemangiomas were also found outside the bones.

Fig. 3.—High magnification of vascular channel and intervascular tissue; × 115.

I have studied a case belonging to the group of vascular tumors of bone, which has seemed to explain certain features of the striking and peculiar angiomatous character of these growths.

REPORT OF CASE

History.—A Lithuanian laborer, aged 45 years, was admitted to Cook County Hospital, Dec. 22, 1917, stating that he had been well until three months previously (five months before his death) when he began to be troubled with pain in the right lumbar region, which soon extended to the left side

6. Trommer: Frankf. Zeit. f. Path. **22**:313, 1920.

also. This pain was exaggerated by exertion, bending and defecation. About this time his legs also became painful and swollen to the knees, so that he was obliged to remain sitting in a chair for three weeks. He then felt better and went back to his work, which involved lifting heavy boxes. After working two days, while lifting a box, he suddenly felt something crack and give way in his back. He was obliged to go to bed where he had since remained, unable to move his legs without discomfort, and with some difficulty in emptying his bladder. Immediately after this incident, he noticed a swelling in his back, which had not increased in size. For the three weeks preceding admission, he had a dull aching pain in the chest, associated with a sense of constriction. No other points of significance are recorded in the history except that he had been a heavy drinker.

Physical Examination.—This revealed slight edema of the feet, slight enlargement of the prostate, and a separation of the left rib from the spinal column with some loss of bone tissue. At this time, the reflexes were normal.

After four weeks he developed paresis of the lower extremities, with loss of reflexes and positive Babinski and Chaddock signs on both sides. The spinal fluid was clear, with a yellowish tinge (xanthochromia?) and an abundance of globulin. The Wassermann reaction was negative with both spinal fluid and blood. The urine was reported as normal, but was not examined specifically for Bence-Jones protein. The blood was normal. No other findings of importance were recorded, except a febrile attack in January, when his temperature rose to 105 F. The clinical diagnosis was neoplasm involving the eleventh rib on the left and the lower dorsal vertebrae with pressure on the cord.

Necropsy Findings.—The patient died in the hospital, Feb. 13, 1918, and the body was examined on the same day.

External examination showed a slight protrusion about the base of the eleventh left rib, and some induration about the end of the twelfth left rib, without adhesion to the skin. Beyond slight edema over the ankles and a slight enlargement of the lymph glands in the left groin, no other external abnormalities were found. The large serous cavities were without important changes. The heart was slightly hypertrophied, with a terminal dilatation of the right ventricle. The blood vessels were practically free from sclerosis. The lungs showed only a slight hypostatic edema, and a laminated thrombus in one of the large arteries in the left lower lobe. No gross signs of tuberculosis were found. The kidneys showed slight chronic nephritis, with an early acute infection, probably ascending from the bladder, which showed a marked acute cystitis, without prostatic changes. The perirenal tissues on the right side were indurated and firmly adherent to the kidney. Otherwise, there were no gross visceral changes.

On the posterior surface of the sternum, at the level of the third rib, on the left side, there was a small area where the bone was twice the normal thickness. When cut with the necropsy knife, no soft tissue was found, the thickening being solid bone growth.

The vertebral column showed a marked lordosis in the lumbar region, with a kyphosis in the lower dorsal region.

The eleventh and twelfth ribs on the left side had apparently lost their attachment to the vertebral column. At the attachment of the eleventh left rib to the vertebra, there was a retropleural, fluctuating swelling, and there

was an increased amount of soft tissue in this location which extended from the tenth to the twelfth dorsal vertebrae.

In the neighborhood of the swelling, there was hemorrhage into the surrounding tissue and a complete solution of continuity of the eleventh left rib, with a gap about 4 cm. long, containing a soft, friable, dark red tissue. The body of the eleventh vertebra was somewhat eroded, and almost completely replaced by a soft jelly-like tissue that greatly resembled a blood clot, although of a somewhat firmer or tougher texture; the vertebral column at this point was easily cut into by an ordinary necropsy knife.

The body of the third lumbar vertebra showed similar invasion by like tissue, as did also the fifth dorsal vertebra at its attachment to the fifth right rib, extending into and involving the fifth right rib to such an extent that a finger could be inserted between the eroded end of the rib and the vertebra.

To the right of the median line, opposite the fifth dorsal vertebra, there was a small subpleural nodule, which appeared to be a pleural metastasis; in this vicinity there was also an independent area of diffuse growth of a distinctly neoplastic nature, whitish in color, measuring 3 cm. square by 0.5 cm. thick.

Microscopic examination of the viscera revealed nothing that was not indicated by the gross examination, except the presence of much hemosiderin in the spleen, and some fatty infiltration and round cell proliferation in the liver.

STRUCTURE OF THE BONE TUMORS

Microscopically the soft tumor tissue outside the bones, including the pleural and subpleural nodules,[7] exhibits the typical features of myeloma of the myeloblastic type, corresponding therefore to the clinical and gross anatomic picture of multiple myeloma of the flat bones.

On the other hand, the bloody or gelatinous growths found in the bones presents an entirely different picture, and indeed it is difficult to find within the bones any tissue resembling the myelomatous growth. About all that remains of the original intra-osseous tumor growth are occasional small islands of myeloblastic cells. Often these persist about the new-formed blood sinuses in large areas of hemorrhagic necrosis, thus suggesting a hemangiosarcoma or a perivascular endothelioma (Fig. 1). However, the amount of myeloma tissue left within the bone is so small that it would be difficult to identify this as a case of multiple myeloma if it were not for the extra-osseous infiltration and the pleural metastases. Had the patient died without extra-osseous growths, as commonly is the case in multiple myelomatosis, the diagnosis would probably have been that of primary multiple vascular tumors of the bones, with uncertainty as to whether this was to be interpreted as an endothelioma or a hemangiosarcoma.

The intra-osseous tumor tissue presents many different features in different sections, passing from the areas where some myeloma tissue still persists in areas of hemorrhagic necrosis, through all the stages

7. The occurrence of true metastasis of myelomas outside the bones has been discussed by Symmers, Ann. Surg. **67**:687, 1918.

of organization of a blood clot until areas can be found where there remains still living bone with its marrow replaced by loosely organized connective tissue with more or less blood pigment, and few or no cells characteristic of bone marrow. Apparently these last named areas, which are found in the intact bony shell about the vascular tumors, represent complete hemorrhagic necrosis and replacement of the peripheral tumor tissue, destroyed by pressure against the intact bone.

A large proportion of the intra-osseous neoplastic tissue, which formed the red, jelly-like masses, consists of organizing clot with wide blood channels, and an intervascular framework of edematous embryonal tissue (Figs. 2 and 3). In some places, this assumes the appearance of myxomatous tissue, in others of a spindle-cell growth suggesting somewhat sarcoma. There are considerable areas in which masses of very large pale cells form the matrix beween the vascular channels, and these seem to correspond to some of the descriptions of endotheliomas in bones, but probably are embryonal cartilage cells. Most of the blood sinuses are lined with cuboidal embryonal endothelium, which is often heaped up into several layers or into nodules, thus intensifying the resemblance to endothelioma. Occasional myeloblastic cells are found in this vascular tissue, enhancing its apparent neoplastic character.

SUMMARY

From the gross and microscopic standpoints, therefore, we find in this case illustrations of two different pathologic processes in the involved bones. Although unquestionably the condition is actually one of multiple myelomatosis of the bones, yet there are features that seem to correspond perfectly to what have frequently been described as either angiosarcoma or multiple endothelioma of bone. If one were presented only with sections of the bloody, gelatinous tumors within the bone, there would be found nothing to suggest the existence of a myeloma, and with some of the sections the diagnosis of hemangio-endothelioma would be strongly suggested. Therefore, *a growth that begins as a myeloma may take on the characteristics of a neoplasm of vascular origin, with no remnants of the original tumor to be found in the entire bone tumor.* It would seem probable that this is the explanation of the case reported by Symmers and Vance, and that necropsy would have disclosed that it really was a case of multiple myeloma.

As an explanation of the production of these highly vascular growths of embryonic type of blood vessels replacing tumors in the bones, these points may be advanced: Because of the unyielding character of the osseous shell of the bone-marrow tumors, the growth of the tumor cells is more likely to shut off the blood supply and to produce necrosis than is the case in tumors located in other tissues. Following the

necrosis, hemorrhage replaces the absorbed material, and organization of the resulting clot takes place. But, again, because of the firm outer shell of intact bone, the organization does not follow the course usual in organization in other tissues, for the contraction and obliteration of the capillaries cannot take place. Instead, the new connective tissue becomes more or less edematous or of a myxomatous type, since it cannot contract to form scar tissue, and the new-formed vessels persist, in their large embryonal form, or even dilate with absorption of the clot, and later secondary proliferative changes of the intima of these blood channels may still further enhance the resemblance to an endothelial neoplasm. Such changes are not peculiar to hemorrhagic tumors in bones, for they may be observed in greater or less degree whenever vascular granulation tissue is prevented from contracting because of its attachment to bones, for example, in some areas of organizing pleural exudates close to the ribs, or in the floor of leg ulcers overlying the tibia.

The observations lend support to the opinion expressed by others, notably Ewing, that many of the tumors described as multiple vascular endotheliomas of bone, and sometimes also as bone aneurysm, are really myelomas. This view is in harmony with the fact that myelomas are the chief form of multiple bone tumors, and that the frequency, if not the existence, of true endothelioma, is becoming less and less supported. It is, of course, probable that other bone tumors than myelomas may undergo the same sort of hemorrhagic necrosis and replacement by vascular new tissue.

THREE CASES OF SUBPERITONEAL, PEDUNCULATED ADENOMYOMA *

THOMAS S. CULLEN
BALTIMORE

Adenomyomas of the uterus are becoming more and more frequently recognized.

The diffuse adenomyoma may begin in the anterior or posterior wall of the uterus, but not infrequently the growth forms a definite mantle around the uterine cavity. In time portions of it may be forced into the cavity of the uterus forming submucous adenomyomas, which occasionally are expelled through the cervix.

In other cases a portion of the diffuse adenomyoma may be forced to the outer surface of the uterus, producing a subperitoneal or intraligamentary adenomyoma. Such growths are not very common. I have discussed subperitoneal and intraligamentary adenomyomas of the uterus so fully in a previous publication [1] that it would be mere repetition to go into details in the present paper.

During the month of November, 1920, I operated upon three different patients for subperitoneal, pedunculated adenomyoma. In Case 1 the condition was detected in the laboratory, in Cases 2 and 3, the diagnosis became perfectly clear as soon as I had exposed the subperitoneal tumor that lay in the pelvis.

These three cases are such beautiful examples of a relatively rare condition that we may with profit consider them in detail.

The drawings by Mr. Brödel, supplemented by the photomicrographs by Mr. Schapiro, tell nearly the whole story, consequently this paper may be considered merely an accompaniment to their splendid artistic rendition.

REPORT OF CASES

CASE 1.—*Multiple uterine myomas; adenomyoma of the anterior uterine wall densely adherent to the bladder; diffuse adenomyoma of the posterior uterine wall with a pedunculated, subperitoneal adenomyoma springing from it* (Figs. 1, 2, 3 and 4).

History (Gyn. No. 26282).—S. J., colored, aged 39, was admitted to the gynecologic department of the Johns Hopkins Hospital, Nov. 2, 1920. Novem-

---

* From the gynecologic department of the Johns Hopkins Medical School and of the Johns Hopkins Hospital.

1. Cullen, T. S.: Adenomyoma of the Uterus, Philadelphia, W. B. Saunders Company, 1908, Chaper 5, p. 125 et seq.

ber 4 she was transferred to the medical service on account of her cardiac condition. She was readmitted to the gynecologic service, Nov. 9, 1920 (Gyn. No. 26340). Two of her sisters had died of tuberculosis. She had had a dry pleurisy at 30, but otherwise had been healthy. Her menstrual flow ceased completely for one year when she was 18. As a general thing, it had been scant, lasting from two to three days, now it was profuse and was of four to five days' duration. There was no intermenstrual bleeding. The patient was unmarried and had never been pregnant.

In May, 1920, she began having pain in the lower part of the back at the periods. It radiated around to the front, there being discomfort in the lower abdomen particularly on the left side. She had had some nausea and vomiting. During the last two months, the patient had developed shortness of breath and had had insomnia.

Physical Examination.—Her eyes showed interstitial keratitis. The heart was not enlarged, but there was a systolic murmur at the apex which was transmitted to the axilla, and there was an extra systole every third beat.

Partially filling the lower abdomen was an irregular growth. On pelvic examination, a rough, firm, irregular mass was found filling the posterior fornix. This tumor extended upward almost to the umbilicus and laterally reached the crest of the ilium. Arising from the left lateral wall of the vagina was an irregular polypoid growth which appeared at the outlet.

Operation.—Nov. 10, 1920, I performed a supravaginal hysterectomy in the usual manner. Some difficulty was experienced in liberating the bladder, which had become densely adherent to a small myoma situated in the anterior wall of the uterus. The left tube and the appendix were removed with the uterus.

The postoperative convalescence was uneventful and the patient was discharged on the fourteenth day.

Examination of Specimen (Gyn.-Path. No. 26352).—The specimen consists of a myomatous uterus with the left tube and ovary attached (Fig. 1).

The supravaginally amputated uterus is 10 cm. in length, 13 cm. in breadth and 9 cm. in its anteroposterior diameter. Scattered throughout the walls of the uterus are several interstitial and partly submucous myomas. The largest of these is approximately 6 cm. in diameter.

On the anterior surface of the fundus is a sessile nodule, 3 by 1.5 cm. This myoma was covered by adhesions. On splitting it, the cause is found to be evident. The upper portion consists of a discrete myoma, the lower portion of a diffuse myoma, irregular in outline, 1.5 cm. in length, which contains two small brownish areas each about 2 mm. in diameter. This small diffuse growth is without a doubt an adenomyoma.

The cavity of the uterus is 5.5 cm. in length. Its mucosa does not seem to be altered.

Springing from the posterior surface of the fundus is a spherical myoma, 3 cm. in diameter. Its pedicle is unusually well developed, and measures approximately 1 cm. in length and 7 mm. in diameter. This myoma on section presents in most places the usual appearance, but at several points are small areas presenting the typical chocolate-colored appearance. These areas vary from 1 to 2.5 mm. in diameter.

The left tube and ovary offer nothing of interest.

Histologic Examination.—Sections from the endometrium show an intact surface epithelium. The mucosa looks perfectly normal, but here and there it extends into the underlying muscle. The muscle presents a diffuse myoma-

tous appearance. Scattered everywhere throughout the posterior wall of the uterus over a wide area and particularly pronounced in the vicinity of the pedunculated nodule noted on the posterior surface are many areas of uterine mucosa. The picture as a whole is one of a definite diffuse adenomyoma of the posterior uterine wall. In some places individual glands are found in the muscle. Some of these lie in direct contact with it, others are separated from it by a small zone of stroma. Here and there are miniature uterine cavities. Many of the glands are dilated.

The small discrete myoma noted in the anterior wall of the uterus shows a considerable amount of hyaline transformation. The diffuse myomatous thickening beneath this myoma contains uterine glands and also two miniature

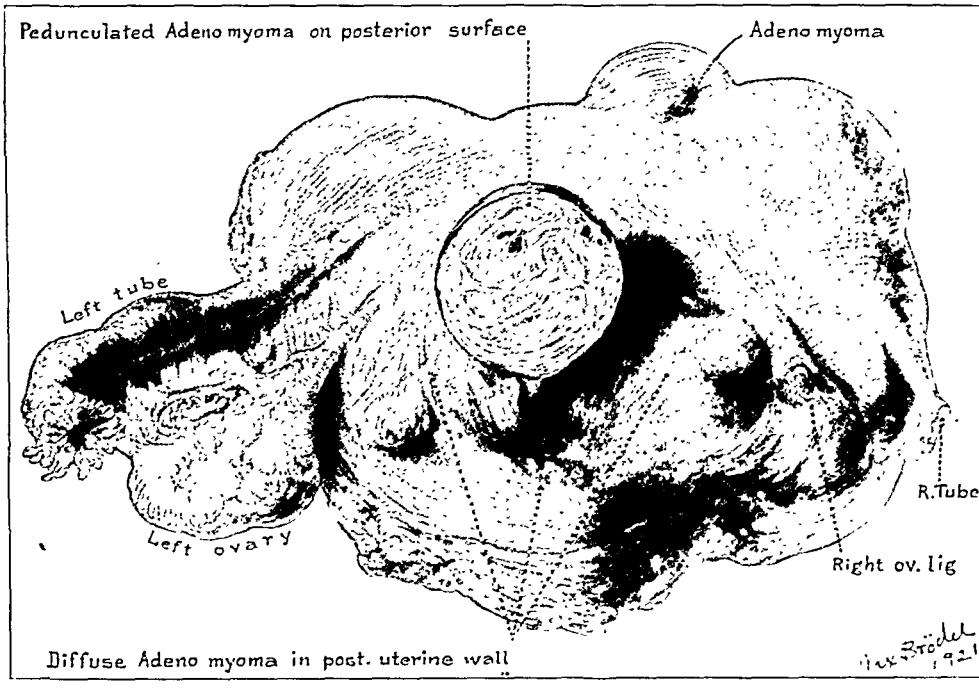

Fig. 1 (Case 1).—A pedunculated adenomyoma springing from the posterior surface of the uterus (Gyn.-Path. No. 26352). Scattered throughout the uterine walls are numerous interstitial and subperitoneal myomatous nodules. In the anterior wall just beneath a myoma, and at a point indicated by the arrow, was a small diffuse adenomyoma. To this the bladder was densely adherent. The posterior uterine wall is occupied by a very extensive diffuse adenomyoma. Springing from this area is a pedunculated myoma. On section this is seen to contain several small cavities in its upper portion. The histologic appearances of this pedunculated myoma are shown in Figures 2, 3 and 4. The cystic areas which were filled with chocolate-colored material are miniature uterine cavities. Islands of uterine mucosa were also scattered throughout the myoma.

uterine cavities, both of which contain a small amount of blood. These are the cavities that were filled with chocolate-colored material. It was at this point that the bladder was densely adherent at the time of operation.

The pedunculated subperitoneal myoma springing from the posterior surface of the uterus consists of typical myomatous tissue, very dense in character. At one point just at the surface of the myoma is an especially dense area, 5 mm. long and varying from 2 to 3 mm. in breadth (Fig. 2). This stains very deeply and consists of myomatous tissue. It contains a definite miniature uterine cavity and a large area of typical uterine mucosa, the stroma of which shows old blood (Fig. 3).

In the depth of the myoma there is a definite miniature uterine cavity (Fig. 4). Lining one side of this is the characteristic uterine mucosa, which shows some hemorrhage. The greater part of the cavity is lined with flattened epithelium lying in direct contact with the muscle. This miniature uterine cavity contains exfoliated epithelium, a few polymorphonuclear leukocytes and some blood. The tumor is a pedunculated subperitoneal adenomyoma.

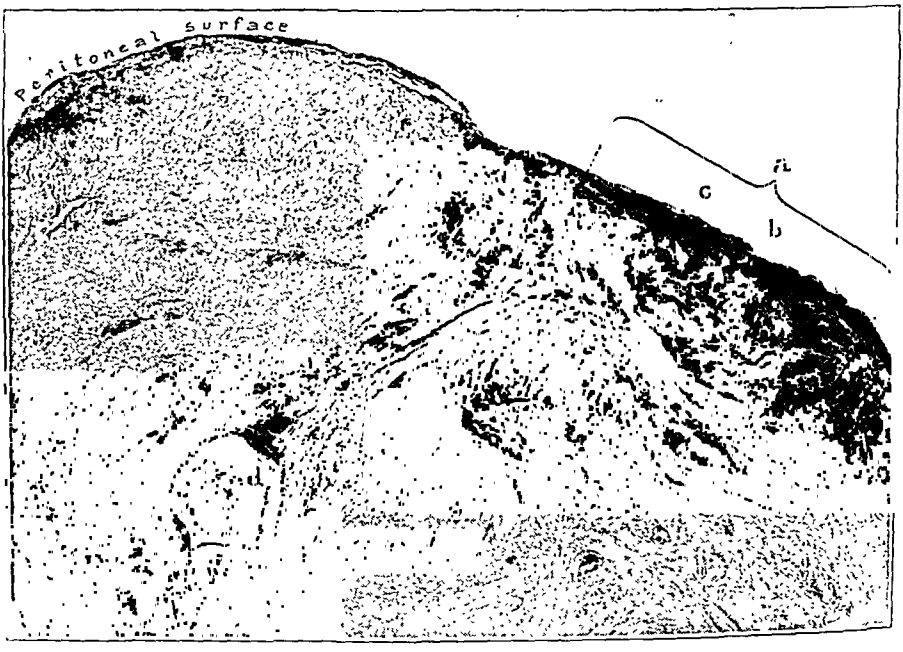

Fig. 2.—A subperitoneal pedunculated adenomyoma of the uterus (Gyn.-Path. No. 26352). This is a very low power picture of a portion of the pedunculated myoma springing from the posterior surface of the myomatous uterus seen in Figure 1. At *a* is a sharply circumscribed myomatous area. Just beneath the peritoneal surface it contains an island of typical uterine mucosa (*b*), also a miniature uterine cavity (*c*). An enlargement of this area is shown in Figure 3. In the lower left part of the field is another miniature uterine cavity *d*. An enlargement of this is shown in Figure 4.

When we consider the specimen as a whole, we find that the endometrium shows a definite tendency to extend downward. Myomatous nodules are scattered throughout the uterine walls. There is a diffuse adenomyoma in the anterior wall of the uterus. This is in the outer layer. It reaches the surface and has become densely adherent to the bladder. There is a widespread diffuse adenomyoma of the posterior uterine wall, confined in large measure to the outer layers of the uterus. The pedunculated adenomyoma of the posterior

wall springs from this diffuse adenomyomatous area. The pedicle of the adenomyoma, however, does not contain uterine glands.

This is one of the most widespread distributions of adenomyoma of the uterus that I have ever seen.

CASE 2.—*A subperitoneal, pedunculated adenomyoma springing from the posterior surface of the uterus, filling Douglas' culdesac, firmly adherent to the sigmoid and easily recognized on account of its bluish black cysts* (Figs. 5 and 6).

History.—Mrs. T. H., aged 42, came to see me, Nov. 8, 1920, complaining of pain on the right side of the lower abdomen. Her menses began at 14 and were always regular. The flow was moderate in amount. There had been some pain just before the period. She had had one miscarriage.



Fig. 3.—Uterine mucosa in a pedunculated subperitoneal myoma (Gyn.-Path. No. 26352). This is an enlargement of the area *a* in Figure 2. A blood vessel just beneath the peritoneum is shown at *a*. Occupying the right and central portion of the field is a large island of uterine mucosa consisting of glands and stroma. Some of the glands are dilated. At *b* is a miniature uterine cavity.

Four years before I saw her, she fell from a chair, and two days later her period came on and lasted for twelve days. A little later she fell down thirteen steps, landing on her head. She had an attack of inflammatory rheumatism, and it was impossible for her to raise her hands.

Physical Examination.—She was well nourished and weighed 152 pounds. Her digestion had not been good.

I found the outlet moderately relaxed and the cervix small. Behind the cervix were two or three nodular lumps extending off to the right and there was a tumor mass which reached half way to the umbilicus and seemed to involve the body of the uterus. A diagnosis of multiple fibroids was made.

Operation.—The patient was admitted to the Church Home and Infirmary and operated upon, Nov. 11, 1920. When the abdomen was opened, we found the uterus retroposed and attached to the fundus a pedunculated myoma, 3 cm. in diameter. Just below this was the pedicle of a somewhat globular tumor that filled the pelvis. This tumor was firmly adherent to the sigmoid flexure and was loosened with a good deal of difficulty. As soon as we exposed it, we saw several bluish black cysts varying from 3 to 5 mm. in diameter just beneath the peritoneal surface of the tumor, and at one point an irregular oval area about 1 by 2 cm., with the characteristic brownish yellow color. It was perfectly clear that we were dealing with a pedunculated subperitoneal adenomyoma,

Fig. 4.—A miniature uterine cavity in a subperitoneal pedunculated adenomyoma (Gyn.-Path. 26352). This is an enlargement of the area *d* in Figure 2. Lining the cavity on the right is typical uterine mucosa. The remainder of the cavity is lined with one layer of more or less flattened epithelium, which for the most part lies in direct contact with the muscle. Partially filling the cavity are fragmented nuclei, polymorphonuclear leukocytes, old blood and crystals.

as a matter of fact, the best example of a pedunculated adenomyoma that I have ever seen. There was a little oozing in the pelvis near the right ureter, which was difficult to check. To remedy this we put in two cigaret drains and drew them out through the lower angle of the incision. The patient made an uninterrupted recovery.

Examination of Specimen (Gyn.-Path. No. 26354).—The specimen consists of a myomatous uterus. The uterus is 5.5 cm. in length, 6 cm. in breadth and 4 cm. in its anteroposterior diameter. It is only very slightly enlarged. Spring-

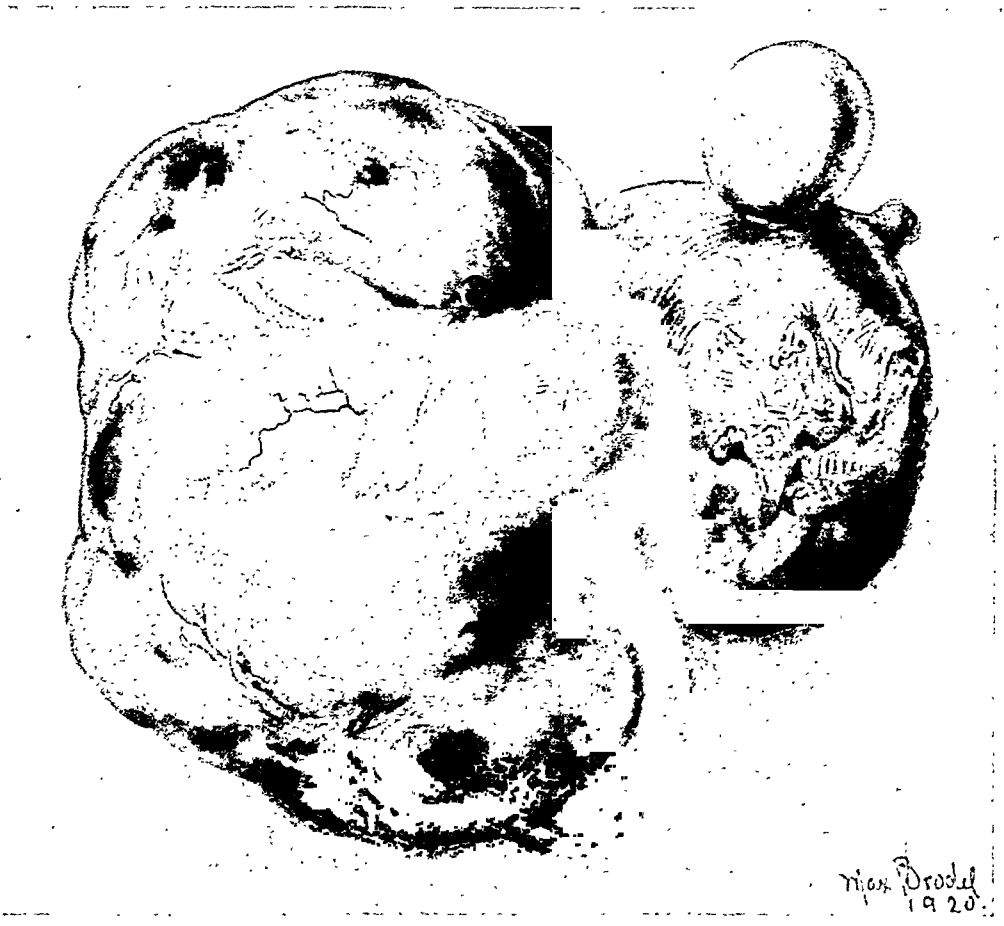

Fig. 5 (Case 2).—A pedunculated subperitoneal adenomyoma springing from the posterior surface of the uterus (Gyn.-Path. No. 26354). Attached to the surface of the uterus are a few small myomas. The chief interest centers in a lobulated pedunculated myoma springing from the posterior surface of the uterus. This tumor was firmly fixed at the floor of the pelvis and was intimately attached to the sigmoid. At the lower end of this tumor is a slightly yellowish area. This is where the pelvic fat was blended with the tumor. Shining through the peritoneum of the tumor are bluish black cysts and along the convexity near the middle is a rusty brown area. From the picture it is at once evident that we are dealing with a pedunculated subperitoneal adenomyoma. Figure 6 shows the appearance of this tumor on section

Fig. 6.—A longitudinal section of a pedunculated subperitoneal adenomyoma of the uterus (Gyn.-Path. No. 26354). This is a longitudinal section of the subperitoneal pedunculated tumor seen in Figure 5. In the upper part of the specimen is a definite cavity with the muscle arranged spherically around it. In the middle of the convex surface, we find cross sections of several cysts which were filled with chocolate-colored contents. One of these cystic areas reaches the surface and corresponds to the situation of the rusty area noted in the water color. These cysts were lined with one layer of cylindric epithelium. In the lower part of the specimen are numerous small spaces. The majority of these are miniature uterine cavities. The picture is characteristic of a widespread adenomyoma on section.

ing from its surface are a few small myomas, varying from 1 to 7 mm. in diameter, and projecting from the top of the uterus is a pedunculated myoma, 1.5 cm. in diameter.

Springing from the posterior surface of the uterus near its top is a subperitoneal, slightly pedunculated myoma. This pedicle was so short that when I went to lift the tumor up it tore away from the uterus leaving no appreciable pedicle but just a raw area, 1.5 cm. in diameter. This myoma is roughly kidney-shaped, 11 cm. in its longest diameter, 7 cm. broad and 6 cm. thick. At one point is a fatty adhesion, 1.5 cm. long. The general appearance, as noted at operation, is well shown in Figure 5. Scattered over the surface are cysts. Some of them are 1 cm. in length, most of them are bluish black. At one point near the middle of the convex surface of the tumor is a brownish area, 1.5 cm. in diameter.

The tumor, on section, presents the usual myomatous picture, but at many points there are chocolate-colored areas (Fig. 6). These are more noticeable near the convex surface of the tumor. The bluish black cysts are filled with blood or grayish brown material, evidently old blood, or with a brownish material. At one pole of the tumor is a somewhat punctiform area, 3 by 4 cm. The punctiform spaces are filled with old blood or with a grayish black material. Here and there are yellowish brown areas. Without further examination, we could unhesitatingly say that this subperitoneal nodule is an absolutely typical adenomyoma.

Histologic Examination.—Sections from the endometrium show that it is relatively normal. The mucosa itself presents the usual picture. At some points, however, it shows a definite tendency to extend into the underlying muscle.

The small myoma projecting from the fundus presents the usual picture.

Sections from the cystic area of the kidney-shaped pedunculated subperitoneal myoma show typical miniature uterine cavities lined usually on one side with one layer of cylindric epithelium, on the other with a zone of normal uterine mucosa. They are filled with blood. Occasionally an isolated gland is found in the myomatous tissue. The cysts filled with chocolate-colored contents are for the most part lined with one layer of cylindric epithelium. In some places, this epithelium rests directly on the muscle, at other points there is a small layer of intervening stroma. Opening into the cyst spaces, one finds here and there normal uterine glands.

This is a fine example of a widespread adenomyomatous condition of a subperitoneal, pedunculated myoma.

CASE 3.—*Multiple uterine myomas; diffuse adenomyoma of the anterior and posterior uterine walls* (Fig. 7); *pedunculated, subperitoneal adenomyoma springing from the posterior uterine wall and filling Douglas' culdesac* (Figs. 8 and 9).

History (Gyn. No. 26421).—O. M., aged 35, white, married, was admitted to the Johns Hopkins Hospital, Nov. 27, 1920, complaining of nervousness, soreness in the left lower abdomen and shooting pains in the legs, more marked on the left.

The family history was negative, and the previous history, apart from occasional intermenstrual bleeding during the last year, was without interest. She had had one full-term child and six or seven induced abortions at the second month.

In 1913, following an abortion, the patient began to have pain in the left lower abdomen. In 1917, this became more severe. The patient was run

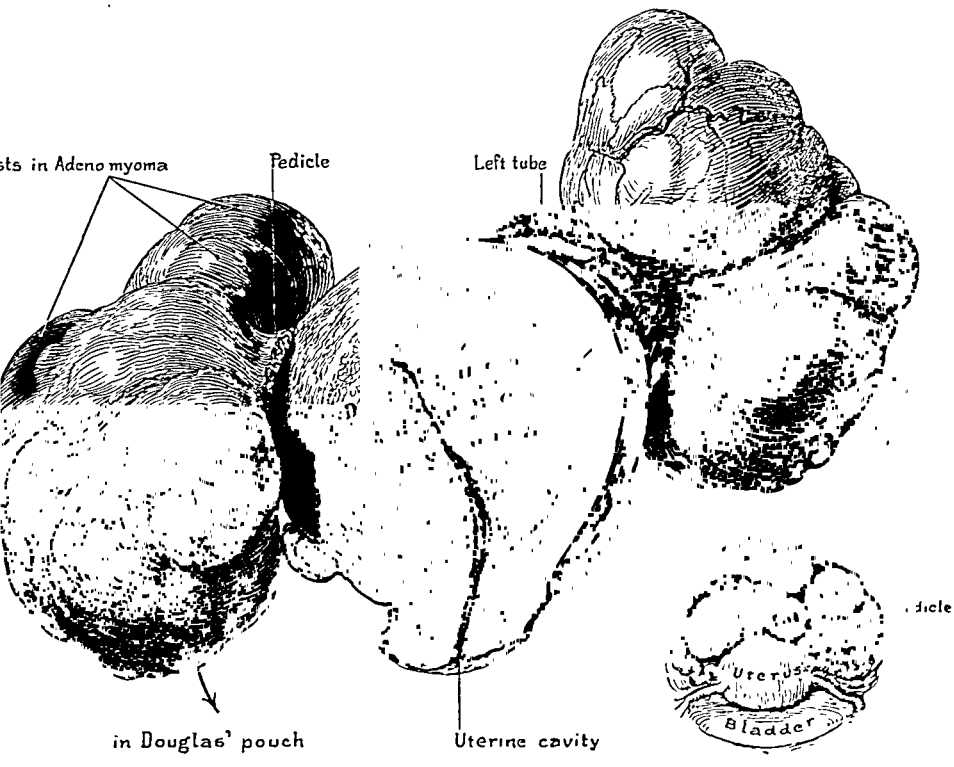

Fig. 7 (Case 3).—Subperitoneal, pedunculated adenomyoma associated with diffuse adenomyoma of both the anterior and posterior walls of the uterus (Gyn.-Path. No. 26401). The uterine walls are much thickened owing to the presence of a diffuse adenomyoma which occupies both the anterior and posterior walls. There are also a few small discrete myomas. Springing from the fundus just behind the insertion of the left tube is a lobulated myoma with numerous blood vessels coursing over its surface. Attached to the posterior surface of the uterus by a very short pedicle is a lobulated myoma which lay in Douglas' culdesac and was adherent to the sigmoid. Projecting from the surface of this were bluish black cysts. These are well shown in Figures 8 and 9. The relation of the uterus with its tumors to the bladder and rectum is indicated in a small sketch in the right lower corner.

down physically and was informed she had an abdominal tumor. From that time on the menstrual flow had been more profuse.

Physical Examination.—The Wassermann test was negative, the urine was normal, there were 9,600 leukocytes and hemoglobin was 65 per cent.

A firm, rounded tumor mass could be felt on the left side, extending 4 cm. above the symphysis. The outlet was moderately relaxed, the cervix was firm and pointed forward. In the posterior fornix was a hard nodular tumor, approximately 10 or 11 cm. in diameter. It appeared to be somewhat adherent. Movement of the cervix caused movement of both the anterior and posterior tumor masses.

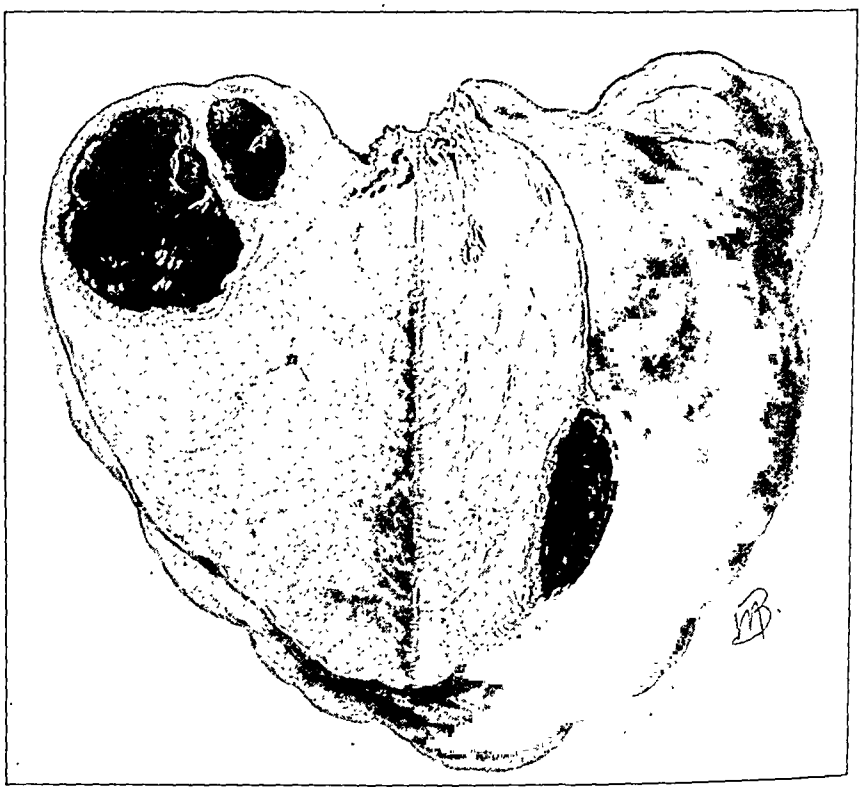

Fig. 9.—A subperitoneal pedunculated adenomyoma of the uterus (Gyn.-Path. No. 26401). The specimen has been so cut that about one fourth of it has been removed. We see the bluish black cysts noted in Figure 8, on section. They are filled with blood. The cysts were lined with one layer of cuboidal epithelium which in places was in direct contact with the myomatous muscle, at other points separated from it by a definite stroma. Scattered throughout the tumors were isolated glands lined with cylindric epithelium.

Operation.—Nov. 29, 1920, I removed the uterus, both tubes, the right ovary and the appendix. The hysterectomy was accomplished without much difficulty. The tumor occupying the culdesac tore away from the uterus and was removed separately. This tumor was somewhat adherent to the sigmoid. The bluish black cysts on its surface told us at once that we were dealing with a subperitoneal pedunculated adenomyoma. The left tube was apparently patent, though nodular. The right tube was the seat of a hydrosalpinx. The right

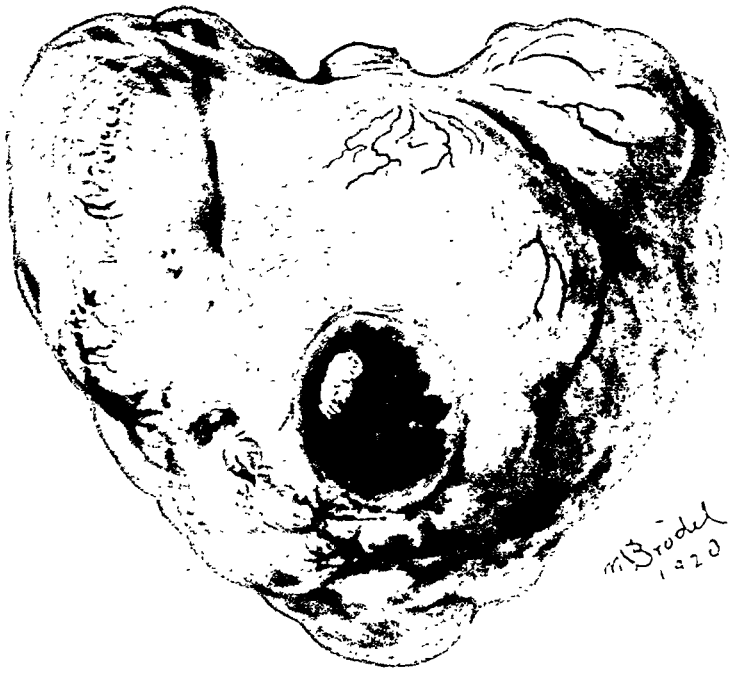

Fig. 8.—A pedunculated, subperitoneal adenomyoma of the uterus (Gyn-Path. No. 26401). This is the pedunculated myoma which sprang from the posterior surface of the uterus seen in Figure 7. The tumor is lobulated, and projecting from its surface is a bluish black cyst. That there are other cysts similar in character is clearly evident from the bluish black appearance in the left upper portion of the picture. Several other small bluish black cysts are also noticeable along the left half of the specimen. The appearance of the specimen on section is shown in Figure 9. The gross appearance at once indicates adenomyoma. The tumor at operation was adherent to the sigmoid flexure.

ovary contained a corpus luteum cyst, 4.5 cm. in diameter. The postoperative course was uneventful and the patient was discharged Dec. 18, 1920.

Examination of Specimen (Gyn.-Path. No. 26401).—The specimen consists of a multinodular myomatous uterus which has been amputated through the cervix. Both tubes and the right ovary are also attached.

The uterus itself is 8 cm. long, 7 cm. broad and 6 cm. in its anteroposterior diameter. The anterior surface is relatively smooth, the posterior is covered with shaggy adhesions. The uterus on section shows a normal looking cavity. The posterior wall of the uterus reaches a thickness of 2.5 cm.; the anterior wall is 3.5 cm. thick. Forming a mantle around the upper two thirds of the uterine cavity and implicating both the anterior and posterior walls is a definite diffuse myomatous thickening, which immediately suggests adenomyoma (Fig. 7). Scattered throughout both the anterior and posterior walls are a few small discrete myomas varying from 8 mm. to 1.5 cm. in diameter.

Springing from the posterior surface of the uterus just behind the insertion of the left tube is a lobulated myoma, 10 by 7 by 6 cm., which shows large blood vessels coursing over its surface. On section it presents the usual myomatous picture.

Attached to the posterior surface of the fundus by a very short pedicle, 1.5 cm. in diameter, is a heart-shaped myoma, 9 by 7 by 6 cm. Near its convex surface, this shows a bluish black cyst, about 2.5 cm. long by 2 cm. broad. This is very well shown in Figures 8 and 9. Near the base of the tumor is a rather puckered area just to one side of the pedicle. The underlying tissue here looks rather bluish black. A few other smaller cysts are also noticeable. The bluish black cyst near the apex of the tumor has thin walls and contains blood (Fig. 9). The bluish black area near the pedicle shows a thin-walled cyst, 2.5 cm. in diameter, filled with dirty chocolate-colored material—old blood. This myoma on section, apart from the few cysts mentioned, presents the ordinary myomatous picture.

As was noted in the operative report, the left tube was nodular but patent. The right tube was the seat of a hydrosalpinx.

Histologic Examination.—Sections from the uterine wall show a widespread adenomyoma of the anterior wall, and a moderate grade of adenomyoma of the posterior wall. The uterine mucosa looks normal, as does also that scattered throughout the walls of the uterus. It is readily possible to trace the uterine mucosa directly into the underlying muscle.

Sections from the pedunculated myoma which sprang from the surface of the uterus just behind the insertion of the left tube show a good deal of hyaline transformation and some liquefaction. They do not show any glands.

Sections from the pedunculated nodule which sprang from the posterior surface of the fundus, and in which the bluish black cysts were seen, show that these cysts are filled with blood and that they are lined with one layer of cuboidal epithelium. This in some places is gathered up into little knobs. The epithelium sometimes rests directly on the muscle, sometimes it is separated from it by a definite stroma. Scattered throughout the myomatous tissue are a few small glands lined wih cylindric epithelium. There is no doubt that we have here an adenomyoma and that the blood in the cysts was of menstrual origin. The epithelial elements, however, in this myoma were very meager.

The association of the diffuse adenomyoma of both the anterior and posterior walls of the uterus and of the subperitoneal adenomyoma are very interesting. With such a combination as this the probable origin of the pedunculated subperitoneal adenomyoma is not difficult to surmise.

COMMENT

From a study of these three cases it is perfectly clear that a diagnosis of subperitoneal, pedunculated adenomyoma of the uterus is impossible unless, perchance, a submucous adenomyoma has been previously expelled, and even then a subperitoneal nodule might be only a simple myoma.

In Case 2 we found extension of the uterine mucosa into the muscle and in Cases 1 and 3 there was a diffuse adenomyoma of the uterine wall.

From these cases we can clearly see what complications may develop if such pedunculated subperitoneal adenomyomas are let alone. In previous cases we have found very small subperitoneal adenomyomas projecting from the uterine wall. In a few cases we have noted adenomyomas so intimately blended with the pelvic structures that their removal was utterly impossible.

In Case 1 the adenomyomatous elements of the pedunculated myoma had not yet reached the peritoneal surface of the tumor, but in Cases 2 and 3 the tumor had already become adherent to the sigmoid, the adhesion being particularly pronounced in Case 2.

The more we study adenomyomas the more fully are we convinced that they should, if possible, be removed as soon as they have been diagnosed.

I wish to express my heartiest thanks to Mr. Max Brödel, Director of the Department of Art in Medicine in The Johns Hopkins Medical School, for his remarkable illustrations and to Mr. Hermann Schapiro for his splendid photomicrographs.

OBSERVATIONS ON THE NORMALLY DEVELOPING ELBOW

ISIDORE COHN, M.D.
Associate Senior Surgeon, Touro Infirmary; Professor of Clinical Surgery, Tulane University of Louisiana School of Medicine
NEW ORLEANS

This study was prompted by a desire to know more about the appearance of the developing elbow. Certain facts stand out in bold relief to those who interest themselves in injuries about the elbow, or any other joint, in the young. Some of the points to be mentioned are self-evident, and yet a survey of the literature, or the comparative absence of such a literature, makes their mention of value.

This is only one of a series of studies which will be carried out in a like manner on other joints.

In order to study the subject in a systematic manner, I have divided the paper into four parts:

I. A review of the literature.

II. Observations on a series of normal elbows at various ages.

III. Descriptive findings of the individual roentgenograms.

IV. Clinical experience in the treatment of injuries of the elbow.

I. A REVIEW OF THE LITERATURE

The elbow in the young is frequently the seat of injury. Our predecessors were not so fortunate as we in having the valuable assistance of roentgenograms. In spite of this handicap, a review of the expressions of some of the authorities who wrote before the advent of the roentgen ray will demonstrate how well they utilized their minute knowledge of anatomy for the benefit of the patient. A similar review of more recent literature will prove that since the advent of the roentgen ray proper use has not been made of this aid.

It may prove of interest to others as it has to me to quote some of the authors of the modern period preceding the introduction of the roentgen ray.

Wheelhouse,[1] in 1885, wrote: "You should never consider your knowledge of the bones to be perfect until you have made the anatomy of the epiphyses as thorough as that of every other point in connection with them."

1. Wheelhouse: Clinical Lecture. Surgery of the Epiphysis. Brit. M. J. **1**:475, 1885.

Professor Smith said, "When the surgeon is called upon for his opinion respecting the nature of the injuries occurring in the vicinity of the larger joints in early life, he will find that the knowledge of the anatomy of the epiphyses is of the greatest importance."

Jonathan Hutchinson [2] writing in 1885 on injuries to the epiphyses stated:

"They constitute really a comparatively new topic, and it is almost astonishing to know that within the last half century the opinion was expressed strongly that separations of the epiphyses were impossible. Subsequently Delpeche, and again Malgaigne a few years later, stated as their opinion *that such* separations did not differ in any particular respect from fractures, and that there was no importance in attempting to distinguish between them.

"I am not far wrong in saying that in our current manuals on surgery of the day you will find comparatively little information with reference to these injuries.

"They are tolerably common. . . . They are important to recognize and treat." [3]

John Poland [4] in 1897, under the title of "Diagnosis of Traumatic Separation of the Epiphyses," was content to state that "these injuries can only occur, as a rule, in patients below 21 or 23 years of age before the epiphyses have become united by bone to the shaft."

A. H. Tubby,[5] in 1899, writing on "Traumatic Separation of the Epiphyses of the Upper Extremity" states: "The subject of traumatic separation of the epiphyses is now receiving a fuller measure of attention than formerly. Separations of the epiphyses are even more important than fractures, from their occurrence in young life and the important effects that may ensue in regard to the subsequent growth of the bone."

Case reports and museum specimens of epiphyseal separations are included in this paper, but no allusion is made to the ages at which various epiphyses appear, nor to ages of ossification, and no mention is made of the appearance of these lines and the possibility of misinterpreting them as fractures.

"It is indeed strange that so little has been written upon the subject of epiphyseal separation of the ends of the humerus, either by remote or modern surgeons, *but the epiphyseal structures are small and we are*

2. Hutchinson, J.: Injuries to the Epiphyses, Med. Press & Circ. **40**:461, 1885.

3. No mention is made of ages at which ossification occurs.

4. Poland, John: Diagnosis of Traumatic Separation of the Epiphysis, Pediatrics **4**:49-60, 1897.

5. Tubby, A. H.: Guy's Hosp. Rep. **31**:267-307, 1889.

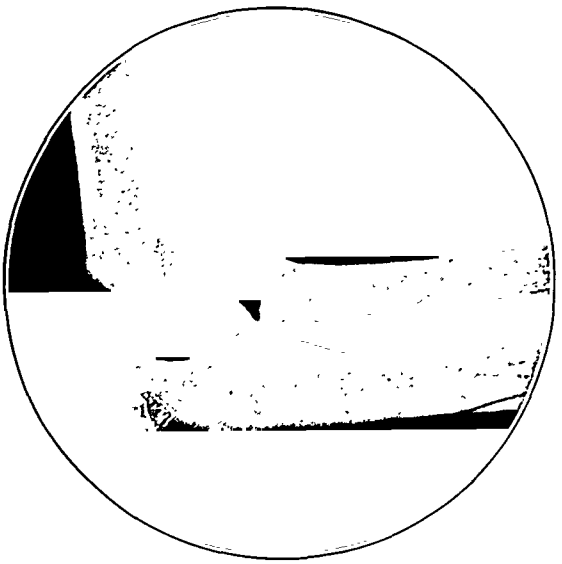

Fig. 1.—Age, 17 months.

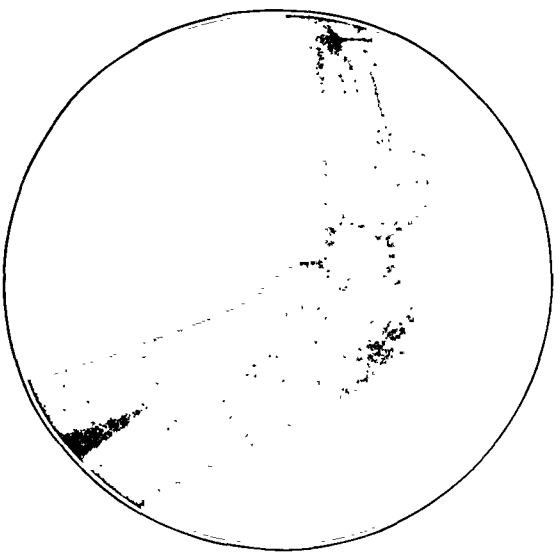

Fig. 2.—Age, 5 years.

Fig. 3.—Age, 5 years.



Fig. 4.—Age, 5 years.

ever conscious of the fact that nowadays most surgeons are looking for larger game," said Lucid [6] in 1899.

He added: "Ossification begins in the radial portion of the articular surface at the end of the second year; in the trochlear portion at the twelfth year, the internal condyle at the fifth year, and the external epicondyle at the fourteenth year. At the sixteenth and seventeenth years of life all of the centers are joined to each other and to the shaft, except the inner epicondyle, which does not unite with the shaft until the eighteenth year."

Fowler,[7] writing on the "Separation of the Epiphysis of the Lower Extremity of the Humerus," in 1899, under the heading of anatomy said: "The lower epiphysis of the humerus includes both epicondyles, the epiphyseal line being fairly straight and crossing the bone just above the two epicondyles. Directly over it lies the olecranon fossa. *The epiphysis has, at first, five separate centers of ossification.* These are subsequently reduced to three. The *ossification* in the *capitellum* is *said* to begin *during the third year."*

Hutchinson has found it at eighteen months and Farabeuf [8] says that "it usually occurs during the second year." The width of the epiphyses increases during the first few years. The depth increases slightly. The nucleus over the internal epicondyle appears at the fifth year. The third nucleus over the trochlear appears in the eleventh or twelfth year. A small separate nucleus appears over the external epicondyle. Fusion with the shaft is completed in the sixteenth or seventeenth year."

The epiphysis grows relatively smaller as the individual advances in years.

Modern anatomies and textbooks on surgery in general pay scant attention to this subject, as will be noted from the following:

The lower end of the humerus develops in the following manner: At the end of the second year ossification commences in the radial portion of the articular surface (capitellum) and from this point extends inward, so as to form the chief part of the articular end of the bone. The center for the inner part of the articular surface does not appear until about the age of 12. Ossification commences in the internal condyle at about the fifth year and in the external one not until the thirteenth or fourteenth year. At about 16 or 17 years, the

6. Lucid: Epiphyseal Separations of the Ends of the Humerus. New York M. J. **70**:406-409, 1899.

7. Fowler, R. S.: Brooklyn M. J. **13**:209 (April) 1899.

8. Farabeuf: Sur l'epiphyse inférieure de l'humérus et son décollement traumatique. Bull. et mém. Soc. de chir. de Par. **12**:692, 1886.

Fig. 5.—Age, 5 years.

Fig. 6.—Age, 6 years.

Fig. 7.—Age, 6 years.



Fig. 8.—Age, 6 years.

external condyle and both portions of the articular surfaces having already joined, unite with the shaft. At the eighteenth year the internal condyle becomes joined to the shaft.

The centers in the lower end of the humerus appear thus according to various authors: in the radial portion of the articular surface (capitellum), at the end of the second year (Knox); end of the second and third year (Cunningham); end of the second year (Gray): center for mesial half of trochlear at the twelfth year (Knox); eleventh to twelfth year (Cunningham); twelfth year (Gray). Internal condyle: fifth year (Knox); fifth year (Cunningham); fifth year (Gray). External condyle: thirteenth or fourteenth year (Knox); twelfth year (Cunningham); thirteenth to sixteenth year (Gray).

The external condyle and both articular surfaces unite between the sixteenth and seventeenth year (Gray); sixteenth and seventeenth (Cunningham); sixteenth and seventeenth year (Knox).

TABLE 1.—TIME OF APPEARANCE OF CENTERS IN THE LOWER END OF THE HUMERUS, ACCORDING TO VARIOUS AUTHORS

Author	Capitellum	Internal Epicondyle	Trochlea	External Epicondyle	Complete Ossification
Lucid (1899)	End of 2d year	5th	12th	14th year	16th to 17th year
Gray	End of 2d year	5th	12th	13th to 16th	
Knox	End of 2d year	5th	11th to 12th	13th	15th
Cunningham	End of 2d year	....	12th	12th	16th to 17th
Cotton	1½ years	5th	....	12th to 14th years	
Scudder	Generalities	Only	....	....	17th
Roberts and Kelly	1st year	10th to 12th	10th to 12th	10th to 12th	20th to 22d
Stimson	1st and 2d	....	Generalities		
Ashhurst	1st ½ year	6th year	11th	12th not constant	15 years

The internal condyle unites with the epiphysis at about the eighteenth year (Knox); from the eighteenth to the nineteenth year (Cunningham); eighteenth year (Gray). The epiphysis unites with the shaft about the fifteenth year or before the outer condyle unites with the articular surfaces (Knox); from the sixteenth to the seventeenth year (Cunningham); about the fifteenth year, or the same as Knox.

Cotton, writing on joint fractures and dislocations in 1910 under the title, "Anatomy of the Epiphysis" states: "At birth, and up to 2 or 3 years of age, the whole lower end of the humerus is a cartilaginous mass in which an ossification center appears at the outer side at about one and a half years of age.

"By 4 or 5 years of age the external condyle has become a definite structure and a cleavage line occurs in the cartilage that has been formed. The internal epicondyle shows a bone center at about 5 years and at

Fig. 9.—Age, 7 years.

Fig. 10.—Age, 8 years.

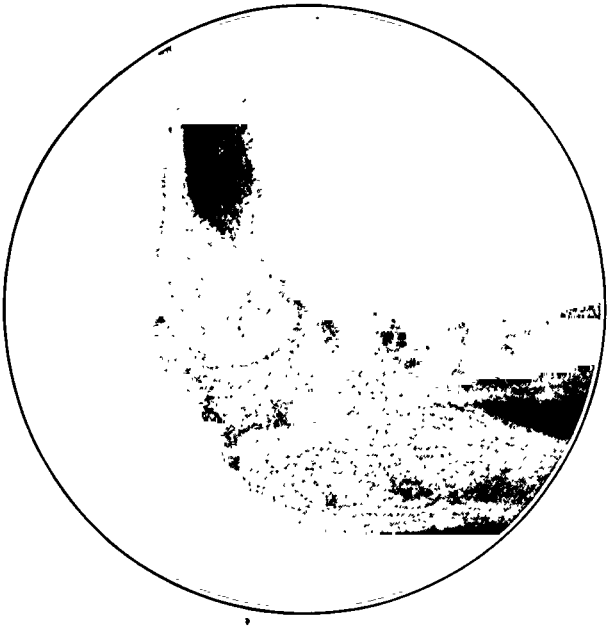

Fig. 11.—Age, 8 years.

Fig. 12.—Age, 9 years.

about 10 or 12 years it has been separated from the rest of the epiphysis by growth of the shaft downward into the epiphysis, leaving only a shell of epiphysis over the trochlear surface, with a small ossification center. From this time onward, growth occurs by progressive ossification of the external condyle and by growth of the diaphysis downward.

"The external condyle unites to the shaft usually between 16 and 19 years of age, but may persist longer.

"There is an ossification center of the external epicondyle appearing at 12 to 14 years fusing, as a rule, with the external condyle by the sixteenth year. This is never more than a scale and is surgically unimportant.

"Growth of the trochlear is by growth of the shaft down into the epiphysis, and the lower end of the ossified shaft becomes very oblique as time goes on.

"The last epiphysis to unite is that of the internal epicondyle. It may join as early as the sixteenth to eighteenth year, but often there is delay, and according to Ramband and Renault it may remain as an epiphysis through life."

Scudder says: "The lower epiphysis of the humerus unites to the shaft about the seventeenth year. The lower epiphysis of the humerus is made up of the external epicondyle, the capitellum and trochlear. These separate centers of ossification unite about the thirteenth year, and about the seventeenth year they join the shaft of the bone. The internal epicondyle is entirely separate from the large, general, lower humeral epiphysis."

Roberts and Kelly say: "The humerus is developed from a center of ossification for the diaphysis, which appears during the eighth week of fetal life, and six or seven secondary centers for the extremities which appear after birth, the epiphysis being cartilaginous. During the first year, the capitellum (of the lower extremity) appears. The trochlea, external and internal epicondyles appear between the tenth and twelfth years. Complete ossification and disappearance of the synchondrosis from the twentieth to twenty-second year."

Stimson says: "During the first or second year a center of ossification appears in the capitellum. Between the eighth and twelfth year this nodule enlarges, nearly or quite reaching the trochlear groove, a nodule appearing in each epicondyle, and the diaphysis sends a prolongation down into the inner portion of the trochlea.

"Between the twelfth and fifteenth years the nodule of the capitellum unites with that of its epicondyle, and after that the final point of ossification with that of the trochlea appears.

"The trochlea unites with the capitellum about the fifteenth year. Soon after there is union with the shaft."



Fig. 13.—Age, 9 years.

Fig. 14.—Age, 9 years.

Fig. 15.—Age, 10 years.

Fig. 16.—Age, 10 years.

Ashhurst[9] states: "The epiphyseal centers around the elbow appear in the following order: (1) capitellum of humerus in the first half year of life; (2) head of radius during the sixth year; (3) epitrochlea, or internal epicondyle, about sixth year of life; (4) trochlea during the eleventh year; (5) olecranon later in the eleventh year, and (6) epicondyle in the twelfth year. This center frequently cannot be detected.

II. OBSERVATIONS

It is manifestly impossible to interpret roentgenograms of joints in the young unless we have a standard for comparison. In the Surgeon-General's Index Catalogue, there is not a single work in English on the development of the epiphyses.

Many have probably made the same errors as we have, interpreting as fracture lines, and epiphyseal separations, normally developing epiphyses.

It might be said, and probably wisely, that such an error could not have crept in if the normal joint had been taken for the purpose of comparison. Such a procedure is advisable and necessary if no standard for comparison is available.

With a view to obtaining roentgenographic information relative to the developing elbow, we have had a series of roentgenograms of normal elbows taken. The ages of the subjects ranged from 6 months to 18 years.

The information obtained from the reading of these roentgenograms forms the basis of this paper.

Since the epiphyses develop through cartilage and since cartilage does not leave a shadow on the roentgenogram, the epiphyses are not apparent roentgenographically until some ossification has taken place.

The lower end of the humerus develops through four centers, one for the capitellum, for the internal epicondyle, the trochlear and the external epicondyle. The time of appearance of these epiphyses roentgenographically varies. The factors which influence this are probably environment, diet, and state of health. This problem is to be worked up at a later date.

The first epiphysis to appear roentgenographically is the capitellum The earliest record of its appearance is at 17 months. Up to the age of 5 years the capitellum is the only epiphysis which is evident roentgenographically. At some time during the fifth year the epiphysis in the head of the radius may appear. This is not constant, as during the sixth year of life the shadow for this epiphysis is often absent. During the seventh year, the epiphysis for the head of the radius is constantly found.

---

9. Ashhurst, A. P. C.: Fractures of the Elbow, Philadelphia, Lea and Febiger, p. 30.

Fig. 17.—Age, 11 years.

Fig. 18.—Age, 11 years.



Fig. 19.—Age, 11 years.

Fig. 20.—Age, 11 years.

The internal epicondyle appears in some instances at this age, but it is not constant. Here we notice a marked contrast between our findings and the statements in several well known textbooks. Reference to the portion of the paper in which we reviewed the literature will show that the time of appearance of the internal epicondyle is given as 5 years of age. We have not found it prior to 7 years of age. It is a curious fact that so many authors have accepted and apparently incorporated the errors of others in their own writings. Not *only is the internal epicondyle not constantly found at 7, when we first find it, but it is not always evident during the eighth, ninth, and tenth years.*

An appreciation of the relationship of the internal epicondyle to the shaft will be helpful in making the diagnosis of epiphyseal separation. The internal epicondyle appears close to, and almost continuous with, the internal oblique line of the shaft of the humerus: as the condyle develops it increases in size from above downward (Figs. 10 and 12).

TABLE 2.—TIME OF APPEARANCE OF CENTERS OF OSSIFICATION IN EPIPHYSES OF LOWER END OF HUMERUS ACCORDING TO THESE OBSERVATIONS

Age	Capitellum	Internal Epicondyle	Trochlea	External Epicondyle	Ossification	Head of Radius	Olecranon
	17 months 5 years						
6 years	Yes	0	0	0	0	½ circumference	0
7 years	Yes	20125–20121 Yes	0	0	0	Yes	0
8 years	Yes	Yes (not constant)	Yes (not constant)	0	0	Yes	Yes (not constant)
9 years	Yes	Yes (not constant)	Yes (not constant)	0	0	Yes	Yes
10 years	....	Yes (not constant)	Yes (not constant)	0	0	....	Yes
11½ years	Yes*	Yes	Yes	0	0	Yes	Yes
12 years	Yes*	Yes	Yes	0	Yes in one instance	Yes	Yes

* United with trochlea in some instances.

At 8 years of age we have noted a beginning olecranon and trochlea. These epiphyses are not constant at this time. Textbooks (Gray, Knox, Cunningham, Roberts and Kelly, Scudder and Ashhurst) give the time of appearance of the trochlea as the tenth to twelfth year. Reference to Figures 10, 11 (8 years) and 12 (9 years) demonstrates the early shadows of an ossifying trochlea. During the tenth year the trochlea develops to a considerable extent (Figs. 15 and 16). We are therefore forced to conclude that the trochlea does appear as early as the eighth year and is constantly found by the tenth year except in cases of underdevelopment.

The capitellum which is the first to appear develops from within outward, and by the tenth year occupies the base of the shaft of the humerus from the middle of the olecranon fossa outward.

Fig. 21.—Age, 11½ years.

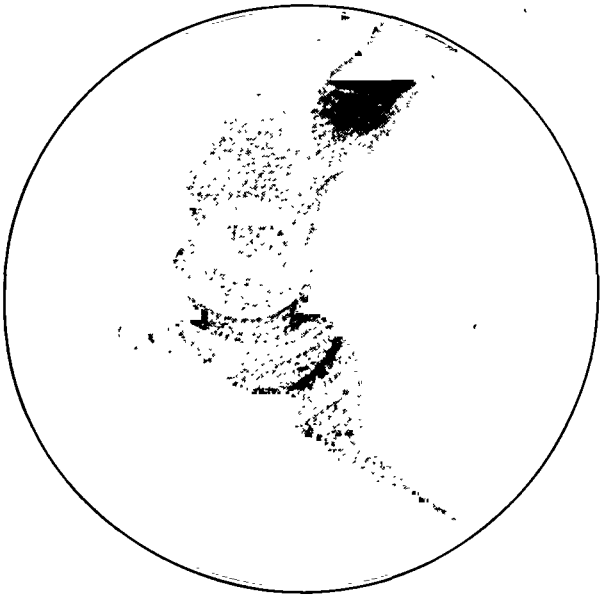

Fig. 22.—Age, 12 years.

Fig. 23.—Age, 12 years.

Fig. 24.—Age, 12 years.

During the eleventh year of life we have noted frequently a union between the capitellum and the trochlea, but no ossification of the epiphyses and the diaphysis. This is not, however, a constant finding, as we find the trochlea and capitellum still ununited in some instances at 12 and 13 years.

During the twelfth year of life the capitellum and trochlear have, in some instances, not only completely developed, but the epiphyseal line between them has become obliterated.

The olecranon and trochlea are the most variable epiphyses at this age. The trochlea is represented in some persons by a small shadow; in others, it has, as previously stated, become united to the shaft.

The olecranon epiphysis appears as early as the eighth year, in some instances as a small elliptical mass widely separated from the ulna. This finding is rare. Occasionally this epiphysis is manifest at 9 years.

During the tenth year, there are at times two distinct shadows in the region of the olecranon epiphysis. By this time this epiphysis is constantly found.

The two shadows for the developing olecranon suggest either an irregular ossification within one epiphysis, or two separate epiphyses, one for the tip and one for the posterior portion of the olecranon. The olecranon is constantly evident and well developed during the eleventh and twelfth years.

At this time, there is some union between the epiphysis and the shaft; the ossification between the two takes place from before backward.

The thirteenth year finds the capitellum and trochlea in most instances completely developed and united; but there is a line separating the united epiphyses from the diaphysis. In some instances, this union has occurred.

The internal epicondyle has not united to the shaft at 13; but the olecranon has become united by one-half its length to the shaft of the ulna.

The well developed head of the radius is also still separated by a line from its shaft. At 14 years of age, we find complete development and union of the epiphyses to their respective shafts, except the internal epicondyle. In one instance, we have noted that this has also occurred.

During the fifteenth, sixteenth and seventeenth years, this condition is noted, the internal condyle alone remaining ununited at 17 years.

Here again we note discrepancies in the literature. Various texts estimate the period of complete ossification as being from 15 to 22 years of age. One American textbook says ossification occurs between the period of 20 and 22 years. All of the texts refer to the external

Fig. 25.—Age, 12 years.

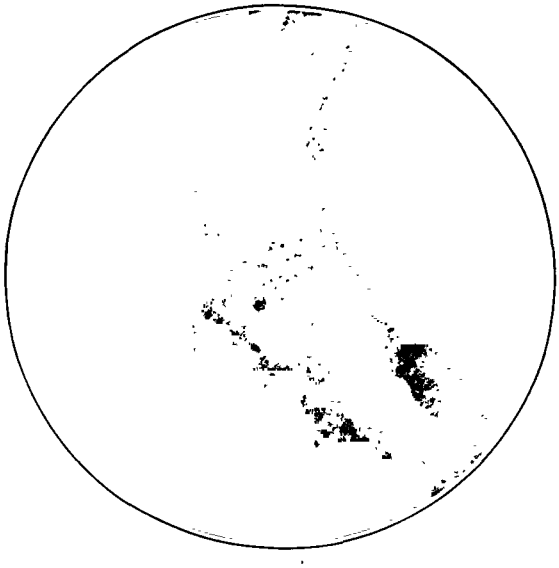

Fig. 26.—Age, 12 years.

Fig. 27.—Age, 12 years.



Fig. 28.—Age, 12 years.

epicondyle as appearing between the twelfth and sixteenth years. Our observations have led us to believe that it is not constant as a separate epiphysis. Its presence is the exception rather than the rule.

III. INTERPRETATION OF ROENTGENOGRAMS OF ELBOWS AT VARIOUS AGES

The first epiphysis to appear is the capitellum.

At Seventeen Months.—A small shadow is present below the shaft. The shadow is located in the plane of the anterior border of the shaft.

At Five Years.—The capitellum is still the only epiphysis which leaves a shadow. The position is slightly posterior to the plane of the anterior border of the shaft.

The plane of the axis of the capitellum intersects that of the shaft at an angle of approximately 60 degrees The anterior border of the capitellum is more closely approximated to the shaft than is the posterior border.

The capitellum roughly measures ½ cm. by ½ cm. (Figs. 2 and 3).

In Figures 4 and 5, the capitellum is nearly 1 cm. by ¾ cm. The epiphysis for the head of the radius is evident, occupying about one-half the circumference of the proximal end of the radius.

At Six Years.—In Figure 6, the capitellum alone is present (measuring not more than ½ cm. by ½ cm.), corresponding in development to that shown in Figures 2 and 3, of a 5 year old patient.

The capitellum (measuring 1½ by 1½ cm.) is closely approximated to the shaft. The head of the radius is one-half the size of the circumference of the shaft (Figs. 7 and 8).

At Seven Years.—The capitellum measures 1½ cm. by 1 cm. and is above the olecranon fossa (Fig. 9).

The internal epicondyle appears as a small round shadow below and internal to the shaft. The head of the radius is one-half the size of the circumference of the shaft.

At Eight Years.—These centers are present: the capitellum, internal epicondyle, trochlea, olecranon, and head of the radius.

The capitellum measures 1½ cm. by 1 cm. It extends outward, so that its external margin is practically continuous with the external oblique line of the broad lower end of the shaft of the humerus. The internal epicondyle is about ½ cm. by ¾ cm. and is separated by a rather marked clear space from the internal oblique line of the shaft of the humerus. The trochlea is represented by a tiny shadow internal to the capitellum and separated from it by about ½ cm. The olecranon is represented by a similar small shadow. The epiphysis of the head of the radius occupies about three fourths of the circumference of the upper end of the shaft of the radius (Fig. 10).



Fig. 29.—Age, 12 years.

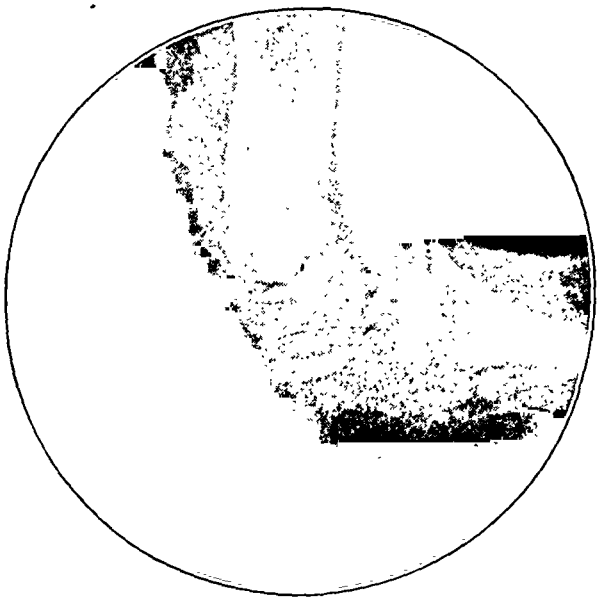

Fig. 30.—Age, 13 years.

Fig. 31.—Age, 13 years.

Fig. 32.—Age, 13 years.

In Figure 11, the appearance is practically that of the preceding picture with the exception of the fact that there is no shadow for the olecranon.

In one instance, there was no shadow for the olecranon, nor for the trochlea. The capitellum has not extended so far out as in the previously described roentgenograms. There is no evidence of an internal epicondyle nor trochlear process. The diaphysis has extended downward, particularly on the inner side.

In another patient of the same age, there is no center for the olecranon nor trochlea. The lower end of the diaphysis of the humerus shows the same tendency to broaden out and extend downward on the inner aspect. There is no internal epicondyle.

At 8 years of age, we have in some instances only one epiphysis sufficiently ossified to manifest itself, that being the capitellum. The other extreme noted for the same age shows well developed capitellum, internal epicondyle, head of the radius, and small shadows of early ossifying trochlea and olecranon (Fig. 10).

At Nine Years.—In Figures 12 and 13, the internal epicondyle is present, the dimensions being ½ cm. by 1 cm. Its upper limit is practically on a level with the oblique line of the shaft. The capitellum measures 2 cm. by 1 cm. in its greatest long axes. Its growth is more marked to the radial side. The trochlea is represented by two shadows ¾ cm. by ½ cm. There is no evidence of an olecranon epiphysis. The epiphysis of the head of the radius occupies almost the entire circumference of the upper end of the shaft. The epiphysis for the head of the radius seems divided as though there were a loss in continuity. Probably this is indicative of an irregular ossification going on in this epiphysis. The capitellum extends fully ½ cm. anterior to the plane of the long axis of the shaft of the humerus.

At Nine Years.—In Figure 14, the internal epicondyle is present, the capitellum developing as in previous descriptions. The epiphysis of the olecranon is evident as a small elliptical shadow. The head of the radius is as usual. Two small shadows suggestive of beginning trochlear process are visible.

A shadow of the olecranon epiphysis is not present in some cases at 9 years, in others it has ossified sufficiently to leave a shadow ¼ cm. in diameter. The trochlea in some is not present, in others there are two shadows present, ¾ cm. by ½ cm.

At Ten Years.—There is no evidence of an internal epicondyle, no evidence of a trochlea, and no evidence of an olecranon in some cases at this age.

In others at 9 years, the capitellum is well developed, occupying that portion of the lower end of shaft from the middle of the olecranon fossa outward (Figs. 15 and 16). There is a distinct epiphysis for the external condyle. The trochlea has developed inward, but has not yet

Fig. 33.—Age, 13 years.

Fig. 34.—Age, 13 years.



Fig. 35.—Age, 13 years.

Fig. 36.—Age 13 years.

united with the capitellum. The internal epicondyle occupies the space between the trochlea. There is no union between the epiphyses and the shaft. The olecranon epiphysis is separated by a wide margin from the shaft of the ulna.

At Eleven Years.—Almost complete ossification of the capitellum and trochlea is shown in Figures 17 and 18.

Union has taken place between the two epiphyses; but they have not become united to the shaft. The internal epicondyle has not united to the shaft. There is no evidence of an external epicondyle.

There are two distinct shadows in the portion of the olecranon epiphysis, suggesting either two separate epiphyses or separate centers of ossification within one epiphysis. The head of the radius still presents the epiphyseal line of separation from the shaft. Figures 19 and 20 present a similar picture with the exception of a more marked development of the olecranon.

At Twelve Years.—Complete ossification and union of the capitellum and trochlea have taken place; a persistent epiphyseal line between the shaft and the united epiphyses may be noted (Figs. 22 and 23).

There is a persistent epiphyseal line between the internal epicondyle and the shaft. There is no evidence of an external epicondylar epiphysis. The olecranon is completely ossified, but persists in having an epiphyseal line. The head of the radius has not become united to the shaft.

Figures 24 and 25 differ from the preceding in that the olecranon is less well developed.

The internal epicondyle is about ¾ by ½ cm.; the capitellum and trochlea have united and occupy practically the entire lower aspect of the shaft. The head of the radius occupies the entire circumference of the upper end of the shaft. The olecranon seems to be made up of two portions, which are approximated from tip backward, more closely in front.

Varying Appearance at Twelve Years.—The olecranon shadow is absent in one (Fig. 27); a small shadow in one (¼ cm.), in another ¾ cm.; almost completely ossified in another. The ossification is more complete near the anterior portion of tip; there is still some separation posteriorly.

The capitellum continues to increase in size; and in some instances there is ossification to the trochlea and to the shaft.

The epiphyseal line is almost entirely obliterated in one instance (Fig. 29).

The trochlea shows a variable stage of development from a small shadow to a completely developed epiphysis, first becoming ossified to the capitellum and later to the shaft.



Fig. 35.—Age, 13 years.



Fig. 36.—Age 13 years.

united with the capitellum. The internal epicondyle occupies the space between the trochlea. There is no union between the epiphyses and the shaft. The olecranon epiphysis is separated by a wide margin from the shaft of the ulna.

At Eleven Years.—Almost complete ossification of the capitellum and trochlea is shown in Figures 17 and 18.

Union has taken place between the two epiphyses; but they have not become united to the shaft. The internal epicondyle has not united to the shaft. There is no evidence of an external epicondyle.

There are two distinct shadows in the portion of the olecranon epiphysis, suggesting either two separate epiphyses or separate centers of ossification within one epiphysis. The head of the radius still presents the epiphyseal line of separation from the shaft. Figures 19 and 20 present a similar picture with the exception of a more marked development of the olecranon.

At Twelve Years.—Complete ossification and union of the capitellum and trochlea have taken place; a persistent epiphyseal line between the shaft and the united epiphyses may be noted (Figs. 22 and 23).

There is a persistent epiphyseal line between the internal epicondyle and the shaft. There is no evidence of an external epicondylar epiphysis. The olecranon is completely ossified, but persists in having an epiphyseal line. The head of the radius has not become united to the shaft.

Figures 24 and 25 differ from the preceding in that the olecranon is less well developed.

The internal epicondyle is about ¾ by ½ cm.; the capitellum and trochlea have united and occupy practically the entire lower aspect of the shaft. The head of the radius occupies the entire circumference of the upper end of the shaft. The olecranon seems to be made up of two portions, which are approximated from tip backward, more closely in front.

Varying Appearance at Twelve Years.—The olecranon shadow is absent in one (Fig. 27); a small shadow in one (¼ cm.), in another ¾ cm.; almost completely ossified in another. The ossification is more complete near the anterior portion of tip; there is still some separation posteriorly.

The capitellum continues to increase in size; and in some instances there is ossification to the trochlea and to the shaft.

The epiphyseal line is almost entirely obliterated in one instance (Fig. 29).

The trochlea shows a variable stage of development from a small shadow to a completely developed epiphysis, first becoming ossified to the capitellum and later to the shaft.

Fig. 37.—Age, 13 years.

Fig. 38.—Age, 13 years.

Fig. 39.—Age, 14 years.

Fig. 40.—Age, 14 years.

The internal epicondyle is constantly present; in one instance, the epiphyseal line is completely obliterated (Fig. 26).

The capitellum (2½ by 1 cm.) extends from the middle of the olecranon fossa outward. The internal epicondyle is increasing in size.

The trochlea is represented by large nodules, not yet united to the capitellum.

There is no evidence of an external epicondyle, and no evidence of an olecranon. The head of the radius covers the entire circumference of the upper end of the shaft. Figure 28 corresponds almost entirely to Figure 27, except that the olecranon nodule is present, but small. There is no evidence of ossification of the epiphyseal centers to one another, nor union of centers to the shaft.

At Thirteen Years.—The capitellum extends from the middle olecranon fossa to the level of the outer border of the oblique line of the lower end of the humerus, 2½ by 1 cm. The epiphyseal line is still well marked (Fig. 30).

The trochlear nodule is larger than in previous years; but there is no union with the capitellum. There is still an epiphyseal line between the internal epicondyle and the shaft. The olecranon nodule is smaller than in some roentgenograms of previous years. The head of the radius occupies the entire upper end of the shaft of the radius; there is no union.

There is union of the trochlea and capitellum (Fig. 32). There is no evidence of the epiphyseal line between the shaft and the united capitellum and trochlea. The epiphyseal line between the internal epicondyle and the shaft is still present.

There is a shadow which is evidently developing upward from the capitellum in the direction of the external epicondyle, suggesting that the external epicondyle may be an outgrowth from the capitellum in some instances.

The olecranon epiphysis is almost completely ossified and is united for one half of its length to the ulna. Union is taking place from before backward.

Figure 33 is practically identical to Figure 32, except that the line between the shaft and the united lower epiphysis seems to have been obliterated.

In Figure 35, there is ossification and union of the capitellum and trochlea, but a persistent epiphyseal line separating the epiphyses and the shaft. The internal epicondyle persists in having an epiphyseal line separating it from the shaft.

The olecranon and head of the radius are still separate from their respective shafts.



Fig. 41.—Age, 14 years.

Fig. 42.—Age, 14 years.

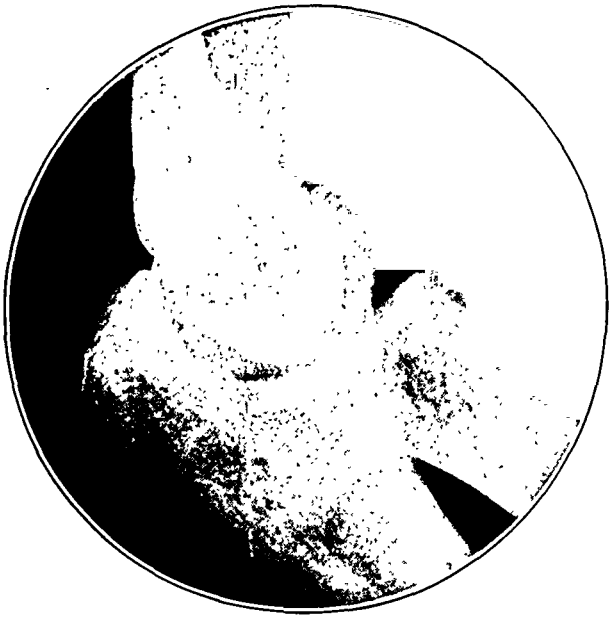

Fig. 43.—Age, 15 years.



Fig. 44.—Age, 15 years.

Figures 37 and 38 show distinctly less development of all of the epiphyses.

At Fourteen Years.—Figures 39 and 40 show complete ossification of all the epiphyses and union of all with the shaft except the internal epicondyle. Figure 41 is the same as Figures 39 and 40 except that there is union of the internal epicondyle to the shaft (Figs. 41 and 42).

At Fifteen Years.—There is complete ossification and union of the epiphyses with the shaft (Figs. 43 and 44).

Figures 45 and 46 show a persistence of all epiphyseal lines. There is a well marked epiphysis for the external epicondyle.

At Seventeen Years.—There is complete ossification and union of all the centers to the shaft (Figs. 47 and 48).

SUMMARY

1. The value of the proper knowledge of the roentgenographic appearance of the normally developing elbow can hardly be overestimated.

2. Many cases have been misinterpreted as fractures of one condyle or another, *which probably should have been interpreted as normal joints.*

3. Emphasis should be laid on the proper position for taking pictures of the developing joints. It seems that the anteroposterior view of the elbow in complete extension, with the forearm in complete supination, gives the best opportunity for observing the normal relationship of the developing epiphyses.

The literature on the subject gives misleading ideas of the time at which the epiphyses unite. Certainly there is no agreement among the authorities as to the period at which union occurs.

We have noted roentgenographically four centers of ossification for the epiphysis of the lower end of the humerus; the capitellum, internal epicondyle, trochlea, and occasionally the external epicondyle as a separate center. The first to appear is the capitellum; this is the only epiphysis present up to 5 years. The internal epicondyle appears next. It is important to note that the internal condyle appears close to and is continuous with the *internal oblique line of the shaft of the humerus.*

At the age of 14 years, we have found complete union of the epiphyses and the shaft with the exception of the internal epicondyle; this may remain ununited at 17 years of age.

The developing capitellum occupies a relatively constant position. This position can be determined best by passing a plane through the middle of the long axis of the shaft of the humerus.



Fig. 45.—Age, 15 years.

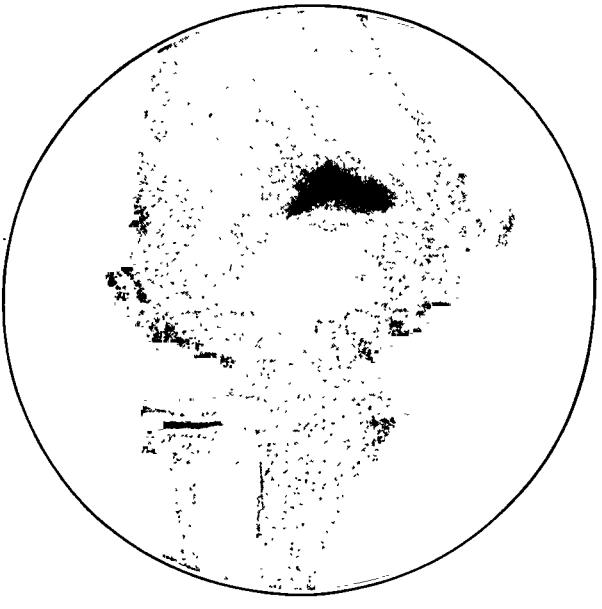

Fig. 46.—Age, 15 years.

Fig. 47.—Age, 17 years.

Fig. 48.—Age, 17 years.

This plane is intersected at an obtuse angle by a plane bisecting the developing capitellum (Figs. 4 and 5). The plane which bisects the shaft of the humerus is posterior to the posterior limit of the capitellum.

The diagnostic value of these intersecting lines will be fully detailed in a subsequent paper to be based on injuries about the elbow.[10]

1211 Maison Blanche Building.

---

10. In addition to the references already given, the following will be found of interest:

Windle: United Epiphysis, Proc. Anat. Soc. Great Britain & Ireland, 1889.

MacDougall: A Note in Connection with Injuries to the Epiphysis, Edinburgh M. J. **36**:825-830, 1890-1891.

Draver, H. C.: Epiphyseal Separation of the Humerus, Univ. Mag. **9**: 118-203, 1896-1897.

Eccles: Traumatic Separations of the Lower Epiphysis of the Humerus with Displacement Forward, Lancet **2**:688, 1898.

Hamilton, F. H.: A Practical Treatise on Fractures and Dislocations, Philadelphia, 1890, p. 191.

THE HISTOGENESIS OF MALIGNANT TUMORS OF THE TESTICLE*

OSCAR T. SCHULTZ, M.D.

AND

DANIEL N. EISENDRATH, M.D.

CHICAGO

Tumors of the testicle constitute one of the most confused and confusing subjects in the field of pathology. A wide variety of terms made their way into the earlier literature; these in turn became incorporated into complicated classifications in the textbooks on surgery. During more recent years, these tumors have formed the basis of a number of careful reports, through which the classification, based on histogenesis, should become simplified. Unfortunately, there is still some difference of opinion as to the origin of several testicular tumors which show undoubted histologic differences. Ewing,[1] in 1911, made a painstaking analysis of the previously reported cases, from which and from the study of nineteen cases of his own, he reached conclusions which, if they could be fully accepted, would greatly simplify matters. He believed that pure tumors of mesoblastic origin, such as fibroma, chondroma, myxoma, myoma and lipoma, are extremely rare and that most of such benign tumors have been derived from teratomas. What is of greater importance, he held that the malignant tumors are likewise teratomatous in origin and are the result of the onesided development and overgrowth of atypical epithelial tissue. Even if one is unwilling to accept in its entirety Ewing's view that all testicular tumors are teratomatous in origin, it is unfortunate that his article is not more widely known, because there would then be fewer reports of sarcoma of the testicle, undoubtedly one of the rarest of the tumors of this organ; and there would be less confusion and better mutual understanding when the surgeon, who thinks of sarcoma as the most frequent type of tumor, receives from the pathologist a diagnosis of carcinoma or embryonal carcinoma. Of Ewing's nineteen tumors, the last is termed an "example of genuine primary lymphosarcoma of the testis." No proof of the teratomatous origin is given except that the tumor arose in the rete, the point of origin of teratoma; perhaps the conclu-

*From the Nelson Morris Memorial Institute for Medical Research and the Surgical Service of the Michael Reese Hospital.

1. Ewing, James: Teratoma Testis and Its Derivatives, Surg., Gynec. & Obst. **12**:230 (March) 1911.

sion reached from the study of the whole group, that all testis tumors originate in teratomas, has influenced the decision to include this tumor among those of teratomatous origin. Six are carcinomas with lymphoid stroma and without other heterologous elements.

In the literature since the appearance of Ewing's article there have been reports of sarcoma by Fata,[2] Stokes,[3] Codman and Sheldon,[4] Leuzzi,[5] Petit de la Villéon,[6] Smith,[7] Lister,[8] Grant,[9] Aguirre,[10] Fansler;[11] of perithelioma by Nizzi [12] and by Brandeis;[13] of hypernephroma by Thompson;[14] of fibroma by Lardennois and Lecène,[15] by Makins,[16] and by Boyer,[17] and of fibrolipoma by Baldwin.[18] In most of these, the microscopic description is too incomplete to permit critical study, but all are probably epithelial tumors except the fibromas and the fibrolipoma. The reported fibromas are apparently pure tumors derived from the tunic of the testis. The 23½ pound fibrolipoma reported by Baldwin was probably teratomatous in origin.

---

2. Fata, M.: Considerazioni sopra un interessante caso di sarcoma del testicolo in un bambino di sei anni, Riv. di sc. med. **56**:547, 1912; ibid. **57**:14, 1912.

3. Stokes, A. C.: Sarcoma of the Testicle, with Report of a Case, New York M. J. **95**:438, 1912.

4. Codman, E. A., and Sheldon, R. F.: The Prognosis of Sarcoma of the Testicle, Boston M. & S. J. **170**:267, 1914.

5. Leuzzi, F.: Enorme sarcoma del testicolo destro, Gior. internaz. d. sc. med. **36**:693, 1914.

6. Petit de la Villéon, E.: Volumineux sarcome du testicule chez un enfant de vingt cinq mois, J. de méd. de Bordeaux **43**:781, 1913.

7. Smith, O. C.: Bilateral Sarcoma of Undescended Testes, Boston M. & S. J. **170**:839, 1914.

8. Lister, C. R.: A Case of Sarcoma of the Undescended Testis, M. J. Australia **1**:31, 1915.

9. Grant, W. W.: Sarcoma of the Intra-Abdominal Testis, J. A. M. A. **67**:915 (Sept. 23) 1916.

19. Aguirre, R. T.. Globocellular Sarcoma of the Right Testicle, Surg., Gynec. & Obst. **27**:47 (July) 1918.

11. Fansler, W. A.: An Unusually Large Sarcoma of the Testicle, Am. J. Surg. **32**:10 (Jan.) 1918.

12. Nizzi, U.: Sopra un peritelioma del testicolo in un lattante, Riv. di clin. pediat. **9**:652, 1911.

13. Brandeis, R.: Tumeur du testicle d'origine périvasculaire, Gaz. hebd. d. sc. méd. de Bordeaux, **35**:65, 1914.

14. Thompson, J. E.: Hypernephroma Arising in the Right Testicle, Tr. South. Surg. & Gynec. Assn. **23**:408, 1911.

15. Lardennois, G., and Lecène, P.: Fibrome de l'albuginée, Bull. et mém. Soc. anat. de Paris **86**:712, 1911.

16. Makins, G. H.: Multiple Fibromata of the Tunica Vaginalis, Proc. Roy. Soc. Med. **5**:155, 1911-1912.

17. Boyer, E. E. H.: Fibroma of the Testicle, Ann. Surg. **70**:210 (Aug.) 1919.

18. Baldwin, A.: A Case of Fibrolipoma of Testicle, Weighing Twenty-Three and a Half Pounds, West Lond. M. J. **22**:78, 1917.

Miyata [19] studied twenty-seven tumors, for which he gives the following diagnoses: twenty-one sarcomas; one sarcoma in a mixed tumor; one carcinoma; one perithelioma and three endotheliomas. Of his sarcomas, one was a fibrosarcoma of the tunic of the epididymis,

Fig. 1.—Cut surface of part of tumor from Case 1.

one a small spindle cell sarcoma of the sheath of the spermatic cord, and one a spindle cell sarcoma of the tunic of the testis. These three

19. Miyata, T.: Zur Kentniss der Hodengeschwulste und die Bedeutung des Traumas für ihre Entstehung. Arch. f. klin. Chir. **101**:426, 1913.

may perhaps be considered homologous pure tumors, although the descriptions are very brief. The rest are probably all epithelial tumors.

In a collection of fifty-nine tumors of the undescended testicle made by Bulkley,[20] the published diagnosis was sarcoma of one form or another in all except these: teratoma, 2; epithelioma, 2; chorio-epithelioma, 2; carcinoma, 7; rhabdomyoma, 1, and cancer, 5.

In addition to these, there have been a number of reports on cases of carcinoma, chorio-epithelioma, and malignant teratoma, which are more in accord with modern ideas. Among the latter articles are several more extensive studies by authors, most of whom do not accept Ewing's theory of the teratomatous origin of all testicular tumors, although they admit the carcinomatous nature of the tumors usually described as sarcomas.

The important literature previous to 1911 has been so well summarized by Ewing [1] that the reader is referred to his article. Frank,[21] in 1911, studied fourteen examples of the large cell, medullary tumor, which is the most frequent type of testicular tumor. The tumors are cellular, with little reticulum. The cells are large, with finely granular cytoplasm and large vesicular nuclei. Frank believes these cells are derived from the germinal cells of the tubuli contorti and asserts that all transition stages from the normal to the neoplastic cells are found. He agrees, therefore, with Birch-Hirschfeld, Tizzoni, Langhans, Chevassu and those others who maintain that the tumor which occurs most frequently is derived from normal, differentiated cellular elements of the testis and not from the constituents of a teratoma. He described also a vascular tumor of the angioplastic sarcoma type, composed of cuboidal, cylindric and irregular cells, and another tumor of mixed type with glandular alveoli, sarcoma-like tissue and smooth muscle. In the latter case, he excludes mixed tumor, for what reason it is not quite clear except that it may be from his desire to derive this tumor and the preceding one from the tubuli recti. He also described a fibro-adenoma, which he compared in structure with fibro-adenoma of the mamma. This involved both testis and epididymis, and Frank believes the tumor is derived from the latter structure. He admits that there are all gradations in histologic structure from the large cell tumor, which he considers a homologous pure tumor of tubular epithelium, to the heterologous mixed tumors. He does not accept the view of the origin of the latter from misplaced blastomeres, but derives them from unripe germinal cells, as opposed to the large cell tumor which is

20. Bulkley, Kenneth: Malignant Disease of the Testicle Retained Within the Abdominal Cavity, Surg., Gynec. & Obst. **17**:703, 1913.

21. Frank, A.: Die histogenetische Ableitung der Hodentumoren, Frankfurt. Ztschr. f. Path. **9**:206, 1911.

derived from ripe cells. This conception explains the varied cytomorphology, but is not susceptible of actual proof. He admits also the possibility of tumors being derived from interstitial cells. According to Frank, there can occur in the testicle four types of tumor: (1) carcinoma derived from differentiated germinal cells of the tubuli contorti; (2) carcinoma derived from the cells of the tubuli recti; (3) mixed tumors, often carcinomatous, from unripe germinal cells, and (4) sarcoma from interstitial cells.

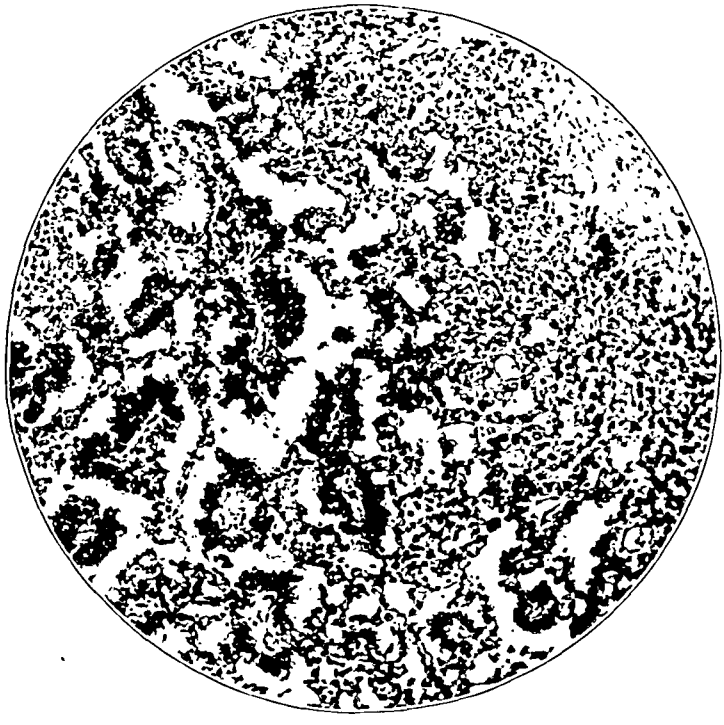

Fig. 2.—Atypical glandular and papillary tissue of tumor from Case 1. ×80.

Stoppato [22] in the same year (1911) concerned himself with tumors of supposed interstitial cell origin, of which Ewing [1] considers that only two examples have been reported, both being hyperplasias rather than neoplasms. Stoppato reports three cases. Whereas Frank holds that the heterogeneous group of alveolar sarcoma, endothelioma, angiosarcoma, etc., are really carcinomas of germinal cell origin, Stoppato concludes that most of the tumors of this group are interstitial cell tumors. The cells of his tumors he describes as being large, epithelial-like, loosely

22. Stoppato, U.: Ueber Zwischenzellentumoren des Hodens, Ziegler's Beitr. z. path. Anat. **50**:113, 1911.

arranged without intercellular substance, forming indistinct cords or solid cell masses. In one of his illustrations, the tumor has a distinctly alveolar character. There can be little doubt that Stoppato's interstitial cell tumors belong to the same group as Frank's germinal epithelial tumors, but derivation of the former from interstitial cells has not been rendered very probable.

Vecchi [23] (1912) studied more especially the mixed tumors of the testis, which he divides into three groups: (1) teratoma or embryoma of Wilms, organoid, usually cystic, relatively benign; (2) teratoid or embryoid tumors of Wilms, solid, often with small cysts, less completely differentiated than the first group. The relation of the structural elements to one another deviates to a greater degree from the normal than is the case in tumors of the first group; (3) mixed tumors derived from the mesoderm of the host, solid, no derivatives of ectoderm or entoderm, but mesoblastic and glandular derivatives of the mesoderm. Tumors of the last group are derived from totipotent cells of the mesoderm, i. e., from cells of the primitive urogenital anlage. They, therefore, are analogous to the congenital mixed tumors of the kidney. Tumors of the first two groups are derived from totipotent blastomeres, which have the value of ova. Of the twenty-four tumors studied, only three were considered teratomas, the rest mesoblastic mixed tumors. Vecchi admits that there are gradations, so that distinction between the three groups is not always possible. In addition to the mixed tumors, Vecchi accepts the derivation of tumors from tubular epithelium, interstitial cells, endothelium and supporting tissues.

Mori [24] (1912) studied a teratoma which contained derivatives of the three germ layers and which gave rise to chorio-epitheliomatous metastases. He concludes that the metastases are derived, not from totipotent cells, but from that element whose growth capacity has become developed to the greatest degree in the original tumor. Different teratomas, as compared with one another, may, therefore, give rise to different kinds of metastasizing tissue, but in any given tumor all the metastases will be formed by the particular tissue components of the primary tumor which have taken on malignant proliferation.

Sakaguchi's article [25] (1913) was based on the personal study of thirty-two cases, which he groups thus: one sarcoma; twenty-one typical large cell tumors; two atypical large cell tumors; seven epithelial

23. Vecchi, A.: Teratome, teratoide Geschwülste und Mischtumoren des Hodens, Deutsch. Ztschr. f. klin. Chir. **114**:104, 1912.

24. Mori, T.: Ueber ein metastasierendes Hodenteratom, *Virchows* Arch. f. path. Anat. **207**:99, 1912.

25. Sakaguchi, Y.: Zur Kenntnis der malignen Hodentumoren, vor allem der epithelialen. Deutsch. Ztschr. f. klin. Chir. **125**:294, 1913.

tumors with partly adenomatous and partly papillary proliferation, and one tumor with adenomatous areas and also solid cell nests. The sarcoma is diagnosed as a small spindle cell sarcoma. The description is meager, and it is impossible to decide whether this was a true pure sarcoma, a sarcoma derived from a mixed tumor, or perhaps an epiblastic epithelial tumor of teratomatous origin. Most interest attaches to the group of twenty-one typical and two atypical large cell tumors.

Fig. 3.—Differentiated heterologous tissue of tumor from Case 1: *A*, gland-like structures lined by cylindric epithelium; *B*, a mass of squamous epithelium. × 80.

These, as the author admits, undoubtedly belong to that most frequent type of tumor of the testis which has been the subject of so much study, the kind of tumor which formed the basis of the reports of Frank[21] and Stoppato.[22] In his review of the literature relating to this group, Sakaguchi thus summarizes the previously held views: (1) carcinoma, derived from (*a*) differentiated epithelium of convoluted tubules (Birch-Hirschfeld, Tizzoni, Langhans, Chevassu, Frank); (*b*) embryonic tubule cells (Debarnardi); (*c*) aberrant epithelial rests of testis

(Monod and Terillon); (*d*) epithelium of Pflüger's tubules of the embryo (Pilliet and Cortes): (2) sarcoma, large cell or alveolar, derived from (a) Highmore's body (Ehrendorfer); (b) interstitial cells (von Hansemann, Kaufmann, Stoppato): (3) endothelioma, derived from lymph endothelium (Krompecher, Cavazzoni); (4) onesided development of a teratoma, embryonal carcinoma (Pick, Ribbert, Ewing). Sakaguchi, as the result of his own study, decided that the tumor cells are identical with spermatogonia and that they are derived from the differentiated epithelium of the tubuli contorti. The illustration of his Case 2 is interesting in that it shows definite intracanalicular growth of the tumor within the seminal tubules. In the two atypical tumors which he asserts belong to this group, the cells were somewhat smaller, the alveolar character was less distinct, and there was a greater degree of extracanalicular growth. In the malignant epithelial tumors with partly adenomatous or papillary growth, reported by him, the chief characteristic was the formation of areas of atypical glandular structures lined by cylindric epithelium, but there were also solid areas of tissue like that characteristic of the large cell tumors. He could find no evidence of a teratomatous nature and concludes, in agreement with Frank, that these tumors are derived from straight or rete tubules.

Butt and Arkin [26] (1914) give the diagnosis of sarcocarcinoma to the bilateral tumors of the undescended testes of an adult. From the description, the tumor tissue was composed of large cells arranged in solid masses and in more or less distinct tubules. Apparently the tumors in this case were of the kind which Chevassu, Frank, Sakaguchi and others believe are derived from the seminal tubule epithelium.

Cooke [27] (1915) described a metastasizing chorio-epithelioma. There were no teratomatous elements, but the origin from teratoma is considered most probable. Forty-six additional cases of chorio-epithelioma were collected from the literature, in about half of which teratomatous elements were present.

Geist and Thalhimer [28] (1917) studied the histopathology of twenty-six tumors. They make this grouping: (1) carcinoma: (*a*) medullary (alveolar, séminome), sixteen cases; (*b*) adenomatous, four cases. (2) teratoma: (*a*) without carcinoma; (*b*) with carcinoma (adenomatous, with medullary or papillomatous areas), six cases. The medullary carcinoma they derive from the spermatogonia. In the adenocarcinoma

26. Butt, A. P., and Arkin, A.: Malignant Disease of the Retained Testicle, Surg., Gynec. & Obst. **19**:419, 1914.

27. Cooke, J. V.: Chorio-Epithelioma of the Testicle, Bull. Johns Hopkins Hosp. **26**:215, 1915.

28. Geist, S. H., and Thalhimer, W.: Histopathology of Carcinoma of the Testicle, Ann. Surg. **66**:571 (Nov.) 1917.

group, the cells lining the gland spaces are smaller than in the first group, and they are cuboidal or cylindric; in the solid areas, if any cells are present, they are also smaller than in the typical medullary carcinomas. The adenocarcinomatous tumors they believe to be derived probably from the tubuli recti. The carcinomatous teratomas are usually glandular in character; they assert that they have never found carcinomatous tissue, of a kind corresponding to that of their first group, in any tumor in which the teratomatous origin was certain.

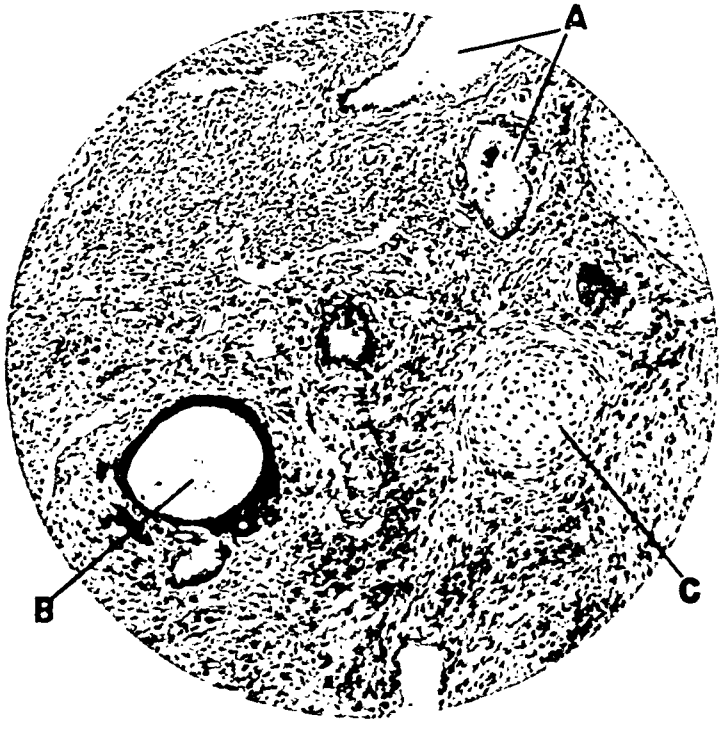

Fig. 4.—Differentiated heterologous tissue of tumor from Case 1: *A*, cystic spaces lined by cuboidal epithelium; *B*, space lined by deeply pigmented columnar epithelium; *C*, cartilage. ×80.

O'Crowley and Martland[29] (1919), as the result of the study of thirteen tumors, accept unreservedly Ewing's point of view and say that "for practical purposes there exists only one tumor of the testicle, namely, a teratoma." Of their thirteen tumors, one was a metastasizing lymphosarcoma, apparently primary in the rete or epididymis of a boy, aged 5 years, with no discoverable teratomatous elements. This

29. O'Crowley, C. R., and Martland, H. S.: New-Growths of the Testis, Surg., Gynec. & Obst. 28:486 (May) 1919.

is the same tumor concerning whose origin from a teratoma Ewing expressed some doubt. Their second case they call a "very early lymphosarcoma." This was a mass only 1 cm. in diameter in the globus major of the epididymis of a man, aged 34. The mass contained small acini lined by cuboidal and flattened epithelium; these acini were not believed to be compressed tubules. The teratomatous nature of this tumor does not appear to be well established; if the acini present are not compressed tubules, but are neoplastic structures, the reason for calling this mass a lymphosarcoma is not very clear. The question may be raised as to whether this is really a neoplasm. Of their remaining eleven tumors, the teratomatous origin is definite in five and probable in an alveolar embryonal carcinoma of an undescended testis. The rest are large cell alveolar carcinomas, with no evidence of heterologous structure except the presence of lymphoid stroma.

It is evident that there are still wide differences of opinion as to the origin and nature of tumors of the testicle. Any histogenetic classification which attempts to include these diverse views must remain as complicated and unsatisfactory as most of the textbook classifications are today. Some unification of opinion ought to be possible, even if it is impossible to accept Ewing's conception of the teratomatous origin of practically all testicular tumors. The incentive to further study of the group of malignant tumors of the testis was given by a patient, admitted to the surgical service of the Michael Reese Hospital, whose case is herewith reported.

REPORT OF CASES

CASE 1.—*History.*—A man, aged 30 years, eighteen months before admission, while lifting a heavy weight, felt something "give way" in the right inguinal region. At that time there was dull pain in the right side of the scrotum, but this disappeared. Enlargement of the right testicle was noticed shortly afterward; this had increased gradually and progressively until admission to the hospital. The increase in size was not associated with pain or tenderness.

Examination.—This revealed a tumor about the size of three adult fists. The surface was smooth; it was ovoid in shape, and there was a tense, elastic condition such as is found in hydrocele. The transillumination test was negative, but this was thought to be due to thickening of the sac. The preoperative diagnosis was hydrocele.

Operation.—An incision through the outer tunics of the mass evacuated a considerable quantity of slightly turbid fluid from the tunica vaginalis. A number of cystlike enlargements of varying size were seen on the exposed surface of the testis, and further exploration revealed similar changes over the entire organ. Orchidectomy, with regional removal of all lymph node bearing fat, was performed.

Pathologic Examination.—The gross pathologic report 20P670, Oct. 4, 1920, was: The specimen is an ovoid mass, 13 cm. long by 8 cm. in diameter, covered by a thickened fibrous tunic which is roughened in places externally by fibrous adhesions. The tumor (Fig. 1) is composed of tissue of varying appearance

and consistency, in which are smooth cystic cavities, the largest 4 cm. in diameter. Some areas are dense and fibrous, and contain small, pale, translucent islands which have the appearance of cartilage. Other poorly defined areas are soft, opaque, yellowish and necrotic; others are dark red, soft and fleshy; still others are soft, pale and gelatinous. At the lower pole the tunica is 0.6 cm. thick. The cord is apparently not involved.

On microscopic examination, marked variation in structure is detected, depending on the place from which the section comes and even in the same section. Large areas are necrotic. Other areas are composed of very dense, hyaline, fibrous tissue, which alternates with islands of soft, myxomatous stroma.



Fig. 5.—A large cyst in the tumor from Case 1 lined by cuboidal epithelium: beneath the latter is a heavy wall of smooth muscle. ×89.

Still other areas are very cellular. Some of these are solid, with no discernible arrangement of the cells. The latter are irregularly polyhedral, with large, vesicular nuclei; many are in mitosis; the cells are closely placed and no reticulum can be seen between them. In places the cells are cylindric and are arrranged regularly about small blood vessels. In still other cellular areas, cells of cuboidal or cylindric shape are arranged about lumens, forming atypical glandlike alveoli. All gradations are seen from the cylindric cells of the glandlike alveoli to the polyhedral cells of the solid areas. The perivascular arrangement of cells of the same origin is apparently due to papillary growth within cystic spaces which have become filled in by proliferating tumor tissue (Fig. 2). A single section, in addition to such tissue as has been here-

tofore noted, contains the following and establishes the nature of the tumor: small, well differentiated tubules, not of normal testicular type, lined by regular, tall, cylindric epithelium (Fig. 3*A*); larger, differentiated glandlike alveoli lined by cuboidal epithelium (Fig. 4*A*); several masses of squamous epithelium (Fig. 3*B*); a glandlike structure lined by a single layer of columnar epithelium which is heavily pigmented by fine black granules (retinal epithelium?) (Fig. 4*B*); wide cystic spaces lined by a single layer of low cuboidal epithelium (Fig. 5); islands of well differentiated hyaline cartilage (Fig. 4*C*); many bands and bundles of smooth muscle, which are often concentrically arranged about the cystic spaces (Fig. 5). In one section, a small island of compressed, adult testicular tissue with edematous stroma is present outside the capsule of the tumor. The epididymis is not recognizable. No tumor tissue is seen in cross sections of the cord.

The teratomatous nature of this tumor is apparent, the three germinal layers being represented by squamous and pigmented epithelium (epiblast); by glands lined by cylindric epithelium and cysts lined by cuboidal epithelium (hypoblast); and by fibrous tissue, mucoid tissue, smooth muscle, and hyaline cartilage (mesoblast). In addition to these well differentiated elements, there is atypical epithelial tissue which has all the characteristics of malignancy. The latter is glandular, papillary or solid; it is derived from the structures with columnar epithelium and is hypoblastic in origin.

There are on file in the pathologic laboratory of the Michael Reese Hospital microscopic sections from fourteen malignant tumors of the testis, in addition to those from the case herewith reported. This material has been subjected to comparative microscopic study, with these results. The original pathologic diagnosis, in quotation marks, is given in each case; this diagnosis depends somewhat on the prevailing opinion at the time the diagnosis was made and to some extent also on the individual responsible for the diagnosis. The original diagnosis is followed by our own review of the material.

Case 2.—Path. No. 19P483, July 20, 1919.—A man, aged 24, whose right testicle had begun to increase in size one month before operation, also suffered pain in the back and a dragging sensation. There was gradual, painless increase to the size of a small orange. "Adenocarcinoma."

Comment.—This is a tumor of markedly glandular type (Fig. 6). The glands, which vary in size and shape, are lined by cylindric epithelium, and suggest a carcinoma of intestinal origin. Where the tumor is most atypical the cells become lower and more irregular and solid masses of irregularly polyhedral cells are formed. The glandular tissue often lies in an immature, spindle cell stroma, which in appearance and relation to the epithelial elements simulates closely the cellular stroma of the congenital mixed tumor of the kidney. Broad bands of denser tissue run through the tumor. These are composed of fibrous tissue, with a few bundles of smooth muscle. In these bands are small glands lined by well differentiated, nonciliated, cylindric epithelium. There are also two small, sharply defined islands of squamous cells, the central cells of each island being large and hyaline. A rounded area of considerable size in the dense tissue is composed of oval and short spindle cells with vesicular nuclei. This is young, incompletely differentiated cartilage.

There are several cystic spaces, some lined by tall columnar epithelium like that of the small glands, and others by similar epithelium which has been somewhat flattened by pressure. In some areas, the atypical glandular tumor tissue has the mucoid appearance of a colloid intestinal carcinoma. The cord contains a small mass of cells within a vessel, not glandular in arrangement, but of the same general characteristics as the solid portions of the tumor of the testis. A small mass of compressed testicular tissue is present at one side of the tumor.

In this tumor, the teratomatous nature is again apparent, although heterologous elements are not so prominent as in Case 1. Derivatives of the three

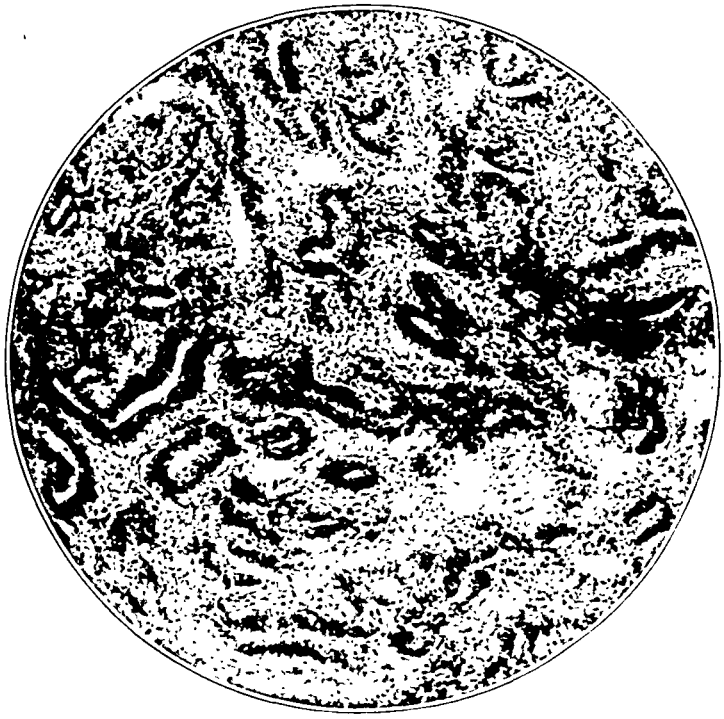

Fig. 6.—Atypical glandular structures lined by cylindric epithelium in the tumor from Case 2. ×80.

germinal layers are present. Again it is the hypoblastic derivatives which have given rise to the atypical malignant tissue, whose resemblance to an intestinal carcinoma is striking. While the stroma has an immature, spindle cell character in places, we believe that only the glandular epithelium is to be considered malignant.

Case 3.—Path. No. 20P567. Aug. 16, 1920.—A man, aged 20, suffered increase in the size of the right testis which was first noted seven years before admission. Growth was slow and gradual, and was never at any time associated with pain or tenderness. The testicle was three times the normal size; it was firm and not fluctuant (Fig. 7). "Embryonal carcinoma."

tofore noted, contains the following and establishes the nature of the tumor: small, well differentiated tubules, not of normal testicular type, lined by regular, tall, cylindric epithelium (Fig. 3*A*); larger, differentiated glandlike alveoli lined by cuboidal epithelium (Fig. 4*A*); several masses of squamous epithelium (Fig. 3*B*); a glandlike structure lined by a single layer of columnar epithelium which is heavily pigmented by fine black granules (retinal epithelium?) (Fig. 4*B*); wide cystic spaces lined by a single layer of low cuboidal epithelium (Fig. 5); islands of well differentiated hyaline cartilage (Fig. 4*C*); many bands and bundles of smooth muscle, which are often concentrically arranged about the cystic spaces (Fig. 5). In one section, a small island of compressed, adult testicular tissue with edematous stroma is present outside the capsule of the tumor. The epididymis is not recognizable. No tumor tissue is seen in cross sections of the cord.

The teratomatous nature of this tumor is apparent, the three germinal layers being represented by squamous and pigmented epithelium (epiblast); by glands lined by cylindric epithelium and cysts lined by cuboidal epithelium (hypoblast); and by fibrous tissue, mucoid tissue, smooth muscle, and hyaline cartilage (mesoblast). In addition to these well differentiated elements, there is atypical epithelial tissue which has all the characteristics of malignancy. The latter is glandular, papillary or solid; it is derived from the structures with columnar epithelium and is hypoblastic in origin.

There are on file in the pathologic laboratory of the Michael Reese Hospital microscopic sections from fourteen malignant tumors of the testis, in addition to those from the case herewith reported. This material has been subjected to comparative microscopic study, with these results. The original pathologic diagnosis, in quotation marks, is given in each case; this diagnosis depends somewhat on the prevailing opinion at the time the diagnosis was made and to some extent also on the individual responsible for the diagnosis. The original diagnosis is followed by our own review of the material.

Case 2.—Path. No. 19P483, July 20, 1919.—A man, aged 24, whose right testicle had begun to increase in size one month before operation, also suffered pain in the back and a dragging sensation. There was gradual, painless increase to the size of a small orange. "Adenocarcinoma."

Comment.—This is a tumor of markedly glandular type (Fig. 6). The glands, which vary in size and shape, are lined by cylindric epithelium, and suggest a carcinoma of intestinal origin. Where the tumor is most atypical the cells become lower and more irregular and solid masses of irregularly polyhedral cells are formed. The glandular tissue often lies in an immature, spindle cell stroma, which in appearance and relation to the epithelial elements simulates closely the cellular stroma of the congenital mixed tumor of the kidney. Broad bands of denser tissue run through the tumor. These are composed of fibrous tissue, with a few bundles of smooth muscle. In these bands are small glands lined by well differentiated, nonciliated, cylindric epithelium. There are also two small, sharply defined islands of squamous cells, the central cells of each island being large and hyaline. A rounded area of considerable size in the dense tissue is composed of oval and short spindle cells with vesicular nuclei. This is young, incompletely differentiated cartilage.

There are several cystic spaces, some lined by tall columnar epithelium like that of the small glands, and others by similar epithelium which has been somewhat flattened by pressure. In some areas, the atypical glandular tumor tissue has the mucoid appearance of a colloid intestinal carcinoma. The cord contains a small mass of cells within a vessel, not glandular in arrangement, but of the same general characteristics as the solid portions of the tumor of the testis. A small mass of compressed testicular tissue is present at one side of the tumor.

In this tumor, the teratomatous nature is again apparent, although heterologous elements are not so prominent as in Case 1. Derivatives of the three

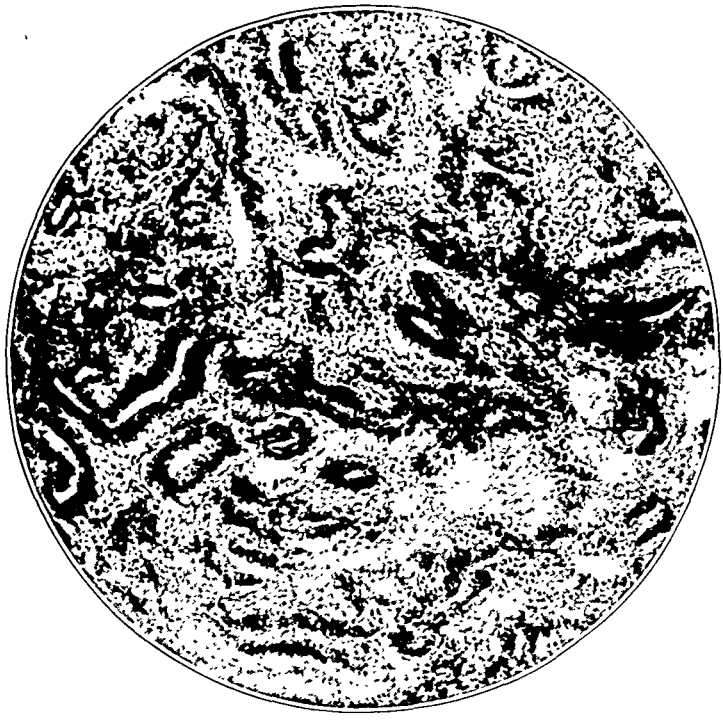

Fig. 6.—Atypical glandular structures lined by cylindric epithelium in the tumor from Case 2. ×80.

germinal layers are present. Again it is the hypoblastic derivatives which have given rise to the atypical malignant tissue, whose resemblance to an intestinal carcinoma is striking. While the stroma has an immature, spindle cell character in places, we believe that only the glandular epithelium is to be considered malignant.

Case 3.—Path. No. 20P567, Aug. 16, 1920.—A man, aged 20, suffered increase in the size of the right testis which was first noted seven years before admission. Growth was slow and gradual, and was never at any time associated with pain or tenderness. The testicle was three times the normal size; it was firm and not fluctuant (Fig. 7). "Embryonal carcinoma."

Comment.—Poorly defined cellular areas of variable size alternate with areas of fibrous and myxomatous tissue. The tumor cells are closely placed and in general are rather spindle shaped. The nuclei are oval or elongated, deeply stained and show little structural detail. A few cystic spaces of moderate size are present. These are lined by from one to three or four layers of cells which are low cuboidal when single layered; the nuclei are dense. This epithelium gives off finger-like processes into the surrounding stroma, which form solid alveolar masses embedded in the stroma (Fig. 8). In these, the cells of the outer layer are elongated; in appearance, and in relation to both the surrounding stroma and to the cells within the alveoli they resemble the cells of the malpighian layer of the epidermis. The central cells are less elongated. As this epithelium invades the stroma further from the cystic spaces from which it is derived, it goes over into the poorly defined masses which, as noted heretofore, make up the bulk of the tumor. No normal testis tissue and no teratomatous elements are seen.

In this tumor, a teratomatous origin is not apparent. It is of relatively long duration, which may have permitted overgrowth of heterologous elements by the more cellular tissue. The latter in general has the appearance of spindle cell sarcoma tissue; the morphology of some of the areas would warrant such a diagnosis. The derivation of such tissue from the low cuboidal epithelium of the cystic spaces is quite definite, and immediately about the spaces the tissue has a markedly alveolar character. The alveoli, however, are solid and nowhere partake of the glandular character seen in Cases 1 and 2. The solid alveoli resemble most closely those of a basal cell carcinoma of the skin; the cell type is also that characteristic of such a neoplasm. We believe that the cysts present in this tumor are epiblastic in origin; that the malignant tissue, in places sarcomatous in appearance and nowhere glandular in character, is derived from epiblast, and that the tumor, therefore, is teratomatous in nature.

Case 4.—Path. No. 19P881, Dec. 22, 1919.—A man, aged 46, noticed slight swelling of the testis first in September, 1919. There was gradual increase to the size of a goose egg; the increase was not associated with pain. "Embryonal carcinoma."

Comment.—This is a very cellular tumor (Fig. 9) composed of round, oval or polyhedral cells, closely placed, with no reticulum between the individual cells. Each cell has a rather wide cell body of faintly stained, coarsely meshed cytoplasm, in which is a large round or oval nucleus. The nuclei stain rather deeply, the chromatin being so finely granular that individual chromatin granules can hardly be distinguished. Each nucleus has one or two deeply stained chromatin nucleoli. The tumor cells are quite uniformly as described; few have the granular character of the nuclear chromatin so striking in developing spermatogenic cells. Narrow stroma bands run through the tumor, causing in places indistinct lobulation. At the periphery of the tumor is a thin compressed strip of testis. In this, the more peripheral cells, spermatogonia, of the tubules are identical with those of the tumor. The more central cells have the characteristic arrangement of the nuclear chromatin of spermatogenic cells. Two tubules contain a few spermatozoa; in the majority of the tubules, compression appears to have interfered with spermatogenesis. In some of the tubules, all of the cells are of the type of those of the tumor. No teratomatous elements are seen. Scattered about in the tumor tissue are irregularly

shaped islands of varying size composed of lymphocytes, which are supported on a fine reticulum. No tumor tissue is present in the cord.

This tumor was of recent origin and grew rapidly. It has throughout a markedly cellular or medullary character. In places it has an indistinct, solid alveolar arrangement, but nowhere is there any suggestion of glandlike structure. Heterologous elements are absent, unless the scattered lymphoid islands should be considered such. None of the latter has the structure of a lymphoid follicle, and all of the cells are of the ripe lymphocyte type. At the periphery, a thin layer of compressed testicular tissue is present. The description calls attention to the similarity of the tumor cells to certain of the cells of the spermatic tubules. The interpretation of this similarity will be discussed later.



Fig. 7.—Tumor from Case 3, showing the small number of small cystic spaces.

The four tumors which have just been described illustrate three types of tumor which have distinct morphologic differences. Cases 1 and 2 are alike in that both are undoubtedly of teratomatous origin. They are alike, furthermore, in that the atypical, proliferating, malignant tissue forms structures of definitely glandular character, which are apparently derived from those elements of the teratoma which are hypoblastic in origin. Case 3 appears sarcomatous in places, but is certainly epithelial. Definite proof of its teratomatous nature could not be found, but there are a few epithelial-lined cystic spaces of a kind which it is difficult to derive from normal testicular structures. The atypical tissue has developed from the lining of these cysts and forms solid, nonglandular alveoli, which appear epiblastic rather than hypoblastic in origin. Case 4 is an example of the type of tumor which has been so frequently described under a variety of names in the literature. No differentiated heterologous tissue was found. The atypical tissue present is quite different from that in

the other tumors. Of the various cell types which may occur in a teratoma of the testis or in normal testicular tissue, only the younger cells of the normal convoluted tubules bear a resemblance to the tumor cells. This resemblance is so close as to be striking. Further discussion of the possible meaning of this similarity of cell type will be delayed until other tumors of similar and different character have been described.

CASE 5.—Path. No. 5305, June 15, 1909.—A man, aged 38, had noticed painless swelling of the right testicle for three weeks. At operation the tumor was found to be the size of a large orange. "Mixed tumor of the testis showing cartilaginous, sarcomatous and atypical epithelial structures."

Comment.—There are areas of dense fibrous tissue, in one of which is an island of well differentiated hyaline cartilage surrounded by perichondrium. Large areas of branching, atypical, markedly glandular structures are lined by epithelium of the cylindric type, which is often piled up and polyhedral. Poorly defined cellular areas are composed of oval and spindle cells with relatively large, vesicular, round or oval nuclei. Embedded in these areas are numerous very large round or oval cells with finely granular, deeply eosin stained, finely fibrillated cytoplasm, each cell with from one to three or four centrally placed, round, vesicular nuclei. Some of these cells are long, narrow and longitudinally fibrillated. No cross striations can be seen, but the cells appear to be young striated muscle cells. There are a few small bundles of narrow smooth muscle cells.

CASE 6.—Path. No. 2591, June 30, 1911.—A man, aged 31, was operated on in another hospital in 1909 for left inguinal hernia and undescended left testicle. For one year before this operation, slight enlargement of the undescended testicle had been noticed. At this operation the testis was brought down into the scrotum but later it retracted into the inguinal canal. Increase in the size of the testicle, which became apparent in 1910, was rapid; it was not associated with pain, but with loss of weight. "Malignant embryoma."

Comment.—Most of the tissue is so completely necrotic that its nature cannot be determined. Broad bundles of dense fibrous tissue are partly infiltrated by polymorphonuclear leukocytes. Some of these bands, which contain narrow bundles of smooth muscle, come apparently from the epididymis. There is a single small, well defined island of cartilage. In some of the fibrous tissue bands there are a number of cystic spaces; some are empty, some are filled with necrotic material, some contain fragments of cells and one is partly lined by single layered, low cuboidal epithelium. Embedded in the fibrous tissue is a poorly defined cellular area composed of oval and round cells with vesicular or elongated nuclei. In this area are a few atypical glandlike structures lined by cylindric epithelium.

CASE 7.—Path. No. 3331, Jan. 29, 1912.—A man, aged 23 years, one month before admission, had noticed a firm, small nodule of the right side of the scrotum. This enlarged rapidly and painlessly to the size of a small orange. "Carcinoma sarcomatodes."

Comment.—At the periphery is stroma which contains small glandlike structures lined by tall cylindric cells and wide cystic spaces lined by cuboidal epithelium. In both kinds of structure the epithelium piles up in places and forms masses of polyhedral cells which invade the stroma, where the masses are often separated from one another by blood and fibrin. These masses are of variable size and shape. Cellular outlines are indistinct or absent, giving

to the tissue the appearance of syncytium. The cells, when they are not fused, are large and irregularly polyhedral, with large vesicular nuclei which have distinct membranes but little chromatin. The cord is inflamed and invaded.

CASE 8.—Path. No. 4513. Jan. 7, 1913.—A man, aged 33, had suffered pain and swelling of the left testis for six weeks. The size of the tumor is not stated. It was firm, not nodular. "Primary carcinoma."

Comment.—Large, solid, cellular alveoli are surrounded by dense, broad bands of fibrous tissue and smooth muscle. The cells are large and irregularly polyhedral. The nuclei are large; each has a distinct membrane and little finely granular or coarser chromatin on a loose reticulum; the nucleolus is

Fig. 8.—The margin of one of the small cystic spaces of the tumor from Case 3. This is lined by cuboidal epithelium, from which solid cellular alveoli are given off and penetrate the stroma. × 80.

distinct and deeply stained. The nucleus is surrounded by a broad zone of coarsely alveolar cytoplasm. The larger alveoli are subdivided by narrow stroma bands which run in from the periphery. A mass of tumor cells is present in a larger artery. A few small alveoli in the dense tissue have a somewhat glandular appearance and are lined by cells of the cylindric type. At the periphery of some of the large, solid alveoli, the cells may be rather regularly arranged, with a shape approaching cylindric. Some of the large alveoli have several lumen-like spaces, about which the cells are more regularly arranged and are columnar. Many large alveoli are centrally necrotic. There

is much dense stroma in one area, with many lymphocytes and bundles of smooth muscle. There is a mass of atrophic testicular tissue near this area.

CASE 9.—Path. No. 8531, Feb. 9, 1916.—A man, aged 23, had suffered hypogastric pain with frequent micturition for two years. He had lost 20 pounds in weight in the last five weeks before admission. Neither testicle was in the scrotum. At operation, a mass the size of a grapefruit was found in the small pelvis; this was a tumor of the undescended left testicle. "Mixed tumor, teratoid not teratoma, malignant."

Comment.—Dense stroma encloses cystic spaces and smaller glands lined by cuboidal or cylindric, nonciliated epithelium. Atypical, glandular, adenocarcinomatous tissue is composed of hyperplastic and irregular epithelium derived from that of the spaces. There is much necrosis. No teratomatous structures and no normal testis tissue are seen.

CASE 10.—Path. No. 9447, Nov. 15, 1916.—A man, aged 38, had experienced sudden pain, following intercourse, in the left testis six months before admission. Slight swelling of the testicle was noticed the next day. The pain disappeared, but the testis increased progressively in size until it was as large as an orange. The mass had been needled twice. There was some pain during the last two weeks before admission. After removal, the tumor measured 12 by 10 by 6 cm.; the cut surface showed dark gray areas of hemorrhage and necrosis. "Malignant teratoma."

Comment.—The tumor is of definitely mixed character and contains areas of differentiated hyaline cartilage, fibrous stroma, many large bundles of smooth muscle and islands of squamous epithelium. Cystlike spaces of variable size are lined by cuboidal to cylindric epithelium; in some of these spaces the epithelium is ciliated. Glandlike spaces of varying size and shape are lined by very tall, well differentiated, columnar epithelium, which is not ciliated and which has the appearance of intestinal epithelium. In some cystic spaces, direct transformation from single layered cylindric epithelium to many layered squamous epithelium can be seen. In some of the larger glands, the epithelium forms papillary infoldings. In one area, the epithelial tissue is still glandular, but atypical; its variable and irregular cells are apparently derived from the cylindric epithelium. In places these cells form irregular syncytial masses. Some of the glands with differentiated columnar epithelium lie in very cellular stroma composed of oval and spindle cells. Embedded in the more differentiated stroma are small, irregularly alveolar masses of cells with densely stained, solid nuclei and with very little cytoplasm. These cells are larger than lymphocytes; in appearance and in their indistinct rosette arrangement in places, they suggest neuro-epithelial tissue.

CASE 11.—Path. No. 1890, Nov. 18, 1910.—A man, aged 39, gave a clinical history of chronic appendicitis. He had been operated on for double inguinal hernia eleven years previously. After recovery from this operation, he noticed only one testicle in the scrotum and was told by the surgeon that he had had only one descended testis, the other being left in the inguinal canal. At the last operation, the right testis was in the scrotum. A tumor mass about the size of an orange extended from the umbilicus to within 1 inch of the pubis; this was a tumor of the undescended left testis. "Large, round cell sarcoma."

Comment.—Narrow stroma bands form a supporting network and subdivide the cellular tumor into polyhedral alveoli. In areas, the alveoli are small and have somewhat the appearance of solid seminal tubules. The cells are large

and have the general morphology of spermatocytes. The chromatin is in the form of fine granules on a distinct network.

CASE 12.—Path. No. 2605, July 3, 1911.—A man, aged 41, had experienced increase in the size of the right testicle, without pain, for one year. At operation, the right testis was found transformed into an irregularly nodular mass the size of a small orange. "Round cell sarcoma."

Comment.—This is a very cellular tumor, with a small amount of stroma. The cells usually show no regular arrangement, but sometimes form indefinite clumps, and rarely are aggregated into groups by confining bands of reticulum.



Fig. 9.—The large celled, indistinctly alveolar tissue of the tumor from Case 4. At one side is an island of lymphocytes. ×80.

The cells are large, round or polyhedral, with a rather wide zone of dense, finely granular cytoplasm. The nuclei are large. In some, the chromatin is in fine granules on a close reticulum. In others, the granules are larger and are more widely separated. Some large nuclei are deeply hyperchromatic. Some nuclei are small and pyknotic. An occasional nucleus is narrow, small, pyknotic, and suggests a sperm head. Tumor cells are present within a large vein which is surrounded by dense fibrous tissue.

CASE 13.—Path. No. 4204, Oct. 8, 1912.—A man, aged 45, had noticed pain and swelling of the left testis for seven weeks, with gradual increase to the size of a small orange. The pain was only slight. The mass was firm and only slightly tender on pressure. "Small, round cell sarcoma."

Comment.—Very cellular tumor tissue has replaced all the original elements. It is composed of rather large, round, oval or slightly elongated cells, each of which has a narrow zone of faintly stained cytoplasm and a relatively large nucleus. The nuclei have a homogeneous appearance, due to the uniform distribution of minute chromatin granules throughout the nucleus. A nuclear reticulum can not be seen. Most of the nuclei contain one or two small indistinct nucleoli. Some nuclei stain more deeply than others. The closely placed cells form indistinct alveolar nests and solid cords, from two to four or five cells wide, separated by narrow bands of reticulum. In a few places, small, solid alveolar masses are surrounded by definite fibrous walls, apparently as the result of the growth of tumor tissue within blood vessels or tubules. Areas of the tissue are necrotic. No glandular structures and no teratomatous elements are seen. The cord is inflamed; some arteries are obliterated by inflammatory tissue; an occasional one contains a mass of cells like the tumor cells.

CASE 14.—Path. No. 5096, June 18, 1913.—A man, aged 33, had first noticed enlargement one year before admission. The increase continued without pain. The patient's blood gave a + + + + Wassermann reaction. At operation, the left testicle was found to be nodular, firm and the size of a hen's egg. "Mixed round cell sarcoma."

Comment.—Large, solid, cellular areas are subdivided by very fine strands carrying capillaries into indistinct polygonal alveoli. The cells are large, irregularly polyhedral and have a considerable amount of granular cytoplasm. The nuclei are large and round, with marked chromatin variation. Some are solid and hyperchromatic. Others are vesicular, with finely granular chromatin on a close meshwork. In other nuclei, the chromatin granules are coarser and are more regularly arranged about the inner surface of the membrane on a more widely meshed reticulum. The cells vary considerably in size. Many of the smaller ones have solid, deeply stained nuclei.

CASE 15.—Path. No. 7817, July 25, 1915.—A man, aged 42, had had swelling of the left testis of five weeks' duration, some tenderness, but no pain. The patient asserted that the increase in size began suddenly and reached three times the normal size of the testis in one week, since which time the size had remained stationary. The clinical diagnosis was tuberculous epididymitis. At operation, both the left epididymis and testicle were found to be enlarged and largely replaced by caseous yellow material. "Primary sex cell tumor."

Comment.—Broad dense stroma bands, which are infiltrated by lymphocytes, subdivide the tissue and surround large, solid, cellular areas. The cells are large, round, oval or polyhedral, closely placed, and have little cytoplasm. The nuclei are large, rich in chromatin, round or oval. The nuclear chromatin is finely granular and is uniformly distributed throughout the nucleus. In most of the nuclei, there is a small, indistinct nucleolus. In some areas, the cells form anastomosing bands which lie in cellular young stroma. There is no glandular arrangement anywhere; and no teratomatous elements are seen. There are large areas of necrosis, about which the tissue contains many polymorphonuclear leukocytes.

GENERAL CONSIDERATION OF CASES

Cases 5 to 15, inclusive, again fall into three groups. In Cases 5, 6 and 10 the presence of heterologous tissue elements establishes the

teratomatous origin of the tumors. Of the greatest importance is the fact that the atypical tissue has a glandular character and is apparently hypoblastic in origin. These three tumors, therefore, are identical with Cases 1 and 2. Cases 7, 8 and 9 form a second group, in that the teratomatous nature can not be definitely established by the presence of heterologous differentiated tissues. But each of these tumors contains, in varying numbers, glandular or cystic structures which are lined by single layered, well differentiated epithelium. These structures, which apparently represent the benign stage of the epithelium from which the atypical tissue comes, have no analogy with any of the structural elements of the normal testis. They are, however, much like some of the glandular elements present in the teratomatous tumors of Cases 1, 2, 5, 6 and 10. Furthermore, the atypical tissue of Cases 7, 8 and 9 is of the same general character as that of the teratomatous tumors. We, therefore, believe that Cases 7, 8 and 9 are to be grouped with Cases 1, 2, 5, 6 and 10 as malignant epithelial tumors which originated in teratomas. From a study of these tumors we believe that the glandular or adenocarcinomatous character of the malignant tissue of testicular tumors is the best criterion of the teratomatous origin of such tumors. In view of the fact that tumors with undoubted heterologous elements almost always give rise to atypical tissue of this sort, we cannot concede the derivation of tumors, which contain the same kind of atypical tissue but no heterologous elements, from the tubuli recti, but agree with Ewing [1] that such tumors are the result of the onesided development of some one constituent of a teratoma. This constituent, we believe to be smaller differentiated glandular or larger cystic structures which are hypoblastic in origin. To the same general group belongs Case 3, already considered above. This we believe to be a malignant epithelial tumor derived from the epiblastic elements of a teratoma.

The tumors of Cases 11, 12, 13, 14 and 15 form a quite distinct group, to which belongs also Case 4, which was selected for more detailed discussion above. Common to all these tumors is their soft, cellular, medullary character, which has been responsible for the widespread use of the term "large round cell sarcoma" for neoplasms of this kind. An alveolar arrangement of the cells can usually be detected; in some examples, it is quite distinct in places, while in others an alveolar character is more difficult to determine. In none of the tumors is there any semblance of a glandular arrangement. In not one of the six tumors of this group in our series is heterologous tissue present. This seems to hold also for the large cell tumors described by others. Dense groups of lymphocytes occur frequently, but they do not have the appearance of true lymphoid tissue. Most characteristic, and most important for any attempt to elucidate the origin of tumors of this

group, is the type of the tumor cell. The latter is large. It is irregularly polyhedral in shape, due to the pressure which the cells exert on one another. The cytoplasm stains faintly and is rather coarsely alveolar. The nucleus is absolutely and relatively large and has a distinct membrane and one or two indistinct, small nucleoli. The chromatin, in different tumors and sometimes in the same tumor, shows differences in arrangement and distribution, but these differences all fall into a definite series. In some tumors, of which Cases 4, 13 and 15 are examples, distinct chromatin granules do not occur or are so fine that they cannot be readily seen. Such nuclei stain with moderate intensity and have a homogeneous ground-glass appearance. Apparently the chromatin is dissolved in the karyolymph or is uniformly distributed in the latter in the form of very fine granules. In other tumors, Case 11 for example, the chromatin is aggregated into distinct but still small granules, which are arranged on a finely meshed intranuclear network. In still other tumors, Cases 12 and 14, the granules are still larger and fewer in number, as the result of further aggregation and condensation of chromatin on the intranuclear network, which is now more coarsely meshed. In addition to these nuclear types, every tumor contains a large or small number of solid, deeply hyperchromatic nuclei. There may be variation in nuclear size, a small proportion of nuclei being larger than the average, but with the typical chromatin distribution, a somewhat larger proportion being smaller than the average. It is more especially the hyperchromatic nuclei which have the smaller diameters.

The nuclear morphology which has been described appears to be very characteristic of the group of tumors under consideration. Malignant tumors of definite teratomatous origin may be composed of large cells with relatively large vesicular nuclei, but such nuclei are quite distinctly different, in that they have the characteristics of young tissue nuclei. The nuclear type under consideration is not found in normal somatic nuclei, either young or old, but it is characteristic of the sex cells of the seminal tubules. The homogeneous nucleus first described is identical with that of the spermatogonia; the two kinds of cell cannot be distinguished from each other when tubules and tumor tissue can be studied side by side in the same section. The finely granular, closely meshed nucleus is like that of the early spermatogenic cell or spermatocyte as it is proceeding to mitosis; and the more coarsely granular, loosely meshed nucleus corresponds to that of the spermatogenic cell just before the chromatin becomes formed into definite chromosomes. These granular stages are very much like the leptotene and pachytene stages in the spermatogenesis of those lower animal forms whose spermatogenic cycle has been carefully studied. The smaller, more con-

densed and hyperchromatic nuclei present in considerable numbers in the cells of some tumors are suggestive of the later stage in spermatogenesis just before the spermatid nucleus elongates to form the head of the spermatozoon. Two of our tumors contain a few scattered groups of elongated, densely stained nuclei, very much like, but larger than, the elongated nuclei of the late spermatid stage. Because these may be the result of degenerative phenomena in the tumors, we hesitate to consider them true derivatives of the tumor cell cycle. Not only do the various cells described bear the greatest resemblance to the cells of the spermatogenic cycle, but the converse is also true. The nuclei bear no resemblance to those of normal somatic cells or to those of tumors derived from somatic cells.

Of the kind of tumor under discussion, Ewing [1] says: "The typical large cell tumor of the testis, with large, round, clear cells and lymphoid stroma, is a highly characteristic structure which is duplicated by no other structure." In this we agree with him, but we believe that the highly characteristic feature relates to the nuclei rather than to the cells or to their arrangement. Our series of tumors does not bear out his further statement that "this characteristic tumor is exactly the type of carcinoma which occurs in the complex teratomata of the author's series." We are unable to find in our tumors of this group any type of tissue which would warrant the assumption of origin from teratoma. More important than such negative evidence is the peculiar nuclear type, which is not found in any of the other tumors, but which is characteristic of the cells of the seminiferous tubules. We can find no evidence of transition from the cellular tissue of definitely teratomatous tumors to cells of this type. In the summary of Geist and Thalhimer's [28] article, the following statements are made: "The common type of carcinoma associated with teratoma is adenomatous in character. The medullary tumors we believe are primary tumors of the testicle arising from the seminiferous tubules." With these conclusions we are in entire accord. We would, however, go a little further and state our conviction that all testicular tumors of adenomatous character are teratomatous in origin, in spite of the fact that heterologous elements are not detected in some of the tumors of this character. The evidence that such tumors are derived from the tubuli recti, as asserted by Geist and Thalhimer, Frank and others, appears inadequate. For the malignant epithelial tumors of certain or probable teratomatous origin. Ewing's designation of them as embryonal carcinoma seems the best. For the large cell, medullary tumors, which in agreement with Chevassu, Frank, Sakaguchi, Geist and Thalhimer and others, we hold to be derived from the epithelium of the seminiferous tubules, a name which would indicate their origin from cells of the spermatogenic cycle

appears preferable. We suggest spermatocytoma as perhaps better than the séminome of Chevassu.

The fifteen tumors, all malignant, studied in this series subdivide themselves thus: Five with definite heterologous structures, the atypical tissue being hypoblastic in character; three without heterologous elements, but with atypical tissue of the hypoblastic type; one without heterologous elements, but with atypical tissue probably of epiblastic origin; six spermatocytomas, all without heterologous tissue. Believing that tumors of hypoblastic or epiblastic type are derived from teratoma, all the tumors can be divided into two groups, which will cover all the malignant tumors of the testis of clinical importance: I, embryonal carcinoma, which would include nine of our tumors and II, spermatocytoma, which would include six of our tumors. The age incidence in these two groups is suggestive. In the first group, the ages in years are as follows, the number of tumors at each age being given in parentheses after the age: 20 (one), 23 (two), 24 (one), 30 (one), 33 (one), 38 (two). In the second group the ages are: 33 (one), 39 (one), 41 (one), 42 (one), 45 (one), 46 (one). In the first group the average age is 29 years; the average is raised by the two tumors at 38 years, all the rest occurring at 33 years or under. In the second group, the average age is 41 years; the average is lowered by a single tumor at 33 years, all the rest being at 39 years or more. If these extreme cases are omitted, the average age in the two groups is, respectively, 26.3 years and 42.6 years. The higher average age incidence of the second group is not due to a longer clinical duration of the tumors of this group; on the contrary, the rate of growth of the tumor is more rapid and the duration shorter in the second group than in the first. Far-reaching conclusions are not permissible from this small number of cases, but the difference in age deserves some consideration when it is correlated with the histologic differences which we consider fundamental. In this connection, it is to be noted that Hardouin and Potel [30] have reported a tumor which they consider a seminoma in a boy, aged 7 years.

Our series includes examples of the different kinds of malignant epithelial tumors except chorio-epithelioma. In three of the glandular, hypoblastic tumors, syncytial cell masses are formed; but these appear to be the result of the same process which leads to cell fusion in rapidly growing carcinomas of the mammary gland and intestine. True chorioma must be derived from embryonic membrane tissue and the explanation of the origin of this form of neoplasm must be based on a satisfactory and acceptable theory of the origin of teratoma of the testis in general. The various theories have been critically analyzed by

30. Hardouin, P., and Potel, G.: Deux observations de tumeur du testicule chez l'enfant, Bull. et mém. Soc. anat. de Paris **79**:150, 1914.

Ewing.[1] He accepts, as subject to the fewest objections, the theory of the origin of teratoma from sex cells. Whether this derivation is from sex cells whose normal development into spermatogonia has been suppressed, as held by Ewing, or from normal sex cells by a process of parthenogenesis, is a question which is impossible of solution in the present state of our knowledge. Origin by parthenogenesis from normal sex cells appears to us to offer fewer theoretical objections than origin from suppressed dormant and undeveloped sex cells. Granted that a teratoma may arise in the testis from a sex cell, either normal or suppressed, then the development of fetal membrane epithelial tissue and of chorioma offers no difficulties, since trophoblast might well be the very first tissue element formed. If the trophoblastic tissue should go on to unrestricted proliferation at this early stage, a pure chorioma without any differentiated teratomatous elements might result, but such a tumor would still have to be considered teratomatous in origin. In Cooke's [27] tabulation of forty-seven chorio-epitheliomas, heterologous tissues were said to have been present in about half. When this combination of chorioma with differentiated tissues of other kinds occurs, the choriomatous tissue must be the result, not of the reversion of differentiated cells of the teratoma, but of the progressive proliferation of trophoblastic tissue which has failed to disappear in the further development of the teratoma. According to this conception, chorio-epithelioma of the testicle would fall into the first of the two groups which we have made heretofore, namely, embryonal carcinoma of teratomatous origin. Hartmann and Peyron [31] conclude that the structural differences which embryomatous tumors show are dependent on the stage of development which the ovum or totipotent cell reaches before malignant proliferation begins, a view which is not opposed to that expressed. The term placentoma, introduced by them for a group which they distinguish from chorioma, does not appear applicable to testicular tumors and should be reserved, if it is used at all, for tumors originating from decidual tissue. We cannot agree with Glaserfeld [32] that the fetal ectoderm, metastasizing as such, may give rise at some point distant from the primary tumor to chorionic epithelium as well as to other ectodermic structures, although we do not preclude the possibility of the formation of syncytial masses from ectodermal tissue. The mere formation of multinucleated protoplasmic masses without distinct cell boundaries does not constitute chorioma. The formation of such syn-

31. Hartmann, H., and Peyron, A.: Placentomes et choriomes du testicule. Bull. Acad. de méd. **81**:733 (June 3) 1919. Sur les néoformations d'origine chorioectodermique dans les tumeurs du testicule. Compt. rend. Acad. d. sc., Paris **168**:1131, 1919.

32. Glaserfeld, B.: Ueber das Hodenteratom mit chorionepitheliomähnlichen Bildungen. Ztschr. f. Krebsforsch. **9**:570, 1910.

cytial masses is a property of a wide variety of cells other than those of the fetal membrane epithelium.

Since the testicle contains various kinds of mesoblastic tissues in addition to the specific tissues which give rise to the tumors considered, any classification of tumors of the testis must include the various possibilities and must therefore be somewhat complicated. In the suggested classification which follows, only the two groups that are italicized are of clinical importance; the remaining headings, which may be disregarded for practical purposes, are included merely to give a place for tumors whose origin from elements other than those of teratoma or seminiferous tubules may be considered definitely established:

I. Homologous Tumors:
  A. Benign:
    1. Epithelial:
      (*a*) Adenoma of the seminal tubules (the tumors of Chevassu and of Pick [Ewing[1]]).
    2. Mesoblastic:
      (*a*) Fibroma (arising in the tunics; the tumors of Lardennois and Lecène,[15] Makins[16] and Boyer[17]).
      (*b*) Leiomyoma (arising in the epididymis; Ewing[1] accepts the tumors of Trelat, Rindfleisch, and Hericourt; a specimen recently received by the pathologic laboratory of the Michael Reese Hospital is a tumor of the epididymis of this kind).
      (*c*) Vascular tumors (lymphangioma, hemangioma).
      (*d*) Interstitial cell tumors. (A specimen in his own laboratory and the case reported by Chevassu, Ewing[1] considers examples of hyperplasia rather than neoplasia.)
  B. Malignant:
    1. Epithelial:
      (*a*) *Spermatocytoma.*
    2. Mesoblastic:
      (*a*) Sarcoma. (Extremely rare; possibly Sakaguchi's[25] case and three of Miyata's[19] cases arising in the tunics may be accepted.)

II. Heterologous Tumors:
  A. Benign:
    1. Cystic dermoid.
  B. Malignant:
    1. *Embryonal carcinoma.* Heterologous tissue may be present or may have been overgrown. The atypical tissue may be:
      (*a*) Trophoblastic (chorio-epithelioma).
      (*b*) Hypoblastic (the usual adenomatous tumor).
      (*c*) Epiblastic (solid alveoli of basal cell type, or tumors of neurocytoma type).
    2. Sarcomatous mixed tumor (true sarcoma in a teratoma appears to be rare).

CONCLUSIONS

In malignant tumors of the testicle, heterologous tissues may be present or absent. In the former case, the teratomatous nature is established. Tumors without heterologous elements may or may not be derived from teratoma.

In malignant tumors whose teratomatous origin is undoubted, the atypical tissue usually has a glandular character, suggestive of derivation from hypoblastic epithelium. In a certain proportion of tumors without heterologous tissue, the atypical tissue is of the same glandular character. Such tumors are derived from hypoblastic epithelium, whose proliferation has suppressed or overgrown such teratomatous structures as may have been present, or the malignant proliferation may have begun so early that differentiated mixed tissues were not formed.

In another group of tumors, the atypical tissue may have the characteristics of chorionic epithelium. In about half of the reported tumors of this group, heterologous elements were present and establish the teratomatous origin. Chorioma arises from the trophoblastic constituents of a teratoma. This may occur at so early a stage that histioid or organoid structures have not been formed, or at a later stage. In the latter case the heterologous elements may persist, or they may be overgrown by the choriomatous tissue.

In a small group of tumors, origin from the epiblastic constituents of a teratoma appears probable. The atypical tissue may have the structure of basal cell carcinoma or of neurocytoma.

For those tumors whose teratomatous origin is either definitely established by the presence of heterologous elements or is rendered very probable by the character of the atypical tissue, the designation embryonal carcinoma should be accepted. This term may be modified by the adjective hypoblastic, trophoblastic or epiblastic if the atypical tissue is glandular, syncytial or solid.

Quite distinct from the embryonal carcinomas are the tumors of the solid, medullary, large cell type. The distinguishing characteristic of these tumors is the cell type. The tumor cell is morphologically identical with the younger cells of the spermatogenic cycle and is probably derived from the cells of the seminiferous tubules. For this kind of tumor the term spermatocytoma is suggested.

In our series, none of the tumors which we have considered to be spermatocytomas contains any heterologous elements, nor does the atypical tissue have the morphology of that of any of the embryonal carcinomas.

In our series, the age incidence of spermatocytoma is distinctly higher than that of embryonal carcinoma; the clinical duration is shorter and the course is more rapid.

cytial masses is a property of a wide variety of cells other than those of the fetal membrane epithelium.

Since the testicle contains various kinds of mesoblastic tissues in addition to the specific tissues which give rise to the tumors considered, any classification of tumors of the testis must include the various possibilities and must therefore be somewhat complicated. In the suggested classification which follows, only the two groups that are italicized are of clinical importance; the remaining headings, which may be disregarded for practical purposes, are included merely to give a place for tumors whose origin from elements other than those of teratoma or seminiferous tubules may be considered definitely established:

I. Homologous Tumors:
  A. Benign:
    1. Epithelial:
      (*a*) Adenoma of the seminal tubules (the tumors of Chevassu and of Pick [Ewing[1]]).
    2. Mesoblastic:
      (*a*) Fibroma (arising in the tunics; the tumors of Lardennois and Lecène,[15] Makins[16] and Boyer[17]).
      (*b*) Leiomyoma (arising in the epididymis; Ewing[1] accepts the tumors of Trelat, Rindfleisch, and Hericourt; a specimen recently received by the pathologic laboratory of the Michael Reese Hospital is a tumor of the epididymis of this kind).
      (*c*) Vascular tumors (lymphangioma, hemangioma).
      (*d*) Interstitial cell tumors. (A specimen in his own laboratory and the case reported by Chevassu, Ewing[1] considers examples of hyperplasia rather than neoplasia.)
  B. Malignant:
    1. Epithelial:
      (*a*) *Spermatocytoma.*
    2. Mesoblastic:
      (*a*) Sarcoma. (Extremely rare; possibly Sakaguchi's[25] case and three of Miyata's[19] cases arising in the tunics may be accepted.)

II. Heterologous Tumors:
  A. Benign:
    1. Cystic dermoid.
  B. Malignant:
    1. *Embryonal carcinoma.* Heterologous tissue may be present or may have been overgrown. The atypical tissue may be:
      (*a*) Trophoblastic (chorio-epithelioma).
      (*b*) Hypoblastic (the usual adenomatous tumor).
      (*c*) Epiblastic (solid alveoli of basal cell type, or tumors of neurocytoma type).
    2. Sarcomatous mixed tumor (true sarcoma in a teratoma appears to be rare).

CONCLUSIONS

In malignant tumors of the testicle, heterologous tissues may be present or absent. In the former case, the teratomatous nature is established. Tumors without heterologous elements may or may not be derived from teratoma.

In malignant tumors whose teratomatous origin is undoubted, the atypical tissue usually has a glandular character, suggestive of derivation from hypoblastic epithelium. In a certain proportion of tumors without heterologous tissue, the atypical tissue is of the same glandular character. Such tumors are derived from hypoblastic epithelium, whose proliferation has suppressed or overgrown such teratomatous structures as may have been present, or the malignant proliferation may have begun so early that differentiated mixed tissues were not formed.

In another group of tumors, the atypical tissue may have the characteristics of chorionic epithelium. In about half of the reported tumors of this group, heterologous elements were present and establish the teratomatous origin. Chorioma arises from the trophoblastic constituents of a teratoma. This may occur at so early a stage that histioid or organoid structures have not been formed, or at a later stage. In the latter case the heterologous elements may persist, or they may be overgrown by the choriomatous tissue.

In a small group of tumors, origin from the epiblastic constituents of a teratoma appears probable. The atypical tissue may have the structure of basal cell carcinoma or of neurocytoma.

For those tumors whose teratomatous origin is either definitely established by the presence of heterologous elements or is rendered very probable by the character of the atypical tissue, the designation embryonal carcinoma should be accepted. This term may be modified by the adjective hypoblastic, trophoblastic or epiblastic if the atypical tissue is glandular, syncytial or solid.

Quite distinct from the embryonal carcinomas are the tumors of the solid, medullary, large cell type. The distinguishing characteristic of these tumors is the cell type. The tumor cell is morphologically identical with the younger cells of the spermatogenic cycle and is probably derived from the cells of the seminiferous tubules. For this kind of tumor the term spermatocytoma is suggested.

In our series, none of the tumors which we have considered to be spermatocytomas contains any heterologous elements, nor does the atypical tissue have the morphology of that of any of the embryonal carcinomas.

In our series, the age incidence of spermatocytoma is distinctly higher than that of embryonal carcinoma; the clinical duration is shorter and the course is more rapid.

The very great majority of malignant tumors of the testicle are epithelial and are either embryonal carcinomas or spermatocytomas.

The term sarcoma, as a designation for malignant testicular tumors, should be discarded unless the derivation of the tumor from mesoblastic tissue can be established. This applies particularly to alveolar sarcoma, large round cell sarcoma, globocellular sarcoma, angioplastic sarcoma, etc., which are names that have been improperly applied to tumors of the spermatocytoma group. The peritheliomas, hypernephromas and interstitial cell sarcomas probably all belong to this group.

Homologous pure tumors of the testis, except spermatocytoma, are rare. A few fibromas, leiomyomas, and spindle cell sarcomas, arising in the epididymis or in the tunics of the cord, epididymis or testicle may be accepted.

30 North Michigan Avenue.

ACCESSORY PANCREATIC TISSUE

REPORT OF TWO CASES *

E. J. HORGAN, M.D., M.S. in Surgery

ROCHESTER, MINN.

The occurrence of accessory pancreatic tissue in man is rather uncommon; a careful review of the literature by Warthin[1] in 1904 revealed only forty-seven cases, to which he added two. One case was reported in 1894 by Biggs,[2] which was not included in Warthin's survey, since which thirty-one additional cases have been reported (Table 1). Twelve of these thirty-two cases were found at operation, the remainder at necropsy.

In a series of 321 consecutive necropsies in the Mayo Clinic in which the entire length of the intestine was opened in 314 cases, I found accessory pancreases in two cases (0.6 per cent.). In one case the aberrant tissue was in the stomach; in the other, in the duodenum. These statistics conform to Opie's,[3] who found ten cases of aberrant pancreatic tissue in 1,800 necropsies. In several instances, I have observed accessory pancreatic tissue in the jejunum at operation. In one instance, it was about 3 inches from the ligament of Treitz opposite the mesentery, and it was necessary to go below it in order to perform a gastro-enterostomy.

A macroscopic and microscopic study of the two specimens of accessory pancreatic tissue that I found at necropsy forms the basis of this investigation. I have, in addition, reviewed the embryology of the pancreas in an effort to ascertain the cause of abnormally situated masses of pancreatic tissue.

SPECIMENS OF ACCESSORY PANCREATIC TISSUE

CASE 1 (139972).—At necropsy on a woman, aged 64, a small tumor was found in the duodenum, 5.5 cm. below the pylorus and 3 cm. above the papilla of the common bile duct. The base of the tumor was 1.5 cm. by 1.5 cm., and it projected 1 cm. into the lumen of the bowel (Fig. 1). Microscopic examination disclosed it to be an aberrant mass of pancreatic tissue. All the histologic structures of the pancreas were present, namely, ducts, acini, islets and connective tissue. The growth was covered by the mucous membrane of the duodenum and appeared to be embedded in the submucosa.

---

*From the Section on Surgery, Mayo Clinic.

1. Warthin, A. S.: Two Cases of Accessory Pancreas (Omentum and Stomach), Physician & Surg. **26**:337-340, 1904.

2. Biggs, G. P.: Supernumerary Pancreas in the Pylorus, Proc. New York Path. Soc. 1894, pp. 55-56.

3. Opie, E. L.: Disease of the Pancreas, Its Cause and Nature, Ed. 2. Philadelphia, J. B. Lippincott Company, 1910.

CASE 2 (130601).—At necropsy on a woman, aged 21, on the posterior wall of the stomach near the greater curvature, in the prepyloric region, a hemispherical tumor mass was found, with its rounded surface covered by mucous membrane, projecting into the lumen of the stomach (Figs. 2 and 3). The base was 3 cm. by 2.5 cm., the thickness 1.2 cm. On section, the cut surface of the tumor was pinkish-white with many small lobules. A rich blood supply was manifested by several large blood vessels. The tumor had the appearance of pancreatic tissue. Microscopic study verified the macroscopic diagnosis by the finding of pancreatic acini, ducts, islets, and connective tissue in about the same relation as in the normal pancreas. Its bases rested on the submucosa and its rounded surface was covered over by the muscularis mucosae and mucous membrane.

HISTOLOGIC APPEARANCE OF THE SPECIMENS

In both specimens, all the histologic units of the pancreas were identified under the microscope, namely, ducts, acini, islets, and connective tissue (Figs. 4, 5, and 6). In Specimen 1, all the microscopic sections examined showed an increase in the interlobular, interacinar and periductal connective tissue. In Specimen 2, all the sections presented the well known microscopic picture of the normal adult pancreas.

Ducts.—Each specimen contained one large duct, which was patent, lined with high columnar epithelium, with an outer coat of dense fibrous tissue, and which I believed to be the main excretory duct. Into this outer coat the interlobular ducts passed obliquely as they do in the normal gland, an observation which I had made previously.[4]

Acini.—The arrangement of the cells forming the acini was the same as in the normal pancreas. These large secreting cells are pyramidal in shape and resemble the normal acini cells. The so-called centro-acinar cells were present.

Islets.—In Specimen 1, the islets were small and few in number, and there was a moderate fibrosis. In Specimen 2, the islets were numerous. They were normal in size and the cells resembled those of the normal islet.

In order to determine whether the acinic cells in the alveoli had been functioning, and if so to demonstrate their activity of function, sections were stained for zymogen. Sections from both specimens were found on microscopic examination to contain large zymogen granules in the cytoplasm of the apical portion of the acinic cells (Fig. 7).

The presence of zymogen granules in the acinic cells and a patent excretory duct are sufficient evidence to prove that these tissues were producing pancreatic juice; and by the presence of the islets, one is justified in concluding that they were producing a hormone, which was the same as the internal secretion from the islets in the pancreas. These observations make it reasonable to assume that aberrant masses of pancreatic tissue are capable of the same function as the normally placed gland and that they function independently of it.

EMBRYOLOGY

A careful study of the embryology of the pancreas in the minute human embryo [5] has been possible only in a few instances, and most of

4. Horgan, E. J.: The Histogenesis of Carcinoma in the Islets of the Pancreas, J. Lab. & Clin. M. **5**:429-442 (April) 1920.

5. Lewis, F. T.: Development of the Pancreas, in Keibel, F., and Mall, F. P.: Manual of Human Embryology, Philadelphia, J. B. Lippincott Company, 1912 **2**:429-445.

Fig. 1 (A129972).—Accessory pancreas in the duodenum 5.5 cm. below the pylorus (Probe point may be seen projecting through ampulla of common bile duct).

the data are from the study of the development of the pancreas in the lower vertebrates. For this reason and because an accessory pancreas in the dog has been reported by Mann,[6] I reviewed the comparative anatomy and embryology of the pancreas.

Comparative Anatomy and Embryology.—From the researches of Oppel [7] and a complete survey of the literature which was compiled and reviewed by him, we have recorded data to prove the occurrence of the pancreas in the vertebrata from the cyclostomes, the lowest form of fish, through the orders of fishes, amphibians, reptiles, birds and mammals, to man. For a long time it was believed that the pancreas was missing in fishes and amphibians, but the organ has been found in many species



Fig. 2 (A130601).—Accessory pancreas in the posterior wall, near the greater curvature, in the prepyloric region of the stomach.

of these two orders. Oppel believes it could be found in every species of vertebrate if the investigator would make an earnest search for it.

It is of interest to know that even though Oppel made serial cross sections of the entire animal he could not demonstrate a pancreas in *Amphioxus lanceolatus,* the animal which is the only species representing the order of acranial vertebrates and spanning the gap between the vertebrates and the invertebrates. Other organs are missing in this animal and the pancreas may be. Oppel leaves it an open question.

6. Mann, F. C.: Accessory Pancreas in the Dog, Anat. Record **19**:263-268, 1920.

7. Oppel, A.: Lehrbuch der vergleichenden mikroskopischen Anatomie der Wirbeltiere. Jena, Fischer, 1900, **3**:742-870.

No doubt the extreme variation in the form of the pancreas in different species of animals has been the cause of its being overlooked by some investigators, for there is no regularity of form for each order of vertebrates. Oppel and others have found that the gland may exist in the form of (1) single or multiple masses of gland tissue embedded between the muscularis and serosa in the wall of the stomach or duodenum, or both, and having one or more short or long ducts from each mass; (2) one or several gland masses spread out between the layers of the mesentery and attached to the stomach, duodenum, or intestine and emptying through one main excretory duct from each mass; (3) numerous small or very small glands in fine cordons dispersed throughout the entire



Fig. 3 (A130601).—Cut surface of bisected accessory pancreas in the wall of the stomach showing lobules and blood vessels.

cavity between the layers of the mesentery, or, (4) numerous small or very small glands growing along the blood vessels, enveloping them like a sheath, and advancing with the blood vessels into the liver and spleen, interweaving the liver as it follows the vessels in their various directions, or into the spleen by entering at the hilum with the blood vessels, or spreading over the splenic capsule from the hilum.

In man, the fully developed gland is constantly found to lie in a transverse position, firmly fixed against the spine with the head engaged in the concavity of the first portion of the duodenum, while in many of the mammals, it is rather loosely placed between the layers of the mesentery of the small intestine and distributed over a large area.

Cells believed to be islet cells have been described as occurring in the gland tissue of all the various species in which the pancreas has been

studied. In the fishes, amphibians and reptiles, they occur in groups of a few cells only, and have a tubular structure; in birds and mammals, there is a greater differentiation of the cells and a well defined arrangement of the cells in the formation of the islets.

It has been well established that the pancreas is an organ which has developed from the duodenum, and in its embryologic development, the anlages first appear as buds on the duodenum. The anlages are multiple; in some animals as many as four have been found. They progress to a certain stage, independently of one another, between the folds of the primitive mesentery, to coalesce later and develop into the pancreas.

Embryology of the Pancreas in Man.—The pancreas in man develops from cells in the duodenum which differentiate and form two anlages in

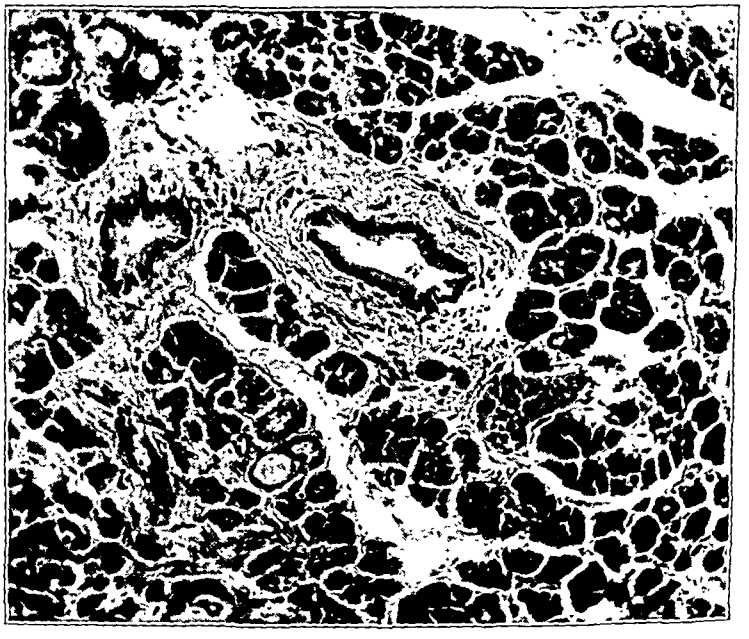

Fig. 4 (A129972).—Accessory pancreas, showing acini, ducts and islet, with increase in connective tissue.

the embryo of 3 or 4 mm. in length. The dorsal pancreatic anlage begins as an outpouching on the duodenum, the ventral pancreatic anlage as a grooved bud arising from the common bile duct at its juncture with the duodenum (Fig. 8). The growth of the dorsal pancreas is more rapid than that of the ventral. The anlages grow separately until by their circumrotation and growth around the inner aspect of the duodenum they meet posteriorly, where they coalesce and continue development in one mass in the dorsal mesentery. The body and tail grow upward and to the left so that they lie in the dorsal mesogastrium, posterior to the stomach. As the stomach and dorsal mesogastrium change position, the pancreas moves within the dorsal mesogastrium until its position is

transverse, when it becomes firmly fixed to the parietal peritoneum of the posterior abdominal wall.

The primitive outpouchings are lined with columnar epithelium similar to that in the duodenum. As the buds grow, the epithelium develops branching ducts ramifying the connective tissue. The main duct of the dorsal pancreas opens into the duodenum, while the main duct of the ventral pancreas opens into the common bile duct at the ampulla. When the dorsal and ventral anlages unite, the main duct of the ventral pancreas anastomoses laterally into the main duct of the dorsal pancreas. In this way, the main duct of the ventral pancreas with the distal half of the duct of the dorsal pancreas forms the duct of Wirsung, and the proximal half of the duct of the dorsal pancreas is the duct of San-

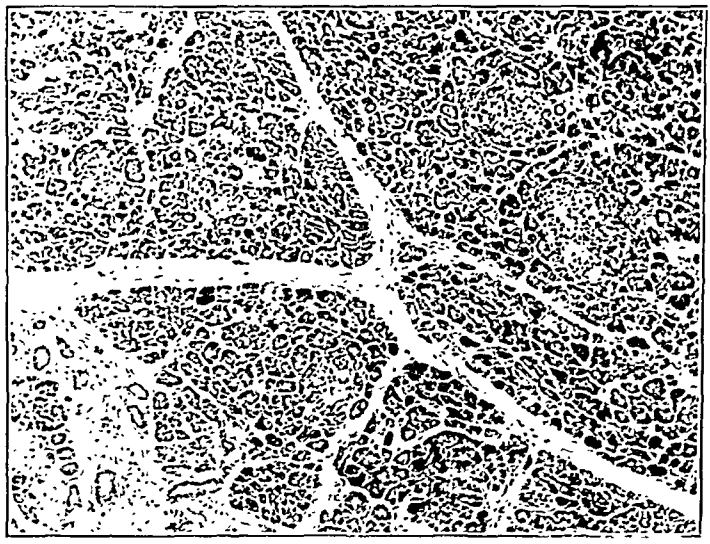

Fig. 5 (A130601).—Accessory pancreas, showing acini, small ducts and four islets.

torini. When the embryo is from 26 mm. to 33 mm. in length, and the tail of the pancreas extends well out into the dorsal mesogastrium, branching tubules can be seen throughout the gland. No acini or islets are to be seen at this stage, and there is no evidence of lobulations. The connective tissue forms the major portion of the organ. At the end of the branches of the main duct, the tubules have an enlarged bud. This bud branches and forms new tubules until the acini begin to form by several buds at the tip of each nodule. After the acini have begun to form throughout the gland, the islet cells appear in the connective tissue along the small ducts. Pearce [8] found masses of cells which he identi-

8. Pearce, R. M.: The Development of the Islands of Langerhans in the Human Embryo, Am. J. Anat. 2:445-455, 1902-1903.

fied as islet cells in an embryo of 54 mm. The connective tissue is derived from the mesodermal tissue of the dorsal mesentery.

In a general way, it may be said that each phase of the embryologic development of the pancreas in man, from the time the cells which form the anlages begin their differentiation in the wall of the duodenum until the gland becomes fixed in its transverse position, represents a mature development in a lower vertebrate. But, in contradistinction to this, all the variations in form which occur in the lower vertebrates are not represented in man.

SURGICAL CONSIDERATIONS

The normal conditions prevailing in the area where a mass of accessory pancreatic tissue is engrafted may differ greatly from those under which the normal gland exists, and for this reason, it is logical to presuppose that in the abnormal location in which these masses of accessory pancreatic tissue are found, they are more prone to inflammatory processes and malignancy. Therefore, in addition to the surgical and pathologic conditions usually found in the normal pancreas, there may be others resulting from the abnormal situation of the accessory pancreatic tissue.

Opie [3] has pointed out in the necropsy specimens studied by him the occurrence of chronic interstitial inflammation in accessory pancreatic tissue and Mayo-Robson [9] has reported a case found at operation. Warthin [1] reported two cases in which there was increased connective tissue, and in one of these there were also areas of localized fat necrosis in the surrounding tissue. Gibson [10] reported a case which he believed to be an acute pancreatitis.

The possibility that accessory pancreatic tissue may be the cause of carcinoma has been suggested by Eloesser [11] and others, but our only conclusive evidence is from Branham,[12] who reported a case of pyloric obstruction in which he performed a pylorectomy for a mass "2 inches long and 1 inch across. This was found, on microscopic examination by Professor Welch, to be a 'malignant adenoma' of the pylorus originating in misplaced pancreatic tissue."

It is possible that carcinoma of the duodenum, which is occasionally observed, originates in accessory pancreatic tissue. Such origin, how-

9. Mayo-Robson, A. W.: A Case of Chronic Pancreatitis Probably Starting in an Accessory Pancreas, Lancet **2**:1823-1825, 1905; Anatomy of the Pancreas in Relation to Its Diseases, Brit. M. J. **1**:1153-1161, 1908.

10. Gibson, C. L.: Accessory Pancreas in the Gastro-Intestinal Tract, Med. Rec. **82**:426-427, 1912.

11. Eloesser, L.: Die in den letzten 10 Jahren an der Heidelberger chirurgischen Klinik beobachteten Fälle von Pankreaserkrankungen Mitt. a. d. Grenzgeb. d. Med. u. Chir. **18**:195-294, 1908.

12. Branham, J. H.: Operative Treatment of Cancer of the Stomach, with Report of Six Partial Gastrectomies, Maryland M. J. **51**:144-148, 1908.

ever, cannot be established in any given case of carcinoma of the duodenum, as in all probability, the accessory pancreatic tissue if present will be unrecognizable. The histogenesis of carcinoma from these disconnected masses of tissue will be proved only by a careful study of a number of specimens in which all the pathologic changes can be demonstrated from the normal to a well defined carcinoma.

The tendency for intussusception in cases in which there is a tumor in the wall of the intestine has long been known. Benjamin [13] reports a case of obstruction of the intestine in which abdominal exploration revealed an intussusception of the jejunum. The intussusception was

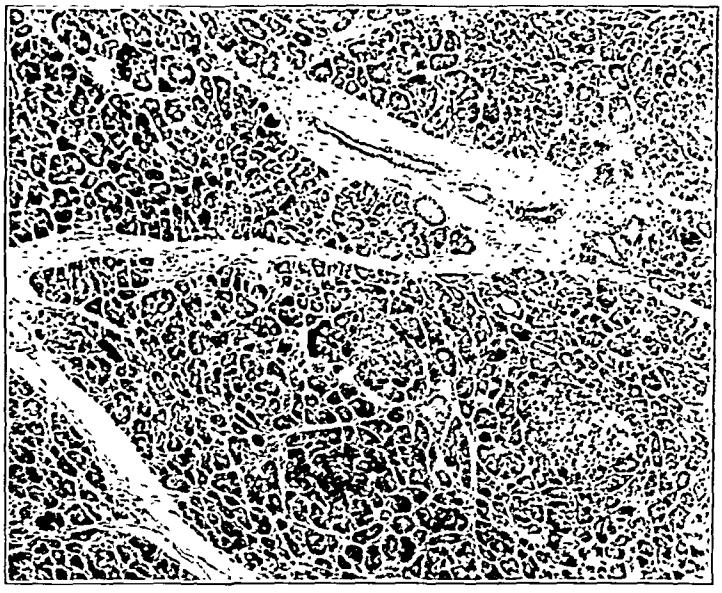

Fig. 6 (A130601).—Accessory pancreas, showing acini, ducts and two islets.

reduced and found to contain a tumor-like mass which proved to be an accessory pancreas. Several similar cases have been reported.

Diverticula of the intestinal wall with aberrant pancreatic tissue in the tip of the diverticulum have been reported by several observers who regarded the accessory pancreatic tissue as the cause of the diverticulum. In a few of these cases, the tip of the diverticulum, containing the inflammatory accessory pancreatic tissue, had become attached to the abdominal wall or to the intestine, and the band thus formed produced a loop-hole through which a coil of the small intestine passed, later to become obstructed and strangulated.

13. Benjamin, A. E.: Accessory Pancreas with Intussusception. Ann. Surg. **67**:293-298 (March) 1918.

DISCUSSION

Inasmuch as the collated studies of disconnected pancreatic tissue, recorded in the literature and supplemented by my own observation, have proved that these masses contain all the histologic units of the pancreas, that they have a blood supply, carry on a function independently of the pancreas, may become malignant, produce obstruction, intussusception and diverticula, the finding of this tissue is of more than academic interest.

Fig. 7 (A130601).—Oil immersion photomicrograph of acini, showing large zymogen granules in the cytoplasm of the apical portion of the acinic cells.

There does not appear to be an accepted theory as to the cause of accessory pancreatic tissue. Zenker [14] believed it to be an anomaly occurring very early in embryonic life by the formation of an additional diverticulum which develops into a single gland mass independently of the normal pancreas and, as the intestine grows longer, may be carried away a great distance. Glinski [15] attributes it to a failure of one or

14. Zenker, F. A.: Nebenpankreas in der Darmwand, Virchows Arch. f. path. Anat., **21**:369-376, 1861.

15. Glinski, L. K.: Zur Kenntniss des Nebenpankreas und verwandter Zustände, Virchows Arch. f. path. Anat. **164**:132-146, 1901.

more of the primitive anlages to coalesce with the main pancreas, which he believed developed chiefly from the ventral anlage.

Warthin states, "It is more probable that accessory pancreatic tissue is formed from lateral budding of the rudimentary pancreatic ducts as they penetrate the intestinal wall, the mass of pancreatic tissue thus formed being snared off and carried by the longitudinal growth of the intestine either upward or downward."

Accessory pancreatic tissue cannot be looked on as an anlage which has failed to coalesce with its codeveloping companion. If it were due to failure to coalesce, the masses would be large and would be found always in the duodenum, whereas, in fact, all the aberrant masses are small and the accessory tissue has been found in the stomach, duodenum,

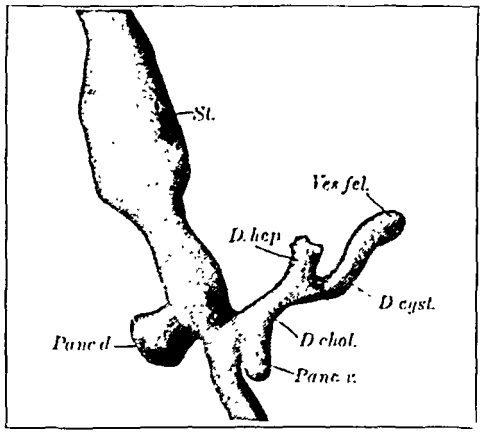

Fig. 8.—Reconstruction from a human embryo of 7.5 mm. (H.E.C. 256, Thyng, F. W.: Am. J. Anat. **7**:489-503, 1908), ×55; *D. chol.*, ductus choledochus; *D. cyst.*, ductus cysticus; *D. hep*, ductus hepaticus; *Panc. d.*, pancreas dorsale; *Panc. v.*, pancreas ventrale; *St*, stomach; *Ves. fel.*, vesica fellea.

jejunum and ileum, spleen, splenic capsule, mesentery, omentum and umbilicus. Nor can these masses of accessory pancreatic tissue be looked on as embryonic rests. They are adult tissues composed of differentiated cells having a function similar to the normal pancreas, and do not, in any way, conform to the theory of Cohnheim.

It is obvious that any hypothesis which may be advanced will of necessity be speculative, but after a review of studies of embryos recorded in the literature and the study I have made of sections of human embryos, I believe a reasonable explanation may be made, on developmental grounds, of the pancreas, stomach, intestines and mesentery. It is true that in the early stage of the development of the intestine and pancreas these structures resemble the intestine of the adult species of some of the lower orders of vertebrates, but we should be going far

afield to theorize on atavistic tendencies of the gland in explaining this abnormality. It should be borne in mind that this gland is changing its position and growing rapidly between the layers of the primitive mesentery from the time the anlages appear until the gland becomes firmly fixed to the parietal peritoneum of the posterior abdominal wall, and, at the same time, the stomach is developing, the intestine is rapidly increasing in length and pulling with it the mesentery so that there is a movement of these tissues in directions opposed to that of the pancreas.

In man, the primitive anlage which develops into the pancreas appears when the embryo is from 3 mm. to 4 mm. in length. At this time the primitive intestine is an almost straight tube and the buds are

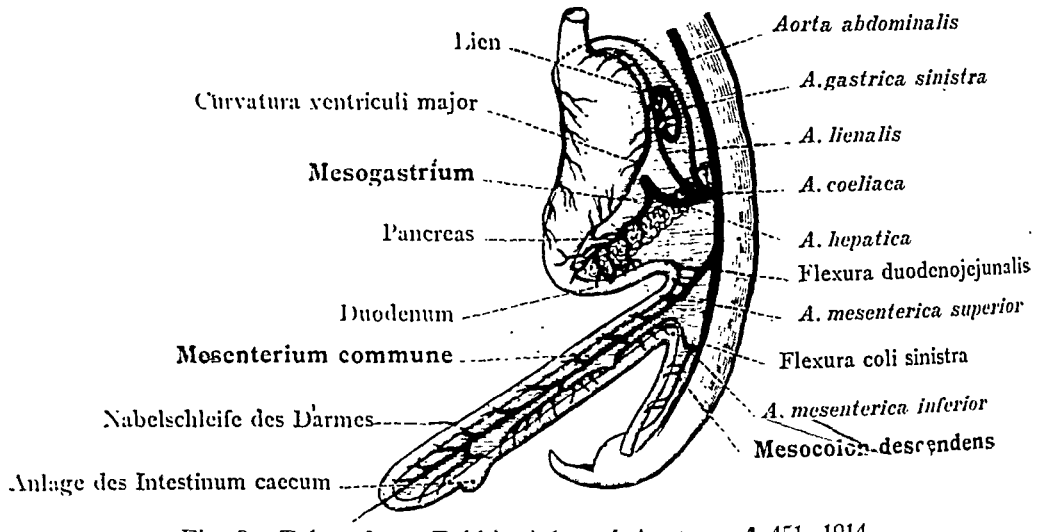

Fig. 9.—Taken from Toldt's Atlas of Anatomy **4**:451, 1914.

comparatively large. The growth of the pancreas, like that of the liver, suprarenals and kidneys, is very rapid, and it attains a comparatively large size before the intestine is markedly increased in length (Fig. 9). The dorsal and ventral pancreatic anlages conjoin when they meet posterior to the duodenum, and continue to grow upward and to the left.

During the partial circumrotation of the posterior and anterior pancreatic anlages until they coalesce to form one body, and during the migration of the body upward, its branching buds come in contact with the wall of the stomach, intestine or mesentery and may become engrafted thereon. Later, as the gland pulls away in its growth and movement, the small bud which has become attached to the wall of the intestine is cut off and becomes incorporated in the wall of the intestine as a graft. As the intestine grows in length, the graft becomes further separated from the pancreas, unless the graft happens to be in the stomach or duodenum.

While the gland is growing and changing its position in the primitive mesentery, the mesentery is also growing and pulling in the opposite direction. In this manner, a bud may become attached to the mesentery and be pulled away from the gland. This may explain the case reported by Warthin in which he found an accessory pancreas in the fat of the great omentum.

TABLE 1.—ACCESSORY PANCREAS: THIRTY-TWO CASES REPORTED IN THE LITERATURE SINCE 1904

Year	Reported by	Location	Microscopic Structure
1894	Biggs[2]	Pylorus	Pancreas
1901	Gandy and Griffon[16]	Duodenum	Pancreatic acini, ducts and islets
1903	Reitmann[17]	Ileum	Pancreatic acini, ducts and islets
1903	Reitmann[17]	Jejunum	Pancreatic tissue
1904	Turner[18]	Jejunum	Pancreatic acini and ducts
1904	Bize[19]	Diverticulum of intestine	Pancreatic acini and ducts
		Diverticulum of intestine	Pancreatic acini and ducts
1904	Müller[20]	Stomach	Pancreatic acini and ducts
1904	Alburger[21]	Jejunum	Pancreatic acini and ducts
1905	Lewis[22]	Small intestine	Pancreatic acini and ducts
1905	Mayo-Robson[9]	Duodenum	Pancreatic acini
1906	Thelemann[23]	Stomach	Pancreatic acini, ducts and islets
1907	Basselt[24]	Diverticulum of duodenum	Isolated bits of pancreatic tissue
1907	Basselt[24]	Diverticulum of duodenum	Isolated bits of pancreatic tissue
1908	Branham[12]	Stomach	Malignant adenoma of pancreatic tissue
1908	Clogg[25]	Diverticulum of intestine	Pancreatic tissue
1908	Thompson[26]	Diverticulum of intestine	Pancreatic tissue
1909	Reynier and Masson[27]	Pylorus	Pancreatic acini, ducts and islets
1909	Von Heinrich[28]	Jejunum	Pancreatic acini and ducts
1910	Weidman[29]	Splenic capsule	Pancreatic acini, ducts and islets
1911	Finkelstone[30]	Jejunum	Pancreatic acini and ducts
1912	Gibson[10]	Stomach	Pancreatic acini and ducts
1913	Carwardine and Short[31]	Jejunum	Pancreatic tissue
1913	Carwardine and Short[31]	Jejunum	Pancreatic tissue
1913	Kremer[32]	Jejunum	Pancreatic acini, ducts and islets
1913	Kremer[32]	Jejunum	Pancreatic acini, ducts and islets
1913	Kremer[32]	Jejunum	Pancreatic acini and ducts
1913	Kremer[32]	Jejunum	Pancreatic acini, ducts and islets
1913	Kremer[32]	Jejunum	Pancreatic acini, ducts and islets
1913	Kremer[32]	Duodenum	Pancreatic acini, ducts and islets
1918	Benjamin[13]	Jejunum	Pancreatic acini and ducts
1919	Nieuwenheijse[33]	Stomach	Pancreatic tissue

The buds from the primitive anlage contain the germinative cells from which all the histologic units of the gland can develop. So, in case the graft finds a suitable environment and lives, it will develop into a small accessory gland with all the function of the pancreas. The size to which the accessory pancreatic tissue grows is in proportion to the normal capabilities of development of the bud which becomes engrafted in the abnormal situation, and of the environment it finds therein.

16. Pancréas surnuméraire. Bull. et mém. Soc. anat. d. Paris **76**:451-453, 1901.

17. Zwei Fälle accessorischem Pankreas. Anat. Anz. **23**:155-157, 1903.

18. An Example of Accessory Pancreas. Lancet **2**:1566, 1904.

19. Etude anatomo-clinique des pancréas accessoires situés a l'extrémité d'un diverticule intestinal, Rev. d'orthop. **5**:149-159, 1904.

20. Accessory Pancreas in Posterior Wall of Stomach. Proc. Path. Soc., Philadelphia **7**:226, 1904.

21. Aberrant Pancreas in Wall of Jejunum, Proc. Path. Soc., Philadelphia **7**:227-229, 1904.

22. Note Upon an Accessory Pancreas in the Intestinal Wall, Med. & Surg. Rep. City Hosp., Boston, 1905, p. 172.

23. Ueber accessorisches Pankreas in der Magenwand, Deutsch. Ztschr. f. Chir. **85**:692-709, 1906.

24. Duodenal Diverticula, with Especial Reference to Diverticula Associated with Pancreatic and Biliary Ducts, Tr. Chicago Path. Soc. **7**:83-94, 1906-1909.

25. Acute Intestinal Obstruction, Lancet **1**:639-640, 1908.

26. Diverticula of the Intestinal Tract, Lancet **1**:860, 1908.

27. Sténose pylorique due à un lobule pancréatique aberrant, Bull. de l'Acad. de méd. **62**:100-106, 1909.

28. Ein Beitrag zur Histologie des sogen, akzessorischen Pankreas, Virchows Arch. f. path. Anat. **198**:392-401, 1909.

29. Aberrant Pancreas in the Splenic Capsule, Proc. Path. Soc., Philadelphia **13**:267, 1910.

30. Accessory or Aberrant Pancreas, with Report of a Case, J. A. M. A. **57**:1124-1125 (Sept. 30) 1911.

31. The Surgical Significance of the Accessory Pancreas, Ann. Surg. **57**: 653-657, 1913.

32. De la fréquence des pancréas accessoires, Arch. de méd. expér. et d'anat. path. **25**:595-602, 1913.

33. Over het pancreas accessorium, Nederlandsch Tijdschr. v. Geneesk. **26**: 2105-2113, 1919.

A SHORT ACCOUNT OF THE DEATHS OCCURRING IN THE GYNECOLOGIC SERVICE OF THE JOHNS HOPKINS HOSPITAL DURING THE YEAR 1919

HENRY N. SHAW, M.D.
Former Resident Gynecologist, the Johns Hopkins Hospital
BALTIMORE

In the course of a discussion of the results of the year's work, at a recent meeting of the gynecologic staff, it was suggested that we might, with profit, briefly analyze the histories of our fatal cases, inasmuch as one can often learn more from failures than from successes. At Dr. Cullen's request, I have prepared this short paper.

During the year 1919, 1,024 patients were admitted to the gynecologic service. Of this number, 793 were anesthetized. From the accompanying table, one can gather a clear idea of the number and character of the operations performed.

NUMBER AND CHARACTER OF OPERATIONS PERFORMED DURING THE YEAR 1919

Operation	Number	Operation	Number
Appendectomy	370	Exploratory laparotomy	12
Salpingectomy (double and single)	108	Nephrectomy	2
Salpingo-oophorectomy (double and single)	216	Nephrolithotomy	1
Hysterectomy	190	Nephropexy	2
Panhysterectomy	19	Cholecystostomy	14
Perineal repair	165	Repair of vesicovaginal fistula	8
Dilation and curettage	187	Hemorrhoidectomy	13
Amputation of cervix *	17	Removal of carcinoma of vulva	2
Trachelorrhaphy	3	Cauterization of cervix	10
Modified Gilliam suspension	77	Repair of complete perineal tear	8
Modified Coffey suspension	5	Lipectomy	4
Kelly round ligament suspension	1	Ureterotomy	2
Vaginal suspension	8	Suture of vesical neck	7
Ventral fixation	3	Resection of bladder	1
Miscellaneous	48	Colostomy	2
Pelvic drainage	30		
Radical cure of hernia	25	Total	1560

* Amputation of the cervix is rarely performed on patients during the child-bearing period.

From this table, it will be seen that in only two cases was the kidney suspended, whereas, in former years, from fifteen to twenty such operations were performed. A loose kidney is very common.

especially in thin individuals, but rarely gives rise to symptoms requiring operative interference. Formerly, it was deemed necessary to stitch up the kidney in those cases in which the renal discomfort was marked, but Dr. Hunner, and later, others have found that the pain in many of these cases is due to a ureteral stricture, and that after one or two ureteral dilations the discomfort disappears, and operation is rendered unnecessary.

Following out the suggestion of Dr. Kelly, made years ago, the gallbladder region is invariably palpated in every case in which there is the faintest suspicion of trouble in the right upper quadrant, just as soon as the abdomen is opened, because when a pelvic infection exists, the infection might readily be carried into the upper abdomen if the examination is deferred until the pelvic operation has been completed. It is interesting to note that among more than 400 laparotomies, in which this routine examination was made, in only fourteen cases, or about 3.5 per cent., was trouble found in the gallbladder.

REPORT OF DEATHS

CASE 1 (Gyn. No. 24669).—E. M., white, aged 31, was admitted to the hospital on Jan. 18, 1919. She had been married fourteen years, but had never been pregnant. The menstruation had been irregular for the last ten years, and for the last year there had been amenorrhea. During that period, however, she had had irregular bleeding five or six times, and the abdomen had gradually increased in size, in eighteen months, to that of a full term pregnancy. She had very little pain or discomfort, but had had a temperature varying from 100 to 103 F. A diagnosis of left ovarian cyst was made, and the patient was sent home for two weeks.

She was readmitted on March 5. The leukocyte count was 5,400, and hemoglobin 42 per cent.

The uterus, tubes, ovaries and appendix were removed by Dr. Hampton in two hours and five minutes. At operation a tuberculous peritonitis was found together with a ruptured right ovarian cyst.

On the evening of the fourth day the patient suddenly became cyanotic, had great difficulty in breathing, complained of severe pain in the chest, and died in a few minutes.

The clinical diagnosis was pulmonary embolism.

Necropsy was refused.

CASE 2 (Gyn. No. 24747).—S. S., colored, aged 37, was admitted on March 21, 1919. She had been married seven years, but had never been pregnant. She complained of occasional pain in the left side of the abdomen. She had a retroposition of the uterus, her hemoglobin was 65 per cent.

March 26, Dr. Wooley shortened the round ligaments according to the modified Gilliam method and removed the appendix. The operation lasted one hour.

On April 6 (the twelfth day), the patient suddenly collapsed and died in fifteen minutes.

Necropsy (No. 5869) revealed a thrombosis of the pelvic veins, pulmonary embolism with occlusion of the main branches of the pulmonary arteries of both lungs, and focal necroses in the liver.

CASE 3 (Gyn. No. 24894).—H. R., colored, aged 45, was admitted on May 9, 1919. She had an umbilical hernia which had gradually increased in size until the umbilical ring was 6 cm. in diameter. Her hemoglobin was 83 per cent., blood pressure was 204 systolic and 120 diastolic. Operation was performed, May 22, by Dr. Shaw for radical cure of the umbilical hernia. Duration of the operation was one hour and forty-five minutes.

On the tenth day she developed hesitancy of speech and the left side of the face was drawn. She went into coma at 6 p. m. and died at 7 a. m. on the following morning.

Necropsy (No. 5920) revealed a pulmonary embolus.

CASE 4 (Gyn. No. 24986).—L. G., white, age not obtained, admitted July 6, 1919, was suffering from a puerperal infection due to a criminal abortion performed nine days before. When the patient entered the hospital she was in coma and no history could be obtained. Operation was out of the question, and the patient died a few hours after admission.

The diagnosis was puerperal sepsis. This was a coroner's case.

CASE 5 (Gyn. No. 25153).—F. S., white, aged 35, admitted Sept. 3, 1919, had an inoperable squamous-cell carcinoma of the cervix. The erythrocyte count was 1,800,000, the hemoglobin 12 per cent. No operation was attempted. She died on September 9.

Necropsy (No. 5999) revealed extensive metastases to the pelvic, retroperitoneal and inguinal lymph glands. There were also cirrhosis of the liver, duodenal ulcer and pulmonary edema.

CASE 6 (Gyn. No. 26065).—M. C., colored, aged 64, was admitted July 31, 1919. The menopause had occurred twenty years before. She gave a history of vaginal bleeding for two months. The cervix was replaced by a friable cauliflower-like cancerous growth. The blood pressure was 150 systolic and 105 diastolic; hemoglobin was 70 per cent.

August 2, Dr. Hampton performed a panhysterectomy, and the tubes and ovaries were also removed. The duration of the operation was two hours. The patient did not recover consciousness, and died thirty-six hours after cancerous operation.

Necropsy (No. 5968) revealed double bronchopneumonia.

CASE 7 (Gyn. No. 25014).—M. P. W., white, aged 45, admitted July 2, 1919, had marked diastasis of the recti and an enormous accumulation of fat in the abdominal wall. She weighed 194 pounds.

July 5, Dr. Shaw performed a lipectomy and brought the rectus muscles together. The operation required one hour.

On the fifteenth day, the first day the patient was up, she suddenly became cyanotic, her respirations were labored, and she died fifteen minutes after the onset of the symptoms.

The diagnosis was pulmonary embolism.

Necropsy was refused.

CASE 8 (Gyn. No. 25194).—A G., white, aged 36, admitted Sept. 13, 1919, had become infected as the result of a criminal abortion. Her temperature was 104 F., leukocyte count 11,000, and hemoglobin 79 per cent. A blood culture showed *Streptococcus hemolyticus.*

Dr. Brady, on September 15, removed the infected placenta. The patient died on September 26. As this was a coroner's case, no necropsy was performed.

CASE 9 (Gyn. No. 25249).—A. T., white, aged 39, was admitted on Sept. 26, 1919. The patient had been operated on in a Detroit hospital three years before. The uterus, tubes, and ovaries were removed. At that time the rectum was injured and a rectal stricture developed. She was admitted on the surgical service of this hospital and the stricture was dilated. A general peritonitis followed. She was transferred to the gynecologic department for vaginal drainage. Her general condition did not improve. She died on October 13.

Necropsy was refused.

CASE 10 (Gyn. No. 25390).—M. L., white, aged 51, admitted, Oct. 27, 1919, had had backache, swelling of the ankles, and dyspnea for four years. Filling the pelvis and extending 5 cm. above the umbilicus was a large myoma. The leukocyte count was 4,400, the hemoglobin 25 per cent. The patient was transfused, and before operation the hemoglobin had risen to 40 per cent.

November 10, Dr. Cullen removed the myomatous uterus; the tubes and ovaries were also removed. The operation was a very difficult one, and a large amount of blood was lost. The hemoglobin two days later was 30 per cent.

The patient did well until the eleventh day, when she developed phlebitis of the left femoral vein. On Nov. 22, 1919, she suddenly collapsed. Her respirations grew shallow and ceased. Death was evidently due to pulmonary embolism.

Necropsy was refused.

CASE 11 (Gyn. No. 25450).—D. C., colored, aged 38, was admitted Nov. 10, 1919. In 1906, the patient was on the surgical service of the Johns Hopkins Hospital. Her gallbladder was drained and a stone removed from the common duct.

In 1915 she again entered the Johns Hopkins Hospital. At that time the gallbladder was removed and an appendectomy was performed. Prior to closing the abdomen, the operator examined the right kidney and found that it was large and contained a stone. Three months later she entered the gynecologic service. The phenolsulphonephthalein output at that time was 24 per cent. in the first hour. Two stones were removed from the right kidney.

One week before her admission in 1919, she had pain in the right kidney region with the formation of a painful tumor, 10 cm. in diameter at this point. The leukocyte count was 13,000; the hemoglobin was 45 per cent. The phenolsulphonephthalein output in two hours was nil, the urine was very foul and loaded with pus. The right ureter was catheterized and pure pus was obtained. Cultures from this yielded the colon bacillus. The roentgen-ray examination demonstrated large stones in both kidneys.

Operation was performed, November 22, by Dr. Shaw. Under local anesthesia with 0.25 per cent. procain, a right perinephritic abscess was incised and drained, and 500 c.c. of pus were obtained.

The patient was transfused on November 26, 500 c.c. of citrated blood being introduced. Uremia gradually developed and the patient died on December 8, sixteen days after the palliative operation.

Necropsy (No. 6079) revealed bilateral pyonephrosis and bilateral nephrolithiasis.

CASE 12 (Gyn. No. 25514).—A. J., white, boy, aged 2 days, was admitted, Dec. 29, 1919, with an imperforate anus. Operation was performed, December 29, by Dr. Cullen. As the rectum could not be located on perineal section, a temporary colostomy was performed. Death occurred thirty hours later.

Necropsy (No. 6108) revealed bilateral hydronephrosis. Both kidneys were in the pelvis. The ureters for the lower 4 cm. were impervious. The rectum was lacking. It would have been impossible for this child to live.

CASE 13 (Gyn. No. 25345).—M. H., white, aged 38, was admitted Nov. 10, 1919. The patient had been married six years and had never been pregnant. One brother had died of tuberculosis. For the last seven weeks she had noticed a gradually increasing abdominal tumor and during this time she had lost 25 pounds. She had had a rather obstinate constipation.

On examination we found an abdominal tumor, quite hard, irregular in outline, fairly movable, arising from the pelvis and extending 3 cm. above the umbilicus. It was thought to be a myoma.

On November 11 an exploratory laparotomy was performed by Dr. Cullen, but the loops of the bowels were everywhere so densely adherent to one another that it was impossible to reach the pelvic organs. Any attempt to free the adhesions would have been futile. The patient died six hours later.

Necropsy (No. 6049) revealed a tuberculous peritonitis, although no tubercles were to be seen at operation, even after very careful inspection.

CASE 14 (Gyn. No. 25505.)—A. S., white, aged 64, admitted Nov. 20, 1919, had had bloody urine for four years. Her hemoglobin was 46 per cent.; the leukocyte count was 14,000. The patient had a large papillomatous mass in the base of the bladder. It was about 6 cm. in diameter and occluded the left ureteral orifice. Microscopic examination of the tumor disclosed carcinoma.

No operation was performed, but radium was tried. The tumor, however, rapidly increased in size and became firmly fixed in the left pelvic wall. She died on December 26.

Necropsy was refused.

COMMENT

From the foregoing case reports, it will be noted that in a total number of 1,024 cases there were fourteen deaths. These deaths may be best analyzed by groups.

In three of the cases no operation was performed.

In Case 4 (Gyn. No. 24986), we had to deal with an infected criminal abortion. The woman was in a comatose condition when she entered the hospital and died very soon.

In Case 5 (Gyn. No. 25153), there was an inoperable carcinoma of the cervix, and in Case 14 (Gyn. No. 25505) an inoperable carcinoma of the bladder.

Group 1: Cases 12, 8, 9, 11 and 13 were desperate surgical risks. In Case 12 (Gyn. No. 25514), the child was only 2 days old, and had an imperforate anus. A colostomy was performed, and the child speedily succumbed. Necropsy showed that the ureters were impervious in their lower ends, and that as a consequence the pelves of both kidneys were dilated. No operation would have saved the child.

In Case 8 (Gyn. No. 25194), we had an infected criminal abortion with a temperature of 104 F. Nothing was done except to remove the infected placenta. Blood cultures showed *Streptococcus hemolyticus*.

In Case 9 (Gyn. No. 25249), the patient was referred from the surgical service with a general peritonitis following rupture of a rectal stricture. This patient was so ill on admission that nothing but vaginal drainage was attempted.

In Case 11 (Gyn. No. 25450), the patient was in a desperate condition and had practically no phenolsulphonephthalein output in two hours. Under local anesthesia, a right perinephritic abscess was opened, but uremia gradually developed and the patient died. The outlook in this case was practically hopeless.

In Case 13 (Gyn. No. 25345), an exploratory abdominal operation was performed. The intestinal loops were everywhere densely adherent, so much so, that the pelvic structures could not be located and the operation had to be abandoned. Necropsy showed a widespread peritoneal tuberculosis.

Group 2: In the following three cases, operation offered a reasonable chance of success.

In Case 1 (Gyn. No. 24669), the patient had a tuberculous peritonitis and a right-sided ovarian cyst. On the fourth day she suddenly became cyanotic, complained of severe pain in the chest, and died a few minutes later. The symptoms indicated pulmonary embolism.

In Case 6 (Gyn. No. 26065), the woman underwent an extensive operation for carcinoma of the cervix. She did not recover consciousness, and died thirty-six hours after operation. Necropsy revealed double bronchopneumonia.

In Case 10 (Gyn. No. 25390), the patient had a large myoma. On admission the hemoglobin was 25 per cent. After transfusion, it rose to 40 per cent. On the eleventh day after hysterectomy she had a phlebitis and on the twelfth day she suddenly collapsed and died with signs of pulmonary embolism.

Group 3: Three unexpected deaths occurred in cases in which the operations had been simple.

In Case 2 (Gyn. No. 24747), the patient entered the hospital on account of a retroposition. The round ligaments were shortened by the modified Gilliam method and the appendix was removed. She did well until the twelfth day when she suddenly collapsed and died in fifteen minutes. At necropsy thrombosis of the pelvic veins was found. There were pulmonary emboli with occlusion of the main branches of the pulmonary arteries in both lungs. Focal necroses were also found in the liver.

In Case 3 (Gyn. No. 24894), the patient had a large umbilical hernia, and a rather high blood pressure. On the tenth day after operation she developed a hesitancy of speech. The left side of the face was drawn. She went into coma the same evening and died the next morning. Necropsy disclosed a pulmonary embolus.

In Case 7 (Gyn. No. 25014), the patient had a great quantity of abdominal fat, also marked diastasis of the rectus muscles. A lipectomy was performed and the rectus muscles were approximated. On the fifteenth day, the first day that she was up, she suddenly became cyanotic and her respirations grew labored. She became unconscious, and died fifteen minutes after the onset of the attack. The symptoms were those of pulmonary embolism. A necropsy was refused.

The deaths in these three cases were undoubtedly due to thrombosis of the veins followed by the escape of emboli to the lungs.

CONCLUSIONS

The statistics recently published by Wharton and Hampton from this clinic clearly indicate that trauma of the large veins at operation is an important factor in the causation of thrombi, and Dr. Cullen in the operating room has been insistent that great care be taken not to injure the small veins beneath the rectus muscles. Simple traction on the under surface of the muscle with the finger when the abdomen is being opened will tear them, and troublesome oozing may follow. These veins should be promptly tied and any clotted blood removed. Dr. Cullen believes that the lack of this simple precaution is in some cases responsible for subsequent thrombosis of the pelvic veins.

With the increasing use of transfusion when the hemoglobin is low, and with the more delicate handling of the tissues, the operative mortality will be still further reduced, but even then a sudden fatality from an embolus will occasionally startle us and make us realize that we are not infallible and that we still have much to learn in the handling of abdominal cases.

It is the intention of the gynecologic department to publish a short account of the deaths occurring each year.

DIVERTICULUM OF THE FIRST PORTION OF THE DUODENUM *

ERNEST K. CULLEN, M.D.

DETROIT

The literature on diverticula of the duodenum has been so fully considered by Cole and Roberts [1] and by Case,[2] that I shall, without further comment, add this case to the list of those already reported.

REPORT OF CASE

History.—W. B., aged 40, married, was referred by Dr. William H. Weir of Cleveland, March 30, 1917, complaining of some discomfort in the right lower abdominal quadrant with associated nervousness and severe headaches. She had one child, 6 years old. In 1913, dilation, curettage and trachelorrhaphy were performed. A slight decensus of the uterus being present, a Smith-Hodge pessary was inserted.

Physical Examination.—The patient's general physical condition was good. There was some tenderness elicited on deep palpation over McBurney's point. There was slight decensus of the uterus. Examination of the eyes was negative. The urine was normal.

Treatment and Course.—Tonic treatment was prescribed and the patient soon showed marked improvement.

On May 26, 1920, the patient again consulted me. She stated that with the exception of some trouble with carious teeth one year before, her health had been good until eight weeks before this consultation. At that time she had an acute attack of "gastro-intestinal grip," and consulted my colleague, Dr. S. C. Hanna.

The onset of this attack was marked by severe vomiting, a rise of temperature to 102 F. and severe diffuse pain over the epigastric and gallbladder regions. There was no jaundice, but there was obstinate constipation. The pain which had persisted with some intermittence had assumed a boring-like character, most pronounced from three to four hours after meals, and was located just to the right of the median line. On light palpation, considerable tenderness was elicited, but no definite spasm was present. There was also tenderness to a less degree over the gallbladder area. The area of stomach tympany was not increased. There was very slight tenderness on deep palpation over McBurney's point.

The patient was referred to Drs. P. M. Hickey and William A. Evans for roentgenologic examination. Their report follows:

---

* Read before the Thirty-Third Annual Session of the Southern Surgical Association, Hot Springs, Va., December, 1920.

1. Cole, L. G., and Roberts, D.: Diverticula of the Duodenum, Surg., Gynec. & Obst. **31**:376 (Oct.) 1920.

2. Case, J. T.: Diverticula of Small Intestine Other Than Meckel's Diverticulum, J. A. M. A. **75**:1463 (Nov. 27) 1920.

Roentgenologic Report.—Survey of the chest shows the right and left lung fields clear, and the heart slightly enlarged. There is no disturbance of the mediastinal shadows. The stomach is of the extreme vertical type, shows good tone, the walls remaining strictly parallel during the examination. We are unable to fill the duodenal bulb by manipulation, with the patient in the erect position. Good single wave peristalsis starts at once on the ingestion of the meal. There is no evidence of an incisure.

Patient Examined Prone: The stomach is seen to be considerably dilated. There is marked two-cycle type of peristalsis, the waves being very deep and conspicuous. At times the duodenal bulb seems gigantic in its appearance,



Fig. 1.—Serial roentgenograms taken immediately following the ingestion of the barium meal, showing a large duodenal cap with some irregularity on its external aspect. Extending outward from this is the mass of barium (*A*), which represents the well defined diverticulum.

perfectly smooth, without evidence of distortion. The type of peristalsis, when considered in connection with the apparently normal bulb, would signify extragastric irritation. Serial plates will be made.

Survey at Five Hours: There is no evidence of a gastric retention. There is marked evidence of gaseous distention of the stomach and cecum. The barium is visualized in the ileum and is just beginning to fill the cecum.

Survey at Twenty-Four Hours: There is retention of the barium in a low, deformed cecum. The cecum is too low to permit of manipulation. The patient, however, refers her symptoms to the upper right quadrant. In this region

there is a mass of barium about the size of a hickory nut which seems to be sensitive to manipulation. At least, the area about this shadow is sensitive to pressure. Irregular outlining and relations of the colon are noted.

Examination at Forty-Eight Hours: There is still retention in the cecum. The cecum is elevated somewhat more than at the twenty-four hour survey. The transverse colon is ptotic, but can be elevated. The shadow noted above

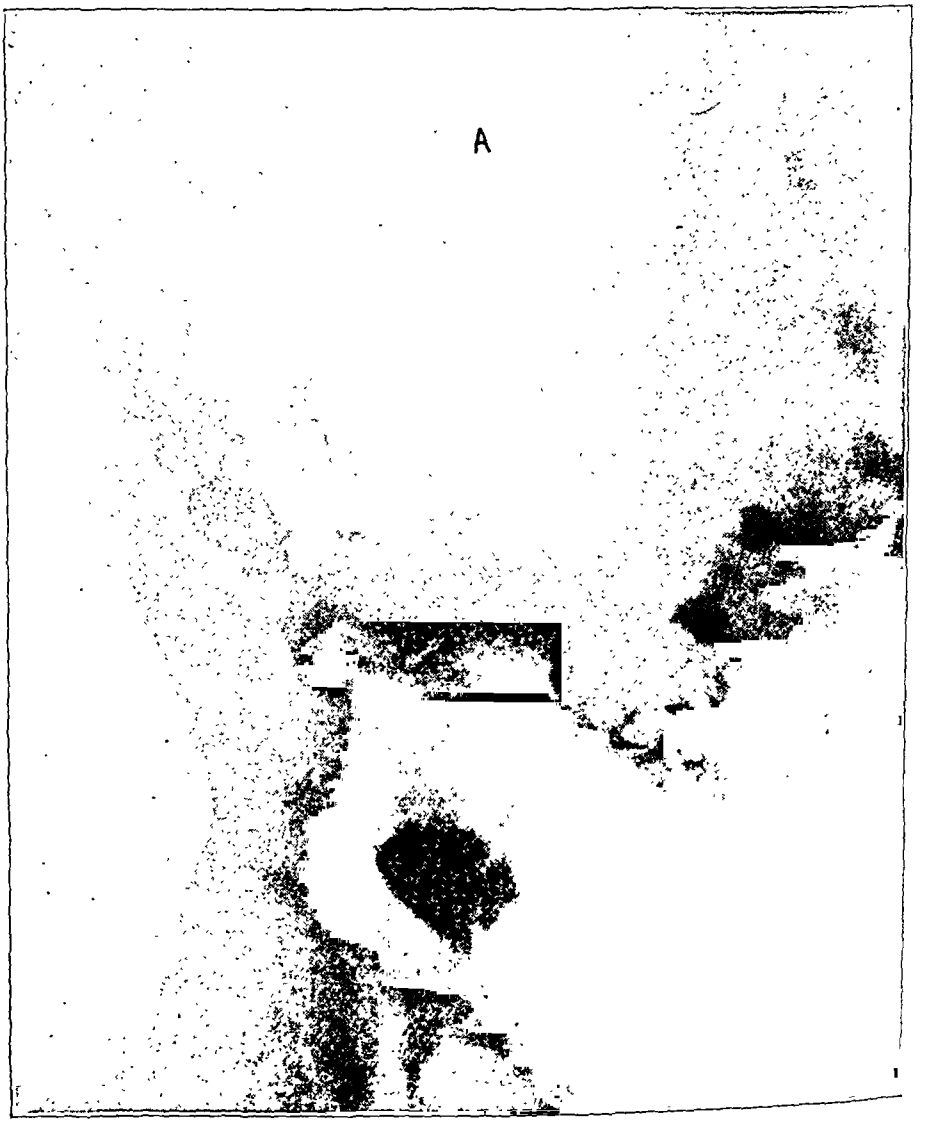

Fig. 2.—Roentgenogram taken twenty-four hours after ingestion of the barium meal, still showing retention in the diverticulum (*A*).

the colon in the upper right quadrant at twenty-four hours is still present. The mass is smaller and still sensitive to manipulation.

Plates of the urinary tract show no evidence of calculus. There is lumbarization of the first sacral segment, but there is no evidence that this has any clinical significance.

Serial plates (Fig. 1) made following the ingestion of the meal show the stomach in active peristalsis, without gastric defect. There is a large duodenal cap. This shows a little irregularity on the external aspect. There is a mass of barium extending out from the outer aspect of the duodenum, which seems to push farther to the right the second portion of the duodenum, without causing duodenal stasis. *The appearance is that of a diverticulum of the duodenum.*

A plate made at twenty-four hours (Fig. 2) shows the position of the cecum and the cecal stasis as described in the fluoroscopic findings. There is a mass of barium opposite the transverse process of the fourth lumbar segment on the right side. This was the mass which was described in the fluoroscopic notes and which was sensitive to manipulation.

Fig. 3.—Roentgenogram taken forty-eight hours after ingestion of the barium meal, still showing retention in the diverticulum (*A*).

A plate at forty-eight hours (Fig. 3) shows still the small mass of barium opposite the transverse process of the fourth lumbar segment on the right side. The cecum is emptying somewhat, and shows elevation. No doubt the shadow described on the twenty-four and forty-eight hour plates as lying opposite the fourth lumbar segment represents the shadow which was interpreted in the serial plates immediately following the ingestion of the meal as a diverticulum of the duodenum.

Conclusion: Duodenal diverticulum, disturbance in the position, outline and function of the cecum, probably secondary to adhesions.[3]

Operation.—The upper abdomen was opened through a right rectus incision. The stomach walls were found to be normal and the pyloric orifice unobstructed. The gallbladder, duodenum and gastrocolic omentum were involved in adhesions, but the gallbladder wall was not thickened nor were stones present. It was found that a small portion of the gastrocolic omentum had in turn become adherent to the anterior portion of the duodenum and the gallbladder. In separating the adhesions, the first portion of the duodenum was pulled upward, causing a distinct sacculation. After separation of the adhesions had been completed, the first portion of the duodenum was found to be considerably redundant. There was no evidence of duodenul ulcer or other diverticula.

Consideration of the patient's symptoms, the undoubted damage to the duodenal mucosa by the retention of food in the diverticulum and the possibility of adhesions' reforming, convinced me that the performing of a gastro-enterostomy would be the safest procedure. A posterior gastro-enterostomy was then performed. The appendix, which was atrophic, was not removed. Apart from discomfort resulting from infection of the abdominal incision, convalescence was uneventful.

Roentgenologic Examination.—This was made on Oct. 13, 1920, and the report follows.

Examination at 11 a. m.: The first portion of the barium to reach the stomach passed rather quickly out through the posterior gastro-enterostomy opening. The opening appeared to be in the middle third. We attempted to force the barium up into the duodenum, but at no time was this structure outlined. After a delay of ten minutes, and in several positions, there was still no duodenal filling. The gastric evacuation by way of the new opening was slow.

Examination at 1:45 p. m.: At least 80 per cent. of the barium meal had escaped from the stomach. There was no evidence that the barium was leaving by the normal route. The duodenum and cap were not well filled.

Examination at 4 p. m.: The stomach was practically empty, with apparent filling of the duodenal cap. The escaped barium had, in part, entered the large bowel.

A plate of the upper right quadrant at four hours following the ingestion of the meal showed outlining of the duodenal cap. There was evidence of a small amount of barium in the second portion of the duodenum.

Examination at Twenty-Two Hours: No barium was detected in the upper right quadrant.

Result.—A report from the patient on Dec. 1, 1920, states that she has been on an unlimited diet for several weeks, and is free from any epigastric pain or distress.

---

3. Following the ingestion of the barium meal, the pain was exaggerated, and the patient suffered considerable discomfort for seventy-two hours. A limited diet was prescribed, but little relief was experienced.

THE EFFECT ON THE KIDNEY OF VARIOUS SURGICAL PROCEDURES ON THE BLOOD SUPPLY, CAPSULE, AND ON THE URETERS *

STUART W. HARRINGTON, M.D.

ROCHESTER, MINN.

This experimental study of the kidney and ureter was undertaken to determine the effect produced on them by some of the common surgical procedures or by accidents to them during operations on other organs.

The problems studied have been classified into four series, and the phases investigated have been arranged in groups.

SERIES I.—The effect on the kidney and ureter of complete sudden occlusion of the ureter or of complete sudden occlusion of the ureter and the collateral venous circulation.

Group 1. Double ligation and section of the ureter (twenty-two experiments).

Group 2. Double ligation and section of one ureter and the collateral venous circulation (thirty-one experiments).

SERIES II.—The effect of occlusion of the various vascular radicals of the kidney.

Group 1. Ligation of the renal artery (five experiments).

Group 2. Ligation of one or more branches of the renal artery (sixteen experiments).

Group 3. Ligation of the renal vein (eight experiments).

Group 4. Ligation of one of the larger branches of the renal vein (two experiments).

SERIES III.—The effect on the kidney and ureter of trauma to the ureter.

Group 1. Clamping of the ureter (eleven experiments).

Group 2. Stripping of the ureter (six experiments).

Group 3. Anastomosis of the ureters (twenty-two experiments).

SERIES IV.—The effect of decapsulation of the kidney.

Group 1. Decapsulation of the kidney and wrapping it in omentum (thirteen experiments).

Group 2. Decapsulation of the kidney and wrapping it in omentum after ligation of the renal artery or branches of the renal artery (seven experiments).

---

* From the Section on Surgery, Mayo Clinic.

* Abridgment of thesis submitted to the Faculty of the Graduate School of the University of Minnesota in partial fulfilment of the requirements for the degree of Master of Science in Surgery, May, 1920.

METHOD OF EXPERIMENTATION

Dogs were used in all the experiments because of the similarity of the anatomy, and particularly of the physiology and blood supply to those of man. Each surgical procedure was carried out with the strictest observance of aseptic technic identical with that used on man. The dogs were anesthetized with ether, the abdomen shaved, and thoroughly cleansed with alcohol and benzin and two applications of 10 per cent. iodin. A straight upper right rectus incision was made in order to permit abdominal exploration and transperitoneal exploration of both kidneys and ureters. In many instances surgical procedures other than those on the kidney and ureter, such as gastro-enterostomy, partial resection of the stomach, cholecystectomy, fat transplantations, and so forth, were carried out in the study of other problems, but in no instance was a procedure undertaken which would influence the results of the problem at hand. The technic of the various surgical procedures is discussed briefly under each series of experiments. The peritoneum and fascia were closed with catgut and the skin with linen. The wound was sealed with collodion. The dogs were kept under the most favorable conditions for health.

SERIES I.—THE EFFECT ON THE KIDNEY AND URETER OF COMPLETE SUDDEN OCCLUSION OF THE URETER OR COMPLETE SUDDEN OCCLUSION OF THE URETER AND THE COLLATERAL VENOUS CIRCULATION

The first problem investigated was the effect produced on the kidney by sudden complete occlusion of the ureter and the factors concerned in the end-results. This problem has a practical significance as it is frequently necessary to ligate one of the ureters during the course of various surgical procedures on man, such as the removal of a malignant growth of the bladder or pelvis when it is impossible or does not seem advisable to make other disposition of the ureter. The ureter has been ligated almost with impunity in man although many textbooks of surgery differ as to the effect produced on the kidney.

Watson and Cunningham [1] state that complete total obstruction of the ureter does not cause hydronephrosis. Morris [2] states that sudden complete stoppage of the outflow of urine leads to rapid atrophy and ultimate disappearance of the affected kidney. Keyes [3] states that sud-

1. Watson, F. C., and Cunningham, J. H.: Diseases and Surgery of the Genito-Urinary System, Philadelphia, Lea and Febiger **2**: 1909.

2. Morris, H.: Surgical Diseases of the Kidney and Ureter, London, Cassell and Company, 1901 **2**:277.

3. Keyes, E. L.: Diseases of the Genito-Urinary Organs, New York, D. Appleton & Co., 1911, p. 852.

den complete obstruction of the ureter causes damming back of the urine on the kidney with acute renal congestion and a diminished secretion of the urine, and that this causes an increased intrarenal pressure. The congestion is exchanged for atrophy. Adami and Nicholls [4] state that complete obstruction to the outflow of urine leads to atrophy of the affected kidney.

Group 1. Double Ligation and Section of the Ureter (Twenty-Two Experiments).—In this group of experiments the operative procedure was practically the same. The appearance and relative size of the kidneys and ureters were determined by transperitoneal exploration; the intestines were packed off and the lower third of the ureters exposed. If one ureter was normal it was doubly ligated with linen and sectioned, then replaced behind the peritoneum (eighteen experiments). In two experiments the ureter was doubly ligated with catgut and sectioned. In two the ureter was ligated with catgut but not sectioned in order to demonstrate the necessity of using permanent suture material to tie off the ureter when complete occlusion is desired. The animals recovered from operation immediately, and their general health during the experiments was good. Eleven of the dogs were killed at desired intervals; five of the remaining nine died of distemper, two of sepsis from other operative procedures, and two as a result of accident. A complete necropsy was made on each animal (Table 1 and Figs. 1 to 8).

The primary effect on the kidney, resulting from ligation of the ureter, is shown in Experiment 20. There was a marked congestion and edema from the increased intrarenal pressure which partially obstructed the venous return by compression of the smaller capillaries. This pressure was at its maximum in about twenty-four hours and gradually decreased with the duration of the obstruction. Rosow [5] found an intrarenal pressure of 90 mm. in twenty-four hours, and of 6 mm. at the end of 279 days. The increased pressure soon produced a dilatation of the pelvis and ureter. The sequence of events was very regular but not uniform in all the animals with the same duration of obstruction.

The increased intrarenal pressure produced by obstruction to the outflow of urine next caused a dilatation of the pelvis of the kidney, a flattening of the renal papillae, and compression of the medulla. This process was well marked in seventy-two hours (Fig. 1). It was progressive and fairly uniform in the sequence with which the portions of the kidney were affected. First there was a definite thinning of the

4. Adami, J. G., and Nicholls, A. G.: The Principles of Pathology, Philadelphia, Lea and Febiger, 1909 **2**:770.

5. Rosow, N.: Harnleiterdruck bei Hydronephrose, Ztschr. f. Biol. **54**: 269-285, 1910.

renal parenchyma in the lateral portions of the kidney within ten days. The poles were next involved, showing a rather marked change in from fourteen to eighteen days. The median sagittal portion was the most resistant, and at twenty-one days considerable renal parenchyma remained (Figs. 2 and 3), while at four weeks or more only a very thin layer of renal parenchyma in scattered patches lining the sac remained. The interior of the kidney was partitioned off by columns of fibrous

TABLE 1.—SERIES I: THE EFFECT ON THE KIDNEY AND URETER OF COMPLETE SUDDEN OCCLUSION OF THE URETER OR OF THE COLLATERAL VENOUS CIRCULATION

Group 1: Double Ligation and Section of the Ureter (Twenty-Two Experiments)

Experiment	Animal	Date of Operation	Duration of Experiment, Days	Ureter Ligated	Necropsy	Pyonephrosis	Hydronephrosis	Dilatation of Capsular Veins	Condition of Kidney not Operated On	Reoperation: Contents of Sac Removed	Sac Refilled
1 (723)	B678	12/23/16	447	Right	121	..	Large	+	Hypertrophic		
2 (566)	C 95	8/10/17	217	Right	119	..	Large	+	Hypertrophic		
3 (43)	B732	1/20/17	153	Right	386	..	Large	+	Normal		
4 (290)	B901	3/26/17	102	Right	407	..	Large	+	Normal		
5 (724)	B655	12/23/16	47	Right	54	..	Large	+	Normal		
6 (727)	B679	12/23/16	40	Right	38	..	Large	+	Hypertrophic	1/12/17	+
7 (31)	B720	1/ 3/17	28	Left	62	..	Large	+	Normal	1/17/18	+
8 (97)	B767	2/10/17	20	Left	105	..	Large	+	Normal	2/17/17	+
9 (631)	C136	9/10/17	16	Plain catgut, right	530	+	Moderate	+	Normal		
10 (17)	B706	1/ 9/17	13	Left	16	..	Moderate	+	Normal		
11 (436)	C 12	6/ 4/17	12	Right	377	..	Moderate	+	Normal		
12 (592)	C115	8/24/17	11	Plain catgut, right	506	..	Moderate	+	Normal		
13 (51)	B740	1/27/17	10	Left	50	..	Moderate	+	Hypertrophic		
14 (18)	B707	1/ 9/17	9	Left	15	..	Moderate	+	Normal		
15 (14)	B703	1/ 6/17	7	Left	13	..	Small	+	Normal		
16 (442)	C 18	6/ 8/17	6	Right	370	..	Small	+	Hypertrophic		
17 (619)	C129	8/31/17	4	Right	511	..	Dilatation of pelvis and ureter	+	Normal		
18 (725)	B528	12/23/16	3	Right	577	..		+	Normal		
19 (284)	B872	3/17/17	3	Left	154	..		+	Normal		
20 (726)	B600	12/23/16	1	Right	576	..	Congestion and edema of entire kidney	+	Normal†		
21*(252)	B874	3/17/17	223	Plain catgut, left	49	..	Ureter, normal	..	Normal†		
22*(250)	B873	3/17/17	239	Left	48	..	Ureter, partially constricted, slight atrophy of kidney		Normal		

* Ligation without section.
† Kidney operated on normal also.

tissue radiating in a fanlike arrangement from the ureteral outlet (Fig. 4). These bands or columns contained the blood vessels which with their fibrous sheaths were relatively unaffected by the intrarenal pressure that caused atrophy of the renal parenchyma lying between them. These bands of fibrous tissue caused the lobulated appearance of the surface of the kidney. The renal vessels could be seen running through the lobular grooves.

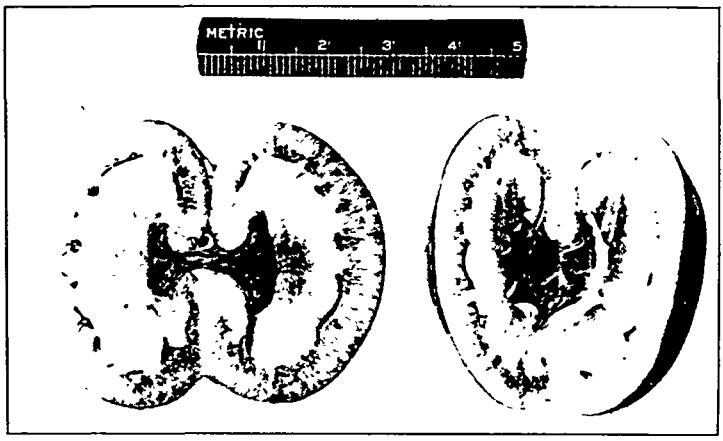

Fig. 1 (Series I, Group 1, Experiment 18 [B 528]).—Ligation of the ureter, three days' duration; beginning hydronephrosis, flattening of the renal papillae with depression and narrowing of the medulla.

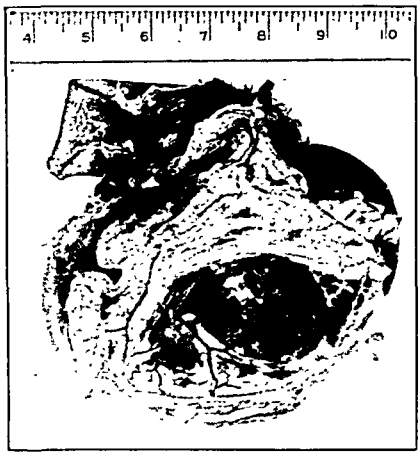

Fig. 2 (Series I, Group 1, Experiment 8 [B 767]).—Ligation of the ureter, twenty days' duration; hydronephrosis; marked dilatation of the capsular vessels over the surface of the hydronephrotic sac.

Fig. 3 (Series I, Group 1, Experiment 8 [B 767]).—Marked dilatation of the renal tubules and degeneration of the renal parenchyma of kidney shown in Figure 2.



Fig. 4 (Series I, Group 1, Experiment 7 [B 720]).—Ligation of the ureter, twenty-eight days' duration; hydronephrosis; marked destruction of the renal parenchyma in the lateral portions, considerable tissue remaining in the median sagittal portion.

The pelvis and ureter were markedly dilated and the capsular veins, radiating from the pelvis and passing over the surface of the sac, were simularly dilated. The degree of dilatation of these veins seemed to depend on the amount of hydronephrosis. The changes in the renal parenchyma followed the same progressive course as the gross changes. The entire tubule (most marked in the collecting tubule and Bowman's capsule) was dilated, and the convoluted tubule and the loop of Henle were compressed. Atrophy was noted first in the convoluted tubules, but was soon followed by the same process in all the tubular structures. The glomerular tufts, like the larger blood vessels in the medulla, were much more resistant than the renal parenchyma and remained for a long time after the tubular structure had disappeared (Figs. 6 and 7).

In Experiment 6 a kidney which had been obstructed for twenty-one days had the power to secrete urine. The dog was reoperated on the twenty-first day, and the contents of the hydronephrotic sac removed. The sac was found refilled with fluid when the dog was killed on the fortieth day. In Experiments 7 and 8 the hydronephrotic sacs were evacuated on the fourteenth and seventh days, respectively, after the ureteral ligation. The sacs had refilled when the dogs were killed on the twenty-eighth and twentieth days, respectively.

The contents of the hydronephrotic sacs were acid in reaction with a fairly constant specific gravity, ranging from 1.008 to 1.010. The fluid contained albumin and urea, and usually sediment containing blood, probably the result of the early congestion of the kidney. In one experiment at necropsy a marked infection (pyonephrosis) was present.

In Experiments 1 and 12 the ureters were ligated with No. 1 plain catgut. In Experiment 1 the dog died on the sixteenth day of peritonitis from leakage of the ureter; a pyonephrosis had developed in the kidney (Fig. 8). In Experiment 12 the dog was killed the eleventh day. The capsular veins were dilated and the ureter and pelvis enlarged but collapsed, showing evidence of a previous hydronephrosis. The contents of the sac had leaked out through the ureter. In both of these experiments the catgut ligature had been absorbed with leakage of the contents of the hydronephrotic sac. In Experiments 21 and 22, the ureters were ligated with No. 1 plain catgut but not sectioned. In Experiment 21, the dog died 223 days after operation. On examination of the ureter the site of the catgut ligature could not be found. There was no dilatation of the ureter and the kidney was normal. In Experiment 22 the dog was killed in 239 days because of an infection resulting from another operation. When the ureter was examined a slight constriction was found at the point of ligation, with some dilata-



Fig. 5 (Series I, Group 1, Experiment 4 [B 901]).—Ligation of the ureter, 102 days' duration; complete destruction of the renal parenchyma; large monolocular hydronephrotic sac.



Fig. 6 (Series I, Group 1, Experiment 3 [B 732]).—Ligation of the ureter, 153 days' duration; complete destruction of the renal parenchyma; connective tissue bands radiating from the pelvis.

Fig. 7 (Series I, Group 1, Experiment 3 [B 732]).—Marked atrophy of the renal parenchyma of kidney shown in Figure 6; glomeruli fairly well preserved.

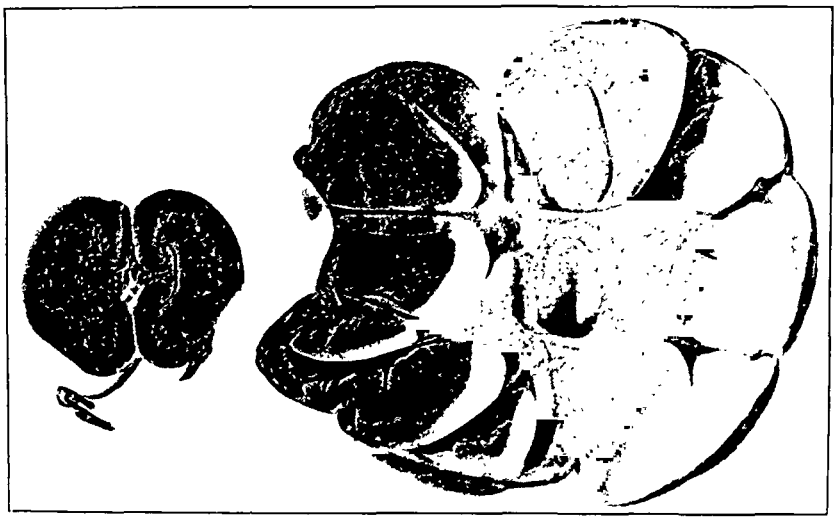

Fig. 8 (Series I, Group 1, Experiment 1 [B 676]).—Ligation of the ureter, 447 days' duration; enormous lobulated hydronephrotic sac; loculations due to connective tissue septums; complete destruction of the renal parenchyma.

tion of the ureter and pelvis about the constriction. The kidney was slightly atrophied; it weighed 33 gm. The opposite kidney weighed 37 gm.

Experiments 21 and 22 show the necessity of using permanent ligating material when complete obstruction of the ureter is desired, since absorbable ligatures may produce only partial constriction, and atrophy of the kidney may ensue.

The experiments on this group of dogs conclusively demonstrate these points:

1. Sudden complete occlusion of the ureter produces a hydronephrosis in every instance, the degree depending on the duration of the obstruction.

2. The hydronephrotic cavity is developed by dilatation of the pelvis and atrophy of the renal parenchyma and of the walls of the kidney.

3. The atrophic changes are quite uniform in distribution but vary in different animals.

4. The kidney is capable of secreting after thirty-six days of complete ureteral obstruction.

5. The renal blood vessels are the last structures to be affected by the increased intrarenal pressure.

6. In every instance the capsular veins are dilated, the enlargement depending on the amount of hydronephrosis.

Group 2. Double Ligation and Section of One Ureter and the Collateral Venous Circulation (Thirty-One Experiments).—The consistency with which dilatation of the capsular veins accompanied hydronephrosis led to the experiments in Group 2.

The collateral veins are ordinarily too small to be noticed in the normal kidney. The dilatation of these veins during the development of hydronephrosis and the observation that their enlargement seems to be dependent on the amount of renal distention brought up the question of whether they were one of the causative factors in the production of the hydronephrosis or whether they were the result of the hydronephrosis. In order to determine the point, the capsular blood supply was blocked by ligation at the same time as the ureter. Tuffier and Lejars,[6] working on the collateral circulation, ligated the renal vein and found that the renal venous blood is returned to the general circulation by four routes; (1) the inferior diaphragmatic and suprarenal vessels, (2) the ureteric and spermatic vessels, (3) the subcutaneous plexus of the lumbar region, and (4) the plexus which surrounds the last intercostal nerve, the ileo-inguinal nerve and the ileohypogastric nerve.

6. Tuffier and Lejars: Les veines de la capsule adipeuse du rein, Arch. de Physiol. norm. et path. **3**:41-57, 1891.

The technic of the operative procedure in Group 2 differed from that in Group 1 in that after the collateral circulation was carefully dissected out and the ureter freed, both were doubly ligated and sectioned so that the only blood entering or leaving the kidney was that which passed through the renal artery and vein. A definite hydronephrosis was produced in each instance, and its progress was essentially the same as those in Group 1 except that it developed more slowly and to a less degree than when the collateral circulation was left intact. Frequently

TABLE 2.—SERIES I: THE EFFECT ON THE KIDNEY AND URETER OF COMPLETE SUDDEN OCCLUSION OF THE URETER OR OF THE COLLATERAL VENOUS CIRCULATION

Group 2: Double Ligation and Section of One Ureter and the Collateral Circulation (Thirty-One Experiments)

Experiment	Animal	Date of Operation	Duration of Experiment, Days	Ureter Ligated	Necropsy	Pyonephrosis	Hydronephrosis	Adhesions Around Kidney Operated On	Condition of Kidney not Operated On
1 (581)	C697	8/12/18	453	Left	530	..	Large	0	Normal
2 (636)	C730	8/26/18	422	Left	493	..	Moderate	0	Normal
3 (35)	B724	1/13/17	337	Left	658	..	Moderate	+	Hypertrophic
4 (34)	B723	1/13/17	297	Left	592	+	Large	+	Hypertrophic
5 (430)	C 6	5/28/17	217	Right	677	..	Moderate	+	Hypertrophic
6 (582)	C106	8/28/17	200	Left	105	+	Large	+	Hypertrophic
7 (40)	B729	1/20/17	159	Left	396	..	Large	Omentum	Normal
8 (421)	B997	5/25/17	150	Right	555	..	Large	0	Normal
9 (32)	B721	1/13/17	149	Left	363	..	Large	0	Normal
10 (637)	C731	8/26/18	115	Left	702	..	Large	Omentum	Hypertrophic
11 (435)	C 11	6/ 1/17	68	Right	462	+	Large	+	Normal
12 (422)	B996	5/25/17	59	Right	436	..	Moderate	0	Normal
13 (410)	B990	5/14/17	35	Right	380	..	Moderate	0	Normal
14 (580)	C104	8/20/17	34	Left	527	+	Moderate	+	Normal
15 (563)	C 92	8/10/17	32	Left	518	+ ruptured	Large	Omentum	Normal
16 (522)	C 70	6/27/17	27	Left	475	..	Moderate	Omentum	Normal
17 (33)	B722	1/ 3/17	24	Left	52	..	Large	0	Hypertrophic
18 (483)	C608	7/15/18	23	Left	428	..	Moderate	0	Normal
19 (20)	B709	1/ 9/17	23	Left	37	..	Large	+	Normal
20 (525)	C 72	7/27/17	22	Left	490	..	Large	0	Normal
21 (420)	B996	5/25/17	19	Right	368	..	Moderate	+	Normal
22 (41)	B730	1/20/17	17	Left	51	..	Moderate	0	Normal
23 (502)	C627	7/22/18	17	Left	434	..	Small	0	Normal
24 (19)	B708	1/ 9/17	16	Left	40	..	Small	+	Normal
25 (411)	B991	5/14/17	10	Right	336	..	Small	+	Normal
26 (545)	C666	8/ 5/18	10	Right	457	..	Small	0	Normal
27 (545)	C 84	8/ 3/17	9	Left	468	..	Small	0	Normal
28 (522)	C646	7/29/17	8	Left	419	..	Small	0	Normal
29 (580)	C696	8/12/18	5	Right	463	..	Small	Omentum	Normal
30 (722)	C161	10/26/17	5	Right	582	..	Small	0	Normal
31 (503)	C628	7/22/18	4	Left	393	..	Small	0	Normal

the kidney and its hydronephrotic sac were found to be smaller than the opposite normal kidney, in spite of the distinct hydronephrotic cavity produced by the progressive atrophy of the renal parenchyma (Table 2 and Figs. 9 to 22).

In Experiments 1 and 4, of 453 and 297 days' obstruction, respectively, the hydronephrotic sacs were the largest in the group, but not so large as those in Group 1 in which the ureter alone was ligated. In

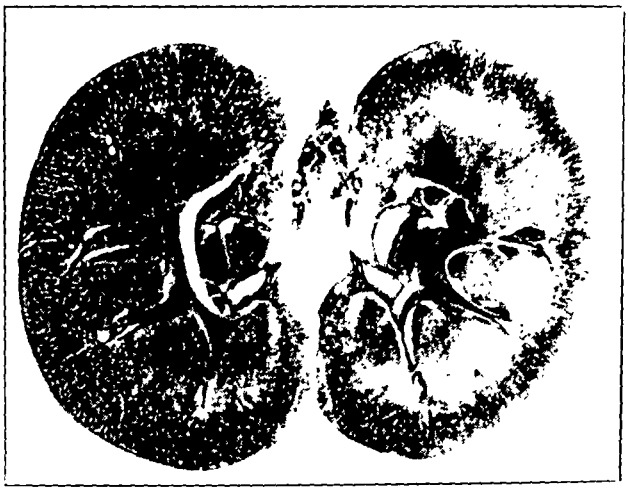

Fig. 9 (Series I, Group 2, Experiment 29 [C 696]).—Ligation of the ureter and collateral blood supply, five days' duration; small hydronephrosis; flattening of the renal papillae and thinning of the medulla.

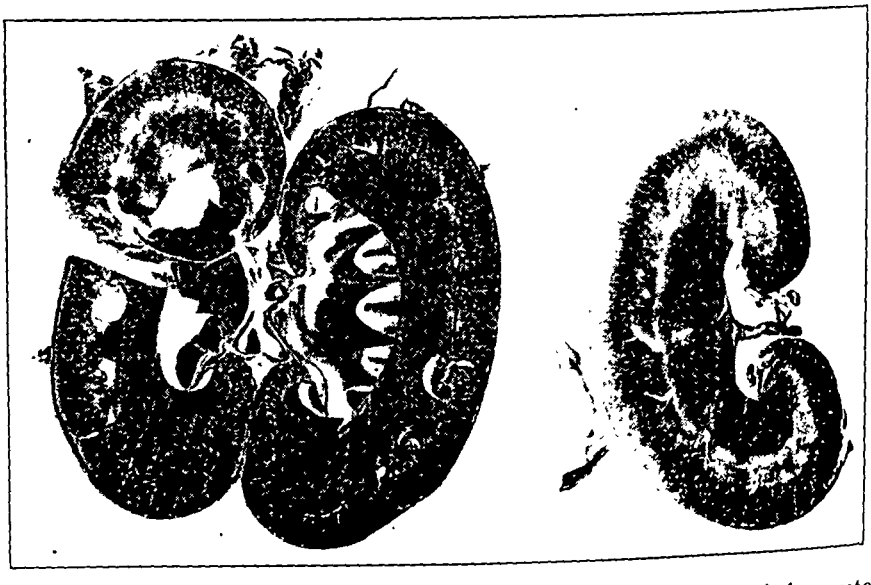

Fig. 10 (Series I, Group 2, Experiment 25 [B 991]).—Ligation of the ureter and the collateral blood supply, ten days' duration; small hydronephrosis; destruction of renal parenchyma in lateral portions, median sagittal portion still preserved; opposite kidney normal.



Fig. 11 (Series I, Group 2, Experiment 23 [C 627]).—Ligation of the ureter and the collateral blood supply, seventeen days' duration; small hydronephrosis; opposite kidney normal.

Fig. 12 (Series I, Group 2, Experiment 18 [B 608]).—Ligation of the ureter and the collateral blood supply, twenty-three days' duration; large hydronephrotic cavity with atrophy of the kidney; opposite kidney normal.

Fig. 13 (Series I, Group 2, Experiment 17 [B 722]).—Ligation of the ureter and the collateral blood supply, twenty-four days' duration; large hydronephrotic sac; atrophy of the kidney, particularly in the lateral portions; opposite kidney normal.

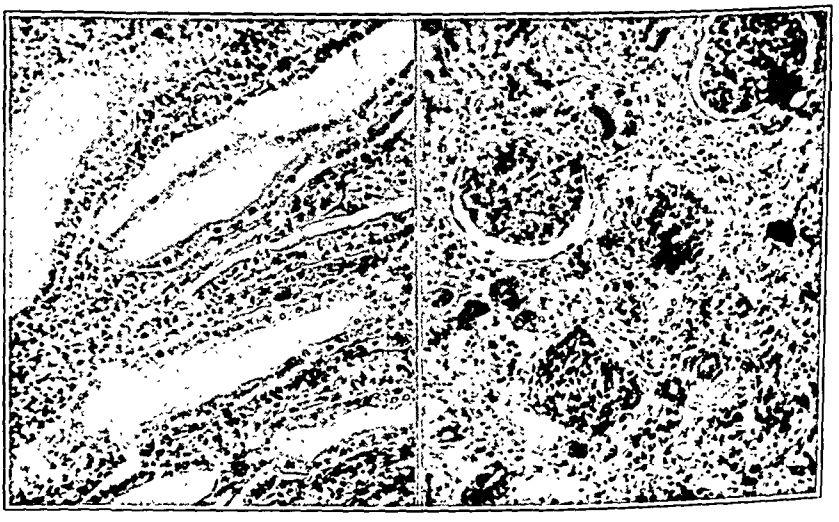

Fig. 14 (Series I, Group 2, Experiment 17 [B 722]).—Degeneration of the convoluted tubules; dilatation of the collecting tubules and glomeruli of kidney shown in Figure 13.

Fig. 15 (Series I, Group 2, Experiment 15 [C 92]).—Ligation of the ureter and the collateral blood supply, thirty-two days' duration; large pyonephrosis which ruptured, causing peritonitis and death.

Fig. 16 (Series I, Group 2, Experiment 13 [B 990]).—Ligation of the ureter and the collateral blood supply, thirty-five days' duration; no dilatation of capsular vessels; large hydronephrotic cavity with atrophy of the kidney; with hydronephrotic sac smaller than opposite normal kidney.



Fig. 17 (Series I, Group 2, Experiment 13 [B 990]).—Ligation of the ureter and the collateral blood supply, thirty-five days' duration; no dilatation of capsular vessels; large hydronephrotic cavity with atrophy of the kidney; kidney with hydronephrotic sac smaller than opposite normal kidney.

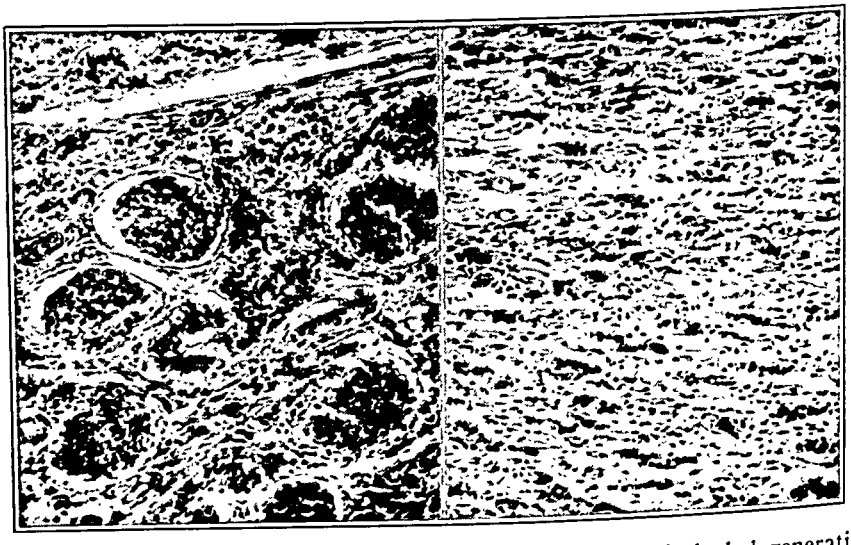

Fig. 18 (Series I, Group 2, Experiment 13 [B 990]).—Marked degeneration of tubules of cortex and medulla of kidney shown in Figures 16 and 17; glomeruli fairly well preserved in cortical portion proximal to the capsule.

Fig. 19 (Series I, Group 2, Experiment 9 [B 721]).—Ligation of the ureter and the collateral blood supply, 149 days' duration; no dilatation of the capsular veins; large hydronephrotic kidney with dilated tortuous ureter; hydronephrotic kidney lower than opposite normal kidney.



Fig. 20 (Series I, Group 2, Experiment 8 [B 997]).—Ligation of the ureter and the collateral blood supply, 150 days' duration; large hydronephrotic sac; complete destruction of renal parenchyma with persistence of connective tissue bands between the lobules; opposite kidney normal.



Fig. 21 (Series I, Group 2, Experiment 2 [C 730]).—Ligation of the ureter and the collateral blood supply, 422 days' duration; large hydronephrotic sac with almost complete destruction of the renal parenchyma except in the median saggital portion; opposite kidney normal.

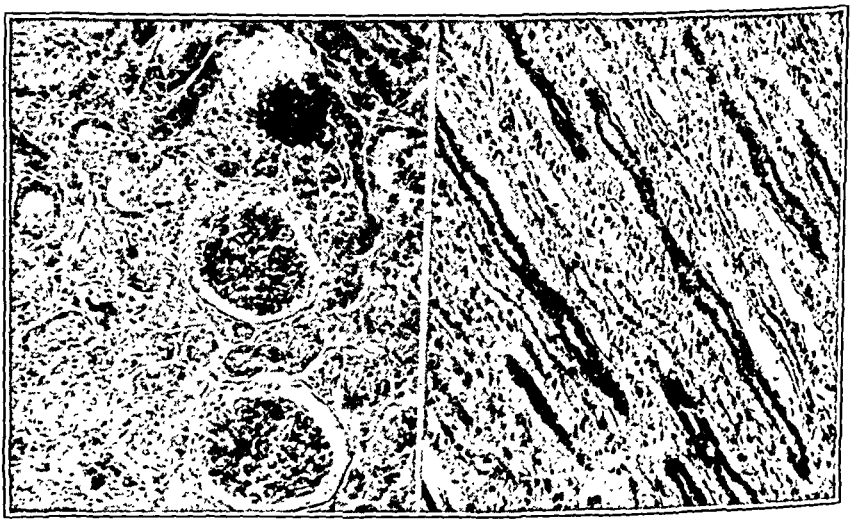

Fig. 22 (Series I, Group 2, Experiment 2 [C 730]).—Ligation of the ureter and the collateral blood supply, 422 days' duration; marked degeneration of the renal parenchyma of kidney shown in Figure 21; glomeruli well preserved.

Experiment 4, of 297 days' obstruction, the animal developed the largest hydronephrotic sac of the series. The kidney weighed 540 gm., and the sac contained 250 c.c. of purulent fluid. There were many adhesions about the kidney. In Experiment 1, of 453 days' ureteral obstruction, the kidney weighed 382 gm., and the sac contained 190 c.c. of clear fluid. The capsular vessels were not dilated.

In Experiments 2 and 3, of 422 and 337 days' duration, respectively, a moderate degree of hydronephrosis developed, the sacs containing 40 c.c. and 30 c.c. of fluid, respectively. No dilatation of the capsular vessels could be detected. In Experiment 2, the hydronephrotic kidney was smaller than the opposite normal kidney (Figs 21 and 22). The parenchyma was completely destroyed.

In Experiment 15 the animal appeared to be in good health the night of the thirty-second day but was found dead the next morning. At necropsy the cause of death was found to be the rupture of a large pyonephrotic sac which had produced a peritonitis. Many adhesions were found about the sac.

The animals in Experiments 4, 6, 11, 14, and 15 also developed pyonephrosis in the kidney operated on, which makes its incidence much higher in Group 2 than in Group 1, in which the collateral circulation was not interfered with.

In many of the animals there were adhesions of the omentum and of the structures adjacent to the kidney operated on, but not sufficient to have any bearing on the blood supply of the kidney.

From these experiments these conclusions may be drawn:

1. Hydronephrosis develops in the kidney of a dog following the ligation of one ureter and of the collateral blood supply.

2. The hydronephrotic sac is smaller and develops more slowly if the collateral circulation is intact.

3. Pyonephrosis is more common if the collateral circulation has been ligated.

4. Progressive atrophic changes occur in the kidney in the same sequence as when the ureter alone is ligated.

5. Ligation of the ureter does not affect the general health of the dog, since ten animals lived more than 100 days and two more than 400 days before being killed.

In summarizing the observations made in Groups 1 and 2 of Series I, it is important to note that after the outflow of urine is obstructed by ligating the ureter the normal secretion of urine continues until the ureter and pelvis of the kidney are completely filled; after that, urinary secretion takes place under the abnormal condition of back-pressure

from the damming up of urine in the pelvis of the kidney, which immediately dilates because its walls are elastic and not capable of resisting this increased intrapelvic pressure. The secreting power of the kidney is greatest at the time of ligation of the ureter, gradually diminishing in direct proportion to the duration of the obstruction, as the increased intrapelvic pressure causes a compression of the renal parenchyma by flattening of the pyramids and thinning of the medulla and cortex and a damming back of urine in the tubules. This exerts pressure directly on the cells lining the tubules and results in decreased nutrition and atrophy of the renal parenchyma. The increased intrapelvic and intrarenal pressures cause a compression of the small venous capillaries where only low pressure obtains, thus partially obstructing the venous return. This produces a congestion and edema of the kidney, but does not completely obstruct the venous return, and blood continues to pass from the kidney through the renal vein although the amount is greatly diminished, and the glomerulus is the last renal structure to be destroyed. The partial obstruction of the venous return affects the renal parenchyma and secretory power of the kidney in two ways. It decreases the amount of blood passing through the kidney and consequently the amount of secretion possible. Likewise the amount of nutrition carried to the cells of the parenchyma must be diminished. Partial obstruction of the venous return is relieved in two ways, first, by dilatation of the capsular veins, and second, by absorption from the medullary portion of the kidney, which is in inverse proportion to the destruction of the renal parenchyma. Dilatation of the capsular veins is caused by increased intrarenal pressure and is secondary to the production of hydronephrosis, since a hydronephrotic sac develops when the collateral circulation is ligated. The partial compensation of the venous return by the dilatation of the capsular vessels permits a greater secretory activity of the kidney because of the increased blood supply and nutrition and results in a larger and more rapidly developing hydronephrosis, which in turn causes more speedy destruction of the parenchyma than is found when the collaterals are ligated. The production of hydronephrosis is dependent on the amount of resistance afforded by the pelvis to the increased intrapelvic pressure incident to the secretory activity, which is variable, but greatest at the time of obstruction, and gradually diminishes so that in four weeks no secretion is demonstrable. It is possible that this may be the explanation of the difference in the results obtained in experimental investigations in animals and the clinical observations noted in man; that is, in man the collateral venous circulation is practically negligible, and the pelvis and capsule of the kidney are more resistant. It seems that if it were possible to enclose the pelvis of the kidney and the ureter in a plaster-of-Paris cast and completely obstruct

the outflow of urine, the increased intrapelvic pressure would become so great that it would stop all secretory activity and result in atrophy of the kidney.

SERIES II. THE EFFECT OF OCCLUSION OF THE VARIOUS VASCULAR RADICALS OF THE KIDNEY

The study of the results of ligation of the various vascular radicals of the kidney was undertaken with the view of determining the ultimate effect on the renal parenchyma and whether or not a collateral venous circulation would be established. It was shown by Bowman,[7] in 1842, that the arterial radicals of the kidney were end arteries, but Hyrtl,[8] in 1882, was first to point out that there was no anastomosis between the branches of the renal arteries. These facts are often lost sight of by surgeons in various surgical procedures upon the kidney, as mentioned by Brödel,[9] in 1901.

Series II comprises four groups. The experiments in Groups 1 and 2 pertain to the arterial blood supply, and those in Groups 3 and 4, to the venous supply. The operative procedures were essentially the same in the four groups except that different vessels were ligated.

Group 1. Ligation of the Renal Artery (Five Experiments).—In this study it was my purpose to determine: (1) the results produced on the kidney, (2) whether or not a collateral blood supply would be established, and (3), whether or not the omentum when wrapped about a decapsulated kidney would furnish sufficient blood to continue the function of the kidney.

After the kidney was exposed, the renal artery was carefully dissected from the perirenal fat and doubly ligated and sectioned. As shown in Table 3, the renal artery alone was ligated in three dogs; the artery was ligated and the kidney decapsulated and wrapped in omentum in two.

Sudden complete occlusion of the renal artery by ligation resulted in a gradual symmetric atrophy of the entire kidney. In Experiments 1, 4, and 5, collateral arterial anastomosis was not formed. In Experiments 2 and 3, of sixteen and ten days' duration, the kidney was wrapped in omentum, but this had no effect on the degree of atrophy of the kidney (Figs. 23, 24 and 25).

---

7. Bowman, W.: On the Structure and Use of the Malpighian Bodies of the Kidney, with Observations on the Circulation Through That Gland, London. Taylor, 1842.

8. Hyrtl, J.: Lehrbuch der Anatomie des Menschen, mit Rüchsicht auf physiologische Begründung und praktische Anwendung. Vienna, 1882, **1**:834, quoted by Brödel.

9. Brödel, M.: The Intrinsic Blood Vessels of the Kidney and Their Significance in Nephrectomy. Bull. Johns Hopkins Hosp. **12**:10-13, 1901.

From these five experiments it is evident that (1) the renal artery is the only source of blood supply to the kidney, furnishing both nutritional and functional blood, and is a strict end artery; (2) a collateral arterial anastomosis is not formed after ligation of the renal artery, and (3) wrapping the kidney in omentum after decapsulation and ligation of the renal artery does not produce arterial anastomosis in order to supply the renal parenchyma and therefore has no effect on the development of atrophy.

Group 2. Ligation of One or More Branches of the Renal Artery (Sixteen Experiments).—In man it is frequently necessary to ligate an aberrant vessel passing to the lower pole of the kidney, causing an intermittent obstruction to the outflow of urine and producing a hydronephrosis.

In sixteen animals after the kidney was exposed, the branches of the renal artery were carefully dissected free from perirenal fat and one or more doubly ligated and sectioned (three to 526 days' duration) with

TABLE 3.—SERIES II: THE EFFECT OF OCCLUSION OF THE VARIOUS VASCULAR RADICALS OF THE KIDNEY

Group 1: Ligation of Renal Artery (Five Experiments)

Experiment	Animal	Date of Operation	Duration of Experiment, Days	Renal Artery Ligated	Decapsulation of Kidney and Wrapping in Omentum	Necropsy	Kidney Tissue Pale and Degenerating	Collateral Arterial Circulation	Atrophy of Kidney Oper. On	Wt. of Kidney Oper. on. Gm.	Adhesions Around Kidney Operated On	Wt. of Kidney Not Oper. On Gm.
1 (190)	B828	3/ 5/17	31	Left	...	214	+	0	+	10	.....	40
2 (99)	B769	2/10/17	16	Left	+	90	++++	0	+++	18	Omentum	27
3 (53)	B742	1/27/17	10	Left	+	53	+++	0	++	14	Omentum	26
4 (242)	B869	3/16/17	8	Left	...	173	+	0	+	30	.....	45
5 (490)	C 47	7/ 9/17	4	Right	...	419	+	0	+	38	.....	42

the view of determining as accurately as possible what may be expected in man if for any reason the same procedure is necessary. In the dog there are usually four branches of the renal artery, two to the anterior surface and two to the posterior surface. The anterior vessels are the larger; they supply the anterior two thirds of the kidney; the smaller posterior branches supply approximately the posterior third. They usually divide just inside the hilum into two smaller branches, one to each pole. For convenience of description these vessels have been termed anterior superior and inferior, and posterior superior and inferior, the areas of the kidney to which they pass being designated quadrants according to the vessel. This division on the basis of the distribution of the arterial branches is not accurate since the posterior branches supply less kidney tissue than the anterior vessels, and there is also a variation in the size of the superior and inferior branches, the size of the vessel being in accordance with the area supplied.

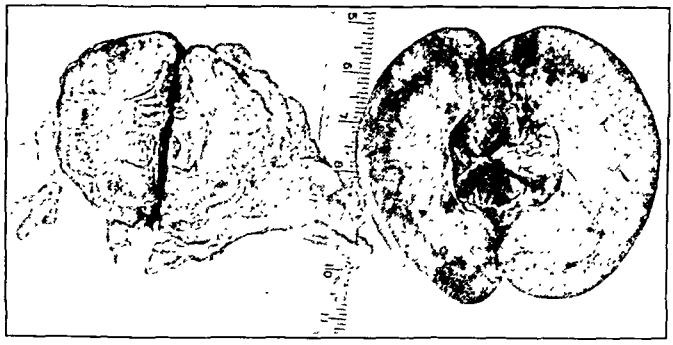

Fig. 23 (Series II, Group 1, Experiment 2 [B 769]).—Ligation of the left renal artery, kidney wrapped in omentum, sixteen days' duration; atrophy of the entire kidney which weighed 10 gm. Wrapping kidney in omentum did not affect the result.

Fig. 24 (Series II, Group 1, Experiment 2 [B769]).—Section of kidney shown in Figure 23; thrombosis of kidney vessels.

Fig. 25 (Series II, Group 1, Experiment 2 [B769]).—Section of kidney shown in Figure 23; amyloid degeneration of the renal parenchyma of the cortex and medulla.

Immediately following ligation of a branch of the renal artery there was marked congestion of the portion of kidney supplied by that vessel, and a bluish discoloration of the cortex with a sharp line of demarcation was produced. A linen thread was sutured accurately around the margin of this area so that it would be possible to determine whether or not the circulation in any part of the area was later restored and what the ultimate fate of this portion of the renal parenchyma was (Table 4, and Figs. 26 to 32).

TABLE 4.—SERIES II: THE EFFECT OF OCCLUSION OF THE VARIOUS VASCULAR RADICALS OF THE KIDNEY

Group 2: Ligation of One or More Branches of the Renal Artery (Sixteen Experiments)

Experiment	Animal	Date of Operation	Renal Artery Ligated	Branches of Renal Artery Ligated				Duration of Experiment, Days	Decapsulation of Kidney and Wrapping in Omentum	Necropsy	Atrophy of Kidney			
				Anterior Superior	Anterior Inferior	Posterior Superior	Posterior Inferior				Anterior Superior Quadrant	Anterior Inferior Quadrant	Posterior Superior Quadrant	Posterior Inferior Quadrant
1 (273)	C444	4/29/18	Right	+	..	..	+	526	+	464	+	..	..	+
2 (442)	C569	7/ 1/18	Right	..	..	..	+	464	..	465	..	..	..	+
3 (398)	C529	6/17/18	Right	..	..	+	+	...	..	...	..	..	+	+
			Left	+	..	+	..	348	+	261	+	..	+	..
4 (265)	C438	4/22/18	Right	..	..	+	+	325	+	93	..	..	+	+
5 (331)	C477	5/20/18	Right	..	+	+	+	43	..	326	..	+	+	+
6 (364)	C505	6/ 3/18	Right	+	..	+	..	...	..	...	..	..	+	..
			Left	..	+	+	+	38	+	347	..	+	+	+
7 (274)	C445	4/29/18	Right	+	+	..	+	...	..	...	+	+	+	+
			Left	..	..	+	..	23	..	261	..	..	+	..
8 (235)	C412	4/ 4/18	Right	..	..	+	+	15	+	220	..	..	+	+
9 (291)	C456	5/ 6/18	Right	+	+	..	..	...	..	...	+	+	..	..
			Left	+	+	..	..	14	..	258	+	+	..	..
10 (236)	C413	4/ 8/18	Right	..	..	..	+	11	..	218	..	..	..	+
11 (257)	C430	4/15/18	Right	+	+	..	..	10	..	230	+	+	..	..
12 (329)	C476	5/20/18	Left	+	+	..	..	7	..	271	+	+	..	..
13 (256)	C429	4/15/18	Right	..	..	+	+	4	..	219	..	..	+	+
14 (225)	C402	4/ 4/18	Right	+	+	..	..	4	..	180	+	+	..	..
15 (224)	C401	4/ 4/18	Right	..	..	+	+	4	..	179	..	..	+	+
16 (363)	C504	6/ 3/18	Right	..	..	+	+	...	..	...	..	..	+	+
			Left	..	..	+	..	3	..	283	..	..	+	..

These experiments show quite conclusively that (1) ligation of any branch of the renal artery causes atrophy of the area of renal parenchyma supplied by it; (2) each branch entering the kidney carries functional and nutritional blood to its respective area, and (3) there is no anastomosis between any of the branches of the renal artery.

Group 3. Ligation of the Renal Vein (Eight Experiments).—This phase of the problem was studied in order to determine (1) the results produced on the kidney; (2) whether or not a collateral venous circulation would be established and if so of what veins it would be comprised, and (3) whether or not this collateral venous circulation would be capable of assuming the function of the renal vein and of maintaining a functionating kidney.

Fig. 26 (Series II, Group 2, Experiment 16 [C 504]).—Ligation of the posterior superior branch of left renal artery and of the posterior superior and inferior branches of the right renal artery, three days' duration; degeneration of the posterior poles and areas supplied by these branches.

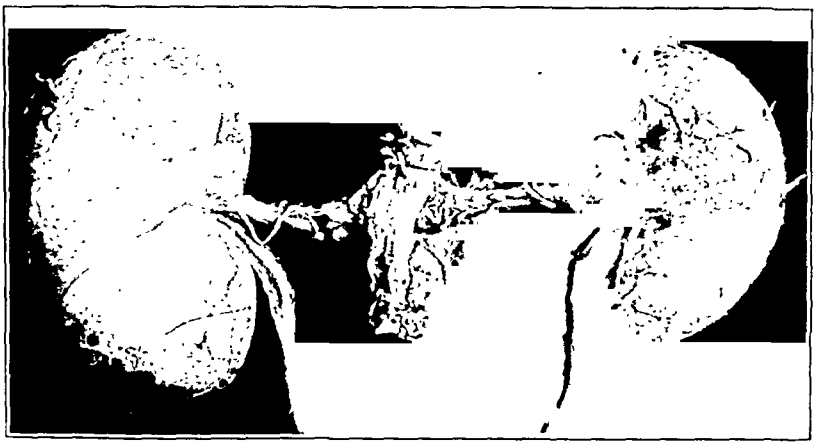

Fig. 27 (Series II, Group 2, Experiment 11 [C 430]).—Ligation of the anterior, superior and inferior branches of the right renal artery, ten days' duration; atrophy of the anterior pole of the right kidney; left kidney normal.

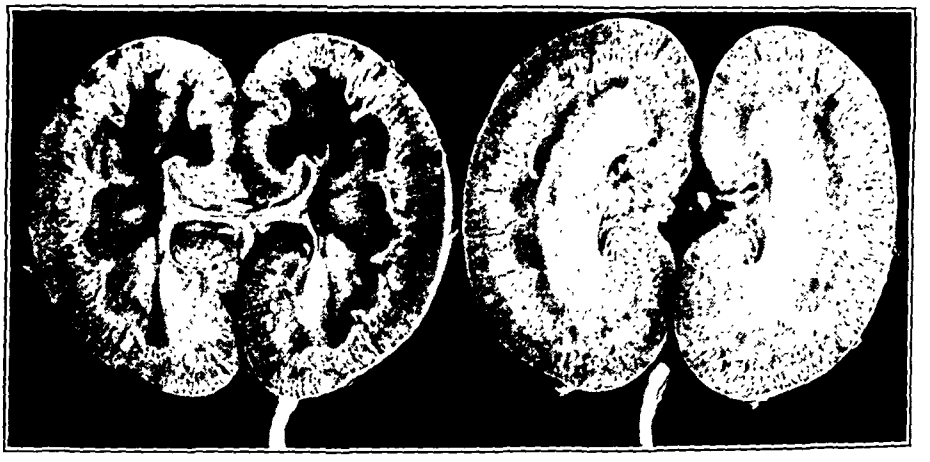

Fig. 28 (Series II, Group 2, Experiment 11 [C 430]).—Ligation of the anterior, superior and inferior branches of the right renal artery, ten days' duration. Atrophy of the anterior pole of the right kidney. Left kidney normal.

Fig. 29 (Series II, Group 2, Experiment 10 [C 413]).—Ligation of the posterior inferior branch of the right renal artery, eleven days' duration; atrophy of the renal tissue supplied by this branch; left kidney normal.

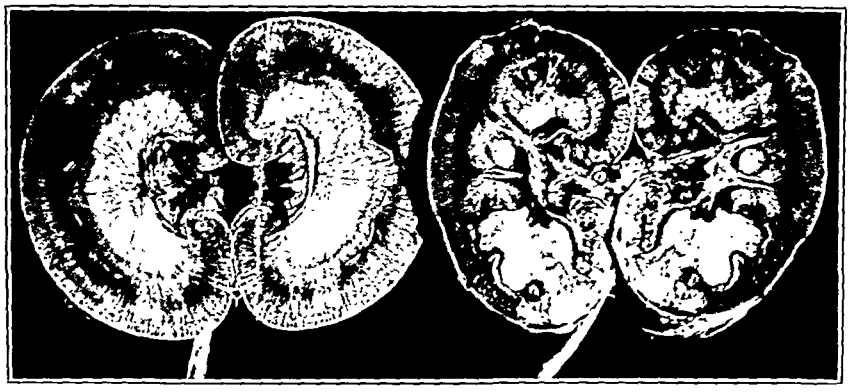

Fig. 30 (Series II, Group 2, Experiment 8 [C 412]).—Ligation of the posterior superior and inferior branches of the right renal artery; right kidney decapsulated and wrapped in omentum, fifteen days' duration; atrophy of the lower pole of the right kidney supplied by the posterior branch; results not affected by decapsulation and wrapping in omentum; new capsule formed in right kidney.

Fig. 31 (Series II, Group 2, Experiment 6 [C 505]).—Ligation of the anterior superior and posterior superior branches of the right renal artery and of the anterior inferior and posterior inferior branches of the left renal artery; both kidneys decapsulated and wrapped in omentum, thirty-eight days' duration; atrophy of area supplied by these vessels; no effects from wrapping kidney in omentum; new capsule formed in both kidneys.

Lindemann,[10] in 1898, stated that after the renal vein is obstructed, a collateral circulation is developed sufficient to maintain the function of the kidney. Téstut,[11] in 1917, stated that the collateral circulation is capable of maintaining the renal function in part. Tuffier and Lejars[6] stated that obliteration of the renal vein results in the formation of a collateral circulation whereby venous blood from the kidney is carried back to the general circulation through this plexus by four routes: (1) suprarenal and inferior diaphragmatic, (2) ureteric and spermatic or

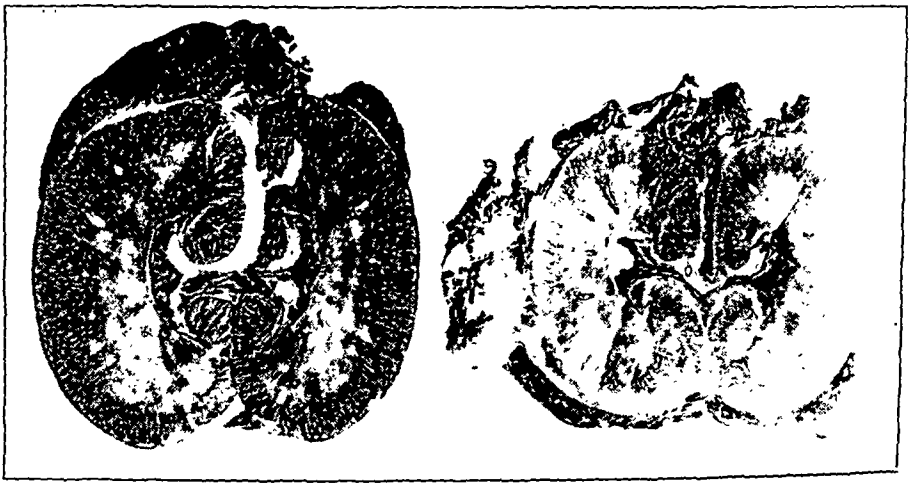

Fig. 32 (Series II, Group 2, Experiment 4 [C 436]).—Ligation of the posterior superior and inferior branches of the right renal artery; right kidney decapsulated and wrapped in omentum, 325 days' duration; atrophy of the posterior half of the right kidney; no effects from decapsulation and wrapping kidney in omentum.

ovarian, (3) subcutaneous plexuses of the lumbar veins, and (4) a plexus which surrounds the last intercostal, ileo-inguinal, and ileohypogastric nerves.

After the kidney was exposed the renal vein was carefully dissected from the perirenal fat at the hilum and doubly ligated and sectioned (Table 5).

Immediately after the renal vein was ligated there was a marked enlargement and bluish discoloration of the kidney from venous congestion. The organ became very tense from the engorgement of blood. This was followed almost immediately by dilatation of the capsular vessels, especially the suprarenal, the ovarian or spermatic, and branches

10. Lindemann, W.: Ueber Veränderungen der Nieren infolge von Ureterunterbindung, Ztschr. f. klin. Med. **34**:299-321, 1898.

11. Téstut, J. L.: Traité d'anatomie humaine, Ed. 6, Paris, O. Doin, 1911-1912.

to the lumbar veins. In a few instances, a vein was found passing directly from the capsule of the kidney to the renal vein. In most instances two or more of these dilated capsular vessels were found.

In Experiments 5, 6, 7, and 8, of six, four, four, and two days' duration, respectively, there was marked congestion and enlargement of the kidney with beginning degenerative changes (Figs. 33, 34 and 35).

In Experiment 6 the dog died on the fourth day. At necropsy it was found that death was caused by hemorrhage from the kidney operated on, which had ruptured in several places (Figs. 33 and 34), allowing the blood to escape and infiltrate the surrounding tissues. This kidney weighed 200 gm. and showed enormous congestion throughout the parenchyma.

TABLE 5.—SERIES II: THE EFFECT OF OCCLUSION OF THE VASCULAR RADICALS OF THE KIDNEY

Group 3: Ligation of the Renal Vein (Eight Experiments)

Experiment	Animal	Date of Operation	Duration of Experiment, Days	Ligation of Renal Vein	Necropsy	Dilatation			Lumbar Veins	Congestion of Kidney Operated On	Atrophy of Kidney Operated On	Weight of Kidney Operated On, Gm.	Weight of Kidney Not Operated On, Gm.
						Capsular Veins	Suprarenal Veins	Ovarian or Spermatic Veins					
1 (156)	B804	2/26/17	345	Left	49	+	+	+	+	.	+	5	30
2 (291)	B902	3/26/17	132	Right	453	+	+	+	..	..	+	4	20
3 (50)	B739	1/27/17	12	Left	55	+	..	+	+	+	+	24	30
4 (418)	C548	6/24/18	10	Left	336	+	+	+	..	+	+	25	37
5 (126)	B795	2/19/17	6	Left	87	+	+	+	+	+	..	34	30
6* (246)	B871	3/17/17	4	Left	164	..	..	..	..	..	..	200	57
7 (240)	B868	3/16/17	4	Left	152	+	+	+	..	+	..	30	20
8 (304)	B913	3/28/17	2	Left	190	+	+	+	..	+	..	32	25

* Kidney ruptured in several places; hemorrhage cause of death.

In Experiments 3 and 4, of twelve and ten days' duration, respectively, there was beginning atrophy of the entire kidney. In both there was pronounced dilatation of the capsular veins.

In Experiments 1 and 2, of 132 and 345 days' duration, respectively, there was a marked atrophy of the entire kidney. In Experiment 1, only a small nodule of kidney tissue was left. In Experiment 2, the remaining kidney tissue was symmetrically atrophied and weighed 4 gm. at the end of 345 days (Fig. 36).

This group of experiments shows that (1) there is symmetrical atrophy of the kidney after complete sudden occlusion of the renal veins; (2) a partial venous collateral circulation to the kidney is established comprising chiefly the ovarian or spermatic veins, the suprarenal veins, and branches of the lumbar veins; (3) the collateral circulation of the kidney is not capable of assuming the function of the renal vein

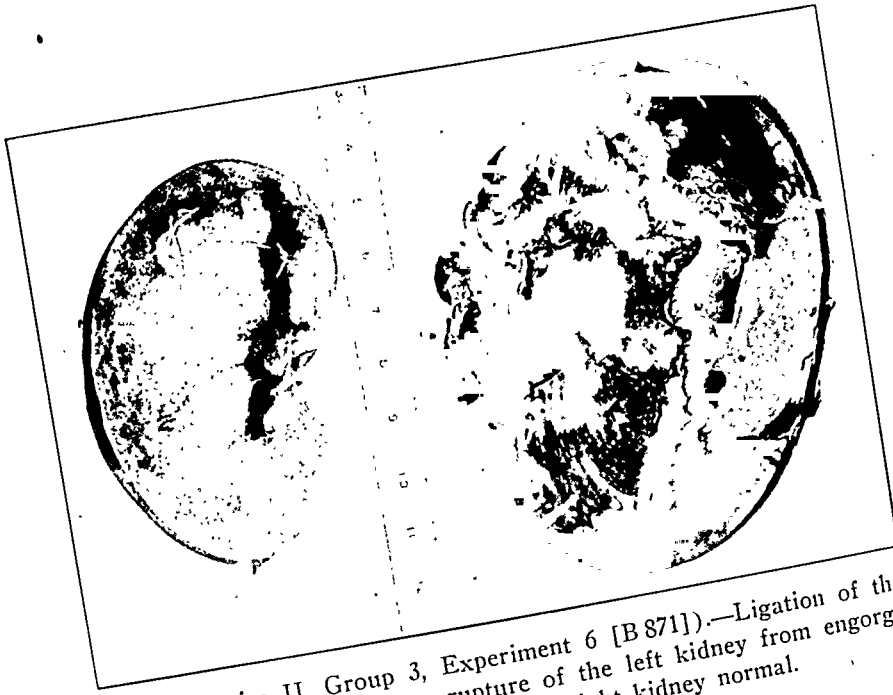

Fig. 33 (Series II, Group 3, Experiment 6 [B 871]).—Ligation of the left renal vein, four days' duration; rupture of the left kidney from engorgement of blood, causing death from hemorrhage; right kidney normal.

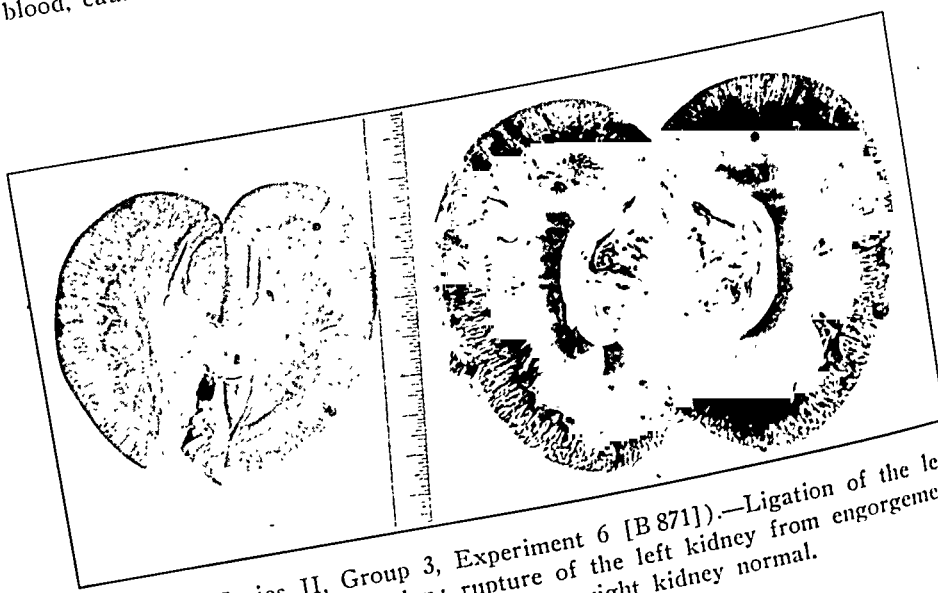

Fig. 34 (Series II, Group 3, Experiment 6 [B 871]).—Ligation of the left renal vein, four days' duration; rupture of the left kidney from engorgement of blood, causing death from hemorrhage; right kidney normal.

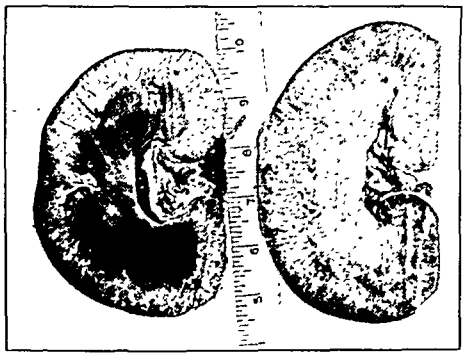

Fig. 35 (Series II, Group 3, Experiment 5 [B 795]).—Ligation of the left renal vein, six days' duration; marked congestion of left kidney, weight 34 gm.; right kidney normal, weight 36 gm.



Fig. 36 (Series II, Group 3, Experiment 5 [B 795]).—Ligation of the right renal vein, 132 days' duration; atrophy of entire kidney, weight 4 gm.; left kidney normal, weight 20 gm.

and maintaining a functionating kidney, and (4) ligation of the renal vein in a dog may cause the kidney to rupture.

Group 4. Ligation of One of the Larger Branches of the Renal Vein (Two Experiments).—This work was undertaken with the view of determining whether or not the capsular vessels would be dilated after partial obstruction of the venous return from the kidney, and whether or not the venous radicals of the kidney would anastomose.

The surgical procedure was the same as that used in former groups except that after the kidney was exposed the larger of the two main branches of the renal vein was dissected free from the perirenal fat and doubly ligated and sectioned. Two experiments were performed (Table 6).

TABLE 6.—SERIES II: THE EFFECTS OF OCCLUSION OF THE VARIOUS VASCULAR RADICALS OF THE KIDNEY

Group 4: Ligation of One of the Larger Branches of the Renal Vein

Experiment	Animal	Date of Operation	Duration of Experiment, Days	Ligation of Renal Vein	Ligation of One Branch of Renal Vein	Necropsy	Congestion of Kidney Operated On	Atrophy of Kidney Operated On	Weight of Kidney Operated On, Gm.	Weight of Kidney Not Operated On, Gm.
1 (416)	C546	6/24/18	359	Right	Posterior anterior	283	0	0	32 right	34 left
2 (393)	C524	6/10/18	37	Left	Posterior	572	0	0	34	37

In Experiment 1, the dog was killed after 359 days. At necropsy it was found that the kidney was normal in size and that no change had taken place in the renal parenchyma but the capsular vessels were slightly dilated.

In Experiment 2, the animal died on the thirty-seventh day. At necropsy the kidney was found to be normal in size, and there was no change in the renal parenchyma, but a moderate dilatation of the capsular vessels (Fig. 37).

SERIES III. THE EFFECT ON THE KIDNEY AND URETER OF TRAUMA TO THE URETER

The frequency with which the ureter is accidentally and unavoidably traumatized during the course of various surgical procedures is very hard to determine. It is known that the ureter is sometimes accidentally clamped with an artery forceps during operations in the vicinity.

Group 1. Clamping of the Ureter (Eleven Experiments).—A review of the literature did not reveal any record of other studies of the effect on the kidney and ureter of clamping the ureter.

The operative procedure was essentially the same as that used in Series II. The ureter was exposed and crushed with a Kocher artery forceps for from one to thirty minutes and then replaced behind the peritoneum.

The eleven experiments of from four to 251 days' duration do not complete the investigation, but Table 7 indicates the results obtained to date (Figs. 38, 39 and 40).

TABLE 7.—SERIES III: THE EFFECT ON THE KIDNEY AND URETER OF TRAUMA TO THE URETER

Group 1: Clamping the Ureter (Eleven Experiments)

Experiment	Animal	Date of Operation	Duration of Experiment, Days	Ureter Clamped	Minutes Ureter Clamped	Notch of Kocher Clamp	Necropsy	Condition of Clamped Ureter			Appearance of Kidney With Clamped Ureter	Hydronephrosis	Dilatation of Capsular Veins
								Area of Degeneration	Partial Constriction	Dilatation			
1 (349)	B953	4/16/17	251	Right	10	Third	619	..	+	+	Normal	Marked (weight 18 gm.)	0
2 (262)	B883	3/19/17	36	Right	30	Fourth	278	.	+	7 to 8 times	Normal (weight 34 gm.)	Slight	0
3 (348)	B952	4/16/17	23	Right	30	Third	318	..	Slight	Slight	Normal	.....	0
4 (191)	B829	3/ 5/17	20	Right	5	Second	194	..	+	0	Normal	.....	0
5 (192)	B830	3/ 5/17	10	Right	10	Second	144	+	+	0	Normal	.....	0
6 (260)	B881	3/19/17	7	Right 2 times	3	Second	181	+	+	0	Normal	.....	0
7 (225)	B799	3/13/17	6	Left 4 times	1	Second	148	Slight	..	0	Normal	.....	0
8 (664)	B746	9/ 9/18	5	Left	45	Second	523	+	+	+	Normal	.....	0
9 (333)	B937	4/ 7/17	5	Right	30	Third	253	+	+	2 times	Normal	.....	0
10 (318)	B923	4/ 2/17	4	Right	30	Fourth	215	..	+	4 times	Normal	Small	0
11 (379)	B974	4/30/17	4	Left	30	Third	417	+	..	Slight	Normal	.....	0

Experiment 1 demonstrates the end-results on the kidney. The right ureter was crushed with a Kocher clamp to the third notch for ten minutes. The animal was killed in 251 days. The ureter was almost completely constricted, but water could be forced through the constricted area with a piston syringe. Both the ureter and pelvis were moderately dilated above the point of constriction. The kidney was small with a large hydronephrotic cavity (Fig. 40), the parenchyma being almost entirely destroyed by pressure atrophy. The entire organ weighed 18 gm. The capsular veins were not dilated, but there was compensatory hypertrophy of the opposite kidney which weighed 50 gm. The condition was very similar to that found in Group 2 of Series I. in which the ureter and the collateral veins were doubly ligated and sectioned.

In Experiment 2, the right ureter was clamped with a Kocher forceps to the fourth notch for thirty minutes. The dog died in thirty-six days. At necropsy a partial constriction of the ureter was found at the



Fig. 37 (Series II, Group 4, Experiment 2 [C 524]).—Ligation of one branch of the right renal vein, thirty-seven days' duration; right kidney normal.

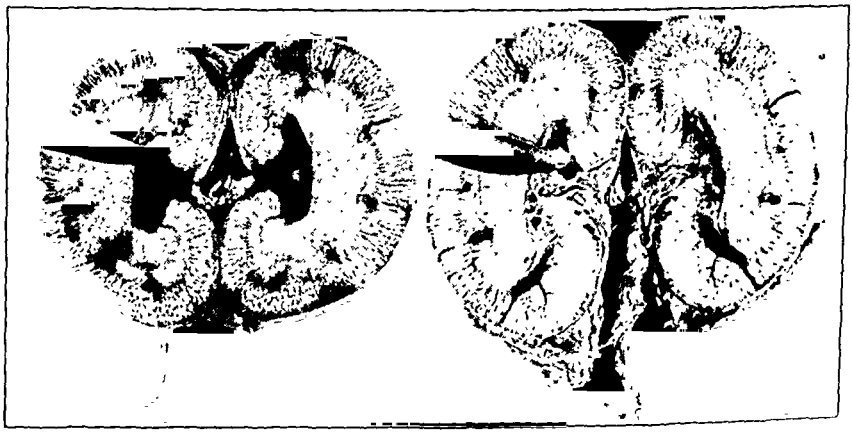

Fig. 38 (Series III, Group 1, Experiment 10 [B 923]).—Clamping of the right ureter, thirty minutes; necropsy after four days; slight constriction of the right ureter which was dilated to four times its normal size; slight hydronephrosis of the right kidney; left kidney normal.

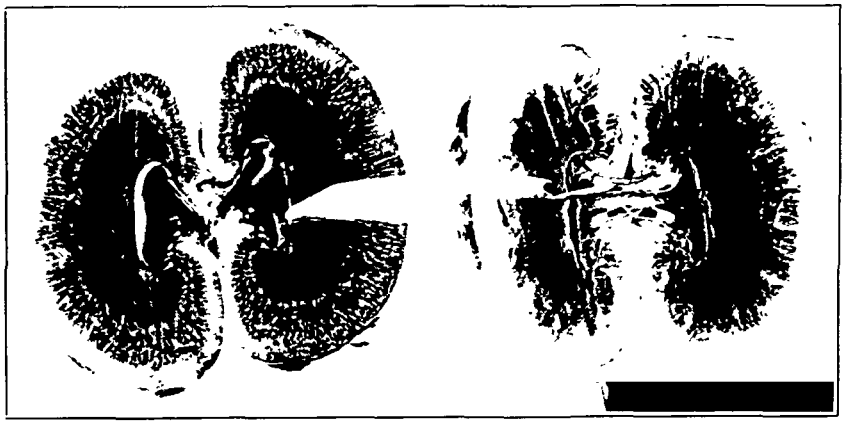

Fig. 39 (Series III, Group 1, Experiment 2 [B 883]).—Clamping of the right ureter, thirty minutes; necropsy after thirty-six days; partial constriction of the right ureter which was dilated to seven or eight times its normal size; slight hydronephrosis of right kidney.

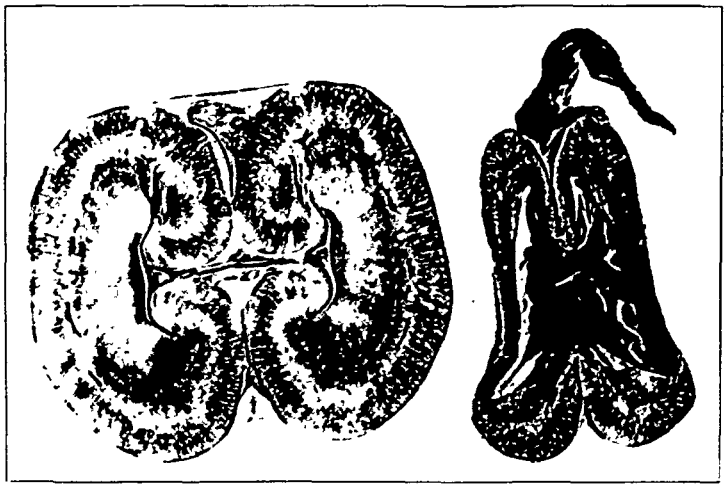

Fig. 40 (Series III, Group 1, Experiment 1 [B 953]).—Clamping of right ureter for ten minutes; necropsy after 251 days; partial constriction with dilatation of the right ureter; large hydronephrotic sac with atrophy of the right kidney; left kidney normal.

point of application of the clamp. The ureter was dilated from seven to eight times its normal size above the point of constriction, and three times the normal size below it. There was a moderate degree of dilatation of the pelvis, a small hydronephrotic cavity, and slight atrophy of the renal parenchyma. The kidney weighed 30 gm. The capsular veins were not dilated. The opposite kidney weighed 37 gm. (Fig. 39).

In Experiments 3 to 11, inclusive, of from four to twenty-three days' duration, there was a degenerating area at the point of application of the clamp which gradually formed into scar tissue, depending on the duration of the experiment. This scar tissue produced a stricture of the ureter with varying degrees of dilatation of the ureter above it (Fig. 38).

The study of this group of experiments shows that (1) injury to the ureter by crushing with artery forceps causes degenerative changes at the point of application, resulting in the formation of scar tissue which produces a partial constriction that may later progress to complete stricture; (2) there is dilatation of the ureter and pelvis in most instances which may progress to the point of hydronephrosis and degeneration of the kidney, with no dilatation of the capsular veins, and (3) no leakage of urine follows the application of a clamp to the ureter.

Group 2. Stripping of the Ureter.—In various surgical procedures on the kidney, ureter, and bladder, and in operations on other organs in their vicinity, it is often necessary to strip the ureter for a distance from the surrounding tissue. The practical significance of the extent to which this may be done is of the utmost importance to the surgeon because of its bearing on the end-results of various surgical procedures. Stewart and Barber,[12] in a series of nine experiments on dogs, produced ureteral paralysis by stripping the ureter of all nerve, vessel, and lymphatic connections from the pelvis of the kidney to the bladder. This ureteral paralysis was accompanied by urinary stasis and distention of the kidney in 66 per cent. of the cases.

Six experiments, ranging from fourteen to seventy-four days in duration, were performed in this group. The operative procedure is essentially the same in each instance. After the ureter was exposed, it was lifted from its bed and stripped with a piece of gauze for a distance of from 2 inches to its entire length and dropped back into the abdominal cavity with care to preserve as much of the blood supply as possible.

A study of the results obtained indicates that the ureter may be stripped of its surrounding tissues without permanent injury or dele-

12. Stewart, G. D., and Barber, W. H.: Hydronephrosis. An Experimental Study, Ann. Surg. **60**:723-728, 1914.

terious effect on the kidney, provided its blood supply is preserved, since pathologic change was not found in the kidney or ureter in a single instance (Table 8).

Group 3. Anastomosis of the Ureters (Twenty-Two Experiments).—Ureters are sometimes cut during the course of various surgical procedures in their vicinity, and not infrequently the ureter is severed by accident, fractures and so forth. In order to determine the best method of anastomosing these injured ureters, twenty-two experiments were performed. The operative procedure was the same as previously described, up to the point of exposing the ureter. The ureter was completely cut across in each instance.

TABLE 8.—SERIES III: THE EFFECT ON THE KIDNEY AND URETER OF TRAUMA TO THE URETER

Group 2: Stripping the Ureter (Six Experiments)

Experiment	Animal	Date of Operation	Duration of Experiment, Days	Ureter Stripped With Gauze	Blood Supply Preserved	Distance of Stripping	Necropsy	No Change in Ureter	Condition of Kidney Operated On
1 (583)	C107	8/20/17	74	Left	+	Entire length	317	+	Normal
2 (536)	C 75	7/30/17	41	Right	+	10 cm.	372	+	Normal
3 (285)	B899	3/24/17	31	Right	+	7.5 cm.	277	+	Normal
4 (191)	B829	3/ 5/17	26	Left	+	5 cm.	194	+	Normal
5 (525)	C 72	7/27/17	22	Left	+	10 cm.	490	+	Normal
				Right	+	Entire length	...	+	Normal
6 (224)	B783	3/13/17	14	Left	+	Entire length	186	+	Normal

In five experiments (Method A) the cut ends of the ureter were anastomosed, end-to-end, with interrupted silk sutures. In thirteen experiments (Method B) the anastomosis was made by drawing the proximal end into the distal end for a distance of 0.625 cm., using three interrupted silk sutures, one at the lower end of the anastomosis and two at the upper end. In the remaining four experiments (Method C) the proximal end of the ureter was anastomosed into the side of the opposite ureter and sutured behind the peritoneum (Table 9).

Method A. End-to-End Anastomosis: Three of the five animals in this group (Experiments 1, 2, and 3) died the third day of peritonitis from urinary leakage. In Experiment 4, the animal died the nineteenth day from sepsis, resulting from an abscess which had formed at the site of the anastomosis and had burrowed into the pelvis, forming a large pocket of pus. In Experiment 5, the animal was killed the fifty-sixth day. At necropsy a slight constriction and dilatation and a slight hydronephrosis were found (Fig. 41).

Method B. Cuff Anastomosis: This group consists of thirteen experiments of from five to 223 days' duration. In Experiment 6, the animal died the fifth day of peritonitis from urinary leakage, the only case of urinary leakage in this group. In Experiments 7 and 10, the ureters were markedly narrowed at the point of anastomosis, causing a partial constriction and dilatation of the ureter above this point with atrophy of the kidney and a moderate degree of hydronephrosis. In the remaining ten experiments, the ureter was slightly constricted at the point of anastomosis, in most cases producing a slight dilatation of the ureter. Little or no effect was produced on the kidney in five cases, and a slight hydronephrosis in five cases (Figs. 40, 43 and 44).

TABLE 9.—SERIES III: THE EFFECT ON THE KIDNEY AND URETER OF TRAUMA TO THE URETER

Group 3: Anastomosis of Ureters (Twenty-Two Experiments)

Experiment	Animal	Date of Operation	Duration of Experiment, Days	End-to-End Anastomosis	Cuff Anastomosis	Uretero-Ureterostomy	Necropsy	Slight Constriction at Anastomosis	Marked Obstruction at Anastomosis	Dilatation of Ureter Above Anastomosis	Urinary Leakage	Condition of Kidney Operated On
A1 (313)	B920	3/31/17	3	Right	.....	.....	199	..	..	..	+	
A2 (443)	C 19	6/11/17	3	Right	.....	.....	371	..	..	..	+	
A3 (483)	C 43	7/ 6/17	3	Right	.....	.....	413	..	..	..	+	
A4 (314)	B921	3/31/17	19	Right	.....	.....	233	..	.	..	+	
A5 (334)	B938	4/ 9/17	56	Right	.....	.....	344	..	..	Slight	0	Slightly hydronephrotic
B6 (452)	C 28	6/22/17	5	.....	Right	.....	397	..	..	..	+	
B7 (617)	C127	8/31/17	14	.....	Right	.....	522	+	+	..	0	Atrophic
B8 (600)	C119	8/27/17	18	.....	Right	.....	520	+	.	Slight	0	Normal
B9 (469)	C 36	7/ 2/17	36	.....	Right	.....	460	+	..	0	0	Normal
B10 (489)	C 46	7/ 9/17	43	.....	Right	.....	493	+	+	+	0	Atrophic
B11 (454)	C 30	5/25/17	48	.....	Right	.....	469	0	..	Slight	0	Normal
B12 (589)	C112	8/24/17	49	.....	Right	.....	538	+	..	Slight	0	Slightly hydronephrotic
B13 (630)	C135	9/10/17	60	.....	Right	.....	597	0	..	Slight	0	Normal
B14 (336)	B940	4/ 9/17	67	.....	Right	.....	373	+	..	Slight	0	Hydronephrotic
B15 (625)	C131	9/ 7/17	81	.....	Right	.....	623	0	..	Slight	0	Normal
B16 (599)	C118	8/27/17	95	.....	Right	.....	633	+	..	Slight	0	Hydronephrotic
B17 (453)	C 29	6/22/17	187	.....	Right	.....	611	0	..	Slight	0	Normal
B18 (455)	C 31	6/25/17	223	.....	Right	.....	8	+	..	+	0	Hydronephrotic
C19 (470)	C 37	7/ 2/17	2	.....	.....	Right into left	402	.	..	..	+	
C20 (498)	C 55	7/13/17	3	.....	.....	Right into left	420	..	..	..	+	
C21 (499)	C 56	7/13/17	4	.....	.....	Right into left	423	..	..	..	+	Left, hydronephrotic
C22 (491)	C 48	7/ 9/17	25	.....	.....	Right into left	44[illegible]	..	+	..	0	Left, atrophic and slightly hydronephrotic

Method C. Uretero-Ureterostomy: In Experiments 19, 20, and 21 the animals died the second, third, and fourth days, respectively, after operation, of peritonitis from urinary leakage. In Experiment 22 the

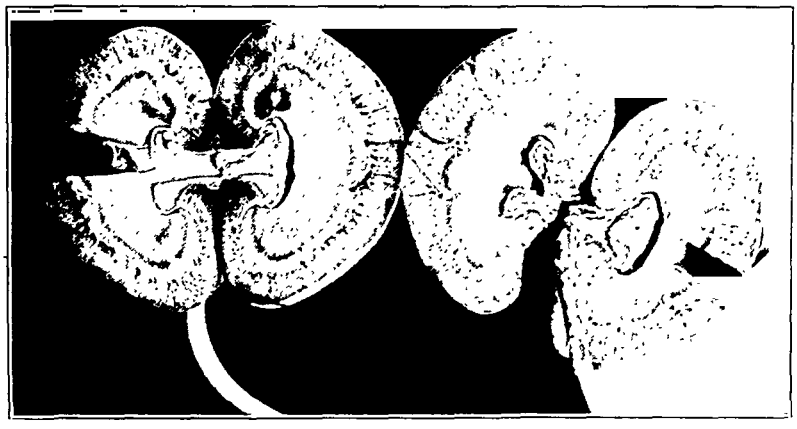

Fig. 41 (Series III, Group 3, Experiment 5 [B 936]).—End-to-end anastomosis of the right ureter; fifty-six days' duration; slight constriction and dilatation of the right ureter, slight hydronephrosis of the right kidney; left kidney normal.

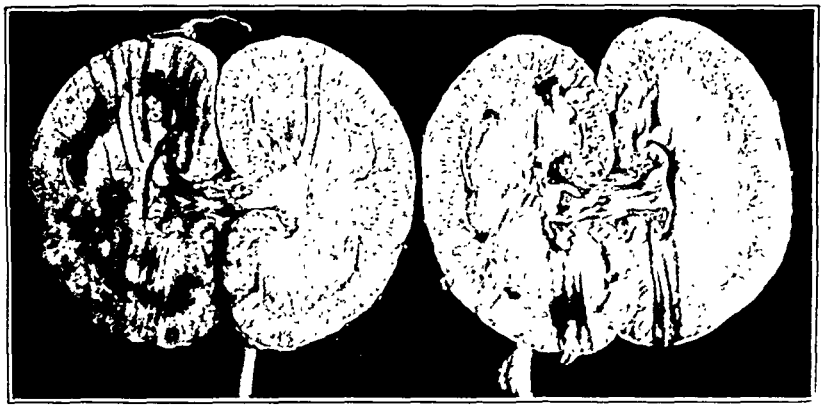

Fig. 42 (Series III, Group 3, Experiment 15 [C 131]).—Cuff anastomosis of the right ureter, eighty-one days' duration; slight dilatation of the right ureter; no stricture; right kidney normal; left kidney normal.

animal was killed the twenty-fifth day. At necropsy it was found that the anastomosis had healed perfectly, apparently without urinary leakage. The anastomosed ureter was dilated from partial constriction at the point of implantation and its kidney slightly atrophied. The recipient ureter was slightly dilated above the point of anastomosis, but the kidney appeared to be normal (Fig. 45).

Fig. 43 (Series III, Group 3, Experiment 10 [C 46]).—Cuff anastomosis of the right ureter, forty-three days' duration; partial constriction and dilatation of the right ureter; slight hydronephrosis with atrophy of the right kidney; left kidney normal.

From these experiments it seems that in the dog, cuff anastomosis is the method of choice as in only one case leakage of urine occurred, and that peritonitis resulting from urinary leakage is the most frequent cause of failure and death in anastomosing ureters.

Fig. 44 (Series III, Group 3, Experiment 8 [C 119]).—Cuff anastomosis of the right ureter, eighteen days' duration; slight constriction and dilatation of the right ureter; right kidney normal.

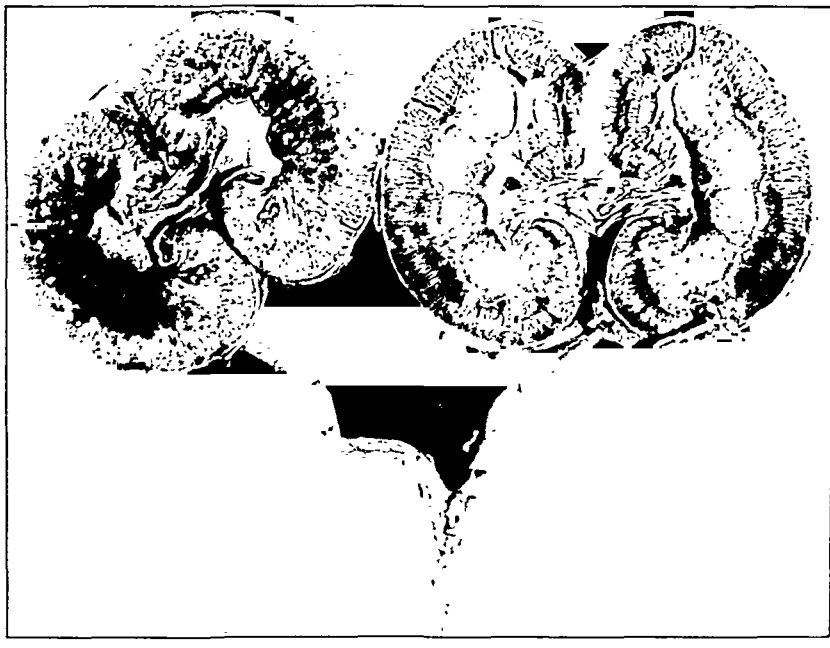

Fig. 45 (Series III, Group 3. Experiment 22 [C 48]).—Transplantation of the left ureter into the right, twenty-five days' duration; partial constriction and dilatation of left ureter with slight hydronephrosis and atrophy of the left kidney; dilatation of the right ureter above the anastomosis; right kidney normal.

SERIES IV. THE EFFECT OF DECAPSULATION OF THE KIDNEY

Great variations have been obtained in the results by experimental decapsulation of the normal kidney, particularly in the distribution of the blood vessels that are formed to repair the injury. The capsule is rapidly formed with an increase in the connective tissue of the cortex. There is still some controversy over the derivation of the new capsule and the distribution of the new blood supply. Emerson,[13] in 1903, after twenty experiments on dogs, concluded that the kidney forms a new capsule with marked vascular connections with the surrounding viscera, but not with the fatty capsule of the kidney, and that bands of connective tissue penetrate the renal parenchyma, simulating a diffuse nephritis. Johnson,[14] in 1903, from experiments on fifteen dogs, concluded that the kidney forms a new capsule and that there is round-cell infiltration of the cortex, but no anastomosis between the renal and peritoneal blood channels. Gifford,[15] in 1904, from experiments on the normal kidney of rabbits, found that a new very vascular capsule is formed after decapsulation, but that these new vessels do not anastomose with the branches of the renal artery of the cortex. Hall and Herxheimer,[16] working with rabbits, observed the formation of a new vascular fibrous capsule, but very few new blood channels between the kidney and the adherent tissues. Siter,[17] in 1912, from two series of experiments on cats and dogs, in two stages, found that a new capsule forms from the omentum and that a collateral circulation is established in ten days which is capable of maintaining the kidney function properly when the renal vessels are tied off.

Group 1. Decapsulation of the Kidney and Wrapping It in Omentum (Thirteen Experiments).—These experiments were undertaken for the purpose of determining (1) whether a new capsule would form; (2) whether the capsular circulation would be increased or decreased; (3) whether the branches of the renal artery and the arterial capsular blood vessels would anastomose, and (4) whether changes are produced

13. Emerson, H., and Meltzer, S. J.: Studies on the Capsule of the Kidney, Tr. Assn. Am. Phys. **18**:192-196, 1903.

14. Johnson, H. A.: Results of Decapsulation of the Kidney. A Study of Changes Noted in the Renal and Peripheral Tissues of Dogs After Decapsulation, Ann. Surg., **37**:592-601, 1903.

15. Gifford, N. H.: Experimental Decapsulation of the Kidneys, Boston M. & S. J. **151**:37-40, 1904.

16. Hall, I. W., and Herxheimer, G.: Experimental Nephritis Followed by Decapsulation of the Kidney, Brit. M. J. **1**:819-822, 1904.

17. Siter, E. H.: Results of Experiments on Kidneys, with Special Reference to Decapsulation and Establishment of Collateral Circulation, Surg., Gynec. and Obst. **15**:702-706, 1912.

in the renal parenchyma. Other points in relation to the decapsulation of diseased kidneys have not been completed.

The operative procedures were the same as those in the other series up to the point of exposing the kidney. In the majority of instances both layers of the fibrous capsule of the kidney were removed, with care

TABLE 10.—SERIES IV: THE EFFECT OF DECAPSULATION OF THE KIDNEY
Group I: Decapsulation of the Kidney and Wrapping It in Omentum
(Thirteen Experiments)

Experiment	Animal	Date of Operation	Duration of Experiment, Days	Decapsulation of Kidney and Wrapping in Omentum	Decapsulation of Kidney	Necropsy	Condition of Cortex	Formation of New Capsule	Increase in Capsular Veins Observed Macroscopically	Decrease in Capsular Veins Observed Macroscopically	Increase in Connective Tissue in Cortex
1 (124)	B793	2/19/17	353	Left	.....	53	.....	+	..	+	+
2 (286)	B900	3/24/17	203	.....	Right	529	.....	+	..	+	+
3 (591)	C114	8/24/17	109	.....	Right	58	.....	..	..	+	+
					Left	...	.....	+	..	+	+
4 (543)	C 82	8/ 3/17	113	Right	Left	675	.....	Right Left	+	..	+
5 (220)	B885	3/12/17	70	.....	Right	333	.....	+	..	+	+
6 (387)	B984	5/ 7/17	51	.....	Right	398	.....	+	..	+	+
7 (398)	B985	5/ 7/17	46	.....	Right	387	.....	+	..	+	+
8 (261)	B882	3/19/17	42	.....	Right	293	.....	+	+	..	+
9 (542)	C 81	8/ 3/17	17	Right	Left	489	.....	Right	..	+	..
10 (538)	C 77	7/30/17	17	Right	Left	480	.....	+	+	..	+
11 (98)	B768	2/10/17	7	Left	.....	77	Left, congested				
12 (535)	C 74	7/30/17	3	Right	Left	447	Left, congested; right, not congested				
13 (537)	C 76	7/30/17	2	Right	Left	446	Right, slightly congested; left, congested				

TABLE 11.—SERIES IV: THE EFFECT OF DECAPSULATION OF THE KIDNEY
Group 2: Decapsulation of the Kidney and Wrapping It in Omentum and Ligation of the Renal Artery or Branches of the Renal Artery (Seven Experiments)

Experiment	Animal	Date of Operation	Duration of Experiment, Days	Decapsulation of Kidney and Wrapping in Omentum	Ligation of Renal Artery	Ligation of One Branch of Renal Artery	Necropsy	Formation of New Capsule	Anastomosis of Renal and Capsular Arteries
1 (273)	C444	4/29 18	526	Right	.....	Right	494	-	
2 (99)	B769	2/10 17	16	Left	Left	.....	99	+	
3 (53)	B742	1 27 17	10	Left	Left	.....	53	-	0
4 (398)	C529	6 17 17	348	Right	....	Right	261		
				Left	.....	Left	..	+	0
5 (265)	C438	4 22 18	325	Right	.....	Right	92	+	+
6 (364)	C505	6/ 2/18	38	Right	.....	Right	347		
				Left	.....	Left	..	+	0
7 (235)	C412	4/ 4 18	15	Right	.....	Right	220	-	0

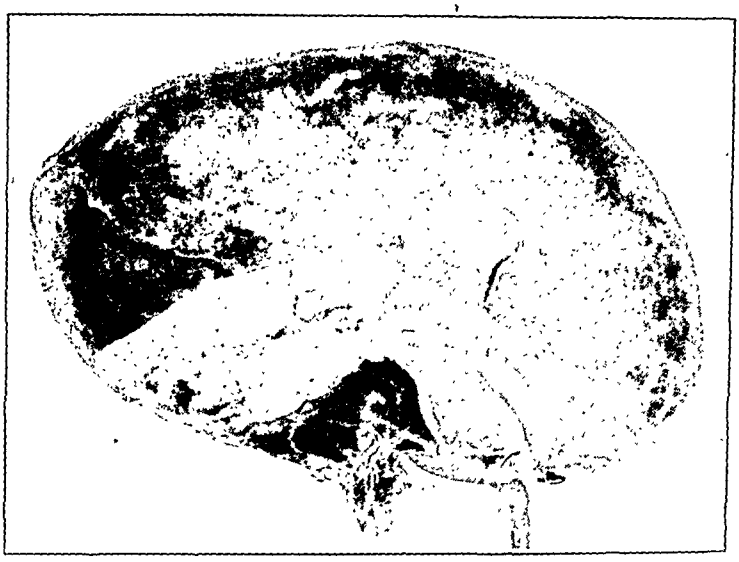

Fig. 46 (Series IV, Group 1, Experiment 7 [B 985]).—Decapsulation of the right kidney, wrapping in omentum, forty-six days' duration; formation of new dense, thick, fibrous capsule.

Fig. 47 (Series IV, Group 1, Experiment 2 [B 985]).—Section of capsule of kidney shown in Figure 46.

Fig. 48 (Series IV, Group 1, Experiment 4 [C 82]).—Decapsulation of right kidney, 115 days' duration; formation of new fibrous capsule closely associated with connective tissue of tubules.

Fig. 49 (Series IV, Group 1, Experiment 1 [B 793]).—Decapsulation of left kidney, wrapping in omentum, 353 days' duration: formation of a thick, fibrous capsule associated with the intratubular connective tissue.

to injure the renal parenchyma as little as possible. It is usually difficult to remove the inner, thin, reticular layer of the capsule because of its intimate association with the connective tissue surrounding the tubules of the cortex. There was considerable oozing of blood from the surface of the kidney after its capsule was removed; this was controlled by compression with gauze for about four or five minutes. The decapsulated kidney was then wrapped in omentum and replaced in the abdomen (Table 10 and Figs. 46 to 49).

The conclusions drawn from these experiments are that (1) the kidney forms a well marked new capsule in about seventeen days, (2) the interstitial tissue of the cortex increases, and (3) the newly formed capsule is more dense and fibrous and contains fewer (new) blood vessels than the normal capsule.

Group 2. Decapsulation of the Kidney and Wrapping It in Omentum and Ligation of the Renal Artery or Branches of the Renal Artery (Seven Experiments).—In two experiments the renal artery was ligated and the decapsulated kidney wrapped in omentum; and in five, one or more branches of the renal artery were ligated and the kidney decapsulated and wrapped in omentum (Table 11). These procedures had no effect on the production of atrophy, which indicates that the capsular vessels do not anastomose with the branches of the renal artery.

TUBERCULOSIS OF BONE

RESULTS OF A STUDY

NATHANIEL ALLISON, M.D.
ST. LOUIS

INTRODUCTION

This study was made on the material collected during the treatment of fifty cases of bone tuberculosis. The patients were under treatment on the surgical service of the Barnes Hospital and the St. Louis Children's Hospital. The material obtained at operation was investigated in the laboratory of surgical pathology of the Washington University School of Medicine.

From the clinical standpoint, the cases used presented varying types of those manifestations usually associated with infectious bone lesions. Forty-two of the patients were adults; eight were children. In most cases, the symptoms and physical data made diagnosis of the tubercle bacillus as the etiologic factor a matter of no great difficulty. In some cases, diagnosis of tuberculosis was not made certain until the material placed in our hands by operation was sectioned and studied microscopically, and the confirmative evidence of animal inoculation was received. The clinical confusion between lesions due to syphilis and tuberculosis was a matter of especial concern. No cases were included in this group of fifty in which there remained any doubt as to the presence of syphilis as a causative factor.

It is not the purpose of this study to attempt to analyze the clinical pictures presented by this group of cases, but rather to call attention to the character of the lesions observed as seen under the microscope, the object in view being the simplification of our notions regarding the classification of the bone lesions due to tuberculous infection.

PATHOLOGIC MATERIAL

The focus of infection in the fifty cases studied was distributed about the bony framework of the body thus: spine, three cases; hip, eight cases; knee, sixteen cases; shoulder, six cases; ankle and tarsus, five cases; wrist, one case; elbow, two cases; trochanter major, one case; trochanter minor, one case; tibia, two cases; ulna, one case; humerus, one case; sternum, one case; malar bone, one case, and rib, one case: total, fifty cases.

Much has been written on the tendency of this disease to manifest itself in certain typical areas of the skeleton. So much is this the case

that an unusual location of the process will give rise to difficulty in diagnosis. In the cases studied in this group, there were several atypical foci of infection, such as might surprise one who had the conventional opinion that this disease occurs only at certain points. On the other hand, in the great majority of instances, the disease occurs and progresses along rather well established lines, well recognized clinically and pathologically. It is my belief that the more unusual forms of bone tuberculosis need a clearer clinical recognition.

CLASSIFICATION OF TUBERCULOUS BONE LESIONS

The pathologic changes that take place in bone tissue have been classified both from their macroscopic and microscopic appearances. Thus we recognize four distinct sets of changes and are schooled to regard these pictures as representative of clinical entities: (1) the encysted tuberculous lesion; (2) the infiltrating tuberculous lesion; (3) the atrophic tuberculous lesion, and (4) the hypertrophic tuberculous lesion.

Furthermore, it has long been the habit of those studying tuberculosis of the bone to include the bone lesions under one head and attempt to classify them as above, whereas the joint disturbances that follow tuberculous involvement of a joint area are separately classified and again regarded as distinct clinical entities. Thus we are schooled to recognize distinct clinical types of bone disease, as above, and joint disease, as, for example: (a) acute miliary tuberculous synovitis; (b) chronic tuberculous synovitis; (c) granulating or fungating tuberculous synovitis; and (d) fibrous tuberculous synovitis.

From the study of the material just mentioned, it seems worth while to attempt a simpler method of dealing with these various clinical and pathologic processes. The pathologic classification of an early day, long before the tubercle bacillus was known, when pathologists gave to us the rudiments of our present classification of disease, still has too firm a hold on the classification of osseous and articular disease. This may be due to lack of modern intensive study in this special field of pathology. In any event, we hang to the old names and old methods of classification. The skeletal structures that furnish the soil upon which tuberculous infection may become localized and develop are these: bone, of the cancellous and cortical types; periosteum; epiphyseal cartilage; articular cartilage; the epiphysis; the metaphysis; the diaphysis; bone marrow; the joint capsule; the ligaments, and the synovial membrane. Tuberculous infection gaining a foothold in any one or in several of these structures behaves in a manner which corresponds to the structure involved. In order that I may make clear my understanding of the changes wrought in the tissues as a result of tuber-

culous infection, I shall take up the material from the point of view of the particular tissue involved. There is no warrant, pathologically or clinically, to consider these lesions from the standpoint of contrasted bone or joint involvement. In most instances in this series of fifty cases, joints were involved in the process. In each and every instance, there was involvement of the bone. I find myself in accord with Nichols,[1] who was led to believe from his study of a similar group of cases that this disease is primarily a disease of the bone. I am not sure in what tissue the primary infection took place in all of these cases. I am sure that in all of them, the bone became the chief seat of the infection. Diligent search was made for evidence of primary synovial involvement, and for synovial involvement alone. No evidence was found of an instance of pure synovial tuberculosis. On the other hand, there is much evidence to show how the primary focus of disease located in the bone progresses to involvement of most of the intra-articular and extra-articular structures, as well as how it spreads in the bone tissue itself.

PART I. BONE TUBERCULOSIS WITH JOINT INVOLVEMENT

First I shall consider the cases in which the disease was apparently localized in the cancellous ends of the long bones and in which, through natural sequence, the adjacent joint or joints became diseased. This subgroup constitutes forty-one of the fifty cases.

In this group we have also the involvement of not only the cancellous bone to consider, but also such structures as the articular cartilage, the synovia, the joint capsule and ligaments. Case 1 is typical.

CASE 1 (Figs. 1, 2, 3, 4 and 5).—In this case a diagnosis of tuberculosis of the shoulder was made on clinical findings. The head of the humerus was excised, a specimen of which is shown in Figure 1. Here there was evident erosion of the joint cartilage; the joint surface was extensively involved, the cartilage being eroded at the margins and on the center of the surface, where there is a depression. Macroscopically, this joint surface inclined us to the belief that we had discovered a case of chronic tuberculous synovitis. After the entire head was decalcified and a section made of the specimen in the midfrontal plane of the humerus, the original focus became apparent (Fig. 2). The macroscopic appearance of the bone trabeculae in the sections cut would justify the diagnosis of atrophic tuberculous lesion. The microscopic sections at the area of the focus would justify the assumption that we were dealing with the infiltrating tuberculous lesion of Nélaton (Fig. 3). Here we have tuberculous granulation tissue surrounding the trabeculae, which are being broken down in a rapid manner by osteoclasts and caseation is spreading rapidly. The attempt in the marrow to fight off the disease is lacking, there being very little fibrous reaction.

1. Nichols, E. H.: Tuberculosis of Bones and Joints, Tr. Am. Orthop. Assn. **11**:383, 1898.

that an unusual location of the process will give rise to difficulty in diagnosis. In the cases studied in this group, there were several atypical foci of infection, such as might surprise one who had the conventional opinion that this disease occurs only at certain points. On the other hand, in the great majority of instances, the disease occurs and progresses along rather well established lines, well recognized clinically and pathologically. It is my belief that the more unusual forms of bone tuberculosis need a clearer clinical recognition.

CLASSIFICATION OF TUBERCULOUS BONE LESIONS

The pathologic changes that take place in bone tissue have been classified both from their macroscopic and microscopic appearances. Thus we recognize four distinct sets of changes and are schooled to regard these pictures as representative of clinical entities: (1) the encysted tuberculous lesion; (2) the infiltrating tuberculous lesion; (3) the atrophic tuberculous lesion, and (4) the hypertrophic tuberculous lesion.

Furthermore, it has long been the habit of those studying tuberculosis of the bone to include the bone lesions under one head and attempt to classify them as above, whereas the joint disturbances that follow tuberculous involvement of a joint area are separately classified and again regarded as distinct clinical entities. Thus we are schooled to recognize distinct clinical types of bone disease, as above, and joint disease, as, for example: (a) acute miliary tuberculous synovitis; (b) chronic tuberculous synovitis; (c) granulating or fungating tuberculous synovitis; and (d) fibrous tuberculous synovitis.

From the study of the material just mentioned, it seems worth while to attempt a simpler method of dealing with these various clinical and pathologic processes. The pathologic classification of an early day, long before the tubercle bacillus was known, when pathologists gave to us the rudiments of our present classification of disease, still has too firm a hold on the classification of osseous and articular disease. This may be due to lack of modern intensive study in this special field of pathology. In any event, we hang to the old names and old methods of classification. The skeletal structures that furnish the soil upon which tuberculous infection may become localized and develop are these: bone, of the cancellous and cortical types; periosteum; epiphyseal cartilage; articular cartilage; the epiphysis; the metaphysis; the diaphysis; bone marrow; the joint capsule; the ligaments, and the synovial membrane. Tuberculous infection gaining a foothold in any one or in several of these structures behaves in a manner which corresponds to the structure involved. In order that I may make clear my understanding of the changes wrought in the tissues as a result of tuber-

culous infection, I shall take up the material from the point of view of the particular tissue involved. There is no warrant, pathologically or clinically, to consider these lesions from the standpoint of contrasted bone or joint involvement. In most instances in this series of fifty cases, joints were involved in the process. In each and every instance, there was involvement of the bone. I find myself in accord with Nichols,[1] who was led to believe from his study of a similar group of cases that this disease is primarily a disease of the bone. I am not sure in what tissue the primary infection took place in all of these cases. I am sure that in all of them, the bone became the chief seat of the infection. Diligent search was made for evidence of primary synovial involvement, and for synovial involvement alone. No evidence was found of an instance of pure synovial tuberculosis. On the other hand, there is much evidence to show how the primary focus of disease located in the bone progresses to involvement of most of the intra-articular and extra-articular structures, as well as how it spreads in the bone tissue itself.

PART I. BONE TUBERCULOSIS WITH JOINT INVOLVEMENT

First I shall consider the cases in which the disease was apparently localized in the cancellous ends of the long bones and in which, through natural sequence, the adjacent joint or joints became diseased. This subgroup constitutes forty-one of the fifty cases.

In this group we have also the involvement of not only the cancellous bone to consider, but also such structures as the articular cartilage, the synovia, the joint capsule and ligaments. Case 1 is typical.

CASE 1 (Figs. 1, 2, 3, 4 and 5).—In this case a diagnosis of tuberculosis of the shoulder was made on clinical findings. The head of the humerus was excised, a specimen of which is shown in Figure 1. Here there was evident erosion of the joint cartilage; the joint surface was extensively involved, the cartilage being eroded at the margins and on the center of the surface, where there is a depression. Macroscopically, this joint surface inclined us to the belief that we had discovered a case of chronic tuberculous synovitis. After the entire head was decalcified and a section made of the specimen in the midfrontal plane of the humerus, the original focus became apparent (Fig. 2). The macroscopic appearance of the bone trabeculae in the sections cut would justify the diagnosis of atrophic tuberculous lesion. The microscopic sections at the area of the focus would justify the assumption that we were dealing with the infiltrating tuberculous lesion of Nélaton (Fig. 3). Here we have tuberculous granulation tissue surrounding the trabeculae, which are being broken down in a rapid manner by osteoclasts and caseation is spreading rapidly. The attempt in the marrow to fight off the disease is lacking, there being very little fibrous reaction.

1. Nichols, E. H.: Tuberculosis of Bones and Joints, Tr. Am. Orthop. Assn. **11**:383, 1898.

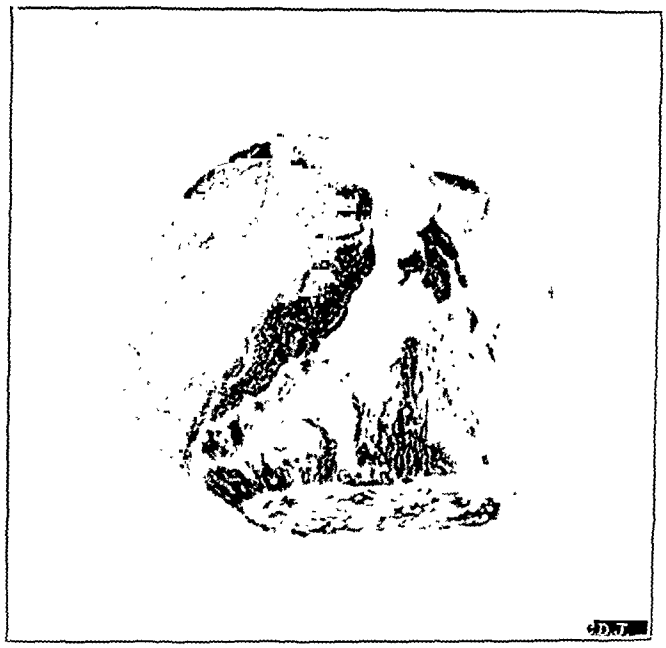

Case 1: Figure 1.

Case 1: Figure 2.

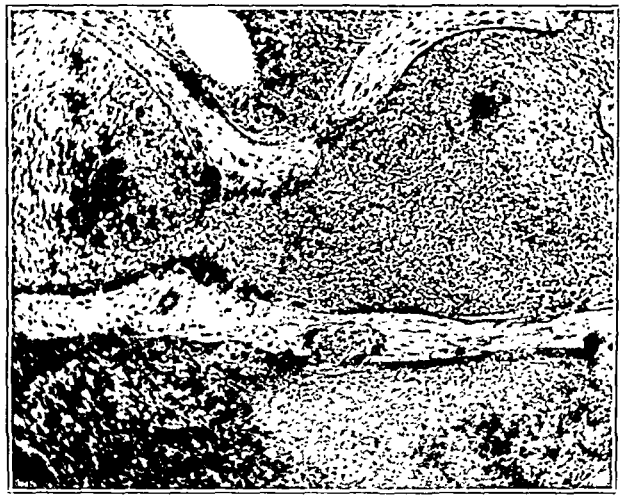

Case 1: Figure 3.

Case 1: Figure 4.

Here also we have erosion of the cartilage of the joint from below, and a "break through" into the joint cavity by tuberculous granulations (Fig. 4).

Finally, Figure 5 shows the thickened synovial membrane, with extensive tuberculous involvement.

Conclusions.—A search through the various tissues studied in this case will reveal pictures corresponding to most of the classifications now used in attempting to group tuberculous bone lesions. Figure 2, which is a slightly enlarged photograph of a section cut through the head, reveals extensive atrophic changes in the bone. I believe this to be disuse atrophy, as bones not used will show similar change in size and number of the trabeculae of the cancellous bone.

Case 1: Figure 5.

At the site of tuberculous involvement, microscopic search will reveal rapid involvement and destruction of bone elements, the cartilage shows erosion and breaking through, and the synovial membrane is thickened and tuberculous. There is: (1) tubercle formation; (2) caseation; (3) atrophic changes; (4) cartilage destruction; (5) infiltration changes; (6) synovial tuberculosis and (7) practically no effort at repair: a typical picture of tuberculosis of the bone with secondary joint involvement.

After two years of clinical quiescence, an operation was performed in this case for flail shoulder. The portions of bone removed from the end of the shaft showed typical features of tuberculosis of bone. Here the disease process had extended to the shaft of the bone and was characterized by proliferative or "hypertrophic" changes.

CASE 2 (Fig. 6).—*Tuberculosis of Shoulder Joint.*—This case, though not so typical in all its details of the history of bone tuberculosis with subsequent joint involvement as is Case 1, is, nevertheless, quite characteristic of some of the points I wish to emphasize. Figure 6, a photomicrograph of the upper end of the humerus, shows clearly the marked atrophic changes in the trabeculae of the cancellous bone, i. e., atrophic type of tuberculosis. In numerous areas, there are seen fields of an infiltrating type of tuberculosis (Fig. 7). Again the breaking through of the joint cartilage is beautifully shown in Figure 8.

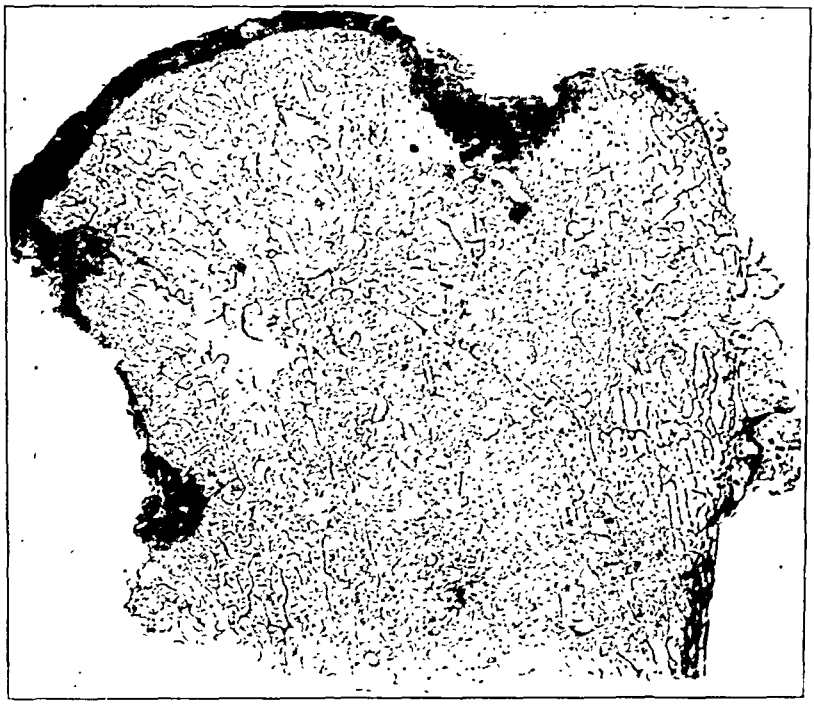

Case 2: Figure 6.

Conclusions.—Here we have atrophic and infiltrating types and the involvement of the joint with extensive cartilage erosion and tuberculosis of the synovial membrane. The atrophic change is due to disuse.

CASE 3 (Fig. 9).—*Tuberculosis of Shoulder.*—Here we see again the extensive atrophy of the cancellous bone of the upper end of the humerus, with cartilage erosion (Fig. 10), and tuberculosis of the synovial membrane. There is also evidence in many fields of the infiltrating type of tuberculosis, with trabeculae that have become necrotic, caseation, and very poor evidence of attempted repair by fibrous tissue formation.

Conclusions.—In the same specimen, we have the various pictures of tuberculous involvement of certain structures. The atrophic change is due to disuse

Case 2: Figure 7.

Case 2: Figure 8.

Case 3: Figure 9.

Case 3: Figure 10.

CASE 4 (Figs. 11 and 12).—In this case of hip disease of many years' duration, sections through the head of the femur show various pictures of the disease process.

Figure 11 shows marked atrophic and infiltrating changes. The trabeculae are being rapidly destroyed by osteoclasts, low vascularity and caseation. Figure 12, on the other hand, shows power of repair; the marrow spaces are filled with fibroblasts, increased vascularity, and the trabeculae are surrounded by osteoblasts, and definite new bone formation.

Conclusions.—Destruction and healing are going on side by side in tuberculous bone disease.

CASES 5 AND 6 (Figs. 13 and 14).—In these cases of hip joint tuberculosis the bone which was excised shows characteristic areas of active tuberculous disease with destruction of trabeculae and at the same time a general atrophy of the cancellous bone. Figures 13 and 14 show characteristic involvement of the joint cartilage. In Figure 13, there is an area of intense "infiltrating" tuberculosis of the cancellous bone directly under the joint cartilage. The cartilage shows by its appearance of "buds" that granulation tissue is pushing through from below. In Figure 14, these "buds" in the cartilage are well shown. In both these cases there was involvement of the synovial membrane.

Brooks and I[2] have carefully described this behavior of the joint cartilage when the cancellous bone becomes the seat of an infectious process. Its behavior does not vary greatly with the type of infectious agent.

CASE 7 (Figs. 15, 16, 17, 18 and 19).—*Tuberculosis of Knee.*—A coal miner, aged 53, appeared at the clinic with evident tuberculosis of the knee. Excision was advised, but operation was refused. A plaster-of-Paris cast was applied, and crutches and a high shoe were used. He was treated conservatively. After eleven months, he returned with the knee much worse. Amputation was advised, but refused. Excision was allowed. The knee joint was excised, and extensive involvement of all tissues was found. Healing took place; but tuberculosis advanced in new areas. The patient submitted to amputation at the end of nine months, but died of general tuberculosis several months later.

As is often the case in surgical treatment, especially of cancer and tuberculosis, the surgeon was a step behind the advance of the disease.

Gross Pathology, After Excision, First Operation.—The tissue consists of the femoral condyles, the head of the tibia, and the patella. There is an area of total bone destruction on the lateral surface of the condyle about 1 cm. in diameter and depth, with typical caseous tuberculous granulation tissue. A similar cavity is found in the head of the tibia also, which communicates with the joint cavity through an opening at the base of the crucial ligaments. There is extensive destruction of the margins of the joint cartilages; those on the joint surface of the patella are completely undermined. The joint capsule at the margins of the patella shows numerous miliary tubercles in granulation tissue.

Gross Pathology, After Amputation, Second Operation.—The specimen received is the left leg amputated at the lower third of the femur. After fixing the leg in liquor formaldehydi it was cut through with a saw in the midline, longitudinally. There was no union between the femur and tibia.

---

2. Allison, N., and Brooks, B.: Ankylosis, Surg., Gynec. & Obst., November, 1914.

Case 4: Figure 11.

Case 4: Figure 12.

Case 5: Figure 13.

Case 6: Figure 14.

Case 7: Figure 15.

Case 7: Figure 16.



Case 7: Figure 17.

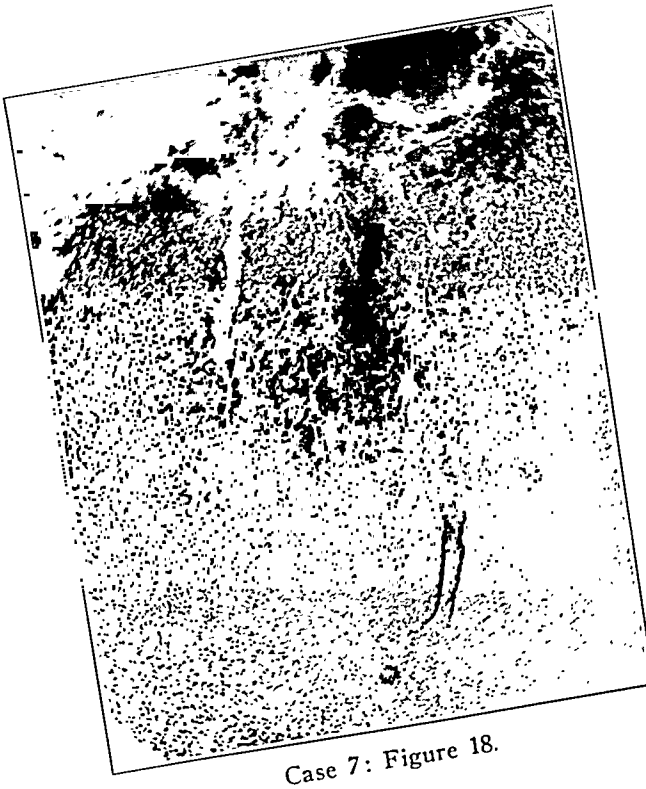

Case 7: Figure 18.

Both the upper tibia and the lower femur are necrotic. A sinus tract extends from the knee down to the middle third of the leg, along the posterior muscle layers.

Microscopic study of the various tissues in this case shows extensive tuberculosis. Figure 15 shows an area of rapid bone destruction with the trabeculae becoming necrotic in a mass of granulation tissue with caseation. Figure 16 shows the joint cartilage resting on a mass of tuberculous granulations. Figure 17 shows extensive tuberculosis in the joint capsule. Figure 18 shows extensive tuberculosis in the wall of the sinus. Figure 19 shows a section through the tibial head with the periosteum. Here there is evident new bone formation. (The new bone formation will be discussed in Part II.)

Conclusions.—Aside from the clinical features of this case, the bare recital of which places enough emphasis on their significance, the case presents the

Case 7: Figure 19.

ultimate results in bone tuberculosis of extension from bone focus to joint, and to all the tissues, i. e., bone cartilage, synovial membrane, capsule, ligaments, muscle layers and skin.

Tuberculous lesions of all described types may be found in these tissues.

CASE 8 (Fig. 20).—*Tuberculosis of Spine.*—A laborer, aged 37, after an injury to the spine, developed typical Pott's disease, kyphosis developing at the fifth and sixth dorsal vertebrae. He became completely paraplegic, with no sensation below the ribs. Under the impression that an exudate might be pressing on the cord, laminectomy was performed. He made a good recovery, with no improvement. The excised laminae and spinous processes were sent to the laboratory.

Gross Pathology.—The tissue consists of several pieces of bone, some of which have muscles attached. The pieces range from 1.5 by 0.5 cm. to smaller particles. No granulation tissue was received.

Microscopic Pathology.—Figure 20 is a section through the spinous process. Very definite tuberculous destruction of bone with tubercles and caseation is seen.

Conclusions.—It is generally assumed that Pott's disease, or vertebral tuberculosis, is localized in the bodies of the vertebrae. It is usually so localized; but it may involve by extension the laminae and spinous processes.

Case 8: Figure 20.

CASE 9.—*Tuberculosis of Tarsal Bones.*—Figure 21 shows the process of healing after a tuberculous invasion of the cancellous bone. Here fibrous marrow has developed; the spaces between the trabeculae are occupied by fibrous tissue.

CASE 10.—*Tuberculosis of Shoulder.*—Figure 22 shows the fatty fibrous appearance of a healing bone lesion. The osteoblasts about the trabeculae may be noted also.

CASE 11.—*Tuberculosis of Knee.*—Figure 23 is a low power photomicrograph of a break through the joint cartilage following bone involvement in the cancellous bone of the tibia.

CASE 12 (Figs. 24, 25, 26, 27 and 28).—*Tuberculosis of Knee.*—Figure 24 is a photomicrograph of the specimen. It shows the gross changes that were observed. The articular surfaces of the femur, the tibia and the patella are covered with a thick granulation tissue. Very little cartilage remains, and that in small islands; but the original focus of bone involvement is shown in the tibial head, and is shown in direct communication with the joint cavity.

Case 9: Figure 21.

Case 10: Figure 22.

Case 11: Figure 23.



Case 12: Figure 24.

Case 12: Figure 25.



Case 12: Figure 26.

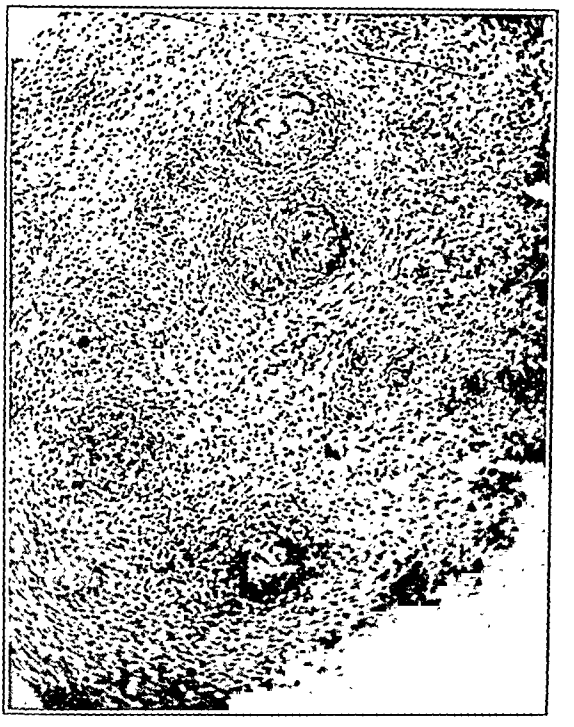

Case 12: Figure 27.

Case 12: Figure 28.

The picture, judged from the gross findings, might be labeled chronic tuberculous synovitis. Microscopic study of the sections reveals extensive tuberculous involvement of cancellous bone (Fig. 25), marked atrophy of bone (Fig. 26), extensive tuberculosis of the joint capsule (Fig. 27), and involvement of the periosteum with proliferation of new bone on the tibial surface (Fig. 28).

Conclusion.—We have here a typical picture of joint involvement occurring with bone tuberculosis. The microscopic findings reveal in the specimen areas that would correspond to most of the classifications of the lesions of the disease. The proliferation of new bone noted in Figure 28 will be discussed in Part II.

SUMMARY OF PART I

The material thus far selected, with three exceptions, reveals the well recognized classical picture of skeletal tuberculosis. The clinical characteristics of this picture are the onset, indicating bone involvement, and the gradual extension, indicating joint involvement. Pathologically, we have in this group the classical pictures also of bone and joint tuberculosis, a slow process with bone destruction, poor healing ability, and this by fibrous tissue, joint destruction with abscess formation, and ankylosis, if the diseased person survives the process sufficiently long. The three exceptions are the pictures of proliferation discovered in the cases in which the disease process had progressed far enough from the cancellous ends of the bone to reach the region where periosteum is found. This tissue responds to infection by rapid proliferation and well illustrates in three instances the point I wish especially to emphasize: The nature of the tissue in its reaction to infection determines the anatomic pathologic condition which results. The results of the search through this material lead to the conclusion that bone tuberculosis has its origin, in the great majority of instances, in the cancellous bone, and its extension to the neighboring tissues with their individual characteristics of reaction to infection explains the various types of the disease.

PART II. BONE TUBERCULOSIS WITHOUT JOINT INVOLVEMENT

It is essential to understand that I regard what is to follow as a report of atypical tuberculous lesions. As stated before, the typical lesion of skeletal tuberculosis is that of bone involvement with joint involvement, going hand in hand. I believe the primary lesion to be osseous, because I have not discovered a primary lesion in other tissues. In all cases, the joint changes and the bone changes are, as a rule, closely associated.

In this portion of the study, I have included those cases that presented bone disease without joint involvement. I do not believe with Stiles and Fraser that this type of lesion is common. At least, it is not so in America. I do wish to point out that Stiles' and Fraser's observa-

tions are correct, and to add my testimony to the truth of Fraser's statement that "hypertrophic" tuberculous lesions do exist. In Fraser's[3] work, "Tuberculosis of the Bone and Joints in Children," he describes a type of bone tuberculosis which he calls "the hypertrophic tuberculous lesion." After a careful description of this lesion as a type, he states in a footnote that he believes that here we are dealing with a syphilitic lesion which has secondarily become infected with tuberculosis. He was led to this statement by the fact that the cases he has studied had not been definitely determined as nonsyphilitic. I wish to show that in all probability, most of his work on what he calls the "hypertrophic" type of tuberculous infection was correctly observed. Before this, in this study, I have cited three instances in which tuberculosis of bone was characterized by new bone formation. I have pointed out that the reason for this is that the infection had gained a foothold in the periosteal region of the bone, and that the periosteum reacts to infection by marked proliferation.

Fisher and 1[4] have described in some experimental work on bone tuberculosis the lesions that take place when the subperiosteal region in dogs' bones was infected with tuberculosis. It showed that tuberculosis could develop subperiosteally as well as in the cancellous bone. Ely has deduced a theory at variance with this experimental fact. His theory also is at variance with the observations of Fraser on the so-called "hypertrophic tuberculous lesion." A study of the cases in this group will throw some additional light on this discussion.

Case 13 (Figs. 29, 30, 31, 32, 33 and 34).—A child, aged 5 years, presented peculiar bone lesions resembling chronic pyogenic osteomyelitis. The Wassermann reaction was negative; the tuberculin test positive; the right ulna, left ulna, and middle of the shaft of the left tibia were involved. Portions of the diseased shafts were removed by operation.

Gross Pathology.—Specimens consist of several fragments of bone and soft tissue. One labeled "new formed subperiosteal bone" consists of bone fragment, 1 cm. in diameter, and 2 mm. in thickness. Another specimen is a portion of the hard cortical bone of the shaft. A third, labeled "medullary cavity," consists of ragged soft tissue adherent to cancellous bone. One or two small white bodies resembling tubercles are seen in this tissue.

Microscopic Pathology.—Figures 29 and 30 show tuberculous lesions in the bone similar in all respects to rapid destruction of cancellous bone by tuberculosis, especially in Figure 30, in which there is a caseating mass of granulation tissue surrounding necrotic trabeculae. In Figure 31, we observe a mass of new bone, rapidly proliferating in close proximity to a mass of tuber-

3. Fraser: Bone and Joint Tuberculosis in Children, New York, The Macmillan Company, 1914, p. 26.

4. Allison, N., and Fisher, R. F.: Experimental Bone Tuberculosis, Am. J. Orthop. Surg. **14**:631 (Nov.) 1916.

Case 13: Figure 29.

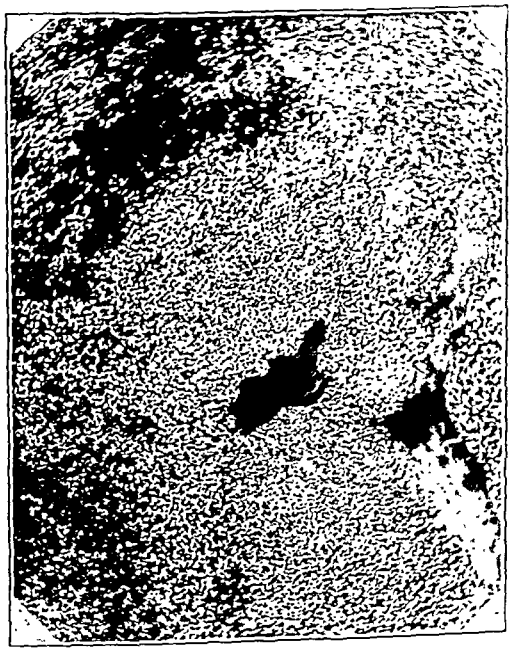

Case 13: Figure 30.

Case 13: Figure 31.

Case 13: Figure 32.

Case 13: Figure 33.

Case 13: Figure 34.

culous granulations. In Figure 32, we have subperiosteal new bone formation, with very active new bone growth. The tissue is fibrous and of increased vascularity.

In Figure 33, to which I wish especially to call attention, we have the compact bone of the shaft of the tibia, and located in it is a tuberculous focus.

In Figure 34, we have a beautiful picture of periosteal tuberculosis, with marked bone proliferation. Of especial significance in these observations is the fact that this child was proved, as far as clinical tests go, to be syphilis negative, and the guinea-pigs inoculated with the material proved tuberculous. Here, then, we have definite new bone proliferation alongside of bone destruction, associated with the activity of the tubercle bacillus. The occurrence of the pure focus of tuberculosis in the compact bone of the shaft shown in Figure 33 offers positive proof that a tuberculous lesion may occur in compact as well as in spongy bone. It is worthy of note that although some of the process is distinctly of the character of "hypertrophic" tuberculosis, destructive lesions are abundant in the tissue.

Case 14 (Figs. 35 and 36).—*Tuberculosis of Ankle Joint.*—Figure 35 is a slightly enlarged photomicrograph of a frontal plane section of the tibia, just at the malleoli. There is very evident bone atrophy; the trabeculae are small and have lost their normal architectural arrangement. At the side is a large tuberculous abscess. Here there is caseation and rapid bone destruction.

Figure 36 is a photomicrograph of a section from just above the abscess through the periosteum and cortex of the tibia. Here we see rapid and extensive new bone formation as a reaction to tuberculous involvement.

Case 15 (Fig. 37).—*Tuberculosis of Knee.*—Here we have extensive and rapid bone proliferation in a section through the periosteum of the tibia, in which the knee was extensively involved in tuberculous disease.

Case 16 (Fig. 38).—*Tuberculosis of Lesser Trochanter.*—A negro, aged 45, for four months had had a lump in the groin, had become unable to walk, and had been confined to bed five weeks. His thigh was swollen. The roentgen ray showed a mass near the lesser trochanter. He was operated on.

Gross Pathology.—The tissue consists of bone from the region of the lesser trochanter and pus from the abscess cavity. The bone is slightly spongy and is 4 by 3 by 2 cm. in size.

Microscopic Pathology.—Sections of this exostosis show newly formed bone in a mass of granulation tissue with definite tubercle formation.

A guinea-pig inoculated with the material showed extensive peritoneal tuberculosis. Figure 38 is a photomicrograph of the granulation tissue in this case. It is definitely of tuberculous character; but there might remain some doubt were it not for the positive guinea-pig reaction. Here we have a pure tuberculous exostosis of a long bone.

Case 17 (Figs. 39, 40, 41 and 42).—*Tuberculosis of Shaft of Humerus.*—A girl, aged 11 years, had had a swelling about the left elbow for five months. The roentgenogram showed large cauliflower-like expansion of the lower third of the shaft of the humerus. The diagnosis was periosteal sarcoma. Amputation was advised but refused by the child's parents. The lower 15 cm. of the humerus was excised. A bone graft was substituted. Subsequent history showed good recovery.

Macroscopic Pathology.—Figure 39 is a drawing of the gross specimen. The shaft at the site of amputation appears normal. There is fusiform swelling of bone. The tumor seems to be some type of subperiosteal growth.

Case 14: Figure 35.

Case 14: Figure 36.

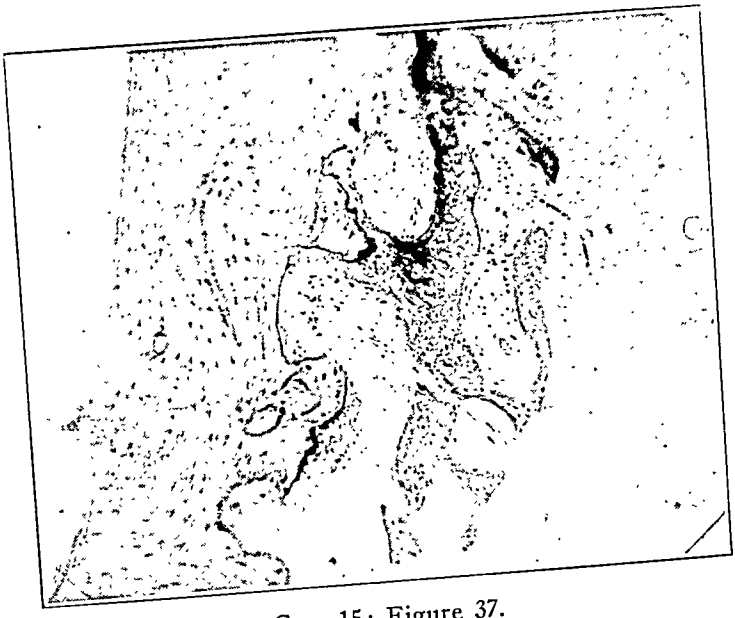

Case 15: Figure 37.



Case 16: Figure 38.

Case 17: Figure 39.

Case 17: Figure 40.

Case 17: Figure 41.

Microscopic Pathology.—Sections show the tissue to be in
are large areas of new bone formations (Fig. 42); the nar
newly formed bone are filled with dense fibrous tissue. T
tumor show an active inflammatory process. There are are
giant cells (Fig. 40) and with typical tubercles.

Figure 41 shows fields of less active destructive proces
ments more evident than in Figure 40.

It is to be noted that this case was not proved to be tub
inoculation. The child was syphilis negative. The subseq
also be against syphilis. I am inclined to believe that he
of pure subperiosteal tuberculosis, with hypertrophic bo
predominating process. There are, however, in the specim
typical rapid tuberculous destruction of bone. This case
so well described by Fraser.

Case 17: Figure 42.

CASE 18 (Figs. 43 and 44).—*Tuberculosis of Tarsus.*—
tuberculous bone lesion is accomplished by the formatio
Around the area of disease, all tissues tend to become fi
loses its cellular character and becomes fibrous or fatty-
43 and 44, this process is well shown. In Figure 43, the i
is still active, but to be noted are the increased amount c
new bone cells. In Figure 44, the process is very well ac
blasts about, and the greatly increased number of bone ce
also the dense fibrous tissue filling the marrow space are

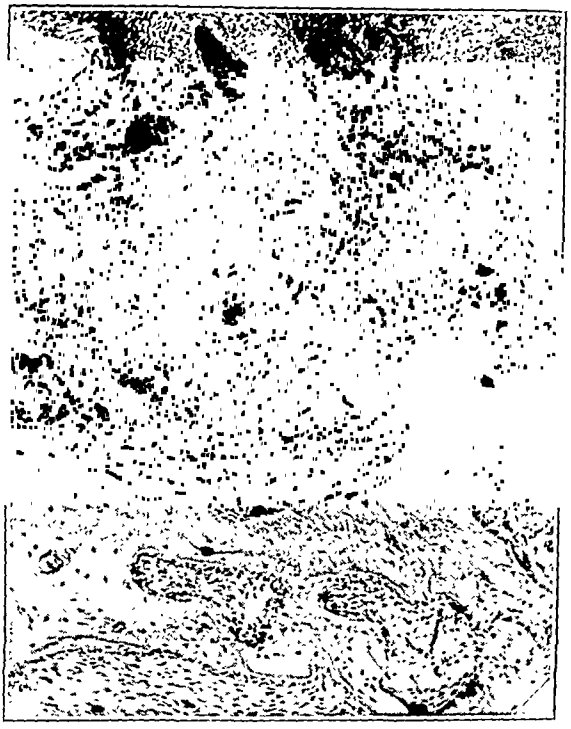

Case 18: Figure 43.

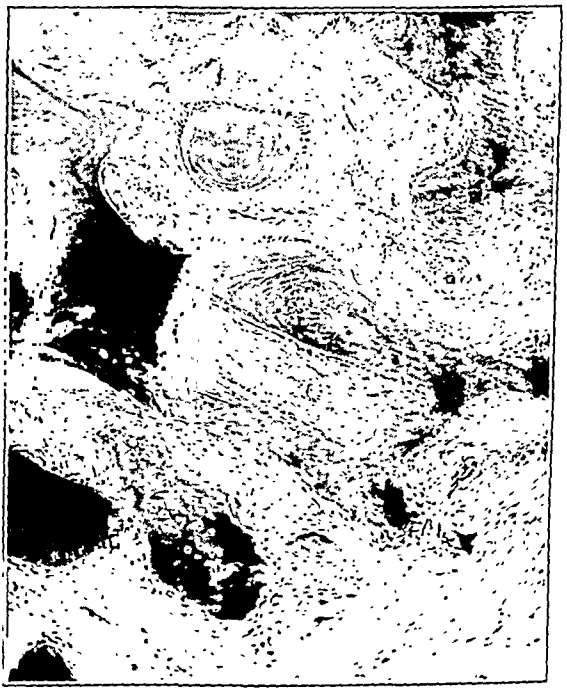

Case 18: Figure 44.

SUMMARY OF PART II

The material grouped here has as its characteristic the involvement of the shafts of the bones away from the epiphyses. It is characterized by a marked tendency to bone proliferation, and might be regarded as "hypertrophic" in type. It is to be observed, however, that the picture of proliferation is accompanied in each specimen by areas that have typical destructive lesions; in consequence, we should not lose sight of the fact that tuberculous lesions behave in a manner directed by the tissue reaction to infectious processes.

When the tubercle bacillus invades tissues which in their reaction to infection readily produce new bone, the lesion observed has as one of its characteristics *new bone formation.*

When the tubercle bacillus invades tissues which in their reaction to infection do not readily produce new bone, the lesion observed has *not* as one of its characteristics new bone formation.

In all instances in this study in which tuberculous bone lesions were observed, there was both bone destruction and bone proliferation. When cancellous bone was involved, destruction predominated. When compact bone was involved, proliferation predominated.

CONCLUSIONS

Tuberculosis may involve any portion or tissue of the bony framework of the body.

Tuberculosis is by far more frequently localized in the ends of the bones, and as a consequence, generally involves a joint or joints.

The pathologic process is to be regarded as not essentially different in its manifestations wherever it may occur. If tissues are involved that possess the property of rapid proliferation when infected, this process will be observed when the tubercle bacillus is the agent. If tissues are involved which do not rapidly proliferate under infection, destruction will be observed when the tubercle bacillus is the agent.

It is cumbersome, confusing, and in a sense wrong, to describe the process of tuberculosis separately, as it affects bone tissue of various types and joint structures. It is all one and the same. The variations are due only to the characteristics of the tissue infected.

It is also unwarranted to classify this disease as to the type of reaction observed. I believe that search will reveal most types of process in practically any well established lesion. I mean by this, that I am opposed to the terms employed in the older literature as classifications, such as infiltrating, atrophic, caseous and hypertrophic tuberculosis of the bone. This is especially true of such descriptive terms as "chronic synovial tuberculosis" and "fungating" or "granulating tuberculous

Case 18: Figure 43.

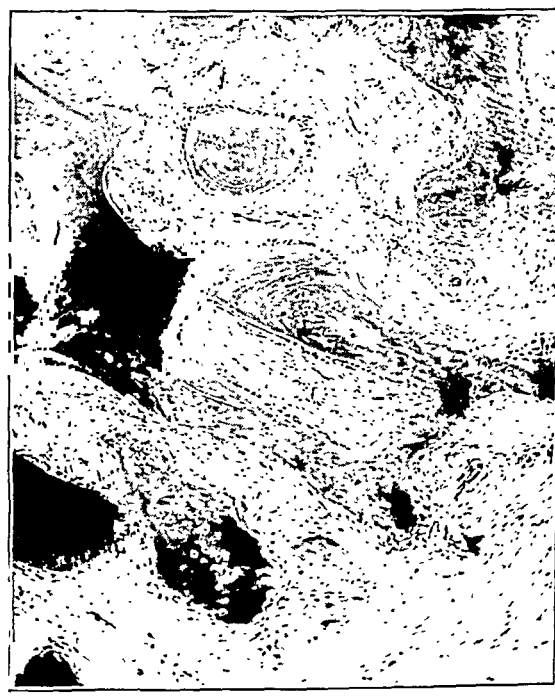

Case 18: Figure 44.

SUMMARY OF PART II

The material grouped here has as its characteristic the involvement of the shafts of the bones away from the epiphyses. It is characterized by a marked tendency to bone proliferation, and might be regarded as "hypertrophic" in type. It is to be observed, however, that the picture of proliferation is accompanied in each specimen by areas that have typical destructive lesions; in consequence, we should not lose sight of the fact that tuberculous lesions behave in a manner directed by the tissue reaction to infectious processes.

When the tubercle bacillus invades tissues which in their reaction to infection readily produce new bone, the lesion observed has as one of its characteristics *new bone formation.*

When the tubercle bacillus invades tissues which in their reaction to infection do not readily produce new bone, the lesion observed has *not* as one of its characteristics new bone formation.

In all instances in this study in which tuberculous bone lesions were observed, there was both bone destruction and bone proliferation. When cancellous bone was involved, destruction predominated. When compact bone was involved, proliferation predominated.

CONCLUSIONS

Tuberculosis may involve any portion or tissue of the bony framework of the body.

Tuberculosis is by far more frequently localized in the ends of the bones, and as a consequence, generally involves a joint or joints.

The pathologic process is to be regarded as not essentially different in its manifestations wherever it may occur. If tissues are involved that possess the property of rapid proliferation when infected, this process will be observed when the tubercle bacillus is the agent. If tissues are involved which do not rapidly proliferate under infection, destruction will be observed when the tubercle bacillus is the agent.

It is cumbersome, confusing, and in a sense wrong, to describe the process of tuberculosis separately, as it affects bone tissue of various types and joint structures. It is all one and the same. The variations are due only to the characteristics of the tissue infected.

It is also unwarranted to classify this disease as to the type of reaction observed. I believe that search will reveal most types of process in practically any well established lesion. I mean by this, that I am opposed to the terms employed in the older literature as classifications, such as infiltrating, atrophic, caseous and hypertrophic tuberculosis of the bone. This is especially true of such descriptive terms as "chronic synovial tuberculosis" and "fungating" or "granulating tuberculous

synovitis." Here the observer has described one phase of a tissue reaction, as a pathologic and clinical entity.

My observations on this series of fifty cases incline me to believe with E. H. Nichols that the disease is primarily osseous.

I am also of the belief that the disease may occur more frequently than is generally believed in the regions of the skeleton away from the joints, and that this fact should be emphasized in the teaching of the characteristics of this disease.

Editorial Review

THE TREATMENT OF ACUTE *EMPYEMA*

The pleural and peritoneal cavities are similar in their embryology, physiology and pathology. The character and arrangement of their contents constitute an important difference, as does also the constitution of their walls. The mobile intestines, with their mesenteries, also the omentum, aid in localizing infective processes and hinder the establishment of effective drainage. The yielding abdominal wall normally keeps the peritoneal cavity a potential, instead of an actual, cavity, while in the chest it is the expanding of the lung which does the same thing for the pleura, the chest wall remaining rigid. As disease commonly impedes pulmonary expansion, it is much more common to have an actual, instead of a potential, pleural cavity, than to have such a condition in the peritoneum. When an intra-abdominal organ, such as the appendix vermiformis, becomes the site of an infective lesion, the diffusible toxins spread beyond the focus of infection and give rise to the phenomena of inflammation in the adjacent peritoneum. There is effusion of lymph, and an adhesive tumor forms, which commonly localizes the infection so that, unless interfered with by injudicious treatment or abuse, resolution takes place or an abscess forms. If the original infection is very virulent, there is no time for the development of protective inflammatory processes and wide-spread infection of the peritoneum results. Absorption of toxins may cause fatal poisoning or dissemination of microbes may cause pyemia or septicemia.

In pneumonitis, of whatever origin, the pleura commonly becomes affected in a manner entirely analogous to that in which the peritoneum is involved. One may look upon pleuritis secondary to lung disease as an attempt on the part of Nature to give the lung rest, and, by means of temporary or permanent adhesions, to limit the area of the pleural cavity which will be exposed to the escape of infective material from the lung.

In croupous or pleuropneumonia (lobar pneumonia), the pleuritis is commonly of the protective variety, and with the subsidence of the pulmonary disease, the pleuritis also disappears. If, however, sufficient infection has passed from the lung into the pleuritic exudate, a localized or extensive empyema results. In these cases, the empyema develops or becomes evident only when the pneumonia is either cured or in process of cure. The empyema itself is then the menace to life and demands treatment.

In the pneumonias, common during epidemics of influenza and other acute infective fevers, the virulence of the infective agent is such that the pleura has no time or has insufficient resisting power to go through the changes necessary for the formation of a barrier of protective inflammation. The condition is entirely like that found in the peritoneum in fulminating appendicitis or in acute perforation of the stomach, but, whereas in peritonitis from such causes as this, the primary lesions are very limited in extent and may commonly be extirpated or closed by operation, in pleuritis the causative pulmonary lesion is not susceptible of surgical removal or repair.

As might be expected in pleuritis following lobar pneumonia, the fluid effused is at first clear, then cloudy, and later it becomes thick creamy pus, containing masses of fibrinous material from the heavy croupous membrane so often formed on the pleura. In streptococcic empyema beginning during active pulmonary disease, the fluid, at first thin and dirty, has much less tendency to become a creamy pus. The pleural infection may appear on the side in which the lung is not involved, or with unilateral pneumonia, there may be bilateral empyema. Cases have been reported in which there has been a true empyema on one side and a sterile collection of clear or puslike fluid on the other. Complications are common, such as multiple abscesses of the lung or brain, nephritis, endocarditis, in fact, the usual phenomena of pyemia and septicemia.

As has already been noted, there is commonly recovery from the protective pleuritis as soon as the causative pneumonia has disappeared; but as in peritonitis, so also in pleuritis, this recovery may be accompanied by the formation of adhesions which may or may not be crippling. If an empyema has not been drained properly or early enough, the lung may fail to expand and obliterate the empyema cavity. This failure may be due to compression exerted by a thickening and contraction of the visceral pleura which result from Nature's efforts at healing, identical with the formation and contraction of scar tissue in any other locality. The lung itself may fail to expand because of atelectasis, or because of long compression during recovery from the pneumonitis, the reparative processes may have accommodated themselves to the diminished volume of the lung, and there is a state of fibrosis which is more or less stable.

INDICATIONS FOR TREATMENT

When empyema is present during the acute stages of pulmonary disease, one might at first think it proper to establish drainage in the hope (*a*) of lessening embarrassing pressure on the lung, and (*b*) of withdrawing large amounts of virulent toxins; but experience has

shown this to be fatally wrong. E. A. Graham [1] finds that in acute empyema, especially of streptococcic origin, there is a low vital capacity.[2] In the early stages, with cyanosis and air hunger, it is evidently difficult to obtain the tidal air which is now equal to the vital capacity; and even a small opening through the chest wall is fatal. In other words, when the acute pulmonary condition is such that the patient cannot inspire by a full effort more air than he could inspire in easy breathing, the tidal air and the vital capacity are equal, and any pneumothorax will decrease the quantity of air inspired.

When epidemics of influenza, measles, etc., invaded the training camps in 1917 and 1918, acute pneumonia and empyema promptly appeared. At first early operation was the rule, and the mortality was frightful (at Fort Riley, 61.2 per cent.). When late operation was adopted, the mortality fell to 26 per cent. and then to 7 per cent. (Stone's statistics, Fort Riley). The danger of early operation, that is, operation while the pneumonic process is active, was well known many years ago; but physicians and surgeons practicing in 1917 were accustomed to empyema following lobar pneumonia and obtained the best results from operation performed early as regards the empyema, but *late* as regards the pneumonia. This they called *early* operation, and they thought the earlier the operation was performed the better. They wrongfully applied the experience gained in treating one class of empyema to a totally different class.

Legendre [3] in a very practical manner divides patients with empyema into two classes: (1) those with "white dyspnea" in whom the dyspnea is moderate, the respiration rate being about 25 to 30 per minute. The pallor is due to toxemia. The pulmonary lesions are either extinct or are nearly well. In such cases, the beginning of the acute infection (influenza, measles, etc.,) dates back from twenty-six to fifty-eight days. The infective agents are various (staphylococci, streptococci, pneumococci, etc.). After operation, the fever subsides promptly, the dyspnea improves progressively, and recovery is the rule. (2) Those with "blue dyspnea" in whom the rate of respiration is from 45 to 50. There is marked cyanosis of the face and extremities. These symptoms are in proportion to the pulmonary and not the pleural lesions. Operation increases the dyspnea, has no effect on the fever and is generally promptly followed by death. According to Legendre, "Neither the nature of the microbe nor the precocity of the operation seems then to modify the prognosis of these purulent pleurisies. This seems to be

1. Graham, E. A.: Surg., Gynec. & Obst. **31**:60 (July) 1920.
2. Vital capacity is the volume of air which can be expelled from the lungs after a full inspiration.
3. Legendre, L.: Presse méd. **27**:22 (Jan. 16) 1919.

almost exclusively dependent on the condition of the subjacent lung and especially of the opposite lung. If the functional value of these is already defective because of extensive lesion, operation aggravates rather than ameliorates the situation." Graham and Legendre, approaching the subject from different angles and working in different countries, have thus come to identical conclusions.

PRINCIPLES OF TREATMENT

The first object of treatment is to keep the patient alive; the second is to obtain a return to perfect health, both functional and anatomic, as quickly and comfortably as possible. The first object must be sought by medical and dietetic treatment and by nursing. Good nutrition, good air and good elimination are essential. Palliative aspirations are often necessary. Vaccines do not seem to have been of much value, especially antistreptococcic vaccines. The treatment of the causative pneumonias belongs exclusively to the physician. Until the pneumonia is at least in process of cure, surgical intervention is almost always objectionable meddling. In the so-called "blue dyspnea," operation is always wrong. As soon as the pulmonary condition permits, provided the general condition of the patient does not forbid, surgical intervention becomes proper or imperative. The principles of surgical treatment are: (*A*) *drainage;* (*B*) *sterilization,* and (*C*) *lung expansion.* Every one is agreed on the necessity of carrying out these principles; the methods employed to carry them out are legion, and their merits are championed with enthusiasm or damned with cordiality.

DRAINAGE

When the empyema cavity is of very limited extent, it should be opened at any convenient point as indicated by roentgenograms and the exploring needle. Every one agrees that in all large empyemas the drainage should be established at the low point; but as will be seen later, the classical operations never fulfill this requirement, and their failure to do so probably accounts for the numerous and complicated methods devised to overcome faulty drainage. If one examines a cross-section of the chest, one is impressed by the depth of the gutter (costovertebral gutter) which exists on each side of the vertebral column, and by the fact that when the body is recumbent, this gutter constitutes the low point of the pleural cavity. An opening made at the angle of the seventh, eighth or ninth rib will drain the cavity absolutely when the body is recumbent. The low point varies much when the body is in the erect posture because the costodiaphragmatic sulcus is obliterated to a varying degree by adhesions. On the cadaver, Chevrier[4] found

4. Chevrier: Presse méd. **27**:9 (Jan. 9) 1919.

that resection of the sixth rib in the posterior axillary line permitted the retention of 650 c.c. of fluid in the recumbent posture and from 1,250 to 1,300 c.c. in the erect; while resection of the eighth rib in the scapular line caused retention of 300 c.c. in the recumbent posture and from 150 to 200 c.c. in the erect. It is difficult to define precisely the low point for the sitting posture by means of the fluoroscope, and dangerous by means of the aspirating needle. Exploratory operations for the same purpose have occasionally been disastrous, as the operator has penetrated the abdomen through an obliterated pleura and the diaphragm. It is essential that drainage be efficient, whether the patient is lying or sitting. The best plan by which to attain the desired aim is to open the chest by intercostal incision or by costectomy as near as possible to the angle of a convenient rib (seventh, eighth or ninth); and, after slow evacuation of pus, to explore, preferably with the finger, and thus find a point which will be "low" both for the recumbent and erect postures. At this point, guided by the exploring finger or instrument, the chest wall should be incised and tubular drainage established. Through one or both of the openings, it is easy to evacuate the great clots of fibrin so commonly present. Should it be impossible to find a point which will serve efficiently for both postures, the primary opening should be used for a tube, to act when the patient is lying, and the secondary opening should be made with reference to the erect posture alone. When the secondary opening suffices for drainage in both postures, the primary opening may be used for the insertion of Carrel tubes or may simply be covered with dressings. If the general condition of the patient is very poor, it is often wise merely to evacuate the pus through the first incision, and at a later day to complete the operation by exploring and making the second opening for real drainage. The object of the treatment outlined is: first, to keep the patient alive, and second, to establish real, automatic, fool-proof drainage, if possible with one tube, in such a way that it will be effective in any posture the patient is likely to assume.

Many methods have been devised to obtain drainage without permitting air to enter the pleura. Apparently the first of these methods was devised by Bulau,[5] who writes:

> You incise the skin, puncture the chest with a trocar and cannula between a fourth and a fifth inch wide, slip a soft rubber catheter through the cannula, put a clip on it, fix it to the chest wall, connect it by a piece of glass tubing with a long piece of rubber tube filled with lotion, and lower the long tube into some lotion. If you leave a coil of the tube loose on the bed, the patient's movements in bed will not stir the catheter. The objection to my method—that it leaves masses of fibrin in the chest—is unreasonable. I admit that the

5. Bulau: Ztschr. f. klin. Med. **18**:31, 1891, quoted by Paget: Surgery of the Chest, Appendix B.

The methods of Murphy, Lister and Hathaway aim to attain sterilization without drainage. Numerous surgeons have combined methods of sterilization with closed drainage, the drainage being either intermittent or constant and established essentially by Bulau's method. Mozingo [7] by means of a trocar introduces a small rubber tube (4 mm. in diameter) so that from 8 to 15 cm. of the tube (fenestrated) lies within the chest and 15 cm. is outside. Through this small tube, the pus is sucked out by means of a bulb syringe and salt solution, surgical solution of chlorinated soda (Dakin's solution) or liquor formaldehydi in glycerin is introduced. Between treatments, the tube is capped by rubber from a medicine dropper held in place by a serrefine to maintain the negative pressure established by the bulb syringe.[8]

In cases of empyema in which the pneumonia is still active and the temperature is high, Mozingo removes the pus and introduces salt solution every four to six hours for the first few days. Usually the treatments are repeated every two hours by day and every three hours by night. Once daily, the cavity is filled to about half its original capacity with the salt solution; this is to prevent the formation of pockets. As improvement develops, Dakin's solution is substituted for from two to fourteen days, and then once daily. After irrigating with Dakin's solution, a few ounces of 2 per cent. liquor formaldehydi in glycerin are introduced. Usually from three to ten days after beginning the injections of liquor formaldehydi in glycerin, the secretion becomes a sterile serosanguineous fluid, and the tube may be removed. Mozingo writes that he "has never seen a case of empyema too sick to be operated by the closed method and he has operated at least ten cases which were considered nearly moribund when operated." He reports 138 cases of empyema in which treatment by his method was employed with a 2 per cent. mortality rate.

Harloe [9] uses practically the same method as Mozingo, but keeps up constant drainage by means of an electric pump. Whittemore [10] advocates the "air tight" method with the electric pump. He believes in early operation, as "in delayed operation there is more danger of septicemia, pyemia and pericarditis." If after four or five weeks, sterilization is not complete, he resorts to costectomy and packing of the small cavity with gauze. It is easy to combine attempts at chemical sterilization with open drainage; but if the drainage has been properly

7. Mozingo, A. E.: J. Indiana M. A. **13**:46 (Feb.) 1920.

8. J. D. Bryant many years ago used a Politzer bag to establish and keep up negative pressure and receive discharges in ambulant patients.

9. Harloe, R. F.: Treatment of Empyema, J. A. M. A. **73**:1874 (Dec. 20) 1919.

10. Whittemore: Boston M. & S. J. **181**:575 (Nov. 13) 1919.

catheter often gets blocked at first, but either you can put this right by going down the tube with your finger and thumb, or you can syringe limewater up the tube, or in a day or two a fit of coughing will drive a lot of pus into the tube, and set it going again. If the patient keeps feverish, either there is suppuration round the puncture, or the tube is blocked; you had better wait and see what happens, for if you take out the catheter, you can hardly ever get it in again; you ought not to touch it for at least eight days. The catheter does not get nipped by the ribs, for with my method the chest does not fall in. If there is pain, the syphonage must be reduced, unless the pain be due to irritation of the pleura by the catheter. After some time you may let the patient get about, keeping the lower end of the tube in a bottle hung below his chest; later still, you may cut off the tube, and just keep the end of the catheter in place till all is healed. There is no need to wash out the pleura. Even if the pus be offensive, my method will be applicable to the case; but a gangrenous empyema depends on gangrene of the lung, and, therefore, resection is necessary

Bulau's operation was much criticized when promulgated and was given up. In recent years, it has been frequently rediscovered and modified in unessential details. It has also been employed to permit the application of sterilizing solutions to the pleura. It seems to me that Bulau's method, or some uncomplicated modification of it, may be a valuable means by which to tide over a critical period.

STERILIZATION

J. B. Murphy long ago concluded that the only logical plan for the treatment of empyemas, whether of the joints or the pleura, consisted in aspiration and sterilization. After aspiration, he injected a few ounces of 2 per cent. liquor formaldehydi in glycerin. The treatment was repeated, as required, at intervals of a few days, until the effusion became a sterile serosanguineous fluid which was permitted to stay until absorbed. Absorption might take from three to thirty months. His theory was that the liquor formaldehydi kills the microbes and favors polymorpholeukocytosis. The latter means increased numbers of phagocytes with serum containing trypsin resulting from dead polymorpholeukocytes. The trypsin converts albuminoids into peptones which are absorbable. Not much success has followed Murphy's method in the hands of other surgeons.

Frank Hathaway,[6] in cases of pneumococcal empyema, even when staphylococci, but never streptococci, are present, advocates opening the chest sufficiently to admit the hand, permitting removal of pus and all fibrin, separation of adhesions and irrigation with acriflavine until the solution returns clear, then filling the cavity with 2 per cent. iodoform-paraffin and closing with sutures. During the after-treatment, it is necessary to remove with the aspirator each day such iodoform-paraffin as escapes from the chest under the skin. Hathaway remarks that Lord Lister carried out similar treatment twenty-five years before him.

6. Hathaway, Frank: Brit. M. J. 1:734 (May 29) 1920.

I feel strongly that in empyema the chest should be opened at the angle of the seventh, eighth, or ninth rib, and after slow evacuation of the pus, the finger should explore the cavity and find that point which will be "low" both for the erect and recumbent postures. At this low point, free drainage should be established. If the drainage is established properly, and at the proper, not necessarily the classical, places, Nature will almost surely provide far better sterilizing agents than can the laboratory of the chemist.

J. F. Binnie, M.A., C.M.,
Kansas City, Mo.

established and is automatic and "fool-proof," there can be no retention of the sterilizing fluids, and one must have recourse to constant irrigation instead of intermittent instillation and removal of the solutions. When chemical sterilization is desired, Chevrier suggests that it can be more easily and effectively accomplished by means of gases than by liquids. It is easy to pass air, or better, oxygen, through a wash bottle containing ether, liquor formaldehydi or some such volatile material, and conduct it into the pleura through the dependent drainage opening, whence it spreads uniformly through the whole cavity to be sterilized.

In a small proportion of cases in which the simpler methods of drainage have failed, it will be necessary to adopt more extensive and hazardous measures, such as Lilienthal has dubbed "major thoracotomy." By this means, it is possible to survey the diseased regions openly, and, using surgical judgment, to recognize and treat the cause of failure of the simpler procedures. Interlobar or other pockets may be properly opened; lung abscesses treated while sclerosed and contracted membranes covering the visceral pleura may be stripped off (Delorme, Fowler) or incised in criss-cross fashion (Ransohoff). In fact, the ordinary principles of surgery may be carried out, and, if possible, the horrible operations of thoracoplasty avoided.

LUNG EXPANSION

Whatever method or methods are used for the treatment of empyema, it is essential that the lung must be encouraged to expand into its normal position against the chest wall. Blowing exercises are of great value as are also calesthenics or "setting up" exercises properly supervised. The exercises should be such as are interesting to the patient, otherwise they will be dodged as much as possible.

A review of the recent literature on empyema makes it plain that good results may be obtained by various means. There are many roads to Rome. Some travelers like hilly paths, while others prefer the smoother highways. Some surgeons require the stimulus of complicated methods; others prefer less complex, but equally efficient, means. Only the poor and the very rich can afford the constant expert attention required for the successful use of some of the more complicated methods devised for the treatment of empyema. Dodge[11] writes:

> I am now firmly of the opinion that the long established principles of surgery as evolved by many years of experience in civil life and enunciated in practically every textbook on surgery as the proper treatment of empyema have not been shaken from their foundation by any of the fads and fancies evolved during the war period.

11. Dodge, W. T.: Empyema at Base Hospital, Camp Sherman, Ohio, J. A. M. A. **72**:1808 (June 21) 1919.

INDEX TO VOLUME 2

PAGE

Jejunum, diverticula of. W. I. Terry and F. R. Mugler..... 347

Johns Hopkins Hospital. A short account of the deaths occurring in the gynecologic service of the Johns Hopkins Hospital during the year 1919. H. N. Shaw..... 535

Kidney. Effect on the kidney of various surgical procedures on the blood supply, capsule, and on the ureters. S. W. Harrington..... 547

Liver. Relation of chronic fibrosis and thrombophlebitis of the spleen to conditions of the blood and of the liver. W. J. Mayo..... 185

Low, H. C.: Progress in orthopedic surgery: fourteenth report of progress in orthopedic surgery..... 367

Mattill, P. M.: The rôle of the ureteral lymphatics in experimental urinary tract infections 153

Mayo, W. J.: The relation of chronic fibrosis and thrombophlebitis of the spleen to conditions of the blood and of the liver..... 185

Meyer, A. W.: Unrecognized destruction of the tendon of the long head of the biceps brachii..... 130

Miller, E. M.: Nerve suture: an experimental study to determine the strength of the suture line..... 167

Mugler, F. R.: Diverticula of the jejunum..... 347

Myeloma. The relation of multiple vascular tumors of bone to myeloma. H. G. Wells 435

Neoplasms, effect of combined radiation and heat on. G. L. Rohdenburg and F. Prime..... 116

Nerve suture: an experimental study to determine the strength of the suture line. E. M. Miller..... 167

Occupational destruction, unrecognized, of the tendon of the long head of the biceps brachii. A. W. Meyer..... 130

Orthopedic surgery, progress in: fourteenth report. R. B. Osgood, R. Soutter, M. S. Danforth, H. C. Low, H. Bucholz, L. T. Brown and P. D. Wilson 367

Osgood, R. B.: Progress in orthopedic surgery: fourteenth report of progress in orthopedic surgery 367

Pancreas. Accessory pancreatic tissue; report of two cases. F. J. Horgan.. 521

Pemberton, J. deJ.: Surgery of substernal and intrathoracic goiters..... 1

Perthes' disease. Operation for epiphysitis of the head of the femur: findings and result. D. B. Phemister..... 221

Pes cavus (hollow claw foot), treatment of. A. Steindler..... 325

Peterman, M. G.: The association of hepatitis with experimental cholecystitis and its bearing on the pathogenesis of cholecystitis in the human 92

Phemister, D. B.: Operation for epiphysitis of the head of the femur (Perthes' Disease): findings and result..... 221

Priest, W. S., Jr.: The association of hepatitis with experimental cholecystitis and its bearing on the pathogenesis of cholecystitis in the human 92

Prime, F.: Effect of combined radiation and heat on neoplasms..... 116

Prostatectomy, prognosis in. J. B. Deaver and L. Herman..... 231

INDEX TO VOLUME 2

PAGE

Danforth, M. S.: Progress in orthopedic surgery: fourteenth report of progress in orthopedic surgery 367

David, V. C.: The rôle of the ureteral lymphatics in experimental urinary tract infections 153

Deaver, J. B.: Prognosis in prostatectomy 231

Diathermy. Effect of combined radiation and heat on neoplasms. G. L. Rohdenburg and F. Prime..... 116

Diverticula of the jejunum. W. I. Terry and F. R. Mugler..... 347

Diverticulum of the first portion of the duodenum. E. K. Cullen..... 542

Duodenum, diverticulum of the first portion of. E. K. Cullen..... 542

Eisendrath, D. N.: The histogenesis of malignant tumors of the testicle.... 493

Elbow. Observations on the normally developing elbow. I. Cohn..... 455

Empyema, acute, treatment of. J. F. Binnie..... 627

Epiphysitis of the head of the femur (Perthes' disease), operation for. D. B. Phemister 221

Exhaustion, studies in: an experimental research. G. W. Crile..... 196

Femur. Operation for epiphysitis of the head of the femur (Perthes' disease): findings and result. D. B. Phemister..... 221

Femur. Treatment of fracture of the femur. K. Speed..... 45

Fibrosis and thrombophlebitis of the spleen, relation of, to conditions of the blood and of the liver. W. J. Mayo..... 185

Fistula. Midline congenital cervical fistula of tracheal origin. M. G. Seelig 338

Fracture of the femur, treatment of. K. Speed..... 45

Fracture reduction and fixation with a specially designed band. A. W. Collins 354

Fractures, repair of bone following. J. A. Blake..... 37

Goiter, exophthalmic. Are there reliable criteria of operability in exophthalmic goiter? David Cheever..... 21

Goiters, substernal and intrathoracic, surgery of. J. deJ. Pemberton..... 1

Grafts, epithelial, correction of scar tissue deformities by: report of five cases. E. B. Spaeth 176

Graham, E. A.: The association of hepatitis with experimental cholecystitis and its bearing on the pathogenesis of cholecystitis in the human.... 92

Graves, W. P.: The gynecologic significance of appendicitis in early life.. 315

Gurd, F. B.: Reactions to the parenteral introduction of horse serum in man 409

Harrington, S. W.: The effect on the kidney of various surgical procedures on the blood supply, capsule, and on the ureters..... 547

Hepatitis, association of, with experimental cholecystitis and its bearing on the pathogenesis of cholecystitis in the human. M. G. Peterman, W. S. Priest, Jr., and E. A. Graham..... 92

Herman, L.: Prognosis in prostatectomy..... 231

Horgan, E. J.: Accessory pancreatic tissue; report of two cases..... 521